

Pleural Nocardiosis in an Immunocompetent Patient: A Case Report

SMITHA BAGALI¹, PRAKASH MANTUR²

ABSTRACT

Nocardiosis is a rare infection that has attracted attention with its increased rate of occurrence in the recent years. In India there is a rare documentation of the pleural involvement in nocardiosis. We report here a case of pleural nocardiosis caused by *Nocardia brasiliensis* in an immunocompetent patient. This case highlights the importance of considering nocardiosis as a differential diagnosis in patients with pleural lesions.

Keywords: *Nocardia brasiliensis*, Pulmonary nocardiosis

CASE REPORT

A 45-year-old male patient presented with complaints of dyspnoea, cough with expectoration and haemoptysis since one month. He also had right sided chest pain, generalized weakness and anorexia. The patient suffered from rheumatic heart disease (RHD) for the past ten years and under penicillin treatment every 21 days. He had no past history of tuberculosis, chronic obstructive pulmonary disease, trauma or any kind of surgery.

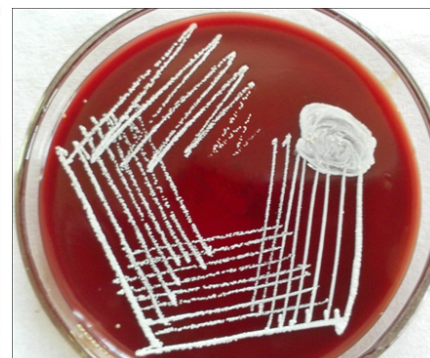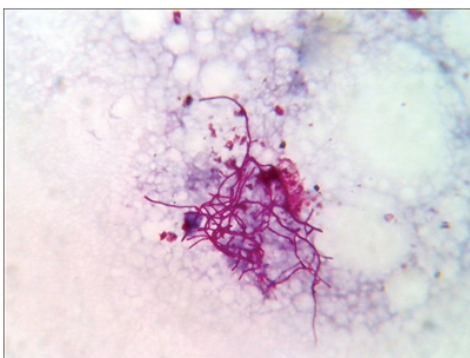
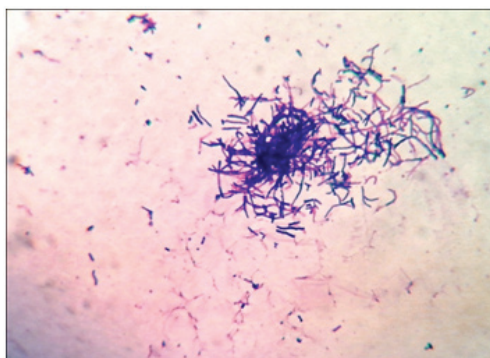
On examination, he was thin built. His pulse rate was 90 per minute, blood pressure 110/80 mmHg, respiratory rate 22 per minute and body temperature 98° F. Physical examination revealed bilateral pedal oedema. Examination of the chest revealed diminished breath sounds and dullness to percussion over the right lower lobe region. Examination of the other systems was unremarkable. His haemoglobin was 15.5 gm%, ESR 45 mm/h, total leukocyte count 18,300 /cu. mm with neutrophil 85%. Random blood sugar was 114 mg/dl, serum creatinine: 1.1 mg/dl and blood urea: 40 mg/dl. Chest X-ray revealed right sided pleural effusion and cardiomegaly, 2D echocardiography showed RHD with grossly dilated left atrium with severe mitral regurgitation. The ELISA test for human immunodeficiency virus antibodies was negative.

Thoracocentesis was performed after taking written consent from the patient and 600 ml straw coloured pleural fluid was drained. Pleural fluid adenosine deaminase was 210 IU/L. Pleural fluid cytology was negative for malignant cells. Gram stained smear of pleural fluid showed the presence of gram positive branching filamentous bacteria [Table/Fig-1]. Conventional Ziehl Neelsen staining for AFB was negative, however modified Ziehl Neelsen staining using 1% sulphuric acid showed acid fast branching filaments suggestive of *Nocardia* species [Table/Fig-2]. Blood agar and Sabouraud's dextrose agar after 48 hours of incubation

revealed dry whitish to tan colonies, which on further incubation showed the typical raised, chalky white dry colonies [Table/Fig-3]. Gram stained smear from the culture showed gram positive filamentous bacteria and modified Ziehl-Neelsen staining revealed acid fast filamentous bacteria. Presuming *Nocardia*, isolate was assigned to traditional grouping based on hydrolysis of casein, tyrosine, xanthine and hypoxanthine. Clearing of tyrosine and hypoxanthine crystals was observed after seven days of incubation indicating the isolate to be *Nocardia brasiliensis*. Patient was put on empirical antibiotic treatment with piperacillin and tazobactam. However, the patient succumbed before the specific treatment for *Nocardia* could be initiated.

DISCUSSION

Nocardiosis is a localized or systemic infection caused by species of the genus *Nocardia* [1]. Nocardiae are aerobic actinomycetes that are found worldwide in soil, decaying organic plant matter and water [1,2]. More than 50 species of *Nocardia* have been recognized till now, on the basis of their phenotypic and molecular characters. Among these, around 22 species have been identified as potential pathogens, the most common one being the *N. asteroides* complex (*N. asteroides sensu strictu*, *N. farcinica*, *N. nova* and *N. abscessus*). The other medically important species are *N. brasiliensis*, *N. otitidiscaviarum*, *N. africana*, *N. brevicatena* complex, *N. carnea*, *N. paucivorans*, *N. pseudobrasiliensis*, *N. transvalensis* and *N. veteran* [3]. *N. asteroides* is commonly associated with pulmonary infection and *N. brasiliensis* with localized skin disease [4]. Most of the *Nocardia* infections are acquired through inhalation. Organism can also be acquired by direct inoculation of the skin and subcutaneous tissue resulting in primary cutaneous nocardiosis [3].



[Table/Fig-1]: Photomicrograph of pleural fluid showing gram positive filamentous branching rods. (Gram's stain, ×1000). **[Table/Fig-2]:** Photomicrograph of pleural fluid showing acid fast branching filamentous bacilli. (Modified Ziehl Neelsen stain, ×1000). **[Table/Fig-3]:** Blood agar plate showing chalky white dry colonies of *Nocardia brasiliensis*.

Pulmonary nocardiosis is an infrequent but serious opportunistic infection that commonly presents as a sub-acute or chronic necrotizing pneumonia, mimicking tuberculosis, lung carcinoma or abscess [1,4]. Pleural involvement in pulmonary nocardiosis is seen in 25% of cases including pleural effusions and empyema [3]. Pleural involvement in nocardiosis is rarely reported from India [5-8]. *Nocardia asteroides* complex is the most common cause of pleuropulmonary nocardiosis [2,3,9]. Pleural involvement due to *Nocardia brasiliensis* is rare. Among the Indian studies, two cases of pleural nocardiosis caused by *Nocardia brasiliensis* have been documented [5,6]. In both the cases aetiological agent was isolated from pleural fluid as in our case.

Nocardiosis occurs mostly in patients that are undergoing corticosteroid therapy or have systemic immunosuppression. The underlying conditions commonly seen in patients with nocardiosis are solid organ transplantation, diabetes, autoimmune diseases, chronic lung disease, chronic granulomatous disease, chronic alcoholism and HIV infection [10,11]. Nocardiosis affects mainly immunocompromised patients but it may also occur in immunocompetent patients. Some previous reports ascertained that 10-20% of patients with nocardiosis had no preexisting illness or immunosuppressive therapy [4,10]. The indexed patient was neither immunocompromised nor receiving any corticosteroid therapy. The possible risk factor in our case is presence of rheumatic heart disease as underlying illness predispose the individual to nocardial infection.

Patil et al., have reported a fatal case of pulmonary nocardiosis in an adult male patient with no obvious immunocompromised conditions [12]. But the patient had co-morbid conditions such as diabetes, cardiomyopathy and bronchial asthma. Kontogiorgi M et al., have also reported a case of pulmonary nocardiosis in an elderly immunocompetent individual with Chronic obstructive pulmonary disease [13]. They studied the innate immune responses in the patient and have given evidence for association between defective innate immune responses and occurrence of pulmonary nocardiosis. Another case report by De S et al., described pulmonary nocardiosis mimicking relapse of pulmonary tuberculosis in an immunocompetent young female [14]. The patient was initially diagnosed as pulmonary tuberculosis for which she received antitubercular treatment for six months. After completion of therapy the patient presented with cavitary lesion in the left upper zone and later diagnosis of pulmonary nocardiosis was ascertained.

Trimethoprim-sulfamethoxazole remains the drug of choice for the treatment of nocardiosis. At times, sulfa drug cannot be used

for treatment due to allergy, intolerance, toxicity or treatment failure with sulfa drug. To choose an alternative drug, the infecting *Nocardia* species and susceptibility pattern should be taken into consideration. Non sulfa drugs found effective against *Nocardia* species are amikacin, minocycline, imipenem, meropenem, ceftriaxone, cefotaxime, erythromycin, moxifloxacin, levofloxacin, linezolid, tigecycline, and ticarcilin/clavulanic acid. In view of the propensity of relapsing disease treatment is required for a prolonged period, which may vary from 6-12 months [15].

CONCLUSION

This particular case emphasizes the need for high index of clinical suspicion of pulmonary nocardiosis. Nocardiosis should be considered even in a patient without any risk factor, particularly if they are not responding to treatment for a more common infection.

REFERENCES

- [1] Lerner PI. Nocardiosis. *Clin Infect Dis*. 1996;22:891-905.
- [2] Saubolle MA, Sussland D. Nocardiosis: Review of clinical and laboratory experience. *J Clin Microbiol*. 2003;41:4497-501.
- [3] Vohra P, Sharma M, Yadav A, Chaudhary U. Nocardiosis: A review of clinic-microbiological features. *Int J LifeSc Bt Pharm Res*. 2013;2:20-28.
- [4] Menendez R, Cordero PJ, Santos M, Gobernado M, Marco V. Pulmonary infection with *Nocardia* species: a report of 10 cases and review. *Eur Respir J*. 1997;10:1542-46.
- [5] Gowrinath K, Rao PS, Mohapatra AK, Prakash PY. Pleural nocardiosis. *Indian J Chest Dis Allied Sci*. 2009;51:169-71.
- [6] Shiva prakash MR, Rao P, Mandal J, Biswal M, Gupta S, Ray P, et al. Nocardiosis in a tertiary care hospital in North India and review of patients reported from India. *Mycopathologia*. 2007;163:267-74.
- [7] Gowrinath K, Das S, Ranjitham M, Shekar U, Thanaskaran V. Nocardial hydropneumothorax. *Indian J Chest Dis Allied Sci*. 2004;46:51-53.
- [8] Gupta E, Dhawan B, Thabab MM, Das BK, Sood S, Kapil A. Nocardia pyopneumothorax in an immunocompetent patient. *Indian J Med Res*. 2006;124:363-64.
- [9] Hui CH, Au VW, Rowland K, Slavotinek JP, Gordan DL. Pulmonary nocardiosis revisited: Experience of 35 patients at diagnosis. *Respir Med*. 2003;97(6):709-17.
- [10] Yang M, Xu M, Wei W, Gao H, Zhang X, Zhao H, et al. Clinical findings of 40 patients with nocardiosis: A retrospective analysis in a tertiary hospital. *Exp Ther Med*. 2014;8:25-30.
- [11] Chen J, Zhou H, Xu P, Zhang P, Ma S, Zhou J. Clinical and Radiographic Characteristics of Pulmonary Nocardiosis: Clues to Earlier Diagnosis. *PLoS ONE*. 2014;9(3):e90724.
- [12] Patil M, C S, Varghese J, Rajagopalan N. A fatal case of pulmonary nocardiosis. *BMJ Case Reports*. 2012;2012:bcr0920114875-bcr0920114875.
- [13] Kontogiorgi M, Opsimoulis P, Kopterides P, Sawva A, Kalodimou V, Belesiotou E et al. Pulmonary nocardiosis in an immunocompetent patient with COPD: The role of defective innate response. *Heart & Lung: The Journal of Acute and Critical Care*. 2013;42(4):247-50.
- [14] De S, Desikan P. Pulmonary nocardiosis mimicking relapse of tuberculosis. *BMJ Case Reports*. 2009;2009:bcr0620080233-bcr0620080233.
- [15] Wilson J. Nocardiosis: Updates and Clinical Overview. *Mayo Clinic Proceedings*. 2012;87(4):403-07.

PARTICULARS OF CONTRIBUTORS:

1. Associate Professor, Department of Microbiology, BLDEU's Shri. B. M. Patil Medical College, Bijapur, Karnataka, India.
2. Associate Professor, Department of Medicine, BLDEU's Shri. B. M. Patil Medical College, Bijapur, Karnataka, India.

NAME, ADDRESS, E-MAIL ID OF THE CORRESPONDING AUTHOR:

Dr Smitha Bagali,
Associate Professor, Department of Microbiology, BLDEU's Shri. B. M. Patil Medical College,
Bijapur-586103, Karnataka, India.
E-mail: drsmithabagali@gmail.com

FINANCIAL OR OTHER COMPETING INTERESTS: None.

Date of Submission: **May 29, 2015**

Date of Peer Review: **Jul 29, 2015**

Date of Acceptance: **Nov 07, 2015**

Date of Publishing: **Jan 01, 2016**