

## Bevacizumab in choroidal neovascularization secondary to Indian tick typhus: A rare case report

[Raghavendra Ijeri](#), [Gautam Beladiya](#), and [Sharad Bhomaj](#)

Department of Ophthalmology, BLDE University's Sri B. M. Patil Medical College Hospital and Research Center, Vijayapura, Karnataka, India

**Correspondence to:** Dr Raghavendra Ijeri, No. MII 49, Adarash Nagar, Asharam Road, Vijaypur - 586 103, Karnataka, India. E-mail: [draghvu.ijeri@gmail.com](mailto:draghvu.ijeri@gmail.com)

Received 2016 Jan 6; Accepted 2016 Sep 1.

**Copyright** : © 2016 Indian Journal of Ophthalmology

This is an open access article distributed under the terms of the Creative Commons Attribution-NonCommercial-ShareAlike 3.0 License, which allows others to remix, tweak, and build upon the work non-commercially, as long as the author is credited and the new creations are licensed under the identical terms.

### Abstract

---

Tick typhus causes hemorrhagic lesions over the skin. Retina also shows hemorrhages and exudates. Many cases have been reported in western literature about this condition. To our best of knowledge, this is the first case report of tick typhus in India which was also associated with inflammatory choroidal neovascularization.

**Keywords:** Bevacizumab, choroidal neovascularization, Indian tick typhus

---

Tick typhus is caused by *Rickettsia conorii*. Tick typhus causes hemorrhagic lesions over the skin. Retina also shows hemorrhages and exudates. Many cases have been reported in western literature about this condition. To our best of knowledge, this is the first case report of retinal findings in tick typhus in India with inflammatory choroidal neovascularization (CNV).

### Case Report

---

We present a case of 30-year-old female who presented with loss of consciousness, vomiting, fever and rash [[Fig. 1](#)] for 1 day.

Fundus examination revealed intraretinal hemorrhages, white retinal lesions.

Magnetic resonance imaging showed multiple cerebral infarcts secondary to vasculitis and cerebral edema.

Blood investigations such as coagulation profile, random blood sugar (RBS), serum electrolytes, complete blood cell, and HIV were normal. Abdominal and pelvis ultrasound were normal.

Weil–Felix test for rickettsia showed OX2 1:160, indicating infection with Indian tick typhus.

Retinal examination after 4 weeks showed intraretinal hemorrhages, white retinal lesions [Figs. 2 and 3]. The patient also had choroidal neovascularization in the right eye which was confirmed with fluorescein angiography (FA) and optical coherence tomography (OCT).

FA showed early phase shows hyperfluorescent area at macula which increases in intensity in transit phase; it shows leakage during late phase. It also shows multiple areas of hyperfluorescence in both eyes which increase in intensity in late phase. These areas of hyperfluorescence correspond to white lesions [Figs. 4–6].

OCT showed retinal pigment epithelium disruption, overlying cystoid macular edema, minimal subretinal fluid suggestive of active CNV [Fig. 7].

## Treatment

During initial presentation patient was given intravenous mannitol, intravenous antibiotics.

Once the patient was diagnosed with CNV, she was given 1.25 mg in 0.05 ml bevacizumab intravitreally every month for 3 months along with doxycycline 100 mg OD for 15 days. The patient was followed up every month for first 6 months and then every 3 months.

Weil–Felix test was repeated after 2 months and showed decreased titers of OX2 indicating response to treatment.

There was an improvement in the vision after the first dose of bevacizumab which was maintained after next two doses of bevacizumab. After 1 year vision was maintained and there was no activity in the CNV both on OCT as well as on FA.

## Discussion

---

Indian tick typhus is caused by *R. conorii*. This causes hemorrhagic manifestations. Tick typhus causes fever, myalgia, rashes, eschar. Local or generalized lymphadenopathy, hepatosplenomegaly may be seen.

Multisystem involvement may be seen such as respiratory, gastrointestinal, renal, CNS, and eye.[1]

Ocular manifestations include mild vitreous inflammation, white retinal lesions, focal vascular sheathing, multiple arterial plaques, intraretinal hemorrhages, white-centered retinal hemorrhages, subretinal hemorrhages, serous retinal detachment, macular star, cystoid macular edema, optic disc edema, branch retinal artery occlusion, optic disc staining, retinal vascular leakage, delayed filling in a branch retinal vein, multiple hypofluorescent choroidal dots, and retinal neovascularization.[2,3,4]

It was confirmed serologically using ELISA and Weil–Felix test.[5,6]

As noted in earlier studies[7] intravitreal bevacizumab was used effectively in inflammatory CNV with good results.

We present a case of a 30-year-old female. The patient had CNV in retina which responded very well with intravitreal bevacizumab.[7] Vision was maintained in the patient even after 1 year, and there was no activity of CNV during the same period.

In conclusion, CNV due to tick typhus occurred within first 4 weeks of onset of systemic and retinal manifestations. Since the CNV was detected early, it responded well to the bevacizumab. The activity of the CNV did not increase during 1 year of follow-up. After observing this case, we conclude that early diagnosis and three, monthly doses of intravitreal bevacizumab helped to improve and maintain the vision of the patient in CNV due to Indian tick Typhus. CNV due to Indian tick Typhus responded similar to other inflammatory CNV.

### **Declaration of patient consent**

The authors certify that they have obtained all appropriate patient consent forms. In the form the patient(s) has/have given his/her/their consent for his/her/their images and other clinical information to be reported in the journal. The patients understand that their names and initials will not be published and due efforts will be made to conceal their identity, but anonymity cannot be guaranteed.

### **Financial support and sponsorship**

Nil.

### **Conflicts of interest**

There are no conflicts of interest.

### **References**

---

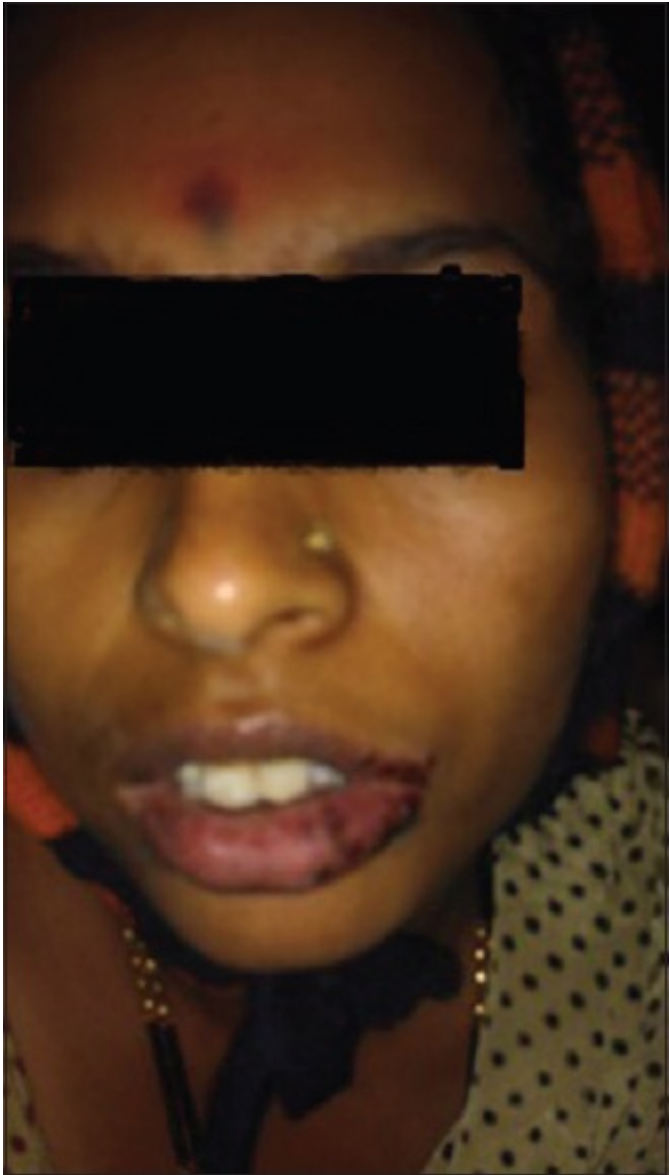1. Mahajan SK. Scrub typhus. J Assoc Physicians India. 2005;53:954–8. [PubMed: 16515236]
2. Khairallah M, Ladjimi A, Chakroun M, Messaoud R, Yahia SB, Zaouali S, et al. Posterior segment manifestations of *Rickettsia conorii* infection. Ophthalmology. 2004;111:529–34. [PubMed: 15019331]
3. Lukas JR, Egger S, Parschalk B, Stur M. Bilateral small retinal infiltrates during rickettsial infection. Br J Ophthalmol. 1998;82:1217–8. [PMCID: PMC1722397] [PubMed: 9924316]
4. Esgin H, Akata F. Bilateral multiple retinal hyperfluorescent dots in a presumed *Rickettsia conorii* infection. Retina. 2001;21:535–7. [PubMed: 11642389]

5. Mahajan SK, Kashyap R, Kanga A, Sharma V, Prasher BS, Pal LS. Relevance of Weil-Felix test in diagnosis of scrub typhus in India. *J Assoc Physicians India*. 2006;54:619–21. [PubMed: 16941792]
6. Isaac R, Varghese GM, Mathai E, Manjula J, Joseph I. Scrub typhus: Prevalence and diagnostic issues in rural Southern India. *Clin Infect Dis*. 2004;39:1395–6. [PubMed: 15494919]
7. Adán A, Mateo C, Navarro R, Bitrian E, Casaroli-Marano RP. Intravitreal bevacizumab (avastin) injection as primary treatment of inflammatory choroidal neovascularization. *Retina*. 2007;27:1180–6. [PubMed: 18046222]

## Figures and Tables

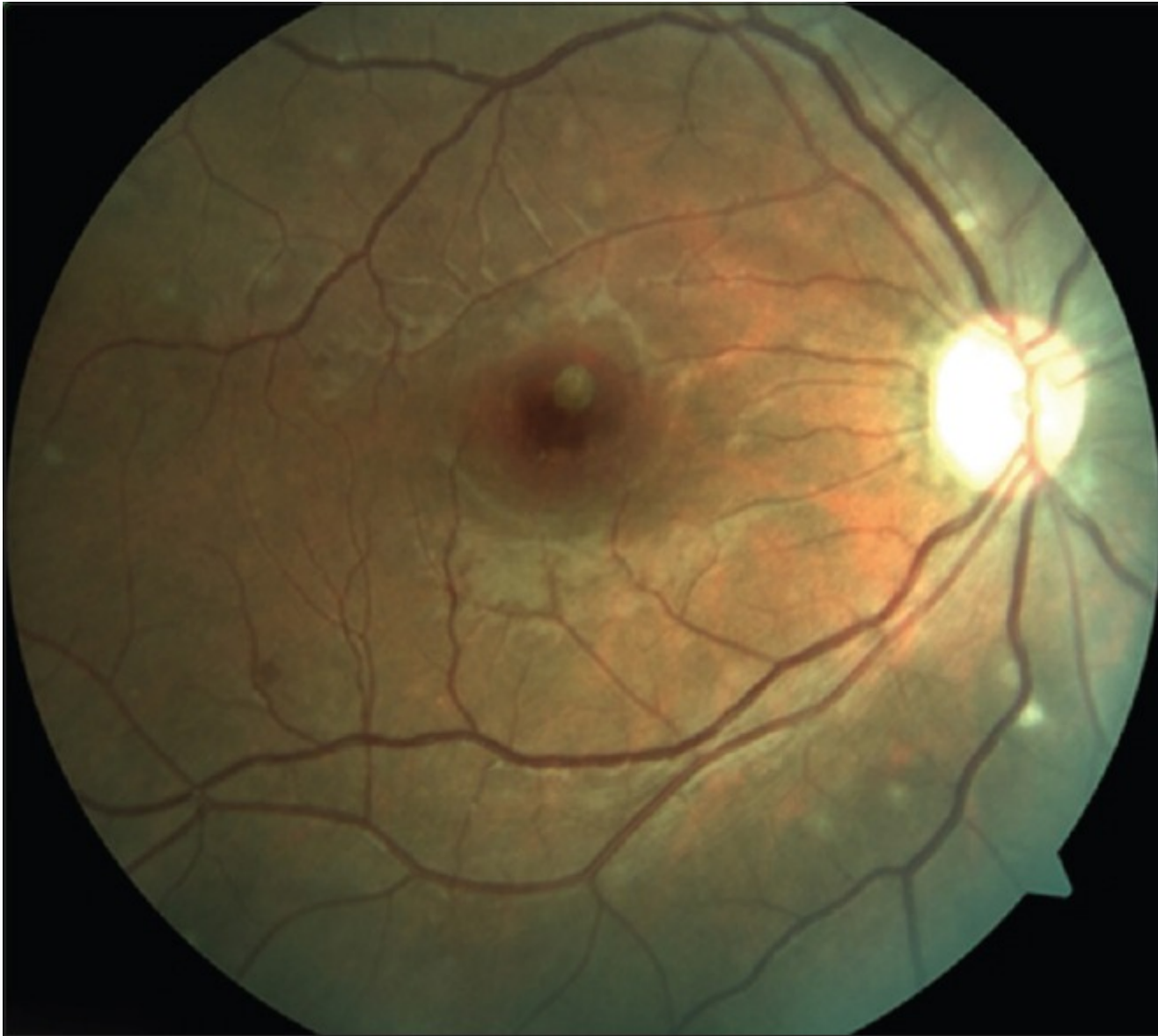
---

### Figure 1



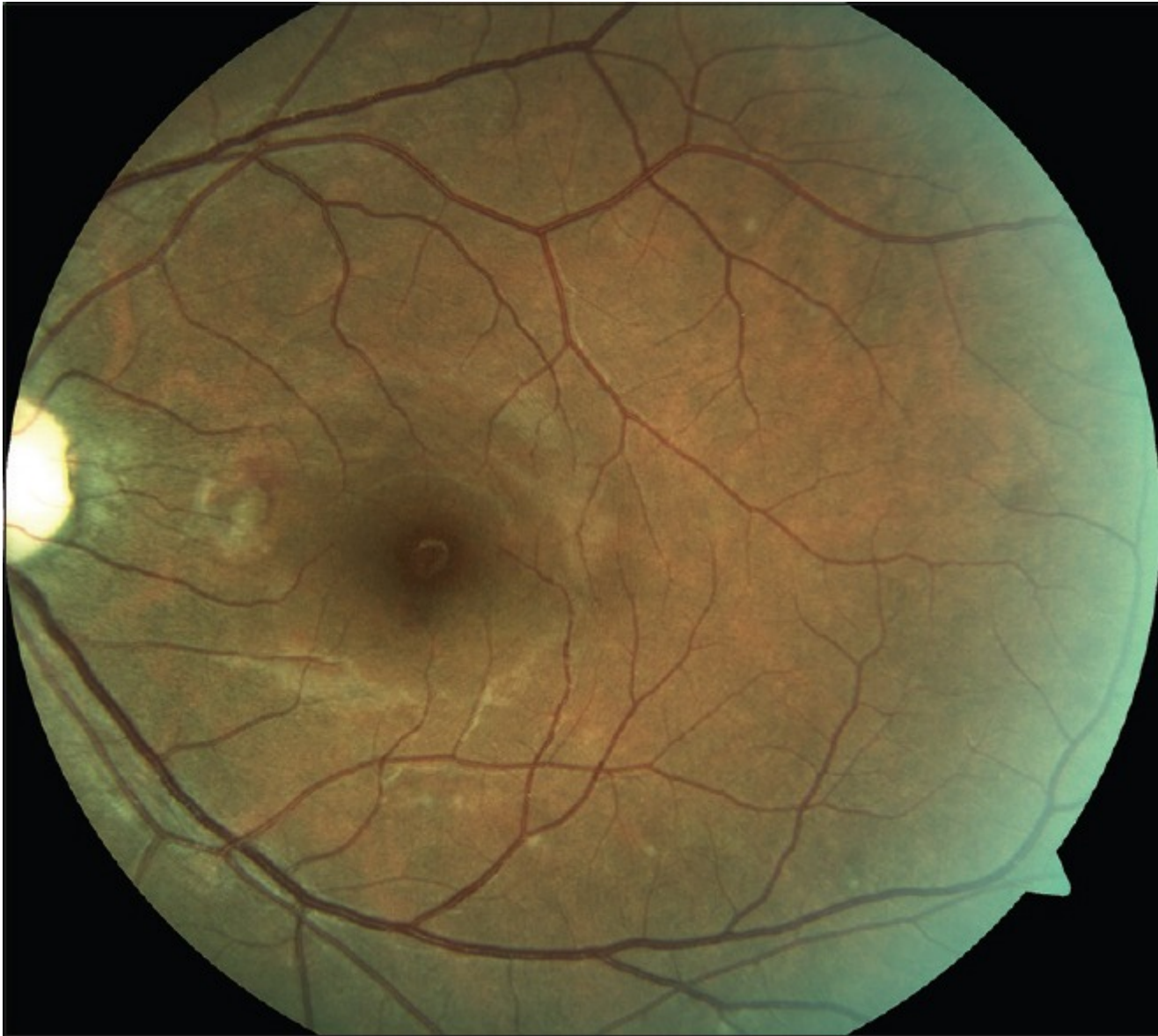Skin rash

**Figure 2**



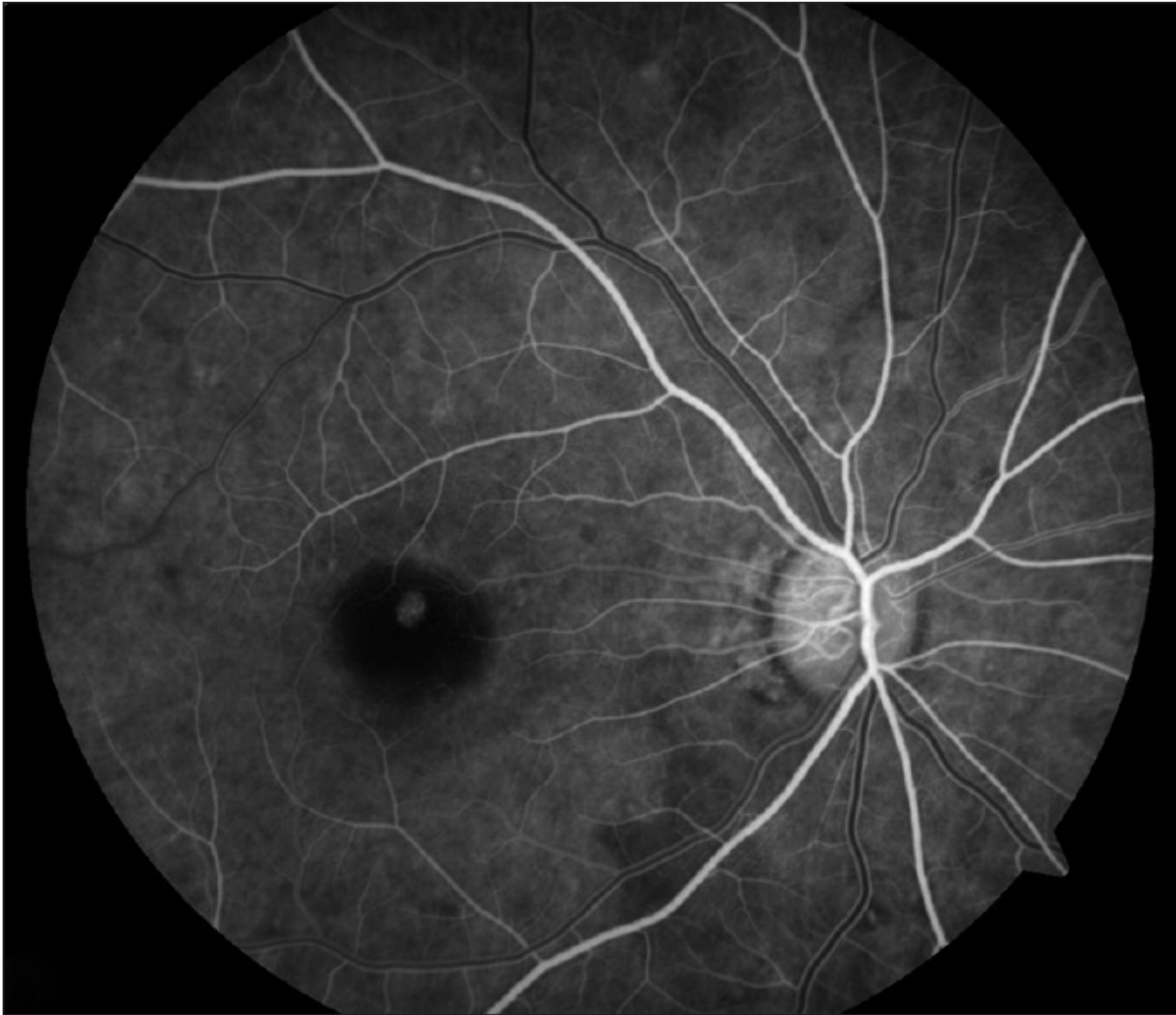
Right eye

**Figure 3**



Left eye

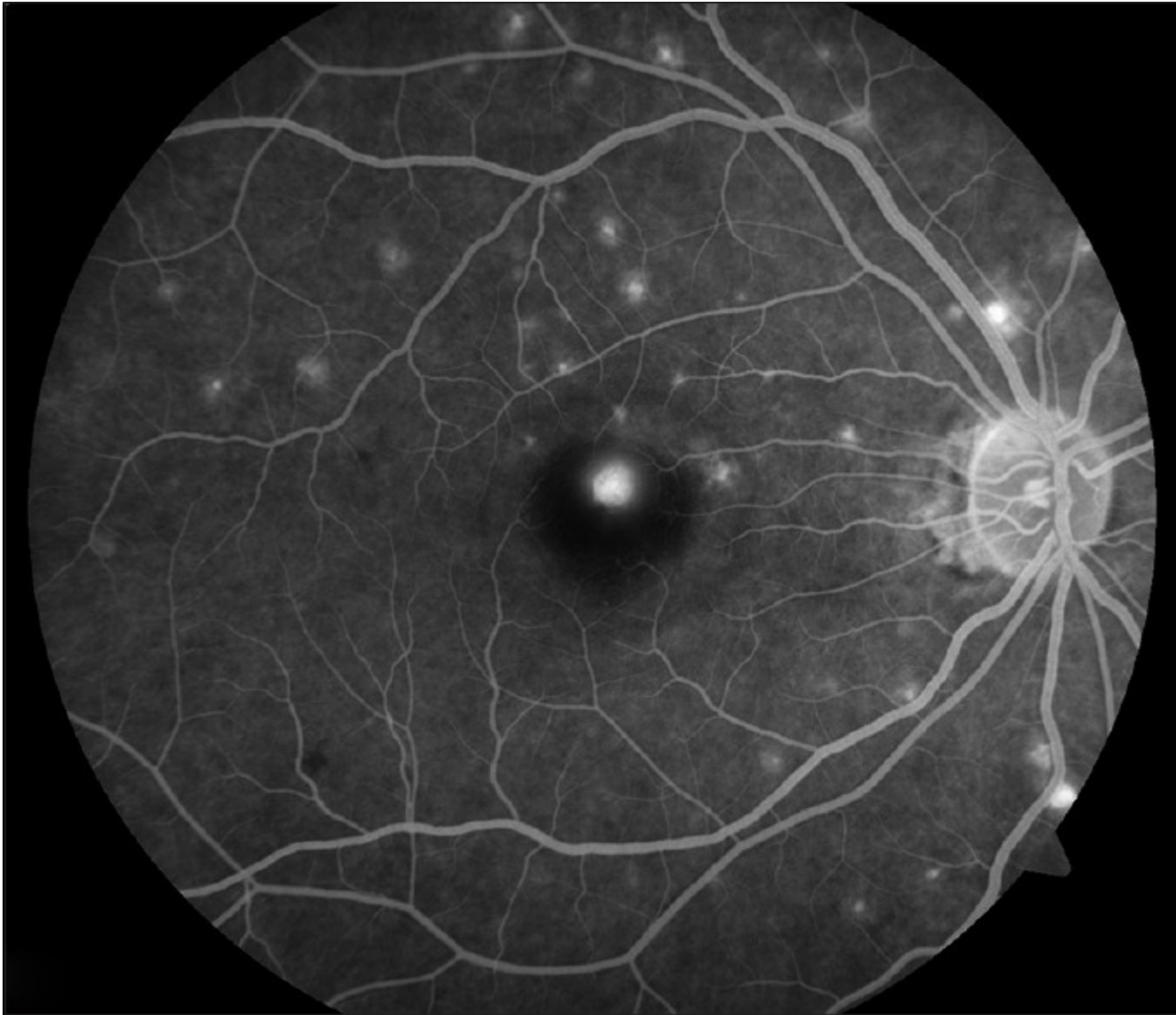**Figure 4**



Early phase (OD)

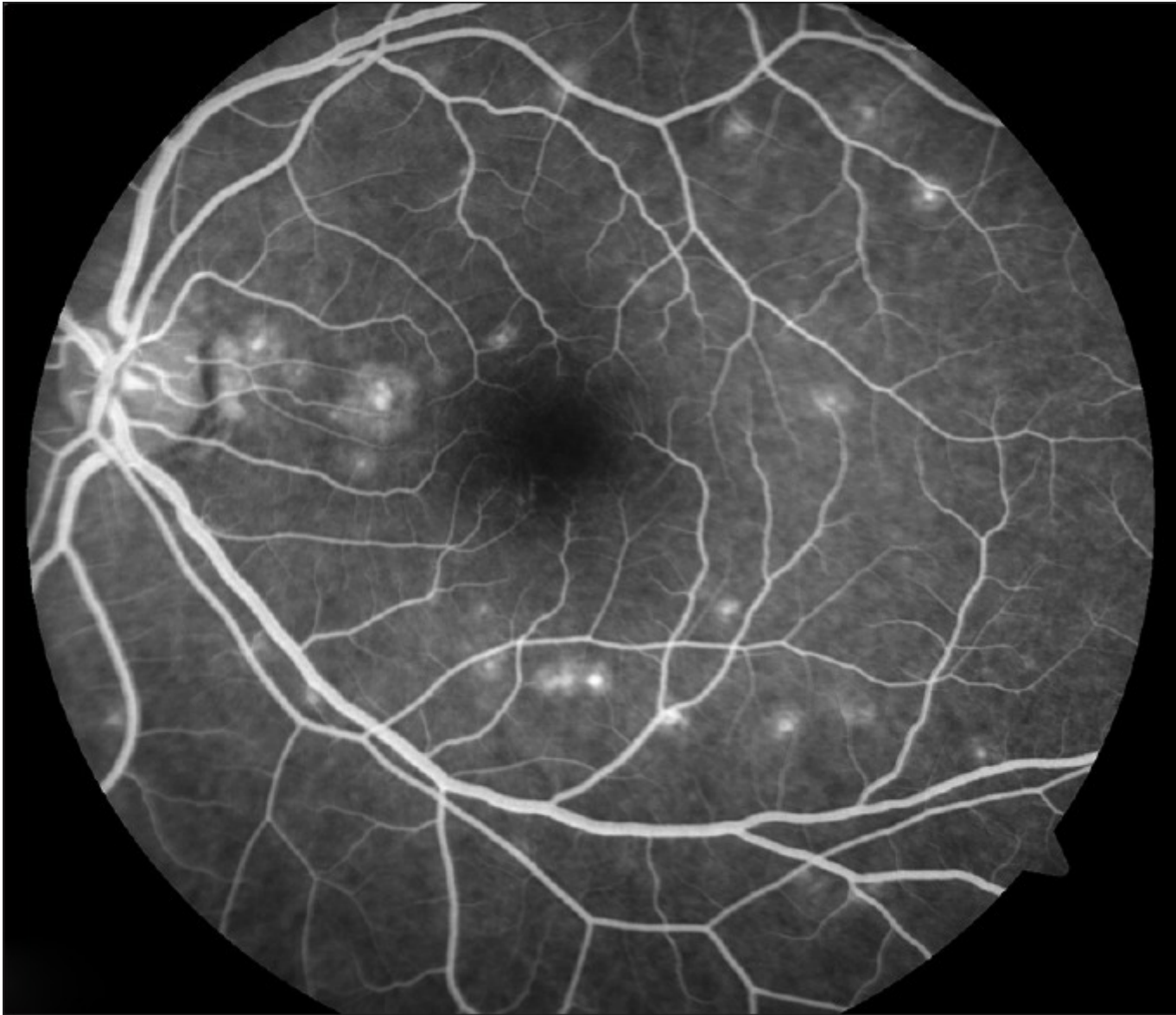**Figure 5**





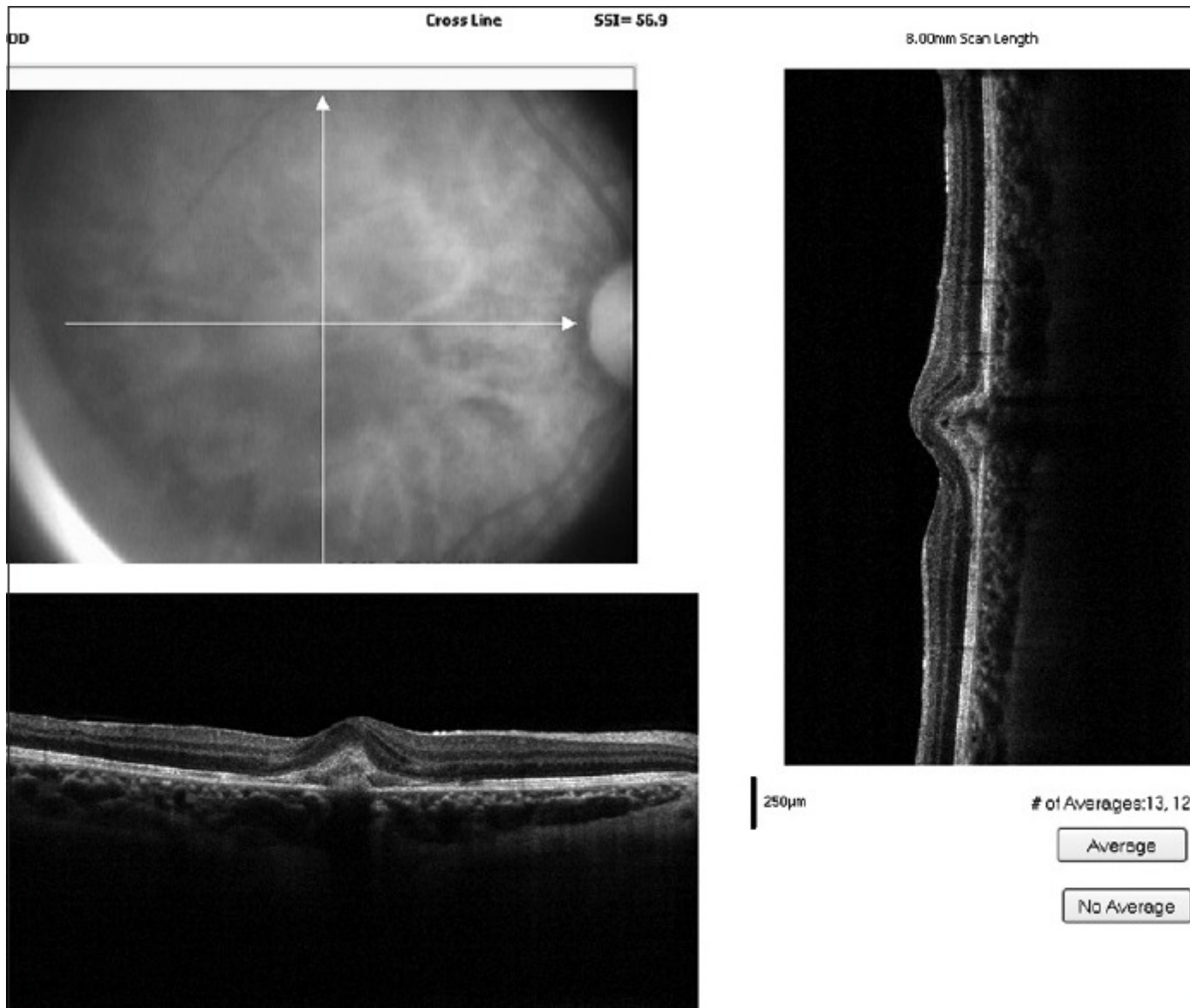
Late phase (OD)

**Figure 6**



Late phase (OS)

**Figure 7**



Optical coherence tomography (OD)