



Unilateral neurovascular and muscular variations in the right upper limb

Published online October 12th, 2012 © <http://www.ijav.org>

Gavishiddappa A. HADIMANI ✉
Shankarappa D. DESAI
Ishwar B. BAGOJI
Babasaheb G. PATIL

Department of Anatomy, Sri B. M. Patil Medical College,
Bld University, Bijapur, Karnataka, INDIA.



✉ Gavishiddappa A. Hadimani
M. Sc., Lecturer
Department of Anatomy
Sri B. M. Patil Medical College
Bld University
Bijapur, Karnataka, INDIA.
☎ +91 8352 262770 ext. 2211
✉ gavish.hadimani@yahoo.com

Received April 27th, 2011; accepted March 24th, 2012

Abstract

In the present case we observed a right upper limb with various variations, those includes variation in branching pattern of axillary artery, third head of biceps brachii, double brachial artery and insertion of biceps brachii forming a tunnel for both the brachial arteries and median nerve. Such attachment of biceps brachii may compress the structures beneath it and lead to neurovasculopathy. The variation in the present case was compared with those reported before. All the above-mentioned variations were observed unilaterally in male embalmed cadaver. As per our knowledge all these variations have observed by many authors; however, in our case we observed them together in a single limb. So, it may be important to know for vascular surgeons, radiologists, surgeons and clinical anatomists.

© *Int J Anat Var (IJAV)*. 2012; 5: 44–47.

Key words [axillary artery] [double brachial artery] [biceps brachii]

Introduction

Variations in the branching pattern of the axillary artery, double brachial artery and third head of biceps brachii are well known. Accurate knowledge of the normal and variant anatomy of the axillary and brachial region is prerequisite for correct diagnosis of an underlying pathology. The vascular variations of these regions should be well known. Certain clinical procedures are at utmost significance for the vascular radiologist, surgeons and clinical anatomists.

Axillary artery, a continuation of subclavian artery begins at the outer border of the 1st rib, and terminates nominally at the inferior border of teres major, where it becomes the brachial artery. Pectoral minor crosses it and so divides in to 3 parts [1]. Variations in the branching pattern of the major arterial trunks have been reported with an incidence of up to 20% in adult human limbs; they have been the subjects of much controversy since beginning of 19th century [2]. The most frequent anatomic variations of the axillary artery are the persistent superficial brachial artery. Superficial brachial artery is defined as brachial artery, which has a superficial course to the median nerve; where as a deep brachial artery corresponds to the brachial artery with its usual course behind the median nerve [3].

Third head of biceps brachii muscle is an often-reported finding of academic interest. It becomes more significant

when causing entrapment of the neurovascular bundle in the vicinity and the resultant clinical presentations. The presence of supernumerary humeral heads of biceps brachii is one of the common variations seen in the region of front of the arm, affecting an estimated population of 19-22% [4]. Many authors have described about variant branching pattern of axillary artery, high division of brachial artery and even about third head of biceps brachii, but simultaneous occurrence of all the above mentioned variations in the same cadaver have not been reported to the best of our knowledge. Surgeons and orthopedists dealing with cases of road traffic accidents need to be aware of such variations as dealing with such cases may not only be difficult but a nightmare too.

Case Report

During routine dissection for undergraduate students in the Department of Anatomy Sri B. M. Patil Medical College, Hospital and Research Center, BLDE University Bijapur; we found unilateral variations in right upper limb. Affected upper limb was smaller in length than left upper limb and we observed muscular wasting also. All the variations were dissected, examined and photographed. Variations included:

1) Unusual branching pattern of axillary artery: axillary artery measured 11 cm in length from 1st rib to lower border of teres major. First part of axillary artery gave a branch that was

superior thoracic artery as it was a usual case. From second part a common trunk-1 that measured 7 mm in length arose. This common trunk divided into 3 branches as a) thoracoacromial artery, b) anterior circumflex humeral artery, c) long thoracic artery. From the 3rd part one more common trunk-2 that measured 11 mm in length arose. Common trunk-2 gave remaining branches as a) posterior circumflex humeral artery, b) subscapular artery, c) profunda brachii artery, d) muscular branches (Figure 1).

2) Double brachial artery: higher division of brachial artery was the next variation. At the level of lower border of teres major, Axillary artery divided into brachial artery-1 and brachial artery-2. Division point of axillary artery measured 20.8 cm from the medial epicondyle. Brachial artery-1 (2 mm) was less thick than brachial artery-2; it continued in the forearm as radial artery, and passed through a space formed between bicipital aponeurosis and 2nd tendon of biceps brachii. Brachial artery-2, 4 mm in diameter, was larger than brachial artery-1, more tortuous in nature. Superior and inferior ulnar collateral arteries were arising from brachial artery-2. In the cubital fossa, brachial artery-2 continued as ulnar artery after piercing 2nd tendon of biceps brachii along with median nerve. Both the arteries lied superficial to the biceps brachii muscle and run in front of median nerve. All these arteries were highly tortuous in their course (Figure 2).

3) Third head of biceps brachii: biceps brachii showed a 3rd head, which took origin from coracoid process of scapula along with short head and coracobrachialis. It had a short tendon and muscle belly, during insertion 3rd head joined the remaining heads (Figure 2). All the 3 heads joined together and formed a single tendon that divided into 3 slips before insertion. The entire 3 slips inserted in different pattern:

- Some fibers inserted into pronator teres through bicipital aponeurosis.
- Some more fibers inserted into pronator teres as 2nd tendon of biceps brachii. Biceps brachii's 2nd tendon lied between bicipital aponeurosis and 1st tendon; 2nd tendon split to surround the median nerve and brachial artery-2.
- Remaining muscle fibers inserted into radial tuberosity through biceps brachii tendon-1 (Figure 3).

As per our knowledge all these variations have been observed by many authors. However, in our case we observed them together in a single limb, so it is important to know for vascular surgeons, radiologists, surgeons and clinical anatomists.

Discussion

It is not uncommon to encounter variations of the axillary artery, brachial artery and supernumerary head of biceps brachii. Many authors have described variations in courses, branching pattern and the number of branches [3-7]. Patnaik et al. quoted that De Garis and Swartley (1928) in a study of 512 axillary arteries found 5 to 11 branches, the most common number being eight [7]. Whereas textbooks' description gives the named branches as six [1]. In our study, we encountered only 3 branches. In that one was superior thoracic artery,

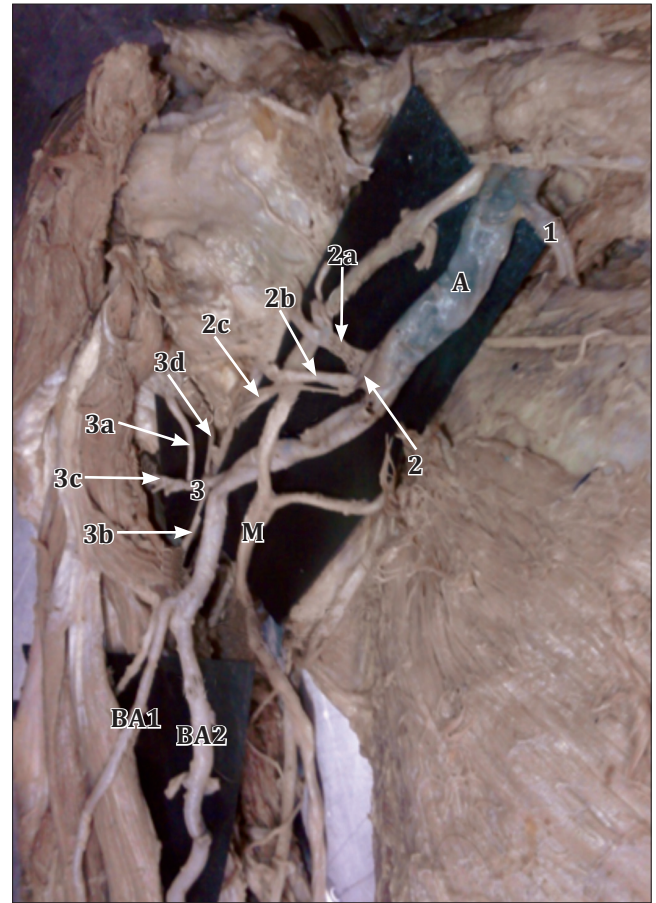


Figure 1. Figure showing the variant branching pattern of axillary artery. (A: axillary artery; M: median nerve; BA1: brachial artery-1; BA2: brachial artery-2; 1: superior thoracic artery; 2: common trunk-1; 2a: thoracoacromial artery; 2b: anterior circumflex humeral artery; 2c: long thoracic artery; 3: common trunk-2; 3a: posterior circumflex humeral artery; 3b: profunda brachii artery; 3c: muscular branches; 3d: subscapular artery)

other 2 were common trunks later these trunks divided to give remaining branches.

Daimi et al. reported 2 trunks for thoracoacromial artery and posterior circumflex humeral artery [6], but in our study we found one branch for each part of artery. In 1st part superior thoracic artery, in 2nd part a common trunk which gave rise to long thoracic artery, anterior circumflex humeral artery and thoracoacromial arteries, in 3rd part one more common trunk, this gave posterior circumflex humeral, profunda brachii and subscapular arteries.

In a study of 49 limbs, Patnaik et al. described that 2% of brachial arteries are dividing in the middle third of the arm as superficial and deep brachial arteries. They also measured the length of brachial artery ranging from 20.5 to 29.0 cm. Patnaik et al. in another study described bifurcation of axillary artery in its 3rd part [7]. In our case axillary artery was dividing just below the lower border of teres major. The

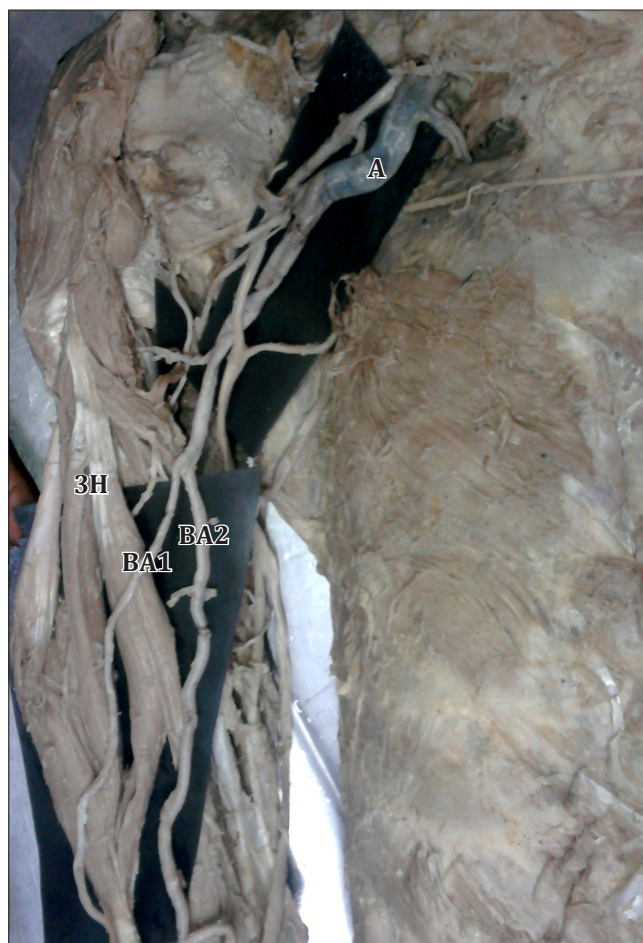


Figure 2. Three heads of biceps brachii and higher division of brachial artery. (*A*: axillary artery; *3H*: third head of biceps brachii; *BA1*: brachial artery-1; *BA2*: brachial artery-2)

distance of division of axillary artery from medial epicondyle measured 20.8 cm, but the length of brachial artery-1 was 23.7 cm and the length of brachial artery-2 was 24.1 cm. The length of artery was larger than the distance of its division from the medial epicondyle because of its tortuous course.

In Gray's Anatomy the incidence of 3rd head of biceps brachii is reported up to 10% [1]. Kasugi et al. described the incidence up to 9–22% [4]. Rai et al. described the incidence of 3rd head of biceps brachii in Indian population up to 7.1%, and also described about the insertion of 3rd head into the radial tuberosity along with the other two heads of the muscle [8]. In our case the 3rd head of biceps brachii took its origin from the coracoid process of scapula along with short head and coracobrachialis. It had a thick and short muscle belly, then joined remaining two heads for insertion. While inserting



Figure 3. Insertion of biceps brachii and the relations to neurovascular structures. (*BA1*: brachial artery-1; *BA2*: brachial artery-2; *M*: median nerve; *1, 2, 3*: tendons of biceps brachii)

biceps brachii formed 3 slips: 1) Bicipital aponeurosis which was inserting in to pronator teres (normally it should attach to deep fascia of forearm), 2) Tendinous slip that split to surround the median nerve and brachial artery-2, and attached to the pronator teres; between bicipital aponeurosis and tendinous slip brachial artery-1 passed out. 3) Tendon; this tendon inserted to the radial tuberosity. Such accessory slips may compress the underlying structures such as the median nerve and the brachial artery-2 in the present case. Compression of median nerve and brachial artery by various types of structures leading to clinical neurovasculopathy has been reported [9–10]. On contraction these muscles may compress the median nerve, causing to further irritation of the nerve, also on contraction these muscle slips may compress both brachial arteries.

References

- 111 Standring S, ed. *Gray's Anatomy*. 40th Ed., Churchill Livingstone, London. 2008: 815–817.
- 121 Rodriguez-Niedenführ M, Burton GJ, Deu J, Sañudo JR. Development of the arterial pattern in the upper limb of staged human embryos: normal development and anatomic variations. *J Anat*. 2001; 199: 407–417.
- 131 Yoshiyuki T, Setsuko T, Cho A, Kohji K, Yumi M. Superficial brachial artery continuing into the forearm as the radial artery. *J Nara Med Assoc*. 2005; 56: 189–193.
- 141 Kosugi K, Shibata S, Yamashita H. Supernumerary head of biceps brachii and branching pattern of the musculocutaneous nerve in Japanese. *Surg Radiol Anat*. 1992; 14: 175–185.
- 151 Krstonosic B, Srdic B, Maric D, Gudovic R, Mijatov S, Babovic SS. An anatomical study of double brachial arteries — a case report. *Int J Anat Var (IJAV)*. 2010; 3: 6–8.
- 161 Daimi SR, Siddiqui AU, Wabale RN. Variations in the branching pattern of axillary artery with high origin of radial artery. *Int J Anat Var (IJAV)*. (2010) 3: 76–77.
- 171 Patnaik VVG, Kalsey G, Singla RK. Branching pattern of axillary artery — a morphological study. *J Anat Soc India*. 2000; 49: 127–132.
- 181 Rai R, Ranade AV, Prabhu LV, Pai MM, Prakash. Third head of biceps brachii in an Indian population. *Singapore Med J*. 2007; 48: 929–931.
- 191 Gessini L, Jandolo B, Pietrangeli A. Entrapment neuropathies of the median nerve at and above the elbow. *Surg Neurol*. 1983; 19: 112–116.
- 1101 Nakatani T, Tanaka S, Mizukami S. Bilateral four-headed biceps brachii muscles: the median nerve and brachial artery passing through a tunnel formed by a muscle slip from the accessory head. *Clin Anat*. 1998; 11: 209–212.