

A Rare Case of Malignant Melanoma of Rectum

Mallappa. V. Huggi, Dr Manjunath Koteavvar, Dr Prasad Sasnur, Dr Prassanna K, Dr Mrinal V

Shri B. M. Patil Medical College, Bijapur-586103, Karnataka, India

*Corresponding Author:

Name: M. V. Huggi

Email: mallikarjunvh@gmail.com

Abstract: We present a case of 50 year old female who presented to the out patient department with complaints of bleeding per rectum and mass per rectum since 2 months. Per rectal examination revealed a pedunculated soft mass at the anal verge. The patient underwent excisional biopsy and during this surgery another mass was palpable whose upper border could not be felt. Histopathologic examination and immunohistochemistry(S-100) of polyp were suggestive of malignant melanoma. Colonoscopy examination revealed a proliferative lesion at 4 o'clock position involving the one third circumference of rectum. The patient underwent abdominoperineal resection and is on adjuvant chemoradiotherapy.

Keywords: Melanoma, Polyp, Colonoscopy, Computed tomography (CT), S-100, Abdominoperineal resection.

INTRODUCTION

Malignant melanoma of rectum is a rare entity. Moore reported melanoma of rectum in 1857 for the first time. Malignant melanoma arise from melanocytes in the skin, they may rarely arise from melanocytes at extra cutaneous sites [1-4]. Patients present with local symptoms such as rectal bleeding, anal mass or change in bowel habit [6]. Most patients have metastatic disease at the time of diagnosis. It carries poor prognosis and mean survival is 24 months following diagnosis [1-10]. Immunohistochemistry with S-100 aids in diagnosis. Surgical management consists of local excision when technically feasible and abdominoperineal resection for large tumours [9-10].

CASE REPORT

A 50 year old female patient presented with chief complaints of bleeding per rectum and mass per rectum since 2 months. On examination the patient appeared pale and per rectal examination revealed a pedunculated soft mass at the anal verge which bled on touch. The patient underwent excisional biopsy. During excisional biopsy another mass was palpable whose upper border could not be felt. The patient underwent colonoscopy which revealed a proliferative growth at 4 o'clock position involving the one third circumference of anorectal region (Fig. 1). Histopathological examination of the excised polyp was suggestive of malignant melanoma and immunohistochemistry was positive for S-100. CT-abdomen showed a large hypo dense mass with heterogenous enhancement in the rectum with few enlarged pararectal lymph nodes (Fig. 2). The patient underwent abdomino perineal resection and received radiotherapy postoperatively (Fig. 3). Histopathology of resected specimen showed pleomorphic tumour cells with round to oval nuclei,

prominent nucleoli. Mitotic figures 2-3/hpf. Many cells show brown black melanin pigment in cytoplasm with tumour extending upto serosa.

DISCUSSION

Malignant melanoma rarely involves rectum. It accounts for 0.1-4.6 % of malignant tumours of rectum. It is predominantly seen in females and usually occurs in 5th to 6th decade [1-5]. Tumour may mimic haemorrhoids, adenocarcinoma, small cell carcinoma and sarcoma [6]. Immunohistochemistry with S-100 and HMB-45 is necessary for diagnosis. Melanoma of rectum usually carries poor prognosis because it is usually advanced at the time of diagnosis and has biologically aggressive behaviour.

There is dilemma regarding the best surgical management. Some surgeons advocate a wide local excision with a 2cm margin with radiotherapy whereas others advocate abdomino-perineal resection since it removes clinically unidentifiable lymph nodes. Most patients die of disseminated systemic disease regardless of treatment. Comparison of the survival of patients who underwent abdomino-perineal resection with those who underwent wide local excision showed no statistically significant advantage for either procedure in patients at all disease stages. Abdomino-perineal resection therefore should be performed when local excision is not possible [7-9]. Most recurrences occur systemically regardless of the initial surgical procedure [10].

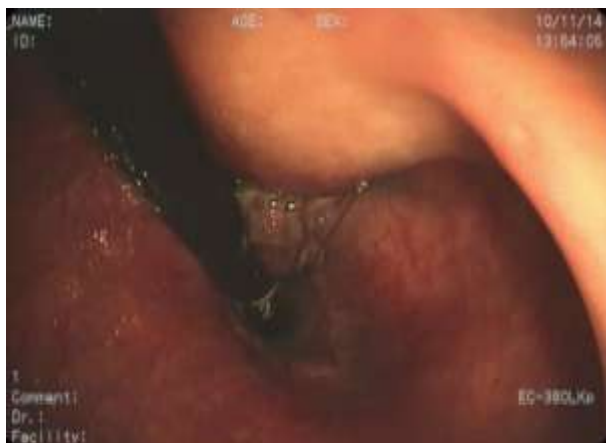

Fig. 1: Proliferative growth at 4 o'clock position involving the one third circumference of anorectal region

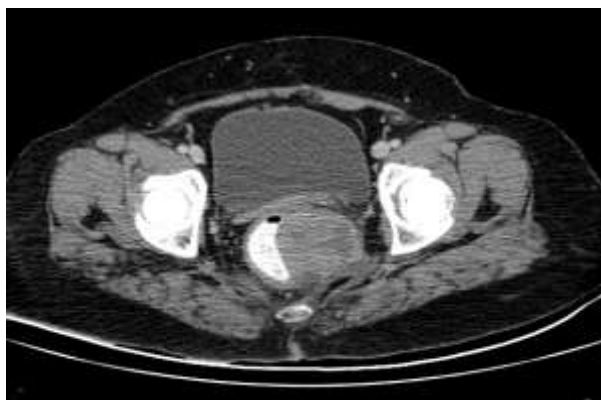


Fig. 2: CT-abdomen showed a large hypo dense mass with heterogenous enhancement in the rectum with few enlarged pararectal lymph nodes

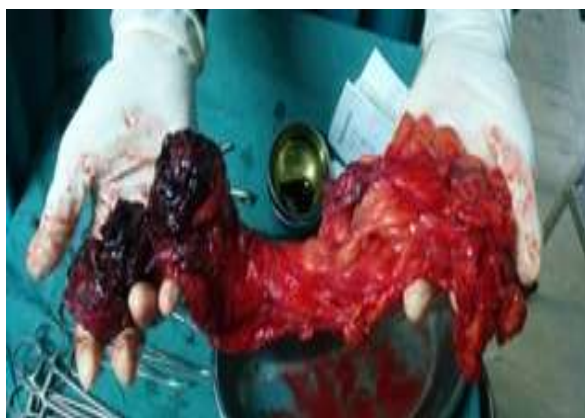

Fig. 3: Abdomino perineal resection

CONCLUSION

Melanoma of rectum is a very rare entity. The prognosis is poor and surgical management should be the least morbid, a wide local excision when technically feasible and abdomino-perineal resection for large tumours. Locally advanced inoperable tumours can be given palliative chemoradiotherapy.

REFERENCES

1. Roviello F, Cioppa T, Marrelli D; Primary anorectal melanoma: considerations on a clinical case and review of literature. *Chir Ital.*, 2003; 55(4): 575-580.
2. Stroh C, Manger T; Primary amelanotic anorectal melanoma – a case report. *Zentrabl Chir.*, 2007; 132(6): 560-563
3. Moore R; Recurrent melanosis of the rectum after previous removal from the anal verge of the anus in a man aged 65. *Lancet.*, 1857; 1: 290
4. Desai M, Parikh B, Prajapati J, Talukdar P, Dave R; Malignant melanoma of the rectum- A rare entity. *The Internet Journ of Surg.*, 2006; 10(1). Available from <https://ispub.com/IJS/10/1/8772>
5. Takashi T, Velasco L, Zarate X; Anorectal melanoma report of three cases with extended follow up. *South Med J.*, 2004; 97(3): 311-313.
6. Solaz Mareno E, Vallalta Morales M, Silla Burdalo G; Primary melanoma of the rectum. *Clin Transl Oncol.*, 2005; 7(4): 171-173.
7. Maqbool A, Linter R, Bokhari A; Anorectal melanoma- 3 case reports and a review of literature. *Cutis.*, 2004; 73(6): 409-413.
8. Kayhan B, Turan N, Ozasian E; A rare entity in the rectum: Malignant melanoma. *Turk J Gastroenterol.*, 2003; 14(4): 273-275.
9. Yap LB, Neary P; A comparison of wide local excision with abdominoperineal resection in anorectal melanoma. *Melanoma Res.*, 2004; 14(2): 147-150.
10. Bullard KM, Tuttle TM, Rotheberger DA; Surgical therapy for anorectal melanoma. *J AM Coll Surg.*, 2003; 196(2): 206-212.
11. van Schaik PM, Ernst MF, Bosscha K; Melanoma of rectum: a rare entity. *World J Gastroenterol.*, 2008; 14(10): 1633-1635