

A Rare Case Report of A Young Male Patient Presenting with Osteblastoma of the Talus

Kiran S Patil¹, Haridas M Somayaji², Santhosh S Nandi¹

What to Learn from this Article?

Presentation and management of Osteblastoma of talus

Abstract

Introduction: Osteblastoma is a rare (incidence <1%) benign locally aggressive osteoblastic lesion of bone with rare malignant transformation. Benign osteblastoma is the term used by Jaffe to denote an uncommon neoplasm of bone characterized by vascular osteoid and bone forming matrix rich in osteoblasts.

Case Report: Here we report a case of osteblastoma of talus in eighteen year old male patient from Bijapur with complaints of pain and difficulty in walking for one year. Relevant investigations and radiographs were taken. It was treated with wide excision and bone grafting from ipsilateral ilium and talo-navicular fusion with cannulated cancellous screw fixation. Histopathology of the biopsy confirmed the diagnosis. Patient was immobilized with below knee plaster cast for six weeks later with gradual mobilization. Guarded weight bear was allowed after three months. Patient achieved satisfactory range of movements and full weight bear mobilization after six months. Symptoms relieved with no evidence of any recurrence in one year follow up.

Conclusion: Osteblastoma of talus is a rare benign tumor, if suspected surgical wide excision and talo-navicular fusion with cannulated cancellous screw fixation, with bone grafting is the better treatment of choice. The condition can only be confirmed after histopathological examination.

Keywords: osteblastoma, talus, tumor.

Introduction

Osteblastoma is a rare bone-forming neoplasm that represents less than 1% of bone tumors in the Mayo Clinic series [1]. Benign osteblastoma is the term used by Jaffe to denote an uncommon neoplasm of bone characterized by vascular osteoid and bone-forming matrix rich in osteoblasts

[2].

Osteblastoma is a benign bone tumour found commonly in the spine and long tubular bones. Involvement of the talus is uncommon, and when present, is found in the neck of the talus [3]. With respect to age, the incidence appears to be highest in the second decade of life [4, 1].

Access this article online	
Quick Response Code	Website: www.jocr.co.in
	DOI: 10.13107/jocr.2250-0685.218

Author's Photo Gallery



Dr. Haridas M Somayaji



Dr. Kiran S Patil



Dr. Santhosh S Nandi

¹Department of Orthopaedics, Shri B.M.Patil Medical College, Bijapur - 586103. India.

Address of Correspondence

Dr. Haridas M Somayaji, Assistant Professor, Dept. Of Orthopaedics, Shri B.M.Patil Medical College, Bijapur - 586103. India. Email: dr_hari81@rediffmail.com

Copyright © 2014 by Journal of Orthopaedic Case Reports

Journal of Orthopaedic Case Reports | pISSN 2250-0685 | eISSN 2321-3817 | Available on www.jocr.co.in | doi:10.13107/jocr.2250-0685.218

This is an Open Access article distributed under the terms of the Creative Commons Attribution Non-Commercial License (<http://creativecommons.org/licenses/by-nc/3.0>) which permits unrestricted non-commercial use, distribution, and reproduction in any medium, provided the original work is properly cited.



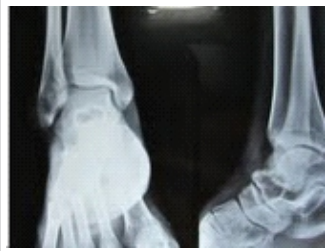

Figure 1: pre operative radiograph.

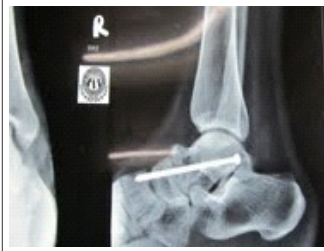

Figure 2: post operative radiograph.

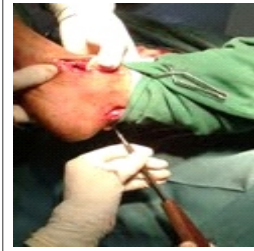


Figure 3: per operative picture.

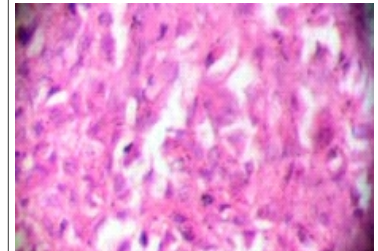


Figure 4: histopathological picture.

The tumour usually is slow growing, and symptoms may be present for 1 to 2 years before a diagnosis is made. The differential diagnosis includes aneurysmal bone cyst and osteoid-osteoma [1]. Radiologically, osteoblastoma is a lytic lesion originating in the medulla of bones with matrix ossification and mild surrounding sclerosis [5]. Histological examination combined with clinical and radiological features are used for the diagnosis of osteoblastoma. The curative treatment for patients with osteoblastoma is surgery. The lesion can be removed with intralesional curettage or wide resection, depending on the clinical situation, location within the bone and suspicion of malignancy. Recurrence rates vary with the surgical approach and wide resection is associated with lower recurrence rates [6]. The purpose here is to report this kind of rare case treated with wide resection and bone grafting with talo-navicular arthrodesis for satisfactory outcome.

Case Report

An eighteen years old male patient, from Bijapur, came with complaints of pain in right ankle, difficulty in walking since one year. Pain was insidious in onset, gradually progressing, intermittent, aggravates with walking and movements of ankle and foot, relieves with analgesic medication. Patient had history of twisting injury to the right ankle one year back. Patient had history of massage. It was interfering in his daily activities like walking, running. No history of swelling and no constitutional symptoms.

On examination, tenderness present over anterior aspect of talus. Terminal movements of subtalar and mid tarsal joints are restricted and painful. Laboratory tests were normal.

Radiology of ankle anteroposterior and lateral views showed an expanded lytic lesion around 2x3 cm in talar neck body junction, involving articular cartilage, with thin shell of periosteal bone, clear zone of transition and sclerotic rim [fig-1]. On the basis of clinical and x-ray features provisional diagnosis of osteoblastoma is done.

The patient was planned for wide excision biopsy, bone grafting from ipsilateral ilium and talo-navicular fusion with cannulated cancellous screw fixation [fig-2, 3]. Biopsy material sent for histopathology and report showed irregular spicules of

mineralized bone and eosinophilic osteoid rimmed by osteoblasts. The vascular stroma is characterized by pleomorphic spindle cells. The tumor cells differentiate into osteoblasts which make varying amounts of osteoid and woven bone confirming osteoblastoma talus [fig-4]. Post operatively, below knee cast was applied with non-weight bear mobilisation for six weeks [fig-5]. Cast was removed at seventh post operative week. Gradual partial weight bear mobilisation carried out from seven to eighteen post operative weeks. Ankle, subtalar joint active and passive movements were also carried out [fig-7, 8, 9, 10]. Patient attained full weight bear painless unaided mobilisation with satisfactory ankle and subtalar movements at the end of six months. No recurrences of disease with one year follow up. Hardware was planned to be removed at a later date.

Discussion

In 1932, Jaffe and Mayer presented a comprehensive report of a metacarpal bone with osteoid and bone forming tumor. Lichtenstein, in 1952, used the name osteogenic fibroma to denote a group of tumors with active osseous proliferation in a highly vascular connective-tissue stroma in which there was osteoclastic resorption and remodelling. In 1954, Golding and Sissons reported two instances of osteogenic fibroma which involved the vertebral column. Jaffe, in 1956, in a comprehensive review objected to the name osteogenic fibroma and advocated the use of the name benign osteoblastoma which later got accepted [4].

With respect to age, like in our case, osteoblastoma typically presents during the second decade of life [7], although cases have been reported in both younger and older patients [4]. Clinically, pain is the most common presenting symptom. The pain increases in severity with time and has an unpredictable response to anti-inflammatory agents [7]. Rodolfo Capanna M.D. et al, in their seven case series study of osteoblastoma of the talus reported that all the patients had symptoms of one year duration or longer, with pain in and around talus not particularly increases at night [8]. We also have similar history and examination findings.

Radiologically lesion was lytic with 2x3 cm in size with sclerotic rim. The differential diagnoses include aneurysmal bone cyst and osteoid osteoma [1]. Osteoid-osteoma and osteoblastoma



Figure 5: post operative cast immobilisation.

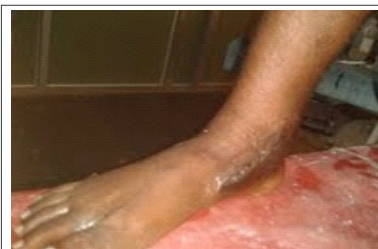

Figure 6: clinical picture after cast removal.

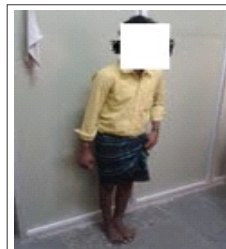

Figure 7: Clinical picture standing.

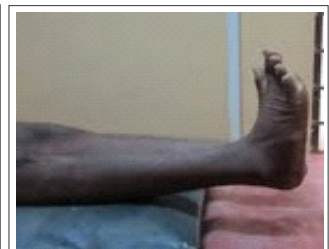

Figure 8: Post operative ankle dorsiflexion.

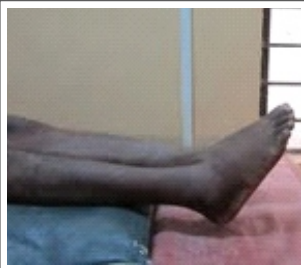

Figure 9: post operative ankle plantar flexion.

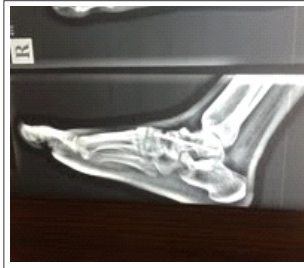

Figure 10: 6 months follow up radiograph.

are considered as variant of the same pathologic process and hence for radiological diagnosis diameter more than 2cm is considered as osteoblastoma [8]. Nicholas and Jack concluded that, it seems virtually impossible to diagnose benign osteoblastoma without benefit of histopathological studies of the material [4].

Treatment consists of extended curettage or resection. Bone grafting of the defect may be necessary [1]. A case report by Nicholas and Jack found that curettage of small to moderate lesions followed by packing of the defect with bone chips seems to be the treatment of choice. Removal of a wide margin of normal bone does not seem to be necessary, although complete excision, when surgically feasible and technically easy, seems also to yield good results and is not contra-indicated [4].

In their twenty case series of osteoblastoma, Yener Saglik et al found that there were no recurrences in the patients who were treated with wide resection of the tumour. Recurrence was observed in one of six patients who underwent marginal excision, and in two of eleven patients who underwent intralesional curettage. The overall recurrence rate in their series was 10%. They concluded that in the treatment of patients with osteoblastoma, wide resection should be considered whenever it is anatomically possible [6]. According to Carol Det al, neither malignant transformation nor

metastases of these lesions has been reported. However, these tumors are more likely to recur following incomplete or intralesional excision. Whenever possible, perform a complete or marginal excision. Recurrence following incomplete intralesional curettage occurs in up to 15% [7].

Considering these in our case, wide excision of the tumor was done and later gap was filled with bone graft and skeletal stabilisation was performed with talo-navicular arthrodesis with cannulated cancellous screw fixation. The resected part was sent for histopathological examination for the confirmation of the diagnosis. Even though the screw used for the fixation is little longer and violating the navicular-cuneiform joint, patient is not complaining of any discomfort or pain. Hardware was planned to be removed at a later date.

Most authors do not recommend radiation treatment unless absolutely necessary for symptomatic inoperable lesions like in spine. Moreover sarcomatous degeneration has been reported and may be more common in lesions previously treated with radiation [1]

Conclusion

Osteoblastoma of the talus is a rare benign tumour occurring mainly in the second decade of life, presents with constant pain in and around talus. Radiology shows lytic lesion with more than 2cm in diameter. Whenever it is suspected and anatomically possible, wide resection with reconstruction to be done for the successful outcome and the condition can be confirmed only by histopathological examination of the material.

Clinical Message

Though rare, osteoblastoma of talus has to be considered when an osteolytic lesion with more than 2cm diameter in second to third decade of life. Whenever suspected it needs to be treated with wide resection with bone graft.

References

1. Robert K. Heck Jr. Benign/Aggressive Tumors of Bone. In: Canale & Beaty: Campbell's Operative Orthopaedics, 11th ed. ISBN: 978-0-8089-2361-9 MOSBY ELSEVIER 2008. P.892.
2. JAFIE, H. L.: Benign osteoblastoma. Bull. Hosp. Joint. Dis. 1956. 18. P.141-51.
3. Naseer Ahmed Mir, Asif Nazir Baba, Saheel Maajid, Abdul Rashid Badoo, Ghulam Rasool Mir. Osteoblastoma of body of the talus— Report of a rare case with atypical radiological features. Foot and Ankle Surgery. 2010, June Volume 16, Issue 2. P.24–26.
4. Nicholas J. Giannestras, M.D., And Jack R. Diamond, M.D., Cincinnati, Ohio. Benign Osteoblastoma of the Talus-A Review of the literature and report of a case. The Journal Of Bone And Joint Surgery. 1958, April, VOL. 40-A, NO. 2. P.469-78.
5. H M Kroon and J Schurmans. Osteoblastoma: clinical and radiologic findings in 98 new cases. Radiology. 1990 June, 175. P.783-790.
6. Yener Saglik, Hakan Atalar, Yusuf Yildiz, Kerem Basarir, Cuneyd Gunay. Surgical treatment of osteoblastoma: A report of 20 cases. Acta Orthop, Belg. 2007, Vol. 73-6. P.747-53.
7. Carol D. Morris, Francis Y. Lee, Mark C. Gebhardt. Benign Bone Tumors. In: Chapman, Michael W: Chapman's Orthopaedic Surgery. 3rd Edition. ISBN: 0-7817-1487-7. Lippincott Williams & Wilkins 2001. P.3386-89.
8. Rodolfo Capanna M.D., James R. Van Horn M.D., Alberto Ayala M.D., Piero Picci M.D., Graziano Bettelli M.D. Osteoid osteoma and osteoblastoma of the talus. Skeletal Radiology. 1986, June. Vol- 15, Issue 5. P. 360-64.

Conflict of Interest: Nil
Source of Support: None

How to Cite this Article

Patil KS, Somayaji HM, Nandi SS. A Rare Case Report of A Young Male Patient Presenting with Osteoblastoma of the Talus. Journal of Orthopaedic Case Reports 2014 Oct-Dec;4(4): 22-24