



Contents lists available at BioMedSciDirect Publications

## International Journal of Biological & Medical Research

Journal homepage: www.biomedscidirect.com



### Case report

## Filariasis presenting as non resolving pleural effusion.

\*<sup>a</sup>Yelikar BR, <sup>b</sup>Potekar RM, <sup>c</sup>Mahesh Kumar U, <sup>d</sup>Vijayalaxmi S Patil

<sup>a</sup> Professor and Head, Department of Pathology,

<sup>b</sup> Professor, Department of Pathology,

<sup>c,d</sup> Assistant Professor, Department of Pathology, Shri BM Patil Medical College, Bijapur, Karnataka, India

#### ARTICLE INFO

##### Keywords:

Filariasis  
Microfilaria  
Pleural fluid

#### ABSTRACT

Filariasis is common in tropical countries and is endemic in India; however, the finding of microfilaria in the pleural fluid is very rare. We herein report a case of filariasis presenting as non resolving pleural effusion. To the best knowledge of the authors, till date only 12 cases have been reported in the medical literature, in which microfilaria was demonstrated in the pleural effusion, ours is the 13th case being reported.

©Copyright 2010 BioMedSciDirect Publications IJBMR -ISSN: 0976:6685. All rights reserved.

### 1. Introduction

Filariasis is a major public health problem in India with heavily endemic areas being Uttar Pradesh, Bihar, Andhra Pradesh, Orissa, Tamil Nadu, Gujarat and Kerala. Wuchereria Bancrofti is the most widespread of filarial organisms infecting humans [1].

The major clinical presentations of filariasis include fever, asymptomatic microfilariaemia, lymphatic obstruction and tropical pulmonary eosinophilia. Acute manifestations are usually fever, adenolymphangitis, funiculitis, epididymitis or orchitis. Lymphoedema, hydrocele, elephantiasis, chyluria are the features of chronic filariasis [2].

The adult worm resides in lymphatic vessels, whereas microfilariae, the larval forms circulate in peripheral blood. Microfilariae probably appear in tissue fluids and exfoliated surface material due to lymphatic or vascular obstruction. Diagnosis of filariasis is made on demonstrating microfilariae in the blood samples and body fluids, Adult parasites can be demonstrated only at autopsy [1].

To the best knowledge of the authors, till date only 12 cases have been reported in the medical literature, in which microfilarias were demonstrated in the pleural effusion, ours is the 13th case to be reported [Table- 1].

**Table 1: List of cases where filariasis was noted in pleural fluid cytology**

No. of Cases	Name of the author / Year
One	Vishwanathan R in 1945. [7]
One	Seth GP in 1969. [8]
One	Boornazian JS in 1985.[9]
One	Agarwal J in 1993.[10]
One	Arora VK in 1994.[2]
One	Arora BS in 2000.[11]
One	Marathe A in 2003.[6]
One	Patil PL in 2005.[5]
(associated with malignancy)	
One	Sivakumaran P in 2007.[12]
( associated with malignancy)	
One	Menon B in 2008.[13]
One	Garg R in 2010.[1]
One	Singh SK in 2010.[4]
(associated with malignancy)	

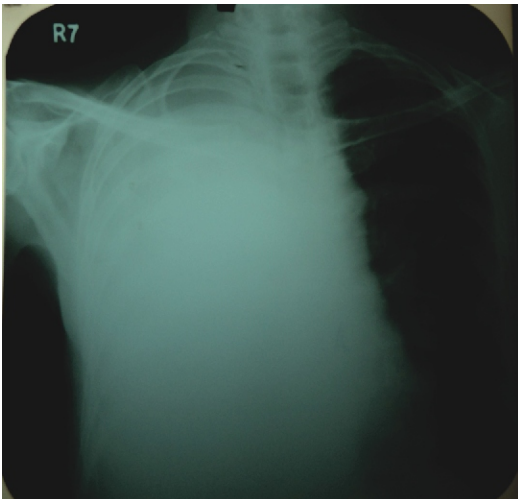
### 2. Case history

A 65 year old male patient presented with productive cough, right sided chest pain, and breathlessness, which is on and off from past one year. But from last 15 days he complaints of low grade fever, abdominal pain and malaise. All other members of the family were reported to be healthy.

\* Corresponding Author : Dr.Yelikar BR  
Professor and Head, Department of Pathology,  
BLDE University's Shri B.M. Patil Medical College Hospital  
& Research Centre,  
Bijapur, Karnataka, India.  
Mobile no: +919739317309  
Email: bldepathology@yahoo.com

On physical examination, he had reduced chest expansion, stony dull percussion and reduced breath sounds on the right side. Vital signs were within normal limits. He was investigated on the lines of non resolving pleural effusion keeping the differential diagnosis of tuberculosis, malignancy and collagen vascular disease in mind. His routine blood investigations and biochemistry were within normal limits. Chest X-ray showed right lower lobe collapse with right sided pleural effusion (Figure-1). Ultrasonography of the chest revealed right encysted pleural effusion with int-echo (exudates/hemorrhage) with partial collapse of right lower lobe. Ultrasonography of the abdomen was within normal limits. Mantoux test showed no induration. Sputum examination was evaluated three times, which was negative for acid fast bacilli and malignancy.

**Figure 1: Chest X-ray showing right sided pleural effusion**



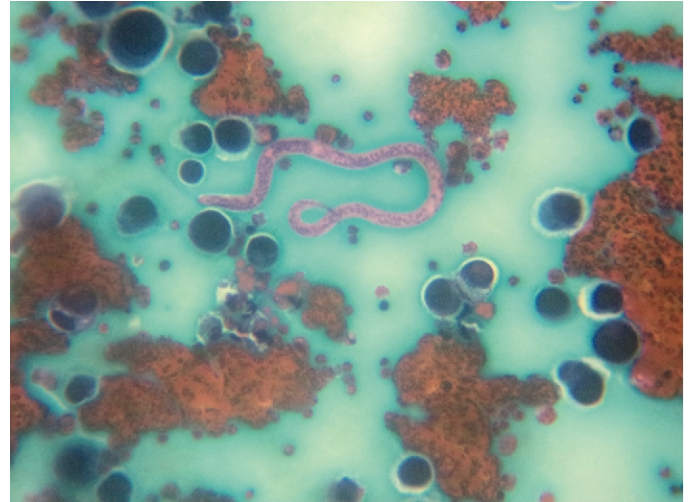
Pleural tap was performed and hemorrhagic fluid was aspirated which on examination showed 500 cells/cu mm, 4.9 gm/dl of protein, 30 mg/dl of glucose. Acid fast bacilli were not detected in the smears made from fluid and culture for mycobacterium tuberculosis was negative.

Microscopic examination of pleural fluid from centrifuged sediments showed many microfilaria with adjacent mesothelial cells, lymphocytes and few reactive mesothelial cells having increased nucleo-cytoplasmic ratio, moderate amount of vacuolated cytoplasm, eccentrically placed nuclei with coarse chromatin and regular nuclear membrane (Figure-2).

Pleural fluid cytology was reported as Primary filarial effusion with reactive mesothelial cells. However, no microfilaria was detected from nocturnal peripheral blood.

The patient was treated with diethyl carbamazine citrate (DEC) in the dose of 6 mg/kg body weight for 12 days orally in divided doses after food, as recommended by WHO. Follow up after 2 months did not show any recurrence of pleural effusion.

**1)Figure 2: Microfilaria is seen with many reactive mesothelial cells.**



### 3.Discussion:

Filariasis is a major public health problem in India. *Wuchereria Bancrofti* is the most widespread of the filarial organisms infecting man. The parasite is endemic in both urban and rural areas of India [2]. It has been estimated that 374 million persons are living in endemic areas and 45 million are infected in India [3].

Diagnosis of filariasis is made on demonstrating microfilariae in the blood samples and body fluids. Microfilaria have been identified in samples submitted for cytological examination, such as aspirated material from lymph node, breast lumps, cutaneous swellings and also from bone marrow, bronchial aspirate, nipple discharge, ascitic, pleural and pericardial fluid, ovarian cyst fluid and cervicovaginal smears. However, pleural effusion is an uncommon manifestation [4].

The host's immune response directed against the parasite lying in different lymphatic vessels appears to be the major factor in determining the clinical presentation. However, whether the immune response is due to the embryos, adult worm or larval antigens is not known. Exudative effusion observed in our patient appears to be due to lymphangitis and incomplete obstruction of lymphatics. However, the atypical hypersensitivity reaction which is known to occur in patients with lymphatic filariasis cannot be ruled out [2].

In India the most common cause of pleural effusion is tuberculosis and therefore this was the first diagnosis considered. Malignancy is the commonest cause of hemorrhagic pleural effusion seen with malignancy of lung, breast, and lymphoma or as adenocarcinoma from occult primary [5].

Ultrasound or CT guided thoracocentesis with cytological examination of pleural fluid aspirated or pleural biopsy performed improves cytological yield greatly.

**4. Conclusion:**

Filarial etiology should be considered in the differential diagnosis of idiopathic cases of pleural effusion from endemic (as well as non endemic) areas. In cases of recurrent effusion, tuberculosis and malignancy should be considered first, but a careful search for microfilaria in centrifuged sediments of pleural fluid may be quite rewarding.

**5. References:**

- [1] Garg et al. Non resolving pleural effusion in an elderly women: A Case report. *Annals of thoracic medicine* 2010;5(4):247-248.
- [2] Arora VK and Gowrinath K. Pleural Effusion due to Lymphatic Filariasis. *Indian J Chest Dis Allied Sci* 1994;36(3):159-161.
- [3] WHO Expert Committee on Filariasis. Lymphatic filariasis. 5th Report, WHO Tech Rep Series 1992; pp 3-45.
- [4] Singh et al. Microfilaria in malignant pleural effusion: An unusual association. *Indian Journal of Medical Microbiology* 2010;28(4):392-394.
- [5] Patil PL, Salkar HL, Ghodeswar SS, Gawande JP. Parasites (filaria and strongyloides) in malignant pleural effusion. *Indian J Med Sci* 2005;59:455-456.
- [6] Marathe A, Handa V, Mehta GR, Mehta A, Shah PR. Early diagnosis of pleural effusion. *Indian Journal of Medical Microbiology* 2003;21(3):207-208.
- [7] Vishwanathan R. Pulmonary eosinophilosis. *Indian Med Gaz* 1945;80:392-396.
- [8] Seth GP, Mukherjee S. Filarial pleurisy with effusion. *Indian J Chest Dis* 1969;9:213-217.
- [9] Boornazian JS, Fagan MJ. Tropical pulmonary eosinophilia associated with pleural effusions. *Am J Trop Med Hyg* 1985;34:473-475.
- [10] Agrawal J, Kapila K, Gaur A, Wali JP. Bancroftian filarial pleural effusion. *Post Grad Med* 1993; 69: 869-870.
- [11] Arora BS, Kumar S, Mathur MD. Filariasis as a cause of pleural effusion. *Indian J Pathol Microbiol* 2000; 43: 491-492
- [12] Sivakumaran P, Wilsher ML. Microfilarial pleural effusion associated with adenocarcinoma. *Intern Med J* 2007;27:341.
- [13] Menon B, Garg A, Kalra H, Sharma R. Microfilarial pleural effusion in a case of tropical pulmonary eosinophilia. *Indian J Chest Dis Allied Sci* 2008;50:241-243.