

Cowden's disease : A rare case

Yelikar BR*, Maheshkumar U**, Vijayalaxmi SP**, Raghunath R***

Abstract

Cowden's disease is an autosomal dominant genetic syndrome characterized by multiple hamartomas involving organs derived from all three germinal layers. Incidence of Cowden's disease is estimated at approximately 1:2,00,000. A 24 year female presented with multiple asymptomatic skin lesions over the face, of 18 months duration. Mucosa of oral cavity showed firm verrucous lesions and cobble stone appearance. On skin biopsy Trichilemmoma was diagnosed. Oral mucosal biopsy was diagnosed as fibroepithelial polyp. Correlating with the clinicopathological features, a final diagnosis of Cowden's disease was made.

Key words: *Trichilemmoma, Fibroepithelial polyp, Cowden's disease.*

Introduction

Cowden's disease is an autosomal dominant genetic syndrome characterized by multiple hamartomas involving organs derived from all three germinal layers. The commonly involved sites are gastrointestinal tract and mucocutaneous locations. It is one of the 50 cancer related genodermatoses and was first reported by Lloyd and Dennis in 1963, who named the disease after their patient Rachel Cowden.^[1]

Case Summary

A female, 24 years old, presented with multiple asymptomatic skin lesions over the face, of 18 months duration. She had undergone thyroid surgery a few months back. On examination, multiple skin coloured papules were seen over the face, ears and neck (Figure 1). Hyperkeratotic hypopigmented papules were seen over the acral areas. Mucosa of oral cavity showed firm verrucous lesions with cobble stone appearance (Figure 2). Operative scar mark was present over the thyroid region. Systemic examination was within normal limits.

* Professor and Head,

** Assistant Professor,

*** Post graduate student,

Department of Pathology, Shri. BM Patil Medical College, Bijapur, Karnataka.

Address for correspondence:

Dr. Yelikar BR,

Professor and Head, Department of Pathology,

Shri. BM Patil Medical College, Bijapur, Karnataka.

E-mail: maheshdearmedico@yahoo.co.in

Pathology

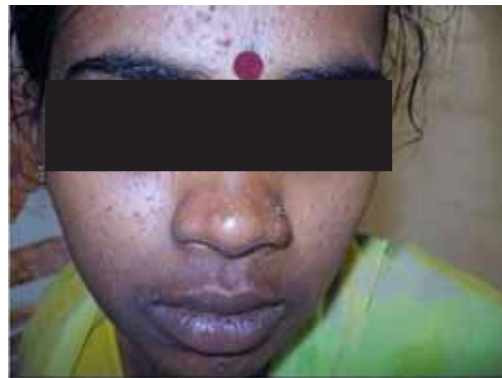

Figure 1: Multiple skin coloured papules over face.

Macroscopy

Adequate biopsies from the skin and the mucosal lesion were carried out.

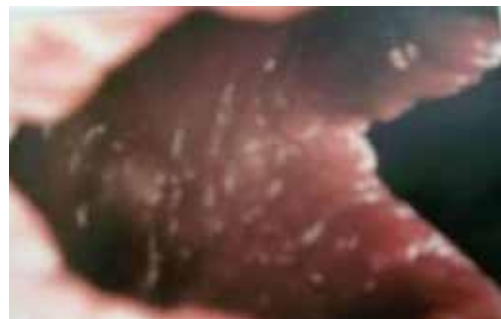


Figure 2: Oral cavity - Verrucous lesion and cobblestone appearance

Microscopy

Biopsies from skin lesions over the face and oral mucosa showed features of trichilemmoma and fibroepithelial polyp respectively (Figure 3, 4, 5, 6, 7).

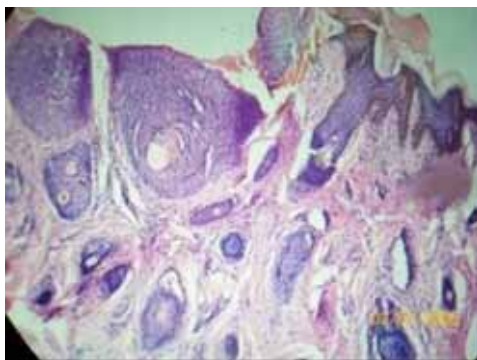


Figure 3: Biopsy showing features of Trichilemmoma and fibroepithelial polyp

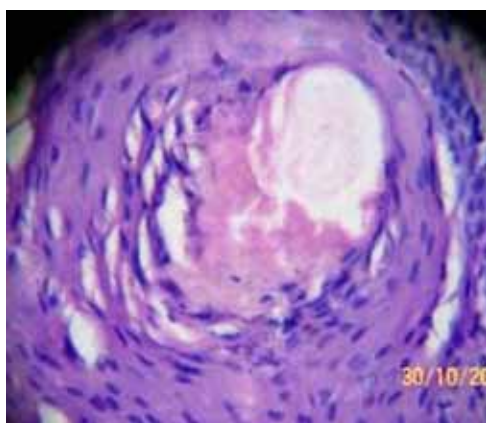


Figure 4: Photomicrograph of lobule, showing nuclear palisading at borders with central keratinization (Haematoxylin and Eosin (H&E) x 400).

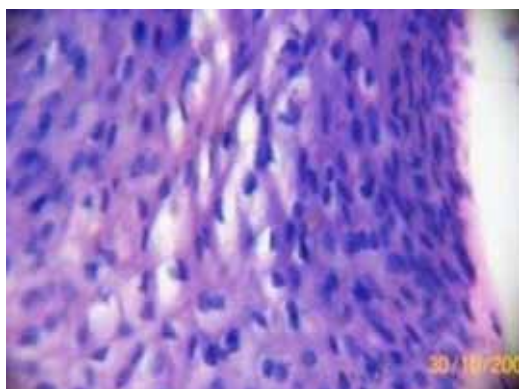


Figure 5: Photomicrograph: Cells showing clear cytoplasm (H&E, x 400).

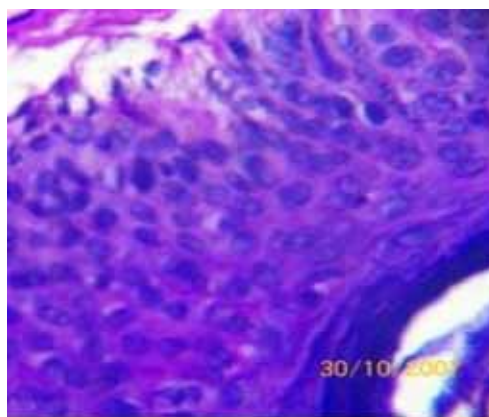


Figure 6: Photomicrograph: Cells showing PAS positivity

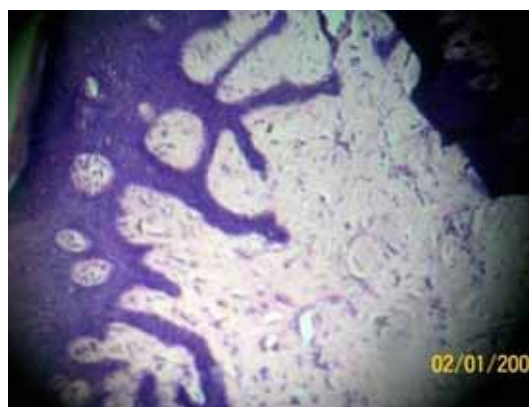


Figure 7: Photomicrograph, showing features of fibroepithelial polyp (H&E, x 400).

Discussion

Incidence of Cowden's disease is estimated at approximately 1:2,00,000.^[1] There appears to be a female predominance of 3:1.^[2] Approximately 80% of the patients carry the mutation in the tumor suppressing gene PTEN (Phosphatase and tensin homologue) located on chromosome 10q23.^[3] This gene inhibits tumor growth acting as regulator of the cellular growth activated by tyrosine kinase.

Four pathognomic criteria proposed by International Cowden Consortium (2000) are: 1) Multiple facial trichilemmomas, 2) Acral keratoses, 3) Papillomatous papules 4) Mucosal lesions.^[3]

While these hamartomatous lesions do not have malignant potential, the syndrome predisposes the patient to develop various malignancies, especially of thyroid, breast, colon, endometrium and brain.^[1]

In our case, multiple trichilemmomas, acral keratoses and oral fibroepithelial polyp were found, which were the pathognomonic lesions of Cowden's disease. Though, patient had undergone thyroid surgery, details were not available.

Conclusion

Cowden's disease is associated with the development of several types of malignancies, in particular breast carcinoma in women and thyroid carcinoma in both men and women. Early diagnosis of mucocutaneous lesions facilitates the monitoring, diagnosis and treatment of the patients in the initial stages, as well as prescribing systematic family screening.

References

1. Uppal S, Mistry D, Coatesworth AP. Cowden's disease: A review. *Int J Clin Pract* 2007; 61(4): 645-652.
2. Tumors of the hair follicle, In: Mckee PH, Calonje E, Granter SR. Eds. *Pathology of the skin with clinical correlations*. 3rded. Philadelphia. Elsevier, 2005:1519-1563.
3. Capitan Canadas LM, et al. Multiple oral fibropapillomatosis as an initial manifestation of Cowden Syndrome-Case report. *Med Oral Pathol Oral Cir Buccal* 2006; 11:319-324.

