

**PROSPECTIVE STUDY TO ASSESS SENSORINEURAL
HEARING LOSS FOLLOWING MIDDLE EAR
SURGERIES**

BY

Dr. TEJASWINI PATEL

Dissertation submitted to the

Rajiv Gandhi University of Health Sciences, Karnataka. Bangalore.



In partial fulfilment

of the requirements for the degree of

MASTER OF SURGERY

In

OTORHINOLARYNGOLOGY

Under the guidance of

Dr. N. H. KULKARNI M.S., D.L.O

PROFESSOR AND HEAD

DEPARTMENT OF OTORHINOLARYNGOLOGY

**B. L. D. E. A'S SHRI B. M. PATIL MEDICAL COLLEGE
HOSPITAL & RESEARCH CENTRE, BIJAPUR.**

2010

DECLARATION BY THE CANDIDATE

I solemnly declare that this dissertation titled “**PROSPECTIVE STUDY TO ASSESS SENSORINEURAL HEARING LOSS FOLLOWING MIDDLE EAR SURGERIES**” has been prepared by me under the direct supervision and guidance of **Dr. N.H. KULKARNI**, Professor and Head of the Department of OTORHINOLARYNGOLOGY, BLDEA`s Shri B.M.Patil Medical College, Bijapur and is submitted to Rajiv Gandhi University of Health Sciences Bangalore in partial fulfilment of its regulations for the award of the degree of “**MASTER OF SURGERY IN OTORHINOLARYNGOLOGY**”. This work has not been submitted by me for award of any other degree or diploma by any other University.

Date:

Dr. Tejaswini Patel

Place:

**BLDEA'S SHRI B.M PATIL MEDICAL COLLEGE, HOSPITAL
AND RESEARCH CENTRE, BIJAPUR.**

DEPARTMENT OF OTORHINOLARYNGOLOGY

CERTIFICATE BY THE GUIDE

This is to certify that this dissertation entitled “**PROSPECTIVE STUDY TO ASSESS SENSORINEURAL HEARING LOSS FOLLOWING MIDDLE EAR SURGERIES**” is the bonafide work of Dr. Tejaswini Patel, a post graduate student in **OTORHINOLARYNGOLOGY** and is done under my direct supervision and guidance at BLDEA'S Shri B.M Patil Medical College, Hospital and Research Centre Bijapur, in partial fulfilment of the regulations of Rajiv Gandhi University of Health Sciences, Bangalore for the award of the degree of “Master of Surgery in Otorhinolaryngology”.

I have satisfied myself that her observations noted in this dissertation are authentic and also that these confirm with the standards of Rajiv Gandhi University of Health Sciences, Bangalore.

I have great pleasure in forwarding this dissertation to the university.

Date:

Place: Bijapur

**Dr. N. H. Kulkarni
Professor and HOD
Dept of Otorhinolaryngology
BLDEA`s Shri. B. M. Patil
Medical College, Bijapur**

**BLDEA'S SHRI B.M PATIL MEDICAL COLLEGE, HOSPITAL
AND RESEARCH CENTRE, BIJAPUR.**

**ENDORSEMENT BY THE HOD, PRINCIPAL/HEAD OF THE
INSTITUTION**

This is to certify that this dissertation titled “**PROSPECTIVE STUDY TO ASSESS SENSORINEURAL HEARING LOSS FOLLOWING MIDDLE EAR SURGERIES**”, a bonafide research work done by Dr. Tejaswini Patel is in partial fulfilment of the regulations of Rajiv Gandhi University of Health Sciences, Bangalore for the award of the degree of “**MASTER OF SURGERY IN OTORHINOLARYNGOLOGY**” under the guidance of Dr. N. H. Kulkarni, Professor and Head of the Department of **OTORHINOLARYNGOLOGY**, BLDEA's Shri B.M.P Medical College, Bijapur.

I have great pleasure in forwarding this dissertation being submitted to Rajiv Gandhi University of Health Sciences, Bangalore.

Dr. N. H. Kulkarni

Prof and HOD,
Department of
Otorhinolaryngology.
BLDEA's Shri B.M. Patil Medical College,
Bijapur.

Date:

Place : Bijapur

Dr. M.S. Biradar

Incharge Principal,
BLDEA's Shri B.M. Patil
Medical College, Bijapur.

Date:

Place : Bijapur

COPYRIGHT

Declaration by the Candidate

I hereby declare that the Rajiv Gandhi University of Health Sciences, Karnataka shall have the rights to preserve, use and disseminate this dissertation / thesis in print or electronic format for academic / research purpose.

Date:

Dr. Tejaswini Patel

Place: Bijapur

© Rajiv Gandhi University of Health Sciences, Karnataka

ACKNOWLEDGEMENT

I take this opportunity to express my most humble and sincere gratitude to my guide and mentor **Dr. N.H. Kulkarni** M.S.,D.L.O. (ENT), Professor and Head of the department of Otorhinolaryngology, BLDEA's Shri B.M. Patil medical college, Bijapur for his invaluable advice, constant guidance and motivation during this dissertation work. I am obliged to him for his patience, co-operation, encouragement and interest which he generously showed during the preparation of this work.

I am very grateful to **Dr. S.P. Guggarigoudar** M.S. (ENT) Professor of the department of Otorhinolaryngology for his prudent and authoritative retrospective of this manuscript and impassioned ebullience, which actuated me to furnish an adept study. I am deeply indebted to him for his invaluable guidance.

I am thankful to **Dr. R.N. Karadi** M.S. (ENT), Professor, **Dr. H.T Lathadevi** M.S. (ENT), Associate professor, **Dr. S.R. Malipatil** M.S. (ENT), Assistant Professor, **Dr. Venkatesh Patil**, D.L.O., D.N.B. (ENT), Senior resident, for their congenial supervision, assiduous concern and positive feedback, which has made it conceivable for me to expedite this dissertation.

I wish to express my thanks to **Dr. M.S. Biradar**, M.D., In charge Principal, BLDEA's Shri B.M.Patil Medical College, Bijapur for allowing me to do this work, to access medical records, utilize clinical material and facilities in this institution.

I am extremely grateful to **Dr. M.A. Mohsin** and **Dr. N. Abhishek** for their advice and support during this period.

I am very grateful to our Audiologist, **Ms. Anupama** (Audiology & Speech Pathology), **Mr. Mohan** M.L.I.S.C, M.Phil (Chief Librarian).

I remain grateful to my friends and well wishers **Dr.Chandrakala, Dr. Roshan, Dr. Sarfaraz, Dr. Preety, Dr. Shilpa, Dr. Anitha, Dr. Sapna, Dr. Sowmya, Dr. Archana.**

I am deeply indebted to my father **Dr. Niranjan**, mother **Dr. Shashikala**, brother **Dr. Abhinandan**, my husband **Dr. Jaitra** and my in-laws **Dr. Prabhakar** and **Smt. Gangambika**, without them there is nothing, whose constant encouragement and moral support led me to successful completion of my dissertation work.

Last but not the least, I convey my heartfelt gratitude to all the patients without whose co-operation this study would be incomplete.

Dr. TEJASWINI PATEL

LIST OF ABBREVIATIONS USED

CSOM	: Chronic suppurative otitis media
dB	: Decibel
KHz	: KiloHertz
PTA	: Pure tone audiometry
SNHL	: Sensorineural Hearing Loss
MRM	: Modified radical mastoidectomy

ABSTRACT

Background: Sensorineural Hearing Loss (SNHL) may result from drill generated noise produced during middle ear surgeries. Though it is suggested by many it is not properly documented.

Objective: This study was carried out to assess sensorineural hearing loss following middle ear surgeries.

Methods: 60 patients were studied and their bone conduction levels were recorded pre-operatively and post-operatively on first, seventh and twenty-first days. The presence or the absence of SNHL was determined by comparing between the two.

Results: Pre operative and post operative bone conduction levels were compared by using paired-t test. The p values post operatively first day (p-0.484), seventh day (p-0.716), twenty-first day (p-0.665) were insignificant.

Interpretation and conclusion: In our study there was no sensorineural hearing loss following middle ear surgeries. No significant correlation was found between duration of discharge, type of surgery, duration of surgery and SNHL.

Key words: Sensorineural hearing loss; pure tone audiometry

TABLE OF CONTENTS

Sl.No.	PARTICULARS	PAGE No.
1	INTRODUCTION	1
2	OBJECTIVE	2
3	REVIEW OF LITERATURE	3
4	METHODOLOGY	45
5	RESULTS	56
6	DISCUSSION	68
7	CONCLUSION	70
8	SUMMARY	71
9	BIBLIOGRAPHY	72
10	ANNEXURE I (Proforma)	76
	ANNEXURE-II (Master Chart)	85

LIST OF TABLES

Sl. No.	TABLES	PAGE No.
1	Duration of symptoms	57
2	Appearance of tympanic membrane	59
3	Sex distribution	60
4	Age distribution	62
5	Surgical procedures performed	64
6	Duration of surgery	66
7	Comparison between pre and post operative bone conduction values	67

LIST OF FIGURES

SL. No.	GRAPHS	PAGE No.
1	Duration of symptoms	57
2	Appearance of tympanic membrane	59
3	Sex distribution	60
4	Sex distribution (pie chart)	61
5	Age distribution	62
6	Age distribution (pie chart)	63
7	Surgical procedures performed	64
8	Duration of surgery	66

INTRODUCTION

Chronic suppurative otitis media (CSOM) is the most common middle ear disease that is encountered in our set up.

There are various surgical procedures that are performed in cases of CSOM and other similar conditions of the middle ear. It has been said that procedures like mastoidectomy, tympanoplasty, ossiculoplasty, stapedectomy etc can lead to sensory neural hearing loss due to the meddling of middle and inner ear.

Temporary and persistent threshold shifts can occur after ear surgeries. Any type of otosurgical procedure involves the risk of inner ear damage. As middle ear surgery is also performed for functional reasons this risk should be taken into consideration.

Exposure to high levels of noise is known to be harmful to the ear. Cochlear injury may be sustained from sudden impact noise or may develop gradually over a period of time if noise exposure is prolonged. Noise exposure to drill generated sound may result in a transient hearing deficit or permanent hearing impairment.

It is certainly accepted that middle ear surgery carries a small risk of sensory neural hearing loss. Apart from inner ear injury resulting from manipulation of the ossicles, drilling itself may cause a hearing loss in a number of ways.

AIM AND OBJECTIVE

1. To assess sensory neural hearing loss following middle ear surgeries.

REVIEW OF LITERATURE:

Schick B, Schick BT, Kochanek S, Starlinger V, Iro H¹ conducted a retrospective analysis of temporary sensory hearing deficits after ear surgery. In this study, thresholds at 500Hz, 1000Hz, 2000Hz and 4000Hz were analyzed in 393 patients before, the first 4 days and 3 weeks after ear surgery to evaluate possible temporary threshold shifts. They concluded that slight temporary threshold shifts could be observed at 2000hz and 4000Hz after ear surgery. Use of the drill and manipulation at the ossicular chain usually results in no significant sensory hearing deficit.

Vallter C, Bair G, Schalln F, Maller J, Helms J² conducted a study on inner ear depression after middle ear interventions. A total of 3989 middle ear cases operated on between 1991 and February 1999 at the department of Otorhinolaryngology, Head and Neck Surgery, University of Warzburg, Germany were studied retrospectively. The pre- and postoperative audiograms in the frequency range between 500 and 8000Hz were analyzed and correlated to the different intra operative findings. They concluded that the risk for sensory neural hearing loss caused by middle ear surgery is low. None of the analysed factors seemed to be a relevant prognostic risk factor for postoperative inner ear depression

Urquhart AC, Mcintosh WA, Bodenstein NP³ conducted a study to demonstrate drill- generated sensory neural hearing loss following mastoid surgery. In a prospective study of 40 patients, audiometric testing was done both pre-and postoperatively to try to detect any significant hearing loss in the immediate postoperative period. It was concluded that sensory neural hearing loss soon after mastoid surgery is not due to the noise generated by the drill and in the event of any hearing loss during this period, other causes should be sought.

Domanech J, Carulla M, Traserra J⁴ conducted a study to demonstrate sensory neural high-frequency hearing loss after drill generated acoustic trauma in tympanoplasty. 24 patients with normal bone- conduction audiometric thresholds scheduled for tympanoplasty were assessed with an electro-stimulation, bone conduction high-frequency audiometer which can measure hearing frequencies up to 20kHz before and after surgery. It was concluded that drilling of the temporal bone could impair the hearing level in the high frequencies in a significant number of patients.

Hattenbrink KB⁵ conducted a prospective study to study the reaction of the cochlea after the trauma of middle ear surgery. For this purpose the bone conduction of fifty patients was tested everyday, beginning on the first post-operative day. To collect the information on possible damaging mechanisms, three surgical techniques were studied: Stapes surgery with the opening of inner ear; Mastoidectomy with drill-generated noise; Tympanoplasty with manipulation at the stapes. He concluded that excessive drilling may result in a temporary threshold shift, which has already resolved at the time of unpacking the ear and no signs of hydraulic damage after manipulation of the stapes could be discovered.

Lukowski M, Bia A, Aczewski L⁶ conducted a study to evaluate bone conduction after ear surgery and stapedectomy. The bone conduction threshold changes of 295 ears, which underwent ear surgery (177 ears) or stapedectomy (118 ears) were determined by comparing last pre-operative with 4-6 weeks post-operative audiogram. Three types of middle ear operations were evaluated: radical mastoidectomy, modified radical mastoidectomy and intact wall mastoidectomy with tympanoplasty. A total stapedectomy was performed with adipose seal and tarflen prosthesis. They concluded that the observed changes in the bone conduction

thresholds could be due to damaging risk of surgical procedure (chronic ear surgery and stapedectomy) and influence of ossicular chain mobilization on bone conduction transmission (stapedectomy). Direct drilling on the middle ear ossicles results in sensory neural hearing loss. Helms (1976) demonstrated experimentally that drilling on the ossicles sets the footplate moving at a speed corresponding to a damaging noise of at least 130 dB. Whether or not drill-generated noise in mastoidectomy may result in a high-tone loss in the ipsilateral ear is still a controversial issue. In large clinical series, sensorineural hearing loss following middle ear surgery has been demonstrated in 1.2 % to 4.5 % of patients (Palva *et al*¹⁸, 1973; Smyth⁸, 1977; Tos *et al*¹⁷, 1984). It was suggested in these studies that drill-generated noise transmitted via the bone, and not via the ossicles, in some cases might be responsible for the high-tone loss, especially since the frequency of 4000 Hz was involved in all cases. Experimental studies in guinea pigs have shown that drilling noise causes a severe loss of sensory cells in the cochlea (Soudijn³¹, 1976).

Measurements on temporal bones performed by Schuknecht and Tondorff¹²(1960) and Paulsen and Vietor²⁴ (1975) showed noise levels of 50-60 dB and it was concluded that bone-conducted noise is of no importance for the development of high-tone loss in patients, whereas air-conducted noise may be dangerous for the surgeon! Performing drilling experiments on temporal bones in intact skulls, Kylan and Arlinger (1976) measured a noise level of 100 dB in the ipsilateral cochlea and of 90-95 dB on the contralateral side; the authors concluded that bone-conducted noise trauma might in some cases be responsible for the high-tone loss. The noise level was highest using large burrs and it was higher with cutting than with diamond burrs. The noise level was lowest, about 70-80 dB, using a 2 mm diamond burr. Variations in

rotation speed and site of drilling did not appear to influence the noise level (Kylén *et al.*, 1977a). Pre-operatively, electrocochleography

Migrov L, Wolf M *et al.*³⁶ conducted a study to determine possible changes in the outer hair cell (OHC) function related to drill noise exposure. Drill-induced noise during mastoidectomy can cause reversible changes in DPOAE in the non-operated ear. OHC function may be diminished during the period after mastoid surgery and last >1 month. Five fresh cadaveric temporal bones were used. Stapes displacement was measured using laser Doppler vibrometry during short drilling episodes. Diamond and cutting burrs of different diameters were used. The effect of the drilling on stapes footplate displacement was compared with that generated by an acoustic signal. The equivalent noise level (dB sound pressure level equivalent [SPL eq]) was thus calculated. This study suggests that drilling on the ossicular chain can produce vibratory force that is analogous with noise levels known to produce acoustic trauma. For the same type of burr, the larger the diameter, the greater the vibratory force, and for the same size of burr, the cutting burr creates more vibratory force than the diamond burr. The cutting burr produces greater high-frequency than lower-frequency vibratory energy.

Alison M, Christopher D³⁵ studied the head trauma and mid-frequency hearing loss. Numerous reports in the literature associate head trauma with high-frequency hearing losses, often mimicking "4K notches" attributed to noise exposure. It was observed that some patients with a positive history for head trauma may show midfrequency notches in their audiometric configurations.

Singh A, Kumar S et al³⁴ studied the inherent risk of inner ear damage with middle ear surgeries in 60 patients. Bone conduction thresholds in different frequencies were recorded by a pure-tone audiometer both pre-operatively and post-operatively. The over-all results showed one case (1.67%) with significant or severe SNHL of more than 25 dB and ten cases (16.66%) with mild to moderate SNHL including three cases of temporary threshold shift. In majority of the cases (11.67%) 2000 and 4000 frequencies were involved. The possible causes have been analysed in the study.

M.Tos³³ MD et al conducted a study on 50 patients for undergoing translabyrinthine acoustic surgery for acoustic neuroma. No case of sensory neural hearing impairment could be demonstrated postoperatively. The distance to the contralateral cochlea is considerably larger than to the ipsilateral cochlea and the large cutting burrs are used for only a short period for resection of cortical bone at the start of the mastoidectomy, but the total effective drilling time of 1.5 hours is considerably longer than for a conservative radical operation. After all, there is a limit to how long even an inexperienced surgeon can use a large cutting burr at a conservative radical operation.

Spencer MG, et al²⁵, conducted a study on 5 patients who underwent mastoidectomy. Post-operative pure tone audiometry was carried out on each patient 48 hours after surgery. No evidence of a bone conduction threshold shift was detected in any of the patients in either the operated or the contralateral ear. So they concluded

that a noise induced hearing-loss following mastoid surgery is an unlikely event, especially if the burrs employed are sharp and the drill performance satisfactory.

Surgical Anatomy Of Middle Ear Cleft

The middle ear cleft consists of the eustachian tube, the tympanic cavity (middle ear), the aditus ad antrum and the pneumatic system of the temporal bone.

The ear is the first organ of special senses to become differentiated in man. The middle ear, however is not completely formed at birth.

The anatomy of middle ear cleft is complex. It contains sound conducting apparatus and it is related to important and sensitive neighbouring structures.

The Tympanic membrane

It forms the partition between the external acoustic meatus and the middle ear. It is obliquely set and as a result, its postero-superior part is more lateral than its antero-inferior part. It is 9-10mm long, 8mm wide and 0.1mm thick.

Tympanic membrane can be divided into two parts:

Pars tensa: It forms most of the tympanic membrane. Its periphery is thickened to form a fibrocartilagenous ring called *Annulus tympanicus*, which fits in the tympanic sulcus. The central part of pars tensa is tented inwards at the level of tip of malleus and is called *the umbo*. A bright cone of light can be seen radiating from the tip of malleus to the periphery in the anteroinferior quadrant.

Pars flacida: This is situated above the lateral process of malleus between the notch of rivinus and the anterior and posterior malleal folds. It is not taut and may appear slightly pinkish.

Layers Of Tympanic membrane

Tympanic membrane consists of three layers.

1. Outer epithelial layer (which is continuous with the skin of the external acoustic meatus).
2. Inner mucosal layer (which is continuous with the mucosa of the middle ear).
3. Middle fibrous layer (which encloses the handle of malleus and has three types of fibres- the radial, circular and parabolic).

The Middle ear :

The middle ear extends much beyond the limits of tympanic membrane which forms its lateral boundary and is divided into: 1) *Mesotympanum* (lying opposite to the pars tensa). 2) *Epitympanum* or *attic* (lying medial to sharpnell's membrane and bony attic wall). 3) *Hypotympanum* (line below the level of pars tensa). The portion of the middle ear around the tympanic orifice of the eustachian tube is sometimes called as *the protympanum*.

Middle ear can be likened to a six sided box with the roof, a floor, medial, lateral, anterior or posterior walls.

The roof is formed by a thin plate of bone called *tegmen tympani*. It extends posteriorly to form roof of aditus and antrum. It separates tympanic cavity from middle cranial fossa.

The floor is a thin plate of bone which separates tympanic cavity from the jugular bulb. Sometimes it is congenitally deficient and the jugular bulb may then project into the middle ear, separated from the cavity by the mucosa only.

The anterior wall has a thin plate of bone, which separates cavity from internal carotid artery. It has two openings in its upper portion, the lower opening for eustachian tube and the upper one for tensor tympani muscle.

The posterior wall is close to mastoid air cells. It presents a bony projection called pyramid, through the summit of which appears the stapedius tendon to get attached to the neck of the stapes. Aditus, an opening through which attic communicates with antrum, lies above the pyramid. Facial nerve runs in the posterior wall just behind the pyramid. Facial recess is a depression in the posterior wall, lateral to the pyramid. It is bounded medially by the vertical part of facial nerve, laterally by the chorda tympani and above by fossa incudis. Surgically, facial recess is important as direct access can be made through this into middle ear, without disturbing posterior meatal wall (Intact canal wall technique).

The medial wall is formed by the labyrinth. It presents a bulge called *promontory* which is due to basal coil of cochlea; oval window into which is fixed the footplate of stapes, round window/ fenestra cochlea which is covered by secondary tympanic membrane. Above the oval window is the canal for facial nerve. Its bony covering may sometimes be dehiscent and the nerve may lie exposed making it vulnerable to injuries or infections. Above the canal for facial nerve is the prominence of lateral semicircular canal. Just anterior to the oval window, the medial wall presents a hook like projection called *processus cochleariformis*. The tendon of the

tensor tympani takes a turn here to get attached to the neck of malleus. The cochleariform process also marks the level of the genu of the facial nerve. Medial to the pyramid is the deep recess called *sinus tympani* which is bounded by the subiculum below and ponticulus above.

The lateral wall is formed largely by the tympanic membrane and to a lesser extent by the bony outer attic wall called *scutum*. Tympanic membrane is semi transparent and forms a window into the middle ear.

The Eustachian [Pharyngo tympanic] tube:

It connects the tympanic cavity with the nasopharynx. In the adult it is 36mm long. Its lateral one third (12mm) is bony while its medial two thirds (24mm) is fibrocartilagenous. These two portions meet at an angle called isthmus which is the narrowest part of the tube. The cartilage forming the medial part of the tube contributes to the medial, superior and upper part of the lateral wall of the tube. The rest of the tube being completed by fibrous tissue. At the pharyngeal end the cartilage of the tube raise an elevation called *torus tubaris*. The eustachian tube is wider, shorter and more horizontal in infants, thus permitting infections to travel easily from the nasopharynx.

The mucosa of tympanic cavity:

The middle ear mucosa is to some degree a respiratory mucosa carrying cilia on its surface and being able to secrete mucous. The extent of the mucociliary epithelium varies in the normal middle ear. It is more widespread in the young and it ends at the line of facial nerve in all ages. Above the facial nerve i.e. in the epitympanum and mastoid, a flat non-ciliated epithelium, with only a very occasional

mucus producing cell is found. The mucous comes from the goblet cells and the mucous gland which are a collection of mucous producing cells linked to the surface by a short duct. In the middle ear, the glands are sometimes absent. In those ears where they are present, they tend to be clustered around the orifice of the eustachian tube. Goblet cells eject mucous directly into the middle earspace and are in highest concentration close to the eustachian tube opening. The presence of the goblet cells and mucous glands is indicative of the potential ability of the middle ear mucosa to undergo changes typical of respiratory epithelium.

The mucous membrane lines the bony walls of the tympanic cavity and it extends to cover the ossicles and their supporting ligaments in much the same way as the peritonium covers the abdominal viscera.

The mucosal folds also cover the tendons of the two infratympanic muscles and carry the blood supply to and from the contents of tympanic cavity. These folds separate the middle ear space into compartments and the epitympanic space is only connected the mesotympanum by way of two small openings between the various mucosal folds, the isthmus tympani anticus and isthmus tympani posticus.

Mastoid antrum:

It is a large air containing space in the upper part of mastoid and communicates with attic through the aditus. Its roof is formed by the tegmen antri which separates it from the middle cranial fossa. The lateral wall of antrum is formed by a plate of bone which is on an average 1.5cm thick in the adults. It is marked externally, on the surface of the mastoid by suprameatal (MC Ewen's) triangle.

Aditus ad antrum:

Aditus is an opening through which the attic communicates with the antrum. The bony prominence of the horizontal canal lies on its medial side while the fossa incudis to which is attached the short process of incus lies laterally. Facial nerve's course is just below the aditus.

The mastoid process:

The mastoid process lies behind the tympanic portion of the temporal bone and on a deep level the styloid process. The mastoid portion of the petromastoid bone is flat at birth. The stylomastoid foramen with facial nerve lies on the lateral surface immediately behind the tympanic ring. Its development begins at the end of first year of life and forms a definite elevation at the end of second year and achieves its definitive size at puberty.

20% of the mastoid becomes honeycombed with air spaces (cellular type). In some persons marrow persists within the bony structure of the mastoid (diploic type) and in others aircells and marrow spaces are completely absent (acellular, sclerotic or ivory type).

Pneumatic system of temporal bone:

In the majority of adult population a more or less extensive system of interconnecting air filled cavities arise from the wall of the mastoid antrum and sometimes even from the walls of the epitympanum and mesotympanum. These aircells like the mastoid itself are lined with a flattened nonciliated squamous epithelium.

The process of pneumatisation begins with the resorption of mesenchyme early in the third fetal month. Resorption of mesenchyme progresses very rapidly during the first two months of infancy. It is practically complete in the middle ear by the sixth month and in the mastoid antrum by the first birthday. Pneumatisation of the petrous apex begins about 3rd or 4th year and may continue into early adult life.

The compartments and folds of the middle ear:

During 3rd to 7th month of intrauterine life, four endothelially lined sacs originate from the first pharyngeal pouch to tubotympanic recess. The four sacs are saccus medius, anticus, posticus and superior. The connecting layers of the sacs later forms the mucosal folds and suspensory ligaments of the ossicles.

Saccus medius: saccus medius develops in the later life to epitympanum. Occasionally saccus anticus also contributes to form the epitympanum.

Prussak's space: the medial most saccule of the saccus medius forms the prussak's space. It lies between the neck of the malleus and sharpnell's membrane laterally.

Boundaries: Medially by the neck of malleus, laterally by sharpnell's membrane, superiorly by fibres of lateral malleolar fold and inferiorly by lateral process of malleus.

Superior incudal space: Is also formed by medial most saccule. This space lies lateral to incus body and above head of malleus.

Isthmus tympani anticus: It runs between stapes and tensor tympani tendon, connecting the anterior mesotympanum and anterior attic.

Isthmus tympani posticus: It passes between the short process of the incus and the stapes tendon to the posterior attic and aditus.

Anterior pouch of Von Troeltsch: lies between tympanic membrane and anterior malleolar folds.

Posterior pouch of Von Troeltsch: lies between tympanic membrane and posterior malleolar folds.

The inferior edge of the fold contains chorda tympani nerve. This pouch is open inferiorly to posterior mesotympanum.

The contents of tympanic cavity

Muscles - Tensor tympani and stapedius

Nerves - Chorda tympani and tympanic plexus

Ossicles - Malleus, incus, stapes

Air

Intratympanic muscles

There are two muscles – Tensor tympani and Stapedius. The former attaches to the neck of the malleus and tenses the tympanic membrane while the latter attaches to the neck of the stapes and helps to dampen very loud sounds thus preventing noise trauma to the inner ear.

The Nerves:

Chorda tympani: this branch of the facial nerve enters the tympanic cavity from the posterior canaliculus at the junction of the lateral and posterior walls. It runs across the medial surface of the tympanic membrane between the mucosal and fibrous layers and passes medial to the upper portion of the handle of the malleus above the tendon of the tensor tympani to continue forwards and leave by way of the anterior canaliculus.

The chorda tympani subsequently joins the lingual nerve to supply the anterior 2/3rd of taste buds of the tongue.

The Tympanic plexus: tympanic plexus is formed by the tympanic branch of the glossopharyngeal nerve (Jacobson's nerve) and by the caroticotympanic nerves which arise from the sympathetic plexus around the Internal carotid artery. The nerves form a plexus on the promontory and provide the following:

- 1) Branches to the mucous membrane lining the tympanic cavity, eustachian tube, mastoid antrum and air cells.
- 2) A branch joining the greater superficial petrosal nerve.
- 3) The lesser superficial petrosal nerve, which contains all the parasympathetic fibres of 9th cranial nerve. The nerve is really a continuation of the tympanic branch of glossopharyngeal nerve, which passes through the foramen ovale to the otic ganglion. From this, postganglionic secretomotor fibres are relayed to the parotid gland via the auriculotemporal nerve.

The ossicles:

Malleus

Malleus is the largest of the ossicles. It comprises of head, neck and three processes arising from below the neck. The overall length of the malleus ranges from 7.5mm to 9mm.

The head lies in the epitympanum and has on its posteromedial surface an elongated, saddle shaped, cartilage covered facet for articulation with the incus. This surface is constricted near its middle and the smaller inferior portion at the joint surface lies nearly at right angles to the superior portion.

This projecting lower part is a cog or spur of the malleus. Below the neck of the malleus, the bone broadens and gives rise to petrotympanic fissure, the lateral process which receives the anterior and posterior malleolar folds from the tympanic annulus and the handle.

The handle or manubrium is crescentic and concave laterally. The lower horn of crescent terminates flatly at the umbo. The upper horn projects into the lumen of the external meatus as the lateral process. The handle runs downwards, medially and slightly backwards between the mucosal and fibrous layers of the tympanic membrane on the deep medial surface of the handle, near its upper end, is a small projection into which the tendon of the tensor tympani muscle inserts. Additional support for the malleus comes from the superior ligament which runs from the head of the tensor tympani.

Incus

The incus articulates with the malleus and has a body and two processes. The body lies in the epitympanum and has a cartilage covered facet corresponding to that on the malleus. The short process projects backwards from the body to lie in the fossa incudis to which it is attached by a short ligament. The long process descends into the mesotympanum behind and medial to the handle of the malleus, and its tip is small medially directed lenticular process which articulates with the stapes.

Stapes

The stapes consists of head, neck, two crura (limbs) and a base or footplate. The head points laterally and has a small cartilage covered depression for articulation with the lenticular process of the incus. The stapedius tendon inserts into the posterior part of the neck and upper portion of the posterior crus. The two crura arise from the broader lower part of the neck, and the anterior crus is thinner and less curved than the posterior crus. Both are hollowed out on their concave surfaces, they join the footplate. The foot plate has a convex superior margin, straight inferior margin, curved anterior and posterior ends.

Relations of the middle ear cleft

The external auditory canal is separated from the cavity by the tympanic membrane. The inner ear is separated from the cavity by its medial wall. The temporal lobe of the brain, in the middle cranial fossa, is separated from the tympanic cavity by the thin tegmen tympani which is formed partly by the petrous and partly by the squamous portion of the temporal bone. It is separated from the mastoid antrum by

the tegmen antri. The carotid canal containing the Internal carotid artery is separated from the lower part of the tympanic cavity, anteriorly by a plate of bone which merges with the floor of the cavity. The jugular bulb is closely related to the bony floor of the cavity which may be deficient in part there is no reliable surface landmark for the location of the sigmoid sinus. The glossopharyngeal, vagus and accessory cranial nerves emerge from the skull through the jugular foramen alongside and just medial to the jugular bulb.

The ganglion of trigeminal nerve (gasserian ganglion) lies in a shallow depression (meckel's cave/cavum trigeminate) on the anterior surface of the petrous apex, between two layers of dura.

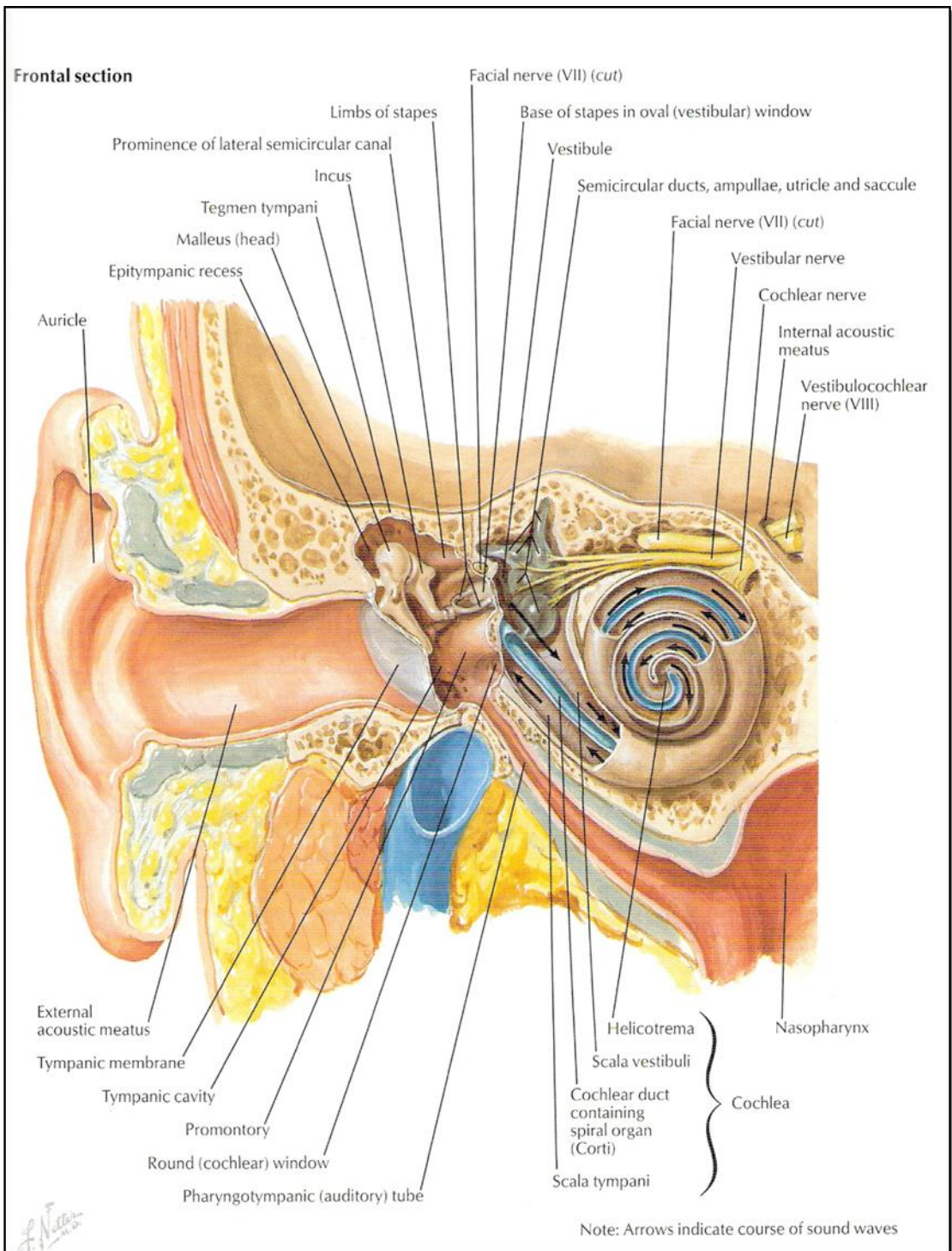
The abducent cranial nerve, the motor nerve to the lateral rectus muscle of the eye, comes into close proximity with the middle ear cleft as it runs along the posterior surface of the petrous apex, in the posterior cranial fossa on its way to Dorello's canal. The canal is formed by the petroclinoid process of the sphenoid bone and the posterior clinoid process of the sphenoid bone.

The facial cranial nerve is related to the middle ear cavity in the horizontal and vertical tympanic portions. The bony covering (the fallopian canal) may be very thin or totally deficient in parts, the nerve being covered only by the tympanic mucoperiosteum in as many as 10% or more of temporal bones.

ANATOMY OF THE INNER EAR

Temporal bone forms a significant portion of base of skull extending from lateral calvaria at the level of ext. auditory canal to almost the centre of the skull as it articulates with basi-sphenoid.

Cranial nerves V to XII course about or through the temporal bone; the middle cranial fossa contents lie on its superior surface and the posterior cranial fossa



Structure of Ear

contents lie on its posterior surface. The internal carotid artery travels through it, and internal jugular vein originates within the temporal bone through the jugular foramina.

The temporal bone consists of four separate bones

- i) Petrous
- ii) Tympanic
- iii) Squamous
- iv) Styloid process.

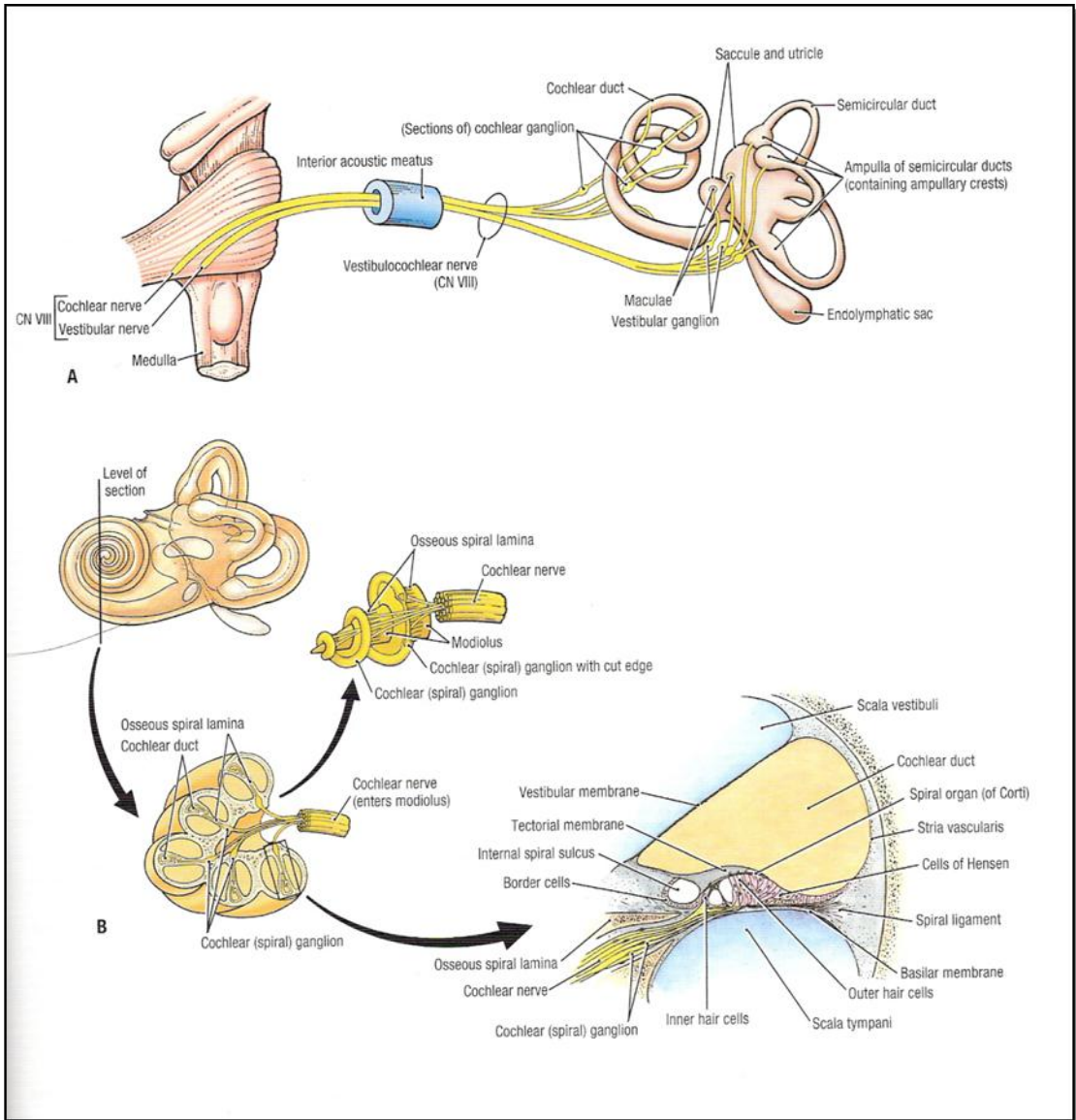
The inner ear or the labyrinth lies in the petrous part of the temporal bone. The auditory and vestibular components of the inner ear are known as the labyrinth because of its serpinginous and convoluted course. Labyrinth is divided into a bony and a membranous portion. The membranous labyrinth containing the sensory epithelium of the cochlea and the vestibular structures lies within the cavities surrounded by the bony labyrinth. The bony labyrinth is derived from inner periosteal layer of the capsule and in adult life consists of a thin but dense bony shell surrounding the vestibule, the semicircular canals and the cochlea.

THE COCHLEA

The bony cochlea lies in front of the vestibule and has an external appearance rather like a shell of a snail. It is a coiled tube, with the inside of the one coil being separated from the lumen of the adjacent coil by a dense, thin bony wall. The shell has approximately two and a half turns. The coil of the cochlea turns about a central cone of modiolus which arises from the cochlear nerve portion of the fundus of the internal auditory meatus. It points laterally and forwards, tapering from the wide base to a narrow apex. The apex of the cochlea therefore, faces laterally and forwards towards the upper part of the medial wall of the tympanic cavity, while the basal coil forms the

bulge of the promontory below this. Arising from the modiolus is a thin shelf of bone that spirals upwards within the lumen of the cochlea as the bony spiral lamina.

The membranous spiral lamina extends from the edge of the bony spiral lamina to the outer wall of the cochlea, thereby dividing each coil into two major portions, scala vestibuli and scala tympani. The scala vestibuli lies above the scala tympani. There is a communication in the perilymph spaces at the apex of the cochlea through an opening called the helicotrema. At the helicotrema the scala vestibuli joins the scala tympani. The part of the otic capsule overlying this apical region is known as cupola of the cochlea. At the cupola the interscalar septum makes an abrupt vertical turn to end in the enchondral bone of the overlying cupola. This abrupt vertical turn of the interscalar septum makes a 90° angle with the hamulus of the osseous spiral lamina. The hamulus circumscribes a semicircle, its outer free edge attaches to the basilar membrane and the inner edge is immediately adjacent to the helicotrema. As the basilar membrane and the spiral ligament reaches the end of hamulus they continue to complete at the apex ultimately ending on the oblique and vertical portion of the interscalar septum. This then creates an oblique channel known as helicotrema formed half by the inner edge of the hamulus of the osseous spiral lamina and half by the end of scala media.



Structure of Inner Ear

CSF may mix with the perilymph through two routes; the cochlear aqueduct and the modiolus. The route through the cochlear aqueduct is direct, the route through the modiolus is serpinginous, beginning in the fundus of internal auditory meatus and passing through the spiral tract of foramina in the cochlear area inferior to the horizontal crest. It then goes directly to osseous spiral lamina at the basal turn of cochlea or through the longitudinal modiolar canals to the middle and apical turn following the nerve fibres. From there the route extends along the osseous spiral lamina, to the habenula perforata at the end of the lamina ultimately entering the organ of corti.

At the base of the cochlea, scala vestibuli opens into the vestibule as fenestra vestibuli and stapes foot plate closes the lateral wall of the vestibule. On the other hand scala tympani is a blind ended tube, but has an anastomosis from the basal end of scala tympani to the cochlear aqueduct.

The modiolus contains many small canals that spread out to enter the bony spiral lamina. Most of the central canals carry fibers to and from the apical regions, while the outermost canals carry the fibers from the more basal parts of the cochlea close to the origin of the bony spiral lamina. These canals dilate to accommodate the bipolar ganglion cells of the spiral (cochlear) ganglion, and the confluence of the dilated spaces has given rise to the name spiral canal of the modiolus.

The cochlear duct (Scala media)

The duct of the cochlea consists of a spirally arranged tube lying on the upper surface of the spiral lamina against the outer wall of the bony canal of the cochlea. Its

average length is 34mm and width approximately 80 μ m. The cochlear duct is a wedge shaped compartment lying between the scala tympani and the scala vestibuli. It is separated from the scala vestibuli by the vestibular (Reissner's) membrane and from the scala tympani by the basilar membrane. The floor is formed by the outer part of the bony spiral lamina and all of the membranous lamina. It has a thin sloping roof i.e. Reissner's membrane – that runs from the bony spiral lamina to the upper part of the outer wall.

The floor of the cochlear duct:

The inner part of the floor is formed by the bony spiral lamina, which separates into two ridges one above the other. The upper one is the spiral limbus, from which the tectorial membrane originates. While the lower ridge gives rise to the membranous spiral lamina and has acoustic nerve fibers running through it to the organ of corti. The membranous spiral lamina has the flattened epithelium of the scala tympani on its outer side, a fibrous middle layer and the organ of corti on its upper surface. This is separated from the spiral limbus by the inner sulcus and from the lateral wall by the outer sulcus.

The organ of corti is a ridge like structure containing the auditory sensory cells and the complex arrangement of supporting cells. The sensory cells are arranged in two distinct groups as inner and outer hair cells. The free surface of each hair cells is covered with bristle like clumps of hair and hence the name. There is single row of inner hair cells, although occasionally extra hair cells may be apparent and also three, four or five irregular rows of outer hair cells with frequent gaps where individual hair cells are absent.

Each hair cell consists of a body, which lies within the organ of Corti and a thickened outer surface called *cuticular plate* from which projects a cluster of stereocilia or hairs. The stereocilia are not true cilia in the sense that they do not have a central duct plus two coils of microtubules, but are more like microvilli comprising of a core of actin molecules packed in a paracrystalline array and covered with a cell membrane. The inner hair cells are separated from the outer by the tunnel of Corti. The bodies of inner hair cells are flask shaped with a small apex and a large cell body. The long axis of the cell is inclined towards the tunnel of Corti, and nerve fibers and nerve endings are located around the lower half of the body. The stereocilia projecting from the thickened cuticular plates are arranged in two or three rows parallel to the axis of the cochlear duct. The shortest row of stereocilia is the innermost while the longest row is the outermost. Along the length of cochlear duct, height of the longest stereocilia increases linearly with distance from the base, although the variation from the base to the apex is not much.

The body of the outer hair cells is cylindrical, with the nucleus lying close to the lower pole, where afferent and efferent nerve endings are attached. The stereocilia that project from this have different arrangement from those of the inner hair cells. There are several rows of stereocilia but the configuration varies from the W-shaped one at the apex. The number of stereocilia also decreases in the passage from the base to the apex, whereas the length increases, although not in a linear fashion.

In the fetus and newborn there are about 3,500 inner hair cells and 13,000 outer hair cells although the number of hair cells varies with the length of the cochlea, shorter cochleae having few inner and outer hair cells. It is observed from cytochleogram that with age there is a generalised reduction in the number of hair

cells and an additional loss both at the base and to a lesser extent, at the apex. These are most marked in the outer hair cell population.

The hair cells are supported by the organ of corti by several types of specialised, highly differentiated cells. These are the pillar cells, Dieters's cells and Hensen's cells.

The tectorial membrane arises from the spiral limbus and extends over the organ of corti to attach close to the Hensen's cell region. The membrane is an acellular gel like matrix containing fibrillar strands and is extremely sensitive to the distortions and shrinkage during most preparation techniques. The tips of the longest cilia of the outer hair cells are attached to or embedded in the undersurface of the tectorial membrane.

The lateral wall of the cochlear duct:

The lateral wall of the cochlear duct has three distinct zones.

1. Stria vascularis above.
2. The spiral prominence below and
3. A transitional zone in between the two.

The stria vascularis forms the bulk of the lateral wall and consists of three cells from the basal cell layer. The marginal cells face the endolymph and are separated by the intermediate cells from the basal cell layer, which is rich in capillaries. The marginal cells have a carpet of microvilli on the endolymphatic surface and tight junctions between neighbouring cells so that the stria vascularis is effectively isolated from the endolymph. These cells are also rich in mitochondria,

have an extensive Golgi apparatus, endoplasmic reticulum and a complex folding of their basal membranes; which interdigitate with the intermediate and basal layer cells. The stria is a metabolically active tissue and it is thought to play an active role in the maintenance of ionic composition and electrical potential of the endolymph.

The roof of the cochlear duct (Reissner's membrane):

Reissner's membrane is a thin membrane stretching from the bony lamina to the upper part of the lateral wall of the cochlear duct. The endolymphatic surface consists of typical squamous epithelial cells with microvilli on their surface and joined together by tight junction. A thin basement membrane separates these cells from those of the upper scala vestibuli side of the partition.

All of the cells lining the scala media are joined by tight junctions which effectively separate the endolymph from the perilymph and helps in maintaining the usual ionic contents of this fluid.

Blood Supply:

The blood supply to the organ of corti and other structures of cochlear duct is provided by vessels within the stria vascularis and also the spiral vessels underlying the basilar membrane and the spiral limbus. The main cochlear artery enters through the modiolus along with the VIII nerve fibers. Arterioles divide at the level of spiral lamina, with one group of vessels proceeding to a position underlying the basilar membrane. The second arteriolar system travels within the periosteal lining across the wall of scala vestibuli to the region of spiral ligament. At this point the arterioles break up to form three capillary networks along the lateral wall of peri-otic labyrinth. The first group of vessels supplies the region of spiral ligament immediately above the insertion of Reissner's membrane. The second group of vessels forms a highly anastomosed capillary bed of stria vascularis. The third set of capillaries supplies the vessels of spiral prominence.

The venous drainage of inner ear is via the vein of the cochlear and vestibular aqueducts. The primary drainage of cochlea is by anterior and posterior spiral veins. The posterior vein drains the inferior medial aspect of cochlea; such as spiral ganglion, scala media and scala tympani. The anterior spiral vein drains the more superolateral, or more anterior cochlea such as scala vestibuli and osseous spiral lamina. These veins enter a common modiolar vein which enters the cochlear aqueduct, tributary to inferior petrosal sinus.

It may be noted that neither the organ of corti nor the corti lymphatic space has blood supply. The neuroepithelium of organ of corti thus receives the oxygen and nutrients indirectly from either the vessels of lateral wall of the cochlear duct or the spiral vessels underlying the basilar membrane.

INNERVATION:

The organ of corti is innervated by two types of nerve fibres. Afferent fibres of auditory portion of VIII conduct nerve impulse from hair cells to brain. Efferent fibres of the olivocochlear bundles conduct nerve impulse from the brain to hair cells.

AFFERENT INNERVATION:

The auditory portion of VIII provides the afferent innervation of the inner and outer hair cells. The cell bodies of the cochlear nerve are located in the modiolus within Rosenthal's canal. Here they form spiral ganglion. The axon of each ganglion cell extends centrally through longitudinal modiolar canal and the cerebellopontine

cistern to synapse in the cochlear nucleus. The peripheral process ends as a dendrite beneath hair cells. The spiral ganglion in the human cochlea is composed of 2 types of neurons. Approximately 9% of the 30,000 ganglion cells are termed type I cells. They have large bipolar cell bodies and a surrounding myelin sheath. The remaining 5% of ganglion cells are type II cells and have small pseudomonopolar cell bodies and relatively thin central and peripheral processes. The peripheral processes of both types of ganglion cells course together and enter the organ of Corti just below the inner hair cells through small openings in the osseous spiral lamina 'The habenula perforata'. Ninety five percent of the processes which arise from type I cells take a direct course to the base of the nearest inner hair cells where they synapse. These are inner radial fibres. Those arising from the type II cells travel basally from about five or six pillar cells and across the tunnel of Corti on the basilar membrane where they are known as basilar fibres. They then extend basally again for 1mm where they are termed outer spiral bundle. Each fibre spirals outward along the rows of outer hair cells and sends branches to about 10 cells.

EFFERENT INNERVATION

The efferent innervation of the hair cells is provided by the olivocochlear bundle. The cell bodies of the olivocochlear bundle are located in the brain stem within the superior olivary complex, primarily in the region surrounding the lateral medial and superior olivary nuclei. The olivocochlear bundle has conventionally been divided into crossed and uncrossed components because each cochlea receives innervation from both sides of the brain. The olivocochlear bundle has been divided into medial, lateral components. The medial division of the olivocochlear bundle consists of

myelinated fibres that originate from large cells in the medial part of superior olivary complex. Axons from the superior olivary complex cross over to the other side of the brain just below the floor of the fourth ventricle and join the ipsilateral fibres. The ipsilateral and contralateral fibres travel peripherally within the vestibular nerve, and join cochlear nerve through port's anastomosis just distal to the spiral ganglion. After entering the modiolus the efferent fibres form the intraganglionic bundles within the rosenthals canal. All fibres lose their myelin sheath before passing through habenula perforata into organ of corti. The medial olivocochlear bundle fibres extend across the middle of the tunnel of corti and make extensive synaptic contact at the base of outer hair cells. The lateral division of the olivocochlear bundle consists of unmyelinated fibres which originates from small cell in the lateral portion of superior olivary muscles. These fibres follow same courses as does the medial division into organ of corti. However; within the organ of corti the fibres course apically beneath the inner hair cells where they are known as inner spiral bundle. They terminate on the dendrites of the cochlear nerve fibres beneath the inner hair cells¹⁹.

Acoustic Nerve:

The acoustic nerve consists of two distinct sets of fibres, the cochlear and the vestibular fibres. The peripheral portion of the cochlear and the vestibular nerves join to form the common acoustic nerve in the internal auditory canal.

It transfers impulses from the organ of corti to the auditory cortex. The receptor cells are hair cells that lie along the entire length of the organ of corti in the cochlear duct.

There are two types of neurons. Type – I neurons are myelinated and are distributed to the inner hair cells and constitute 95%. Type – II neurons are unmyelinated constituting 5% and are distributed to the outer hair cells. The fibres pass from the osseous spiral lamina to the organ of corti via Habanula perforata, at which point they lose myelin sheath. Fibres for the outer hair cells cross the tunnel of corti along the basilar membrane and spiral membrane in three groups between Dieter's cells, and innervate multiple outer hair cells. In contrast each inner hair cell is innervated by multiple type – I fibres, unmyelinated fibers become myelinated in the modiolus. The peripheral processes join the cell body located in the spiral ganglion. From the ganglion cell the bipolar neurons enter the internal auditory meatus to be joined by the fibers of vestibular division of VIII cranial nerve. They transverse internal auditory meatus and enter the posterior cranial fossa, where they immediately enter the brain stem at the cerebellopontine angle.

After entering the brain stem the cochlear fibers divide into two main bundles, one group terminates in the dorsal cochlear nucleus and the other group ends in the ventral cochlear nucleus.

The cell bodies of the second order of neurons relay by two routes, the fibers from ventral cochlear nucleus and perhaps most of the fibers from the dorsal cochlear nucleus without terminating in the superior olivary nucleus continue on directly to the medial geniculate body of the thalamus by passing through the inferior colliculus.

The indirect relay circuit begins on the ventral cochlear nucleus. The axons pass medially in the ventral trapezoid body with some of the fibers terminating in the nucleus of the body where third order neuron arises.

The superior olive is an important relay station in receiving fibres from both the cochlear nuclei and forms the nucleus of the trapezoid body. From the olive fibres reach the inferior colliculus. From the inferior colliculus the fibres eventually terminate in the medial geniculate nucleus of the thalamus which receives auditory impulses from the cortical level.

The cell bodies of the IV order of neurons in the medial geniculate body terminates in the transverse temporal gyri of the cerebral cortex. Tones of the different frequencies have specific reception areas in the auditory cortex.

DEVELOPMENT:

The first pharyngeal pouch grows laterally to form the Eustachian tube and the middle ear. The dorsal part of the first pharyngeal groove is deepened to form the external auditory canal. The endoderm of the pouch and ectoderm of the groove meet at the tympanic membrane where they are separated by mesoderm forming the middle fibrous layer of the tympanic membrane.

APPLIED PHYSIOLOGY:

In man hearing becomes the vital basis for acquisition of speech and language.

Mechanism of hearing can be broadly divided into

- 1) Mechanical conduction of sound.
- 2) Transduction of mechanical energy to electrical impulses (sensory system of cochlea)
- 3) Conduction of electrical impulses to the brain (neural pathways).

Physiology of sound conduction:

A sound signal in the environment is collected by the pinna, passes through external auditory canal and strikes the tympanic membrane. Vibrations of the tympanic membrane are transmitted through the ossicular chain to the cochlea.

Impedance matching mechanism of middle ear:

When air conducted sounds travels to the cochlear fluids, the loss of sound energy that occurs is compensated by impedance matching or transformer action of the middle ear. It is accomplished by

- 1) Ossicular-level chain ratio: It is 1.3:1 between handle of malleus and long process of incus.
- 2) The ratio of area of tympanic membrane and the oval window: The effective area ration is 14:1.
- 3) Phase differential between oval and round window.

INNER EAR:

There are two essential physiological processes in Cochlea namely transmission and transduction. The former accounts for the transfer of acoustic energy from the oval window to the hair cells, while the latter is the process by which this sound energy pattern is converted at the organ of corti into action potentials in the auditory nerve.

Vibrations of the stapes produce a flow of perilymph up the scala vestibuli, through the helicotrema and down the scala tympani to the round window membrane. With vibrations, movement of basilar membrane occurs, which sets up a shearing force between the tectorial membrane and hair cells. Higher frequencies are represented in the basal turn of cochlea and progressively lower ones towards the apex. The distortion of hair cells gives rise to cochlear micro phonics which triggers the nerve impulses. Auditory nerve action potential is the algebraic sum of the neural discharges in the whole of the cochlear nerve. Each nerve fibre has an optimum stimulus frequency for which the threshold is lowest.

Transduction by hair cells:

The individual stereocilia on the apical surface of the hair cell are mechanically rigid, and are faced together with cross links so that they move as a stiff bundle. Therefore, when a bundle is deflected, the different rows of stereocilia could be expected to slide relative to one another. There are fine links running upwards from the tips of the shorter stereocilia on the hair cell, which join the adjacent taller stereocilia of the next row. When the stereocilia are deflected in the direction of the tallest stereocilia, the links are stretched, opening ion channels in the cell membrane.

When the stereocilia are deflected in the opposite direction, the tension is taken off the links and the channels close. This hypothesis is consistent with the present electro-physiological evidence from hair cells.

The stimulus is coupled to the stereocilia by means of the shear of the relative motion between the tectorial membrane and the reticular lamina. As the laminar membrane and the organ of corti are driven upwards and downwards by a sound

stimulus, the stereocilia are moved away from and towards the modiolus. Because the tallest stereocilia are situated on the side of the hair cell farthest away from the modiolus, an upward movement of the basilar membrane is translated in the movement of the stereocilia in the direction of the tallest. The effective direction of the shear between the tectorial membrane and the reticular lamina is therefore radial across the cochlear duct. This is the direction associated with opening of the ion channels. In both inner and outer hair cells the tip links are organized in such a way that they run in a direction most suited for picking up radial shear.

When the channels on the stereocilia are open, ion will enter or leave the cell depending on the electrical and the chemical gradients across the apical cell surface. It appears that the ion channels are rather large and non-selective, so that, for instance, Na^+ , K^+ and Ca^{++} will enter with nearly the same efficacy. Under the generally accepted position, the apical surface of the hair cells is faced by endolymph with a high positive potential ($\pm 80\text{mV}$) and a high K^+ concentration. Inside the cell there is a negative intracellular potential, which is -45mV for inner hair cells and -70mV for outer hair cells. The potential combine to give 125mV (inner hair cells) or 150mV (outer hair cells) of potential drop across the channel, When the channels are open K^+ from the endolymph will tend to be driven into the cell by this big potential gradient, thus making the cell more positive inside. When the channels are completely shut off, the cells will become more negative. Most of the transducer current may be carried by K^+ , as this is the predominant ion in the endolymph. However, it is possible that some of the current is carried by some other ions, such as Ca^{++} . The energy from the whole process comes from the stria vascularis, which by ion pumping, stores energy in the

'battery' of the endolymph. This is the 'battery' or 'resistance modulation' theory of Davis (1965) as it appears in the light of modern evidence.

Neural pathways:

Hair cells get innervation from bipolar cells of spiral ganglion. Central axons of these cells collect to form cochlear nerve which goes to central and dorsal cochlear nuclei. From there, both crossed and uncrossed fibers travel to the superior olivary complex, lateral lemniscus, inferior colliculus and medial geniculate body and finally reach the auditory cortex of the temporal lobe.

THEORIES OF HEARING:

1. Travelling wave theory of Von Bekesy:-

A sound wave depending on its frequency reaches maximum amplitude on a particular place on the basilar membrane and stimulates that segment. If vibrations of the basilar membrane are observed, a travelling wave is seen to start at the base of the cochlea and progress toward the helicotrema with increasing amplitude to a region of maximum displacement, the position of which depends upon the frequency. Higher frequencies are presented in the basal turn of the cochlea and the progressively lower tones towards the apex.

2. Helmholtz's resonance place theory:-

Suggests that the frequency analysis by the ear was due to the fact that each pitch would cause resonant vibration of its own particular place on the basilar membrane. This theory is disproved because basilar membrane cannot act as a resonator.

3. Rutherford's telephone theory:-

This theory suggests that pitch perception is based on the rate of firing of individual nerve fibres.

4. Wever's volley theory:-

This postulates that high frequencies are perceived by place alone in the basal turn, low frequencies (below 1000) stimulate nerve action potentials at a rate equal to the stimulus frequency, while intermediate frequencies are presented in the auditory nerve by asynchronous discharge in groups of neurons whose combined activity represents the frequency of the stimulus.

SENSORY NEURAL HEARING LOSS AND MIDDLE EAR SURGERIES

Exposure to high levels of noise is known to be harmful to the ear. Cochlear injury may be sustained acutely from sudden-impact noise or may develop gradually over time if noise is prolonged over time.

It is certainly accepted that middle ear surgery carries a small risk of sensory neural hearing loss. Apart from inner ear injury resulting from manipulation of the ossicles, drilling itself causes hearing loss in so many ways. Firstly, there may be direct injury to the membranous labyrinth caused by accidental penetration of a semicircular canal. Secondly the burr may come in contact with the ossicles (usually short process of incus) and thirdly the noise due to drilling may be transmitted through the bone resulting in a noise-induced hearing loss.

The short process of incus is most susceptible to trauma from burr. Helms measured the amplitude of the stapes footplate movement when the ossicular chain was drilled with a cutting and a diamond burr. He was able to show that this set the footplate moving at a speed corresponding to a noise of at least 130dB. It was assumed that burr trauma to the ossicular chain was a high risk to the inner ear. Paparella¹¹, in an experiment on cats showed that placing a 4mm cutting burr against the body of incus resulted in injury to the organ of Corti, whereas 0.5 mm cutting burr directly on the long process of incus failed to produce cochlear injury.

Sensory neural hearing loss following middle ear surgery has been shown to occur in 1.2% to 4.5% of patients. It is not known how many of these losses were due to noise trauma to the cochlea. Schuknecht and Tonntorf¹² assumed that the acoustic intensities generated by the burr were at safe levels.

Kylen and Arlinger¹³ calculated the drill induced noise levels in the cochlea from vibration measurements performed on intact skulls and temporal bones of human cadavers. They concluded that the ipsilateral cochlea was exposed to a noise level of 100dB and the contralateral cochlea to 5dB to 10dB lower. They concluded that noise trauma may in fact have been responsible for some of the high-tone sensoryneural hearing losses after Tympanoplasty. It has also been shown on cadavers that size has an influence on the noise levels. The larger cutting burrs produced a louder noise than diamond burrs.

Holmquist , et al.¹⁵ Presented a simple technique for measuring sound intensities during surgery. They stressed that drill-generated noise must be regarded as a risk to the cochlea during ear surgery. They suggested that real sound levels in the air

close to the drill were not appreciably higher than the equivalent noise levels reaching the cochlea through the skull by bone conduction.

Kylen ,et al¹⁴ indicated that drill-induced noise during ear surgery may result in postoperative high-tone sensory neural hearing loss. They supported the view that manipulation of the ossicular chain may result in a predominantly lower-frequency threshold shift.

MATERIALS AND METHODS

1. SOURCE OF DATA

Patients presenting to the outpatient department of ENT in B.L.D.E.A's Shri B. M. Patil Medical College Hospital.

2. METHOD OF COLLECTION OF DATA:

- Details of cases will be recorded including history and clinical examination.
- All patients undergoing middle ear surgeries are subjected to pure tone audiometry pre-operatively and first, seventh and twenty- first days post-operatively.

3. INCLUSION CRITERIA

- All patients undergoing middle ear surgeries in BLDEA's Shri B. M. Patil Medical College Hospital and Research Center, Bijapur.

4. EXCLUSION CRITERIA

- Patients who are undergoing ear surgeries for intracranial complications of middle ear diseases.

5. SAMPLING:

Time period of study: October 2007 to May 2009

Sample size: 65 using statistical formula $n = 4pq/L^2$

Statistical analyses: done using proper statistical tests

- Diagrammatic presentation
- Suitable statistical tests like χ^2 test

METHODS

Patients who presented to BLDEA's Shri.B.M.Patil Medical College Hospital and Research Centre, Bijapur were subjected to the study.

A thorough clinical history was taken for duration of otorrhoea, frequency of otorrhoea, hearing loss, duration and nature of previous treatment.

All cases were subjected to detailed examination which included general physical examination, careful examination of ear, nose and throat. Otoscopic, otomicroscopic examination and tuning fork tests were performed.

All patients undergoing middle ear surgeries are subjected to pure tone audiometry pre-operatively and first, seventh and twenty- first days post-operatively. Hearing assessment done with Elkon EDA 3N3 MULTI audiometer.

The hearing threshold for pure tone audiometer was determined in a sound treated room at frequencies ranging from 125-8000 Hz for air conduction and 250-4000 Hz for bone conduction.



**ELKON PURE TONE
AUDIOMETER**

Interpretation of Audiogram

In this study the degree of sensorineural hearing loss is based on the difference in pure tone averages (in decibels) of bone conduction thresholds at 500, 1000, 2000 Hz between diseased and normal ear.

PURE TONE AUDIOMETRY:

Pure tone audiometry is as much a science as it is an art for ascertaining the hearing acuity (hearing threshold) of a subject for pure tone sounds of various frequencies. The hearing threshold as defined by International Standard Organisation (ISO) is “the lowest sound pressure level, at which under specified conditions, a person gives a predetermined percentage of correct responses on repeated trials”. The result when plotted graphically is called a ‘pure tone audiogram’. The reference intensity level, which is designated ‘0’ dB at each frequency is the mean value of the minimal audible intensity (threshold) of pure tones in a group of healthy, normally hearing, young adults, in accordance with standards set by the (ISO).

Procedure:

The patient is instructed about the procedure in detail. The examiner should be able to observe the subject, but care should be taken to provide no visual clues to the subject, as the examiner operates the audiometer. The head phones are placed over the subject`s ears, so that the center of each transducer is at the ear. Women should remove ear-rings. The subject is instructed that the aim of the test is to establish the quietest sound that he/she can hear at each of the several frequencies. It is helpful to describe the foghorn – like characteristics of a low frequency sound and

the squeaky characteristic of a high frequency sound, so that the subject may anticipate the quality of the sound he is expected to hear.

Tones should be presented for 1 to 3 seconds with the intervals of 1 to 3 seconds between each presentation. It is important to randomize the intervals and to avoid presenting the tones in a rhythmic fashion to facilitate the recognition of true response. The subject responds as soon as he hears the sound, for example by raising the finger or pressing a button, which lights a signal on the audiometer panel, and maintains the response as long as the sound is heard. A method of air conduction threshold assessment by conventional Hughson-Weslake technique slightly modified by Carharts and Jerger is described below.

Technique of air conduction test:

A method of air conduction threshold assessment by conventional Hughson-Weslake technique slightly modified by Carharts and Jerger is described below.

The better ear is tested first. The various frequencies are presented in the following order; 1000, 2000, 4000, 8000, repeated again followed by 500, 250, 125 Hz. For given frequency, the initial presentation should be at an arbitrarily presumed suprathreshold level, to allow easy recognition and identification. If patient hears then the tone is decreased by 10 dB steps until patient stops hearing. Once this stage is reached the tone is raised by 5 dB. If the patient hears this tone, the sound is again decreased by 10 dB. If he does not hear it, the tone is again raised by 5 dB. In this way by several threshold crossings, the exact hearing threshold is obtained when one

gets atleast 3 out of 5 responses correct. Though threshold is defined as ‘the lowest intensity heard on 50 percent of occasions of repeated crossing’, but in clinical practice, this is not usually possible on clinical audiometer where graduations are in 5 dB. The second ear is tested in a similar manner. The faintest audible intensity as established above is recorded against the test frequency on a standard audiogram chart as the threshold intensity. By convention, the symbols ‘o’ and ‘x’ are used for air conduction thresholds for the right and left ears respectively. If the maximum sound intensity of the audiometer at a given frequency cannot be heard, this is indicated by a downward pointing arrow at the level of the maximum output on the appropriate frequency line.

Technique of bone conduction test:

Bone conduction thresholds are obtained in an identical manner to those described for air conduction, but the sound stimulus is produced by a bone vibrator placed on the mastoid process and held firmly, by means of a head band. Care is taken to remove any intervening hair and contact with the cartilaginous external meatus or pinna is also avoided during the test as these structures may carry air conducted sounds. The vibrator should be placed on the mastoid process of the ear with the worse air conduction threshold averaged over the frequency range 250 to 5000 Hz. Measurements are restricted to the frequency range 250 to 4000 Hz and calibration standards do not generally give data for stimuli outside this range. The test is commenced at 1000 Hz, followed by 2000, 4000, 500 and 250 Hz. The subject is instructed to respond to sound regardless of the side on which the sound is actually heard. It must be emphasized that without the use of masking it is not possible to

determine the ear that is responsible for the detection of the 'non-masked' bone conduction threshold.

Bone conduction thresholds cannot be established with such precision as air conduction thresholds, as the threshold of tactile sensation, particularly at low frequencies may be more acute than audition leading to erroneous results. In addition, as the output level of bone vibrations rises so the distortion increases and the threshold measured may relate to second or third harmonics, rather than the fundamental frequency. Care must therefore be taken not to exceed the maximum output level for the particular audiometer in use. At higher frequencies (2000 - 4000), air borne sound radiated by bone vibrator may result in errors. Hence, an essential requirement of bone conduction testing is the exclusion of the non-test ear by an efficient masking sound so that all threshold levels may be reliably attributed to the tested ear. The symbol '>' represents unmasked bone conduction.

Masking:

Masking is the phenomenon by which one sound impairs the perception of another. The most effective sound to mask a pure tone is a narrow band of noise with the central frequency equal to the test tone. In commercially available audiometers the masking band is automatically selected upon selection of the test tone frequency.

Masking is mandatory for:

1. All bone conduction studies, whenever the unmasked bone conduction is 10 dB or more better than the worse air conduction.
2. Air conduction studies.

- a) When the difference in left and right unmasked air conduction threshold is 40 dB or more, and
- b) Whenever the unmasked bone conduction is 40 dB or more better than the worse air conduction.

These requirements for masking may be readily understood considering certain facts regarding the transmission of air and the bone conduction sounds across the head. An air conducted sound is transmitted across the skull with an internal attenuation of the order of 50 dB; while the attenuation for a bone conducted sound is negligible. Hence, in this later condition and apparent threshold level may be a record of the sensitivity of the cochlea not under test.

In practice a masking noise is applied to the ear contralateral to that being tested in order to mask out sounds arriving at the non-test ear. The masking noise employed must be of high masking efficiency, but of minimal loudness to avoid a crossover to the test ear and the phenomenon of central masking (the inputs from the two ears are not neurologically isolated and at high intensity levels a tone or noise presented in one ear can shift the threshold of tone for the same or near frequency in the opposite ear, i.e. 'central masking'). The 'shadowing' technique of determining the true auditory threshold is the most commonly used masking technique.

Hoods plateau method of masking:

Air conduction:

- 1) The unmasked threshold of the ear is ascertained. If it is thought that there is a possibility of cross-hearing, then a masking sound is introduced into the non-test ear at 10 or 15dB above air conduction threshold level of the non-test ear.
- 2) The tone is presented to the test ear (at unmasked threshold). If the patient gets the tone, masking will not be required. But if the patient does not get the tone, it indicates adequate masking will be required to get the actual threshold of the test ear and third step is then started.
- 3) The test tone is raised by 5dB, if patient hears the tone, then next (4th) step is started. If patient does not get the tone, then tone is raised by 5dB steps till the tone is heard, and then the fourth step is started.
- 4) The masking level is raised by 5dB in the non-test ear. Tone is again presented to the test ear to see whether the patient is getting the tone or not. If the patient is still getting the tone, it indicates actual hearing threshold. If patient does not get the tone, it indicates that actual threshold of the test ear has not been reached as yet.
- 5) The test tone is raised by 5dB or in 5dB steps till it is heard. Once the test tone is heard the masking level is raised by 5dB and it is checked whether test tone is still being heard. This process of alternately increasing the masking noise and test tone is continued till a time comes when patient will continue to hear the tone inspite of increasing the masking noise by 2 or 3 steps of 5 dB each. This tone level is the actual hearing threshold level of the test ear.

Bone conduction:

This is similar to air conduction masking.

- 1) Unmasked bone conduction threshold of test ear is ascertained.
- 2) A masking sound is introduced into the non-test ear at a level of 15 dB above air conduction threshold for the non-test ear.
- 3) Tone is given by bone conduction to see whether it is being heard or not. If heard, it indicates that masking threshold is correct. If not heard, then tone and masking sound are increased in 5 dB steps alternately till masking sound level can be increased by 2-3 steps of 5 dB each without requiring any increase in tone sound for the tone sound to be heard. This level of the tone is the actual hearing threshold level of the test ear by bone conduction.

RESULTS

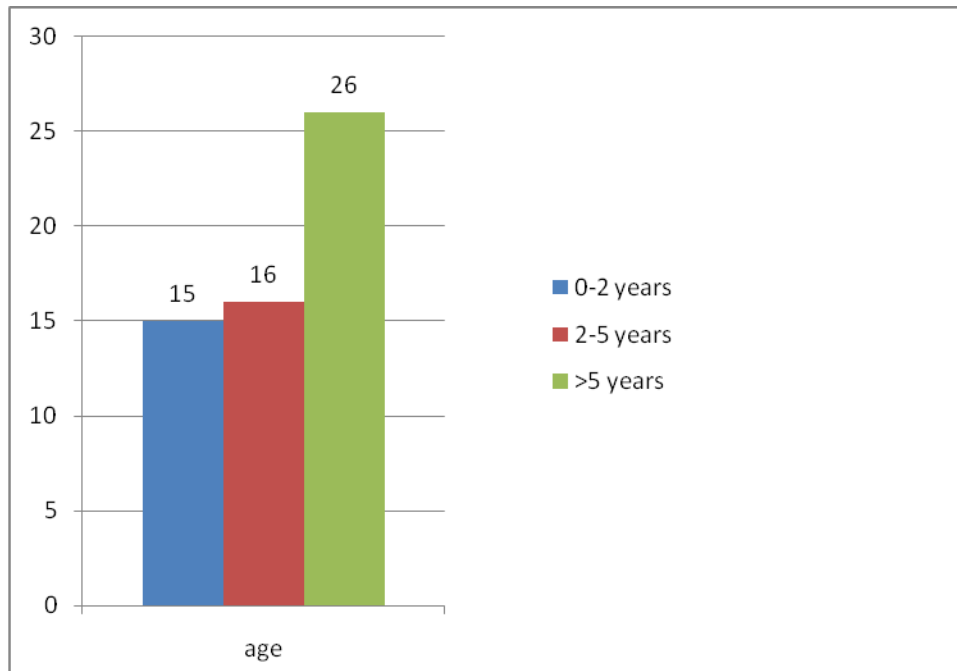
The study was conducted on 60 patients, aged between 15 to 50 years, who underwent ear surgery for csom at sri B.M. Patil Medical college and Research Centre Bijapur, from October 2007 to March 2009. Out of 60 patients, 31 underwent cortical mastoidectomy, 16 modified radical mastoidectomy with Tympanoplasty, 8 modified radical mastoidectomy, 3 stapedectomy. Sensory neural hearing loss was not found in any of the patients following surgery on 1st, 7th and 21st post op day.

Observations of the study are described under the following headings:

TABLE-1:

Duration of symptoms [n=57] (intermittent aural discharge)	
DURATION (years)	NUMBER OF PATIENTS
0-2	15
2-5	16
>5	26

GRAPH - 1



The Paired-Samples T Test procedure is used to test the hypothesis of no difference between two variables. The data may consist of two measurements taken on the same subject or one measurement taken on a matched pair of subjects.

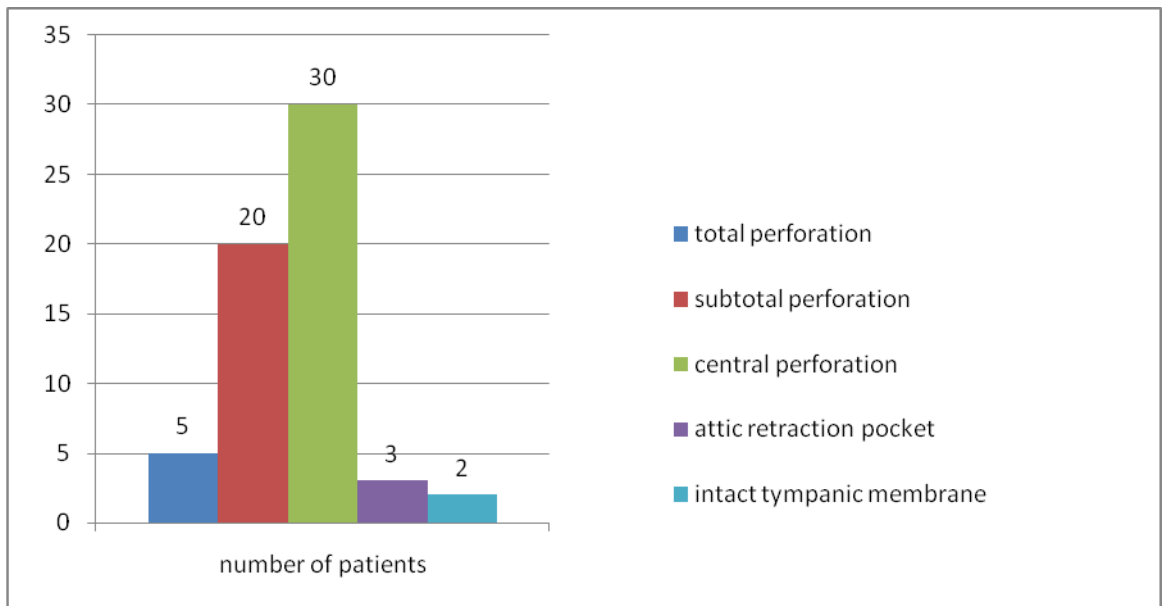
In this study Paired-Samples T Test procedure is used to test the significance difference between the two treatments (pre-post), given on the same patient. Here p value is the probability of t- statistic.

This test shows that there is no correlation between duration of discharge and sensory neural hearing loss.

Table - 2

Appearance of tympanic membrane [n=60]		
TYMPANIC MEMBRANE	NUMBER OF PATIENTS	PERCENTAGE
Total perforation	5	8.3%
Subtotal perforation	20	33.3%
Central perforation	30	50%
Attic retraction pocket	3	5%
Intact tympanic membrane	2	3.4%

GRAPH-2

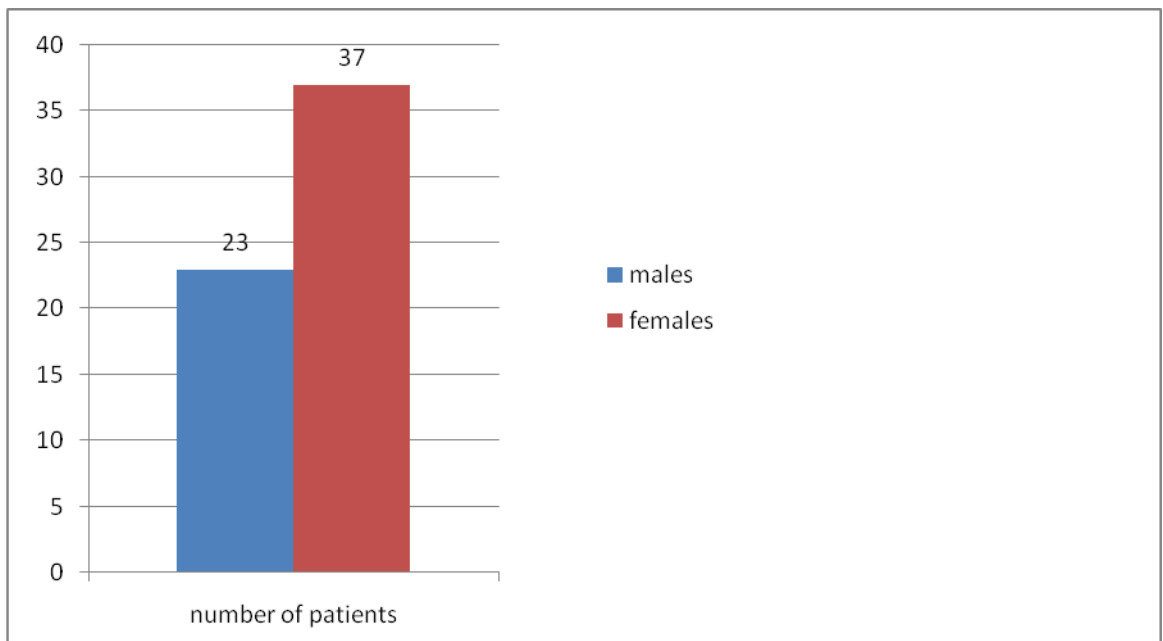


Out of 60 patients , 30 had central perforation, 20 had subtotal,3 had attic retraction pocket, 5 had total perforation and 2 with intact membrane

Table - 3

Sex distribution		
SEX	NUMBER OF PATIENTS	PERCENTAGE
Males	23	38.33%
Females	37	61.67%

Graph – 3



Out of 60 patients ,37 were females(61.67%) and 23 males(38.33%).

Pie Chart

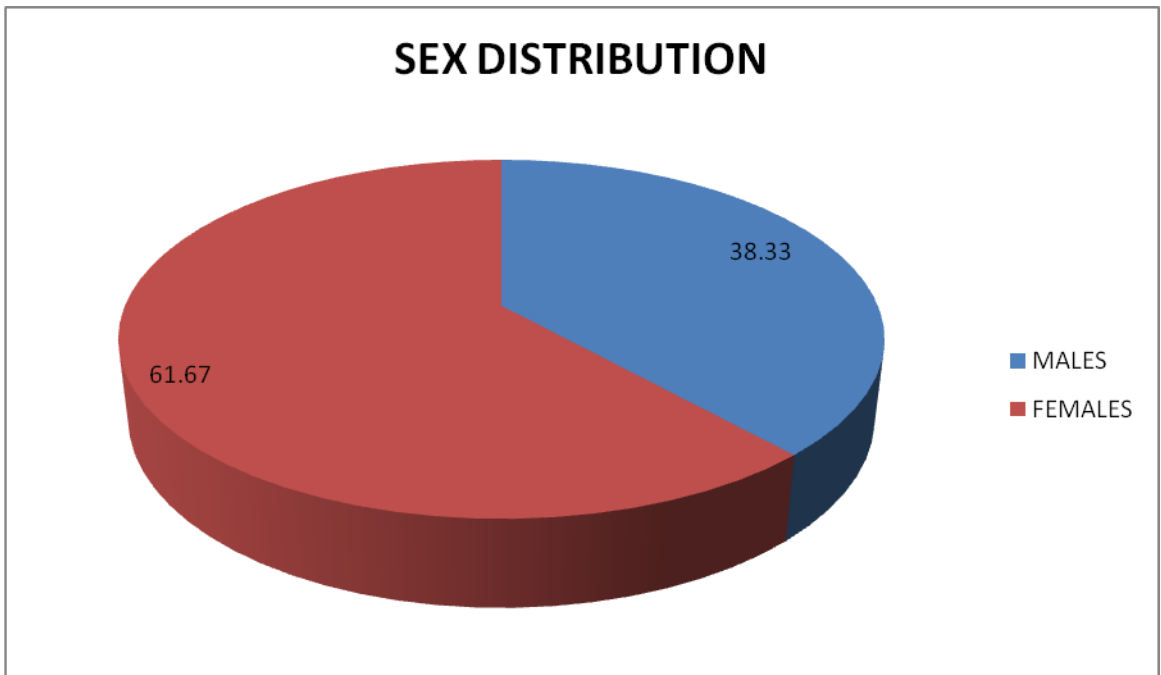
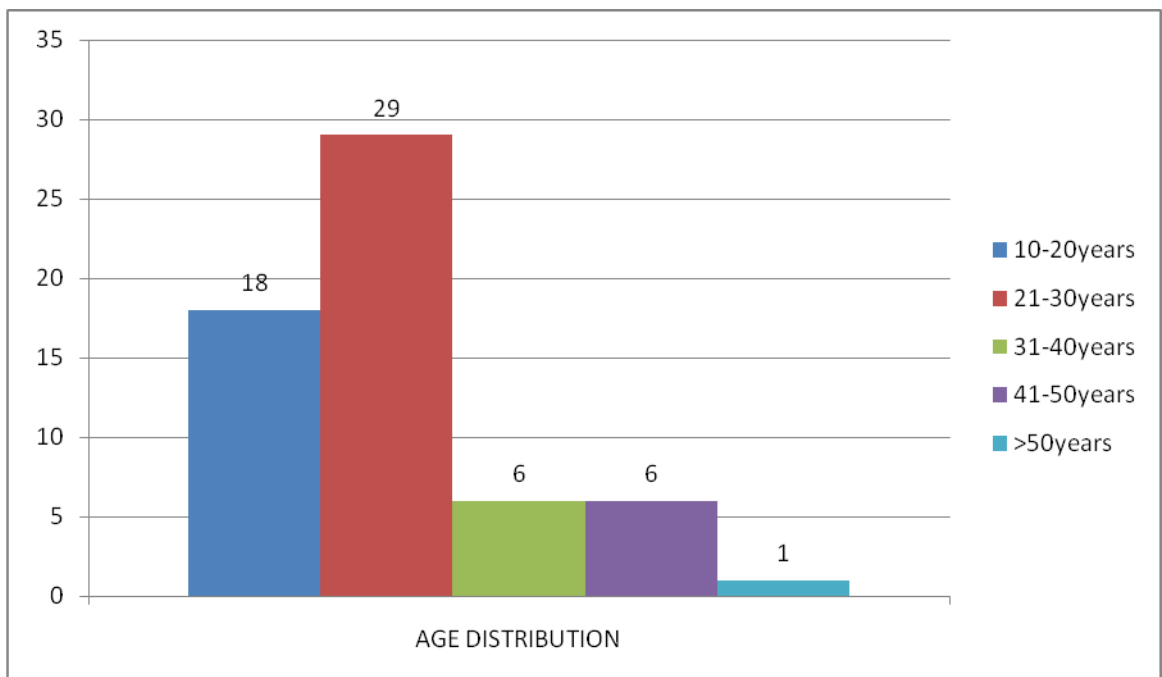


Table – 4

AGE DISTRIBUTION		
Age (in years)	No of patients	Percentage
10-20	18	30%
21-30	29	48.33%
31-40	6	10%
41-50	6	10%
>50	1	1.67%

Graph – 4



AGE DISTRIBUTION

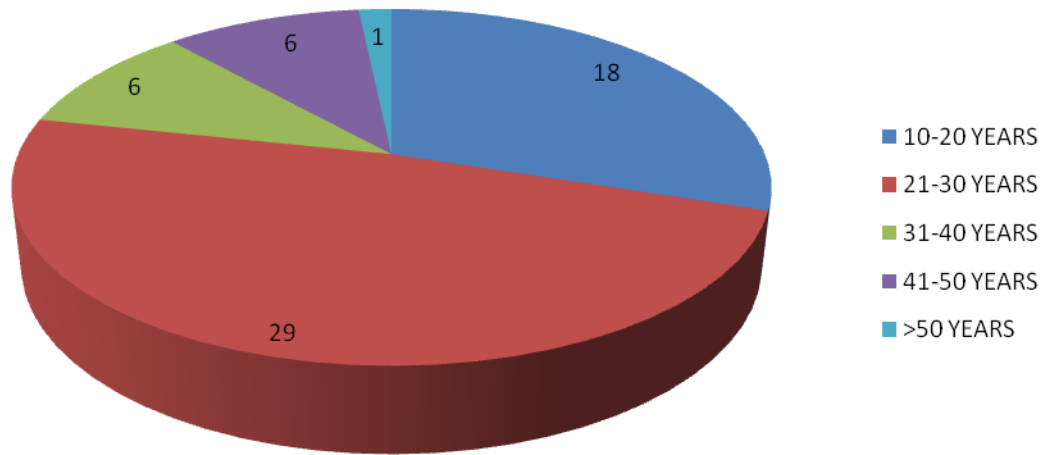
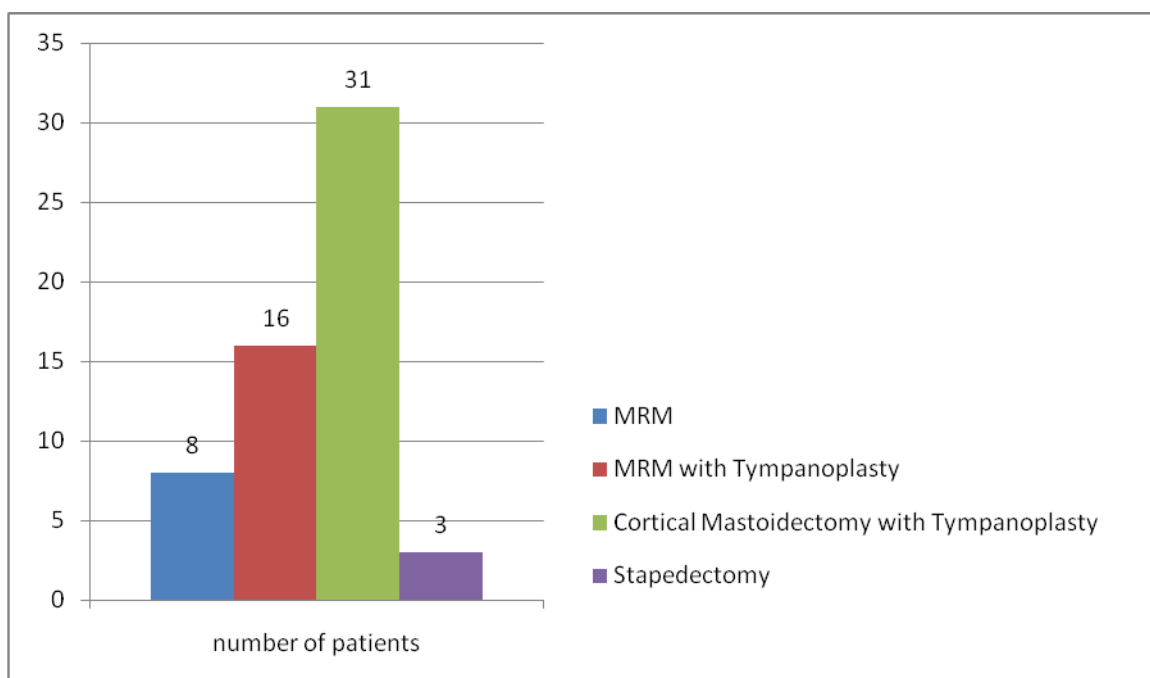


Table – 5

Surgical procedures performed [n=60]			
SURGICAL PROCEDURE	NUMBER OF PATIENTS	PERCENTAGE	p- value
Modified radical mastoidectomy	10	16.66%	0.598
MRM with Tympanoplasty	16	26.67%	0.111
Cortical mastoidectomy with Tympanoplasty	31	51.67%	0.572
Stapedectomy	3	5%	0.175

Graph – 5



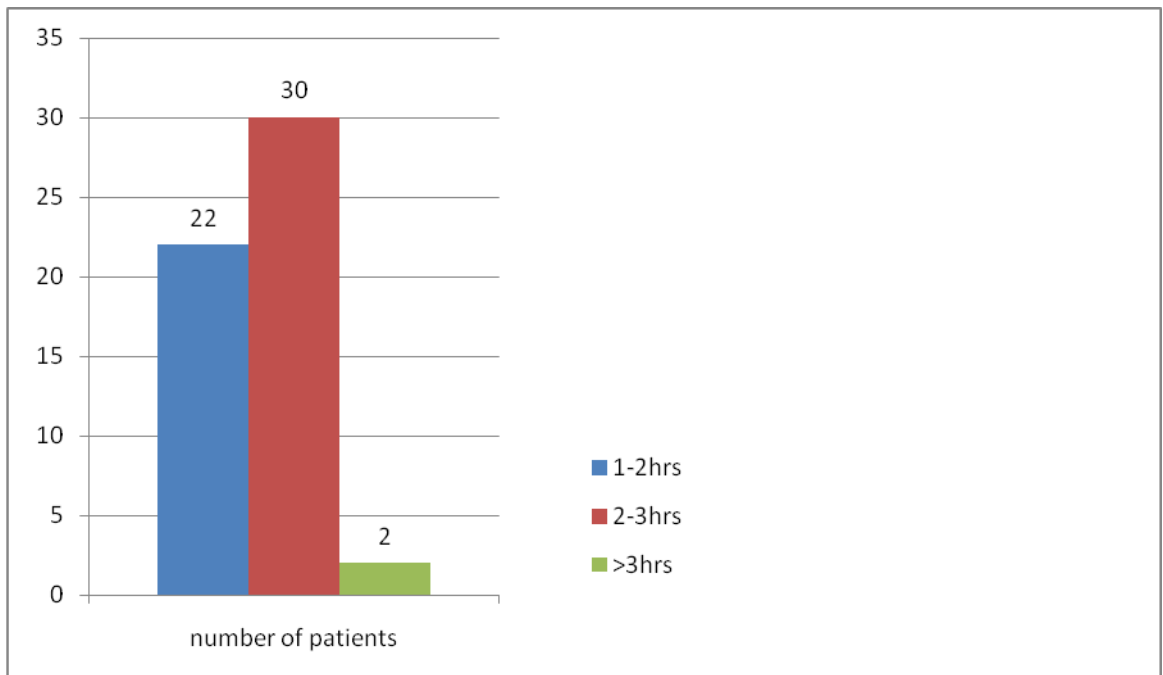
One of the most common experimental designs is the "pre-post" design. A study of this type often consists of two measurements taken on the same subject, one before and one after the introduction of a treatment or a stimulus. The basic idea is simple. If the treatment had no effect, the average difference between the measurements is equal to 0 and the null hypothesis holds. On the other hand, if the treatment did have an effect (intended or unintended!), the average difference is not 0 and the null hypothesis is rejected.

As the p-value is more than 0.05 there is no significant correlation between type of surgery and sensoryneural hearing loss.

Table - 6

Duration of surgery [n=60]		
DURATION (hours)	NUMBER OF PATIENTS	p-value
1-2	22	0.059
2-3	30	0.073
>3	8	0.598

Graph – 6



The Paired-Samples T Test procedure is used to test the hypothesis of no difference between two variables. The data may consist of two measurements taken on the same subject or one measurement taken on a matched pair of subjects. This test shows that there is no significant correlation between duration of surgery and sensoryneural hearing loss.

Table - 7

Frequency (kHz)	Pre op		Postop BCA 1 st Day			Postop BCA 7thDay			Postop BCA 21 st Day		
	Mean	SEM	Mean	SEM	p- value	Mean	SEM	p- value	Mean	SEM	p-value
0.25	8.17	0.788	8.67	0.805	0.484	8.92	0.714	0.140	8.58	0.771	0.374
0.5	11.83	0.732	11.75	0.681	0.885	12.17	0.818	0.560	12.00	0.817	0.766
1	12.50	0.916	12.75	0.844	0.689	12.83	0.826	0.551	12.92	0.892	0.374
2	13.17	0.788	13.00	0.834	0.784	13.42	0.861	0.616	13.50	0.843	0.497
4	11.58	1.073	11.83	0.769	0.732	11.75	0.964	0.716	11.83	0.936	0.665

Result obtained by using paired t test

The Paired-Samples T Test procedure is used to test the hypothesis of no difference between two variables. The data may consist of two measurements taken on the same subject or one measurement taken on a matched pair of subjects.

In this study Paired-Samples T Test procedure is used to test the significance difference between the two treatments (pre-post), given on the same patient. Here p value is the probability of t- statistic. If p –value is < 0.05 then reject the hypothesis otherwise accept the hypothesis that there is no significant difference between the two treatment means. Standard Error of mean is the index of variability. It indicates how well the mean of a sample estimates the mean of a population. It is defined as Standard deviation / \sqrt{n} , where n is the sample size.

$$SEM=SD/\sqrt{n}$$

DISCUSSION

It is known that noise of significant intensity and duration may be harmful to the ear. Ear surgery itself is associated with small incidence of SNHL, but it is not known how much of this is due to noise trauma itself.

In a study by Hagewald, et al²¹, 25 patients undergoing mastoidectomy were tested for SNHL within 48hrs and at 30hrs post-operatively. Our study was done on 60 patients and no sensory neural hearing loss was noted on first, seventh and twenty-first post-op days.

Tos, et al¹⁷, reported that in 50 patients of acoustic neuroma who underwent translabyrinthine tumour removal, no sensory neural hearing loss was noted. The patients underwent audiometric tests pre-operatively and at 30 post-op day. Our study included MRM, cortical mastoidectomies and no sensory neural hearing loss was noted following these surgeries.

Palva and Sorri¹⁸, reported that they found SNHL on the contralateral side during first week post-operatively and concluded that it increased with increased duration of surgery. Our study did not show any statistically significant correlation between pre-op and post-op bone conduction thresholds, factors such as duration of surgery did not appear to influence the final outcome.

Urquhart, et al³, reported that there was no correlation between duration of ear discharge and post op bone conduction level. Our study also showed the same results. Although it is well known that chronic suppurative otitis media cause SNHL, our study group had ear problems since early childhood.

Schick, et al¹, studied the temporary threshold shift after ear surgery in 393 patients. They concluded that temporary threshold shift can be observed at 2000hz and 4000hz after ear surgery. Use of drill and preparation at the ossicular chain usually results in no significant sensory hearing deficit. Our study did not show any temporary or permanent shift.

W.A McIntosh, et al³, concluded that sensory neural hearing loss after mastoid surgery is not due to noise generated by the drill. In the event of any hearing loss during this period, other causes should be sought.

Kylen and Arlinger¹³, calculated the drill induced noise levels in the cochlea from vibration measurements performed on intact skulls and temporal bones of human cadavers. They concluded that the ipsilateral cochlea was exposed to a noise level of 100dB and the contralateral cochlea to 5dB to 10dB lower. They concluded that noise trauma may in fact have been responsible for some of the high-tone sensoryneural hearing losses after Tympanoplasty. It has also been shown on cadavers that size of the burr has an influence on the noise levels. The larger cutting burrs produced a louder noise than diamond burrs. Our study did not include any comparison between the noise levels produced by large burrs and diamond burrs.

Holmquist, et al¹⁵, presented a simple technique for measuring sound intensities during surgery. They stressed that drill-generated noise must be regarded as a risk to the cochlea during ear surgery. They suggested that real sound levels in the air close to the drill were not appreciably higher than the equivalent noise levels reaching the cochlea through the skull by bone conduction.

CONCLUSION

1. There was no variation between pre operative and post operative bone conduction levels.
Therefore middle ear surgeries have not resulted in any SNHL.
2. Duration of ear discharge, duration of surgery, type of surgery had no bearing on post operative sensory neural hearing levels.

KNOWN ISSUES:

- I. The project does not recognise the long term effects of middle ear surgeries on cochlear function.
- II. The exact amount of noise generated by drilling machine was not recorded. However, as there is no SNHL in our case, it is safe to assume that the noise produced by these machines is safer on the inner ear.

SUMMARY

This cross sectional study was performed on 60 patients aged between 10 to 65 years attending BLDEA's Shri B. M. Patil Medical College, Hospital and Research Centre, Bijapur from October 2007 - May 2009.

All patients were subjected to thorough history taking and examination to exclude those patients who are undergoing ear surgeries for intracranial complications.

All patients were subjected to pure tone audiometry for assessment of hearing threshold before and after ear surgeries.

Out of 60 patients, 31 underwent cortical mastoidectomy, 16 modified radical mastoidectomy with Tympanoplasty, 8 modified radical mastoidectomy, 3 stapedectomy. SNHL was not found in any of the patients following surgery on 1st, 7th and 21st post op day.

BIBLIOGRAPHY:

1. Schick B, Schick BT, Kochannek S, Starlinger V, Iro H. Temporary sensory hearing deficits after ear surgery—a retrospective analysis. *Laryngorhinootologie* 2007 Mar; 86(3): 200-5
2. Valter C, Baier G, Schan F, Maller J, Helms J. Inner ear depression after middle ear interventions. *Laryngorhinootologie* 2007 May; 79(5): 260-5
3. Urquhart AC, McIntosh WA, Bodenstern NP. *Laryngoscope* 1992 Jun; 102(6): 689-92
4. Domanec J, Carulla M, Traserra J. *Arch Otorhinolaryngol*. 1989; 246(5): 280-2
5. Hattenbrink KB. *Laryngorhinootologie* 1991 Feb; 70(2): 66-71.
6. Lukowski M, Bia A, Aczewski L. *Otolaryngol Pol* 1994; 48(3): 282-7.
7. Palva T, Karja J and Palva A. High-Tone Sensorineural Losses Following Chronic Ear Surgery. *Arch otolaryngol Head Neck Surg* 1973; 98:176-8.
8. Smyth GDL. Sensoryneural Hearing Loss in Chronic Ear Surgery. *Ann Otol Rhinol Laryngol* 1977; 86:1-6.
9. Tos M, Lau T and Plate S. Sensoryneural Hearing Loss Following Chronic Ear Surgery. *Ann Otol Rhinol Laryngol* 1984; 93:403-9.
10. Helms J. Acoustic Trauma from the Bone Cutting Burr. *J Laryngol Otol* 1976; 90:1143-49.
11. Paparella MM Acoustic Trauma From the Bone Cutting Burr. *Laryngoscope* 1962; 72:116-26.
12. Schuknecht HF and Tonndorf J. Acoustic Trauma of the Cochlear From Ear Surgery. *Laryngoscope* 1960; 70:479-505.

13. Kylen P and Arlinger S Drill Generated Noise Levels In Ear Surgery. *Acta Otolaryngol* 1976; 82:402-9.
14. Kylen P, Stjernvall J-E and Arlinger S. Variables Affecting The Drill Generated Noise Levels In Ear Surgery. *Acta Otolaryngol* 1977; 84:252-9.
15. Holmquist J, Oleander R and Hallen O. Perioperative Drill Generated Noise Levels in Ear Surgery. *Acta Otolaryngol* 1979; 87:458-60.
16. Spencer M.G and Reid A. Drill Generated Noise levels In Mastoid Surgery. *J Laryngol Otol* 1985; 99:967-72.
17. Tos M, Trojaborg N and Thomsen J. The Contralateral Ear After Translabyrinthine Removal Of Acoustic Neuromas: Is There a Drill Noise Generated Hearing Loss? *J Laryngol Otol* 1989; 103:845-49.
18. Palva A and Sorri M. Can an Operation On a Deaf Ear Be Dangerous For Hearing? *Acta Otolaryngol Suppl* 1979;360:155-57.
19. Hornung S and Ostfeld E. Bone Conduction Evaluation Related To Mastoid Surgery. *Laryngoscope* 1984; 94:547-49.
20. Kylen P, Arlinger S.D. and Bergholtz L.M. Perioperative Temporary Threshold Shift In Ear Surgery. *Acta Otolaryngol* 1977; 84:393-401.
21. Hegwald M, Hetman R, Weiderhold M.L, et al. High-Frequency Electrostimulation Hearing After Mastoidectomy. *Otolaryngol Head Neck Surg* 1989; 100:49-56.
22. Soudijn E.R. Otologic Drills- A Possible Acoustic Danger. *Ann Otol Rhinol Laryngol* 1976; 85:43-6.
23. Parkin JL, Wood GS, Wood RD, and Mccandless GA. Drill and suction-generated noise in mastoid surgery. *Archives of Otolaryngology* 1980; 106: 92-6.

24. Paulsen K, and Vietor K. Körperschallmessungen beim Bohren und Schleifen am isolierten, frischen Felsenbein. Archives of Otorhinolaryngology 1975; 209: 159.
25. Spencer MG. Suction tube noise and myringotomy. The Journal of Laryngology and Otology 1980; 94: 383-6.
26. Dommerby H. and Tos M. Sensorineural hearing loss in post-traumatic incus dislocation. Archives of Otolaryngology 1983; 109: 257-61.
27. Koefoed-Nielsen B. and Tos M. Post-traumatic sensorineural hearing loss. A prospective long-term study. ORL 1982; 44: 206-15.
28. Massena-Lacerda S. and Bebea JP. Etudes des variations de la conduction osseuse apres tympanoplastie par la vote transmastoidienne. Revue Laryngologie, Otologie, Rhinologie 1970; 91: 517-25.
29. Miller JD. Effects of noise on people. Journal of Acoustic Society of America 1974; 56: 729-64.
30. Paulsen K. and Vietor K. Lautstarkemessungen fur Luftschall beim Bohren und Schleifen am isolierten frischen Felsenbein. Laryngologie und Rhinologie 1975; 54: 824-34.
31. Soudijn ER. Scanning electron microscopic study of the organ of Corti in normal and sound-damaged guinea pigs. Annals of Otology, Rhinology and Laryngology, Supplement 1976; 29:1-58.
32. Tos M. and Thomsen J. Ten years experience with translabyrinthine acoustic neuroma surgery in Denmark. Ada Otolaryngologica, Supplement 1988; 449: 23-24.

33. Tos M. and Thomsen J. Sequelae after translabyrinthine removal of 400 acoustic neuromas. In Fisch U (Ed): Proceedings of the 6th international symposium on neurological surgery of the ear and skull base. Kugler, Amsterdam.
34. Khurana AS, Verma SK, Singh S. Incidence of sensoryneural hearing loss following ear surgeries. IJO and HNS 1986; 48: 130.
35. Scott AM, Bauch CD, and Olsen WO. Head trauma and mid frequency hearing loss. American journal of Audiology 1999; 8:101-5.
36. Migirov L, Wolf M. Influence of Drilling on the Distortion Product Otoacoustic Emissions in the Non-Operated Ear. Journal of Otolaryngology and head and neck surgery 2009; 71:153-6.

PROFROMA

SCHEME OF CASE TAKING:

1) Name: CASE NO:

2) Age: IP NO:

3) Sex: DOA:

4) Religion: DOS:

5) Occupation: DOD:

6) Residence:

7) Chief complaints

8) History of presenting illness

9) Past History:

1. Diabetes mellitus
2. Hypertension
3. History of any drug intake

10) General Physical Examination

Pallor	present/absent
Icterus	present/absent
Clubbing	present/absent
Generalized Lymphadenopathy	present/absent
Build	Poor/Middle /Well
Nourishment	Poor / Middle / Well

11) Vital signs

PR:	Temp:
BP:	Weight:
RR:	

12) Other Systemic Examination:

- i. Respiratory System
- ii. Cardiovascular System
- iii. Central Nervous System

13) Local examination

Ear:

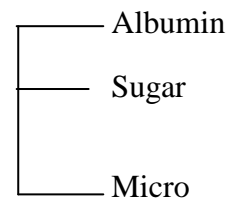
Nose:

Throat:

14) Investigation:

Blood: Hb

Urine:



TC

DC

ESR

BT

CT

BLOOD UREA

SERUM CREATININE

RBS

15) Pure tone audiometry

16) Final Diagnosis:

17) Inference:

18) Comments:

ANNEXURE

**SAMPLE INFORMED CONSENT FROM BLDEA'S SHRI B. M. PATIL
MEDICAL COLLEGE HOSPITAL AND RESEARCH CENTER, BIJAPUR-
586103**

**TITLE OF THE PROJECT - PROSPECTIVE STUDY TO ASSESS
SENSORY NEURAL HEARING LOSS
FOLLOWING MIDDLE EAR
SURGERIES**

PRINCIPAL INVESTIGATOR - DR. TEJASWINI PATEL

**GUIDE - DR. N. H. KULKARNI
PROF AND HEAD OF THE
DEPARTMENT OF
OTORHINOLARYNGOLOGY**

PURPOSE OF RESEARCH:

I have been informed that this is a study to assess sensory neural hearing loss following ear surgeries. I have also been given a free choice of participation in this study.

PROCEDURE:

I am aware that in addition to routine care received I will be asked series of questions by the investigator. I have been asked to undergo the necessary investigations and treatment, which will help the investigator in this study.

RISK AND DISCOMFORTS:

I understand that I may experience some pain and discomfort during the examination or during my treatment. This is mainly the result of my condition and the procedure of this study is not expected to exaggerate these feelings that are associated with the usual course of treatment.

BENEFITS:

I understand that my participation in this study will help to assess sensory neural hearing loss following middle ear surgeries.

CONFIDENTIALITY:

I understand that the medical information produced by this study will become a part of Hospital records and will be subject to the confidentiality and privacy regulation. Information of a sensitive personal nature will not be a part of the medical records, but will be stored in the investigator's research file and identified

only by a code number. The code-key connecting name to numbers will be kept in a separate location.

If the data are used for publication in the medical literature or for teaching purpose, no name will be used and other identifiers such as photographs and audio or videotapes will be used only with my special written permission. I understand that I may see the photographs and videotapes and hear the audiotapes before giving this permission.

REQUEST FOR MORE INFORMATION:

I understand that I may ask more questions about the study at anytime. Dr. Tejaswini Patel is available to answer my questions or concerns. I understand that I will be informed of any significant new findings discovered during the course of the study, which might influence my continued participation.

If during the study, or later, I wish to discuss my participation in or concerns regarding this study with a person not directly involved, I am aware that the social worker of the hospital is available to talk with me. A copy of this consent form will be given to me to keep for careful reading.

REFUSAL FOR WITHDRAWAL OF PARTICIPATION:

I understand that my participation is voluntary and that I may refuse to participate or may withdraw consent and discontinue participation in the study at any time without prejudice to my present or future care at this hospital. I also understand that Dr. Tejaswini Patel may terminate my participation in the study after she has explained the reasons for doing so and has helped arrange for my continued care by my own physician or physical therapist, if this is appropriate.

INJURY STATEMENT:

I understand that in the unlikely event of injury to me resulting directly from my participation in this study, if such injury were reported promptly, the appropriate treatment would be available to me, but no further compensation would be provided. I understand that by my agreement to participate in this study I am not waiving any of my legal rights.

I have explained to _____ the purpose of the research, the procedures required and the possible risks and benefits to the best of my ability in patient's own language.

Dr. Tejaswini Patel
(Investigator)

Date

STUDY SUBJECT CONSENT STATEMENT:

I confirm that Dr. Tejaswini Patel has explained to me the purpose of research, the study procedures that I will undergo, and the possible risks and discomforts as well as benefits that I may experience in my own language. I have read and I understand this consent form. Therefore, I agree to give consent to participate as a subject in this research project.

Participant / Guardian

Date

Witness to signature

Date

MASTER CHART

Sl. No	Name	Age	Sex	Date	IP/OP No	Diagnosis	treatment	Bone Conduction Threshold Preoperative					Bone Conduction Threshold Post op 1st day					Bone Conduction Threshold Post op 7th day					Bone Conduction Threshold Post op 21st day					SN HL							
								0.25K Hz	0.5K Hz	1KH z	2KHz	4KH z	0.25 KHz	0.5K Hz	1KHz	2KHz	4KH z	0.25 KHz	0.5KH z	1KHz	2KH z	4KH z	0.25 KHz	0.5 KHz	1KH z	2KH z	4KHz								
								1	Kumar	20	M	04/10/07	14	Rt CSOM	Rt CM+ Type 3 tympanoplasty	5	5	10	15	10	5	5	10	10	10	10	10		10	10	10	10	10	10	10
2	Raju	28	M	15/10/07	615	Rt CSOM	Rt CM+ type 1 tympanoplasty	20	15	10	15	20	15	15	15	20	20	20	20	20	20	15	20	15	20	15	20	15	15	20	25	25	25	-	
3	Gururaj	20	M	21/10/07	856	Rt CSOM	Rt MRM+ type 3 tympanoplasty	-10	10	-10	5	0	0	10	0	10	5	0	15	0	10	5	-5	15	-5	10	5	5	10	5	5	-			
4	Basamma	18	F	30/10/07	13406	Lt CSOM	Lt MRM + type 4 tympanoplasty	20	20	15	20	20	20	15	15	20	20	20	20	20	25	20	20	20	20	20	20	15	20	20	15	20	-		
5	Shivakumar	22	M	20/11/07	124625	Rt CSOM	Rt CM+ type 1 tympanoplasty	5	5	-5	-5	-15	5	10	0	0	-10	10	10	0	0	-10	10	10	0	0	-10	10	0	0	-10	-			
6	Mahadevi	45	F	25/11/07	411	Lt CSOM	Lt CM+ type 1 tympanoplasty	0	5	15	15	10	0	5	15	15	10	5	10	15	15	15	0	10	20	20	15	20	15	20	15	-			
7	Sangeetha	22	F	07/12/07	19469	Lt CSOM	Lt CM+ type 1 tympanoplasty	5	15	15	10	5	10	15	15	15	5	10	15	15	10	5	5	15	15	10	5	5	15	15	10	5	-		
8	Pundalik	17	M	19/12/07	478	Rt CSOM	MRM	15	20	15	10	10	20	20	15	15	15	15	15	20	20	15	15	15	20	20	15	15	15	15	15	-			
9	Vijayalakshmi	14	F	25/12/07	22804	Rt CSOM	Rt CM+ type 1 tympanoplasty	0	5	10	10	15	10	10	15	15	20	5	5	10	15	20	5	10	15	15	15	15	15	15	15	-			
10	Neelawwa	25	F	02/01/08	23338	Ots	stapedectomy	20	20	25	20	15	15	20	25	20	15	20	25	25	20	15	15	25	25	20	20	20	20	20	-				
11	Shashikala	40	F	13/01/08	2360	Lt CSOM	MRM + ossicular reconstruction	15	25	25	15	10	20	25	20	15	15	20	25	25	20	15	15	25	25	15	15	15	15	15	-				
12	Kallamma	18	F	16/01/08	585	Lt CSOM	MRM + type 3 tympanoplasty	10	15	10	15	10	20	20	15	20	15	15	20	15	20	15	15	20	15	20	15	20	15	-					
13	Suresh	32	M	24/01/08	2723	Rt CSOM	MRM + type 4 tympanoplasty	10	10	20	15	10	10	15	20	15	15	15	15	20	15	15	15	10	20	15	10	15	10	-					
14	Putalabai	22	F	19/02/08	781	Lt CSOM	MRM + type 1 tympanoplasty	0	5	5	0	-5	5	10	5	5	0	5	5	5	0	-5	0	10	10	5	0	0	-						
15	Ashok	28	M	28/02/08	28303	Lt CSOM	Lt CM + type 1 tympanoplasty	15	10	15	15	15	15	15	20	15	15	20	15	15	15	20	15	10	15	15	15	15	15	-					
16	Vidhya	34	F	09/03/08	865	Rt CSOM	Rt MRM+ type 2 tympanoplasty	5	15	10	10	0	5	15	10	15	5	10	15	10	10	5	10	15	15	15	5	5	-						
17	Kashinath	20	M	23/03/08	36620	Lt CSOM	Lt MRM	0	5	10	5	5	10	10	15	5	20	10	10	10	10	10	5	10	15	5	10	15	10	-					
18	Mahadevi	28	F	15/04/08	38575	Lt CSOM	Lt MRM	0	5	0	10	5	5	10	10	15	10	5	10	5	15	10	5	10	5	15	10	10	-						
19	Iramma	20	F	27/04/08	6138	Lt CSOM	Lt CM+ type 1 tympanoplasty	5	10	15	20	20	15	10	15	20	20	5	10	15	20	20	5	10	15	20	20	20	-						
20	Kusuma	67	F	31-04-08	40033	Lt CSOM	Lt CM+ type 1 tympanoplasty	-5	0	-5	10	15	0	5	0	15	15	0	0	5	10	15	0	5	0	10	15	15	-						
21	Sharada	25	F	02/05/08	40580	Rt CSOM	Rt CM+ type 1 tympanoplasty	-5	10	15	10	5	0	15	20	15	10	0	10	15	10	10	0	15	20	15	10	15	10	-					
22	Mallayya	10	M	16/05/08	15277	Rt CSOM	Rt MRM	0	15	15	15	0	5	15	25	20	10	10	20	20	20	10	10	20	20	25	10	-							
23	Vivekanand	17	M	20/05/08	4398	Ots	stapedectomy	0	5	10	20	10	5	5	10	20	10	0	5	10	20	10	0	5	10	20	10	-							
24	Bhagyashree	17	F	01/06/08	45379	Lt CSOM	Lt CM+ type 1 tympanoplasty	0	5	5	15	10	5	5	5	15	10	0	5	5	15	10	0	5	5	15	10	-							
25	Suresh	24	M	18/06/08	1220	Rt CSOM	Rt MRM + type 1 tympanoplasty	10	10	20	15	10	20	10	20	15	15	15	15	20	15	15	10	10	20	15	15	15	-						
26	Girish	25	M	28/06/08	51436	Lt CSOM	Lt CM+ type 1 tympanoplasty	5	10	20	15	20	10	10	20	15	20	5	10	20	15	20	5	10	20	15	20	15	20	-					
27	Prakash	27	M	04/07/08	52608	Rt CSOM	Rt MRM + type 1 tympanoplasty	5	5	5	15	10	10	10	10	20	15	10	10	5	15	15	10	10	10	10	15	15	-						
28	Shivamma	22	F	17/07/08	53218	Rt CSOM	Rt CM+ type 1 tympanoplasty	0	5	10	5	15	5	5	10	5	15	0	5	10	5	15	0	5	10	5	15	5	0	-					
29	Jayashree	28	F	22/07/08	56589	Lt CSOM	Lt CM+ type 1 tympanoplasty	10	15	15	5	0	15	15	15	5	0	10	15	15	5	0	10	15	15	15	5	0	-						
30	Sharanappa	11	M	27/07/08	57644	Rt CSOM	Rt CM+ type 1 tympanoplasty	0	5	10	20	10	5	5	10	20	10	0	5	10	20	10	0	5	10	20	10	-							
31	Shantawwa	45	F	01/08/08	59006	Rt CSOM	Rt CM+ type 1 tympanoplasty	20	15	10	15	15	25	20	15	20	20	25	20	15	20	20	25	20	15	20	20	-							
32	Siddappa	42	M	20/08/08	57606	Rt CSOM	Rt MRM	5	10	20	15	5	15	15	25	20	10	10	15	20	15	5	5	10	25	20	15	-							
33	Ningamma	25	F	30/08/08	6278	Ots	Stapedectomy	10	10	10	5	5	10	10	10	5	5	10	10	10	5	5	10	10	10	5	5	-							
34	Mahadevi	20	F	03/09/08	7577	Rt CSOM	Rt CM+ type 1 tympanoplasty	10	25	20	15	10	15	30	25	20	15	15	25	25	20	15	15	25	25	20	15	-							
35	Mehboobi	24	F	17/09/08	6428	Rt CSOM	Rt CM+ type 1 tympanoplasty	5	0	0	5	10	10	0	0	5	10	5	0	0	5	10	5	0	0	5	10	-							
36	Anand	11	M	03/10/08	1409	Rt CSOM	Rt MRM + type 4 tympanoplasty	0	5	5	10	15	5	10	10	15	20	5	10	10	15	20	5	10	10	15	20	-							
37	Shanta	38	F	25/10/08	7940	Lt CSOM	Lt CM+ type 1 tympanoplasty	5	15	15	10	20	10	15	15	10	20	5	15	15	10	20	5	15	15	10	20	-							

MASTER CHART

Sl. No	Name	Age	Sex	Date	IP/OP No	Diagnosis	treatment	Bone Conduction Threshold Preoperative					Bone Conduction Threshold Post op 1st day					Bone Conduction Threshold Post op 7th day					Bone Conduction Threshold Post op 21st day					SN HL
								0.25K	0.5K	1KH		4KH	0.25	0.5K			4KH	0.25	0.5KH		2KH	4KH	0.25	0.5	1KH	2KH		
38	Anitha	28	F	04/11/08	62516	Rt CSOM	Rt CM+ type 1 tympanoplasty	10	15	15	20	15	10	20	20	25	20	15	20	20	25	20	15	20	20	25	20	-
39	Hanumanthappa	50	M	16/11/08	1882	Rt CSOM	Rt MRM + type 3 tympanoplasty	0	5	5	0	-5	10	10	10	5	0	5	10	10	5	0	5	10	10	5	0	-
40	Rajashree	15	F	29/11/08	76154	Rt CSOM	Rt MRM + type 3 tympanoplasty	5	5	10	15	20	15	15	15	20	20	10	10	15	20	20	10	10	15	20	25	-
41	Sangeetha	21	F	18/12/08	78444	Lt CSOM	Lt CM+ type 1 tympanoplasty	15	5	20	0	0	20	5	20	5	5	15	5	20	0	5	15	10	20	5	5	-
42	Bhimangouda	40	M	27/12/08	1968	Rt CSOM	Rt MRM + type 2 tympanoplasty	10	15	15	20	5	15	20	20	25	10	15	20	20	25	10	15	20	20	25	10	-
43	Mallikarjun	36	M	15/01/09	72984	Lt CSOM	Lt MRM + type 4 tympanoplasty	10	15	5	0	0	10	20	10	5	5	15	20	10	5	5	15	20	10	5	5	-
44	Waseem	18	M	22/01/09	8184	Rt CSOM	Rt CM+ type 1 tympanoplasty	10	5	5	15	0	15	10	10	20	5	15	10	10	20	5	15	10	10	20	5	-
45	Basamma	23	F	02/02/09	41795	Lt CSOM	Lt CM+ type 1 tympanoplasty	10	10	25	5	15	15	10	25	5	15	10	10	25	5	15	10	10	25	5	15	-
46	Jaganath	14	M	25/02/09	80777	Lt CSOM	Lt CM+ type 1 tympanoplasty	5	5	10	20	15	10	5	10	20	15	5	5	10	20	15	5	5	10	20	15	-
47	Shantamma	28	F	13/03/09	82420	Lt CSOM	Lt MRM	5	15	20	25	20	10	20	25	25	25	10	20	25	30	25	10	20	25	25	20	-
48	Ashwini	30	F	29/03/09	82178	Lt CSOM	Lt MRM	5	5	15	20	25	10	10	20	25	25	10	10	20	20	25	10	5	15	20	25	-
49	Mallamma	25	F	10/04/09	93491	Rt CSOM	Rt CM + type 1 tympanoplasty	5	10	20	15	25	10	10	20	15	25	5	10	20	15	25	5	10	20	15	25	-
50	Bagirati	20	F	19/04/09	9631	Lt CSOM	Lt CM+ type 1 tympanoplasty	20	15	20	10	25	20	15	20	15	25	20	15	20	15	25	20	20	25	15	25	-
51	Seetabai	45	F	26/04/09	93799	Lt CSOM	Lt MRM + type 4 tympanoplasty	10	25	20	15	20	15	25	20	15	20	10	25	20	15	20	15	25	20	15	20	-
52	Chandrakala	28	F	30/04/09	93879	Lt CSOM	Lt CM+ type 1 tympanoplasty	5	15	15	20	25	10	15	15	20	25	5	15	15	20	25	5	15	15	20	25	-
53	Pallavi	45	F	02/05/09	9775	Ots	Stapedectomy	15	10	10	5	10	15	10	10	5	10	15	10	10	5	10	15	10	10	5	10	-
54	Rekha	23	F	05/05/09	96576	Rt CSOM	Rt CM+ type 1 tympanoplasty	10	15	10	0	5	10	20	15	5	5	15	20	15	10	10	15	20	15	5	10	-
55	Meti	22	M	10/05/09	9786	Ots	Stapedectomy	10	5	5	0	0	10	10	5	0	0	10	5	5	0	0	10	5	5	0	0	-
56	Tulsa Bai	27	F	13/05/09	2506	Lt CSOM	Lt MRM	15	20	20	25	25	20	20	20	25	25	20	25	20	25	25	15	20	20	25	25	-
57	Akhila	22	F	18/05/09	93450	Lt CSOM	Lt MRM + type 1 tympanoplasty	10	15	15	10	20	15	20	20	15	20	15	20	20	15	20	15	20	20	15	20	-
58	Priyanka	23	F	25/05/09	93477	Rt CSOM	Rt CM+ type 2 tympanoplasty	0	-5	-5	20	15	5	0	-5	20	15	0	-5	-5	20	15	0	-5	-5	20	15	-
59	Sukesh	30	M	26/05/09	93665	Rt CSOM	Rt CM+ type 1 tympanoplasty	15	15	20	25	25	20	13	20	25	25	15	15	20	25	25	15	15	20	25	25	-
60	Sruti	22	F	30/05/09	90042	Lt CSOM	Lt MRM + type 2 tympanoplasty	5	15	10	5	5	5	20	15	10	10	10	20	15	10	10	10	10	20	15	10	-

Key to master chart:

- Lt: Left
- Rt: Right
- CSOM: Chronic Suppurative Otitis Media
- KHz: Kilo Hertz
- CM: Cortical Mastoidectomy
- MRM: Modified Radical Mastoidectomy
- SNHL: Sensoryneural Hearing Loss
- M: Male
- F: Female
- Ots: Otosclerosis