

**“STUDY OF CAROTICO CLINOID FORAMEN IN DRY HUMAN  
SKULL OF NORTH INTERIOR KARNATAKA”**

**by**

**Dr. SUNKESWARI SREEPADMA**

**DISSERTATION SUBMITTED TO THE BLDE UNIVERSITY, BIJAPUR**



In partial fulfillment  
of the requirements for the degree of

**DOCTOR OF MEDICINE**

**IN**

**ANATOMY**

Under the guidance of

**DR. S.D.DESAI MS**

**PROFESSOR AND HOD**

**DEPARTMENT OF ANATOMY**



**BLDEU'S SHRI. B. M. PATIL MEDICAL COLLEGE,  
HOSPITAL AND RESEARCH CENTRE, BIJAPUR -KARNATAKA**

**2011**

## **BLDE UNIVERISTY, BIJAPUR**

### **DECLARATION BY THE CANDIDATE**

I **Dr. Sunkeswari Sreepadma**, hereby solemnly declare that this dissertation entitled **“Study of Carotico clinoid foramen in dry human skull of North Interior Karnataka”** is a bonafide and genuine research work carried out by me under the guidance of **Dr. S.D.DESAI MS Professor and HOD**, Department of Anatomy, B.L.D.E.U’S Shri B. M. Patil Medical College, Hospital and Research Centre, Bijapur.

Date:

Place: Bijapur

**Dr. Sunkeswari Sreepadma**

Post Graduate Student  
Department of Anatomy  
B.L.D.E.U’s Shri B. M. Patil  
Medical College, Hospital &  
Research Centre, Bijapur

**CERTIFICATE BY THE GUIDE**

**BLDEU's Shri B. M. Patil Medical College  
Hospital & Research Centre  
Bijapur**

This is to certify that the dissertation titled “ **Study of Carotico clinoid foramen in dry human skull of North Interior Karnataka** ” is a bonafide research work done by **Dr. Sunkeswari Sreepadma**, in partial fulfillment of the requirement for the degree of M.D in Anatomy.

Date:  
Place: Bijapur

**Dr. S.D.DESAI M.S**  
Professor and HOD  
Department of Anatomy  
B.L.D.E.U'S Shri B. M. Patil  
Medical College, Hospital &  
Research Centre,  
Bijapur-586103

**ENDORSEMENT BY THE HEAD OF THE DEPARTMENT AND PRINCIPAL**

**BLDEU'S Shri B. M. Patil Medical College  
Hospital & Research Centre  
Bijapur**

This is to certify that the dissertation entitled "**Study of Carotico clinoid foramen in dry human skull of North Interior Karnataka**", is a bonafide research work done by Dr. Sunkeswari Sreepadma under the guidance of **Dr.S.D.DESAI**, MS Professor and HOD, Department of Anatomy, BLDEU'S Shri B. M. Patil Medical College Hospital and Research Centre, Bijapur.

Seal & Signature of the  
Head of Department of Anatomy  
**Dr. S.D.DESAI**  
**M.S (ANATOMY)**  
**BLDEU'S Shri B.M Patil**  
**Medical College, Hospital**  
**& Research Centre, Bijapur**

Date:

Place: Bijapur

Seal & Signature of the  
Principal  
**Dr. R.C.BIDRI**  
**M.D (Gen. Medicine)**  
**BLDEU'S Shri B.M Patil**  
**Medical College, Hospital**  
**Research Centre,**  
**Bijapur**

Date:

Place: Bijapur

## **COPYRIGHT**

### **Declaration by the Candidate**

I hereby declare that the BLDE University , Bijapur, Karnataka shall have the rights to preserve, use and disseminate this dissertation in print or electronic format for academic/research purpose.

Date:

**Signature of the candidate**

Place: Bijapur

**Dr. Sunkeswari Sreepadma**

**© BLDE University , Bijapur, Karnataka**

## **ACKNOWLEDGEMENT**

I am highly thankful to God for providing me the courage, inspiration & ability to work.

I heartily take this golden opportunity to express my heartiest gratitude & deep sense of indebtedness with humble respects and profound gratitude to my eminent and esteemed teacher & guide Dr S.D.DESAI MS, Professor and Head, Department of Anatomy, BLDEU's Shri B M Patil Medical College, Bijapur for his valuable guidance and constant encouragement in task of completion of this dissertation. His neverending willingness to render help, and meticulous attention during the thesis work, encouragement coupled with his rich knowledge and keen interest were a constant source of inspiration.

My deep gratitude to Dr.R.C.Bidri MD Principal BLDEU's Shri B M Patil Medical College, Bijapur for permitting me to utilize resources in completion of this work.

I sincerely thank to all teaching staff members, non-teaching staff members and colleagues of anatomy department for their kind support and cooperation.

My sincere thanks to Prof & Head Department of Community Medicine, Mrs.Vijaya Sorganvi Statistician, for valuable help in statistical analysis of data.

My thanks to library and digital library staff for their valuable help and kind cooperation in my study.

I am thankful to my husband Dr.Rajeev Joshi for his constant support & encouragement. I am thankful to my parents, my in laws, my brothers & sister in laws & friends for their blessings & moral support in successful completion of this dissertation.

My sincere thanks to one and all who supported for the completion of this dissertation.

Date:

**Dr Sunkeswari Sreepadma**

Place: Bijapur

**LIST OF ABBREVIATIONS USED**  
**(In alphabetical order)**

ACP-Anterior Clinoid Process

BL- Bilateral

C-complete

IC-Incomplete

ICA-Internal carotid artery

ICB-Interclinoid bar

Lt-Left

MCP- Middle Clinoid Process

PCP- Posterior Clinoid Process

Rt-Right

SB-Sellar Bridge

UL-Unilateral



## ABSTRACT

**Background & Objectives:** The anterior, middle and the posterior clinoid processes are located in the middle cranial fossa of the skull. Variations in sellar region like the interclinoid bar (the ossification between the anterior and posterior clinoid processes); and the carotico clinoid foramen (the ossification between the anterior and middle clinoid processes) may cause difficulty for clinoidectomy procedures. Therefore, to obtain a satisfactory result from these surgeries, detailed anatomical knowledge of the region and the type of ossification between the clinoid processes is necessary. The present study is an effort to know more about carotico clinoid foramen in skulls of North Interior Karnataka region.

**Methods:** For the present study, dry unknown human skull were obtained from north interior Karnataka region collected in the department of Anatomy of BLDEU's Shri B.M.Patil Medical College Hospital and Research centre Bijapur. The carotico clinoid foramen were studied in the dry human skull and were observed for various parameters like complete or incomplete, unilateral and bilateral and type of sellar bridges.

**Results and interpretations:** The data was analyzed statistically with chi square test. Carotico clinoid foramen was observed in 223 skulls and was found in 83(37.19%) skull bones. Amongst 223 skull bones, in 39 (17.47%) skulls the carotico clinoid foramen was forming a complete foramen; and in 44 (19.71%) skulls the carotico clinoid foramen was forming incomplete foramen.

Complete bilateral carotico clinoid foramen was found in 23 skulls (10.31%) and complete unilateral was found in 16 skulls (7.16%). Incomplete bilateral carotico clinoid foramen was found in 7 skulls (3.13%).

Incomplete unilateral carotico clinoid foramen was found in 37 skulls (16.58%) on right side -20 skulls (8.96%) and left side-17 skulls (7.62%) . The sellar bridging between anterior, middle and posterior clinoid processes was also studied.

**Conclusion:** Detailed knowledge of carotico clinoid foramen will increase the success of the regional surgery.

**Key words:** Carotico clinoid foramen, anterior clinoid process,  
middle clinoid process, sellar bridge.

## **TABLE OF CONTENTS**

	<b>CONTENTS</b>	<b>Page No.</b>
<b>1.</b>	<b>INTRODUCTION</b>	<b>1-3</b>
<b>2.</b>	<b>OBJECTIVES OF THE STUDY</b>	<b>4</b>
<b>3.</b>	<b>REVIEW OF LITERATURE</b>	<b>5-19</b>
<b>4.</b>	<b>MATERIALS AND METHODS</b>	<b>20-23</b>
<b>5.</b>	<b>RESULTS</b>	<b>24-38</b>
<b>6.</b>	<b>DISCUSSION</b>	<b>39-50</b>
<b>7.</b>	<b>CONCLUSION</b>	<b>51-52</b>
<b>8.</b>	<b>SUMMARY</b>	<b>53</b>
<b>9.</b>	<b>BIBLIOGRAPHY</b>	<b>54-59</b>
<b>10.</b>	<b>ANNEXURES</b>	<b>60-67</b>

## LIST OF TABLES

<b>S.No.</b>	<b>TABLES</b>	<b>Page No.</b>
1.	Complete and Incomplete type of carotico clinoid foramen Unilateral and bilateral type of carotico clinoid foramen	24
2.	Type 1 Sellar Bridge	31
3.	Type 2 Sellar Bridge	32
4.	Type 3 Sellar Bridge	33
5.	Type 4 Sellar Bridge	35
6.	No. of complete and incomplete Carotico clinoid foramen in right and left sides	37
7.	Chi square test for association between sides of Carotico clinoid foramen	37
8.	Comparative studies on the occurrence of the Carotico clinoid foramen	44
9.	Comparison of sellar bridges of present study with other study	45
10.	Comparison of sellar bridges of present study with other study	45

## LIST OF FIGURES

<b>S.No.</b>	<b>FIGURES</b>	<b>Page No</b>
1.	Interior of skull showing three cranial fossae	6
2.	Sphenoid bone	8
3.	Skulls from 1-110	22
4.	Skulls from 111-223	23
5.	Bilateral complete carotico clinoid foramen	27
6.	Unilateral complete carotico clinoid foramen Left side	27
7.	Unilateral complete carotico clinoid foramen Right side	27
8.	Bilateral incomplete carotico clinoid foramen	29
9.	Unilateral incomplete carotico clinoid foramen Left side	29
10.	Unilateral incomplete carotico clinoid foramen Right side	29
11.	Type 1 sellar bridge	34
12.	Type 4 sellar bridge	34

## LIST OF GRAPHS

<b>S.No.</b>	<b>Graphs</b>	<b>Page No</b>
1	Complete and incomplete carotico clinoid foramen	25
2	Bilateral and unilateral carotico clinoid foramen	26
3	Complete unilateral and complete bilateral carotico clinoid foramen	28
4	Incomplete unilateral and incomplete bilateral carotico clinoid foramen	30
5	Type 1 sellar bridge	31
6	Type 2 sellar bridge	32
7	Type 3 sellar bridge	33
8	Type 4 sellar bridge	35
9	Different types of sellar bridges	36
10	Sellar bridges represented by right and left sides	38
11	Sellar bridges represented by side with complete or incomplete type	38

## INTRODUCTION

The carotico clinoid foramen, first described by Henle (1855), is an osseous bridge between the tip of the middle clinoid process and the anterior clinoid process.

The microsurgical and radiological anatomy of the clinoid processes and their bridging structures give neurosurgeons more details about the anterior clinoid process, the middle and the posterior clinoid processes and their relations to the vascular and nervous neighbourhood during intradural and extradural clinoidectomy, thus making the operative procedures successful and safer.<sup>1</sup>

The knowledge of detailed anatomy of carotico clinoid ligament and foramen could increase the success of diagnostic evaluation and surgical approaches to the region. The ossification of the ligamentous structures in various parts of the body is frequently observed. This may result in a clinical problem such as compression to neighbouring structures or complications in the regional surgery.

In neurosurgical operations, the anterior clinoid process is usually accessed in order to gain entry into the clinoid space. After the internal carotid artery leaves the cavernous sinus, it is related medially to the anterior clinoid process. The presence of the ossified carotico clinoid ligament may form a potential site for compression of the internal carotid artery. Variations in the anterior clinoid process may pose a risk while it is being removed in regional surgical procedures.

The study of carotico clinoid foramen is immensely beneficial in skull based surgery. Excision of the anterior clinoid process may be required for many skull based surgical procedures and the presence of the carotico clinoid foramen may pose problems. The study of these structures is immensely beneficial and especially related to neurosurgeons and radiologists.

Research studies have also reported the fact that an ossified carotico clinoid ligament makes the removal of anterior clinoid process more difficult, especially in the presence of an aneurysm. Drilling of anterior clinoid process when required, may cause inadvertent injury to the internal carotid artery and optic nerve. Another important clinical characteristic is the pneumatization of the anterior clinoid process, which has to be evaluated preoperatively, in order to avoid serious complications like pneumocephalus and rhinorrhea. For any surgery involving anterior clinoid process, preoperative imaging may be advised, to keep such anomalies in view.

In 60% of cases, anterior clinoid processes are pierced by narrow venous canals arising from the anterior cavernous sinus and traversing through clinoid space. These are considered as potential source of bleeding during removal of the anterior clinoid process.<sup>2</sup> In any surgical operation involving exposure of the clinoid segment of the internal carotid artery, excision of the anterior clinoid process is mandatory. Even to expose the cavernous sinus, superiorly and to manage the paraclinoid aneurysm, the anterior clinoid process has to be removed. The clustering of the neurovascular structures in the vicinity of the anterior clinoid process renders the surgery more risky. Prior anatomical knowledge is essential for



identifying any inadvertent injury to the internal carotid artery. Recent studies proposed that the segment of the internal carotid artery located medial to the anterior clinoid process, so called the clinoid segment.

The newer concept is that the lower( proximal) dural ring , formed by the dura extending medially from the lower surface of the clinoid process, is the border between the intracavernous segment and the more recently described clinoid segment and that the upper(distal) dural ring separated the clinoid segment from the intradural segment.

The increasing recognition of the degree to which the aneurysms and tumors involve the clinoid segment has led to a greater focus on the anatomy of this area.<sup>3</sup> It is important to remember that the artery passes not only along the medial edge of the clinoid process but also courses upwards against , often grooving ,the medial half of the lower surface of the clinoid. The posterior tip of the anterior clinoid process may project medially behind the clinoid segment towards the middle clinoid process to which it may be united by an osseous bridge, thus forming a complete bony ring around the clinoid segment of the internal carotid artery.

Regrettably, there are few studies which have described the morphological and clinical characteristics of the carotico clinoid foramen. The main thrust of the present study emphasizes on the morphometry and topographic features of the clinoid region on bony specimens as a guide for neurosurgeons and the vascular surgeons to provide information on the limited intraoperative view and reduce mortality and morbidity in surgical approaches.

## **OBJECTIVES**

1. To know the prevalence of carotico clinoid foramen among the skull samples studied.
2. To study the carotico clinoid foramen in relation to: complete unilateral or complete bilateral and incomplete unilateral or incomplete bilateral.

## REVIEW OF LITERATURE

### **Normal Anatomy**<sup>4</sup>

The sphenoid bone is situated at the base of the skull in front of the temporals and basilar part of the occipital. It somewhat resembles a bat with its wings extended, and is divided into a median portion or body, two great and two small wings extending outward from the sides of the body, and two pterygoid processes which project from it below.

**Body (corpus sphenoidale):** The body, more or less cubical in shape, is hollowed out in its interior to form two large cavities, the sphenoidal air sinuses, which are separated from each other by a septum

**Surfaces:** The superior surface of the body presents in front a prominent spine, the ethmoidal spine, for articulation with the cribriform plate of the ethmoid; behind this is a smooth surface slightly raised in the middle line, and grooved on either side for the olfactory lobes of the brain. This surface is bounded behind by a ridge, which forms the anterior border of a narrow, transverse groove, the chiasmatic groove (optic groove), above and behind which lies the optic chiasma; the groove ends on either side in the optic foramen, which transmits the optic nerve and ophthalmic artery into the orbital cavity. Behind the chiasmatic groove is an elevation, the tuberculum sellae; and still more posteriorly, a deep depression, the sella turcica, the deepest part of which lodges the hypophysis cerebri and is known as the fossa hypophyseos.

Fig:1

The anterior boundary of the sella turcica is completed by two small eminences, one on either side, called the middle clinoid processes, while the posterior boundary is formed by a square-shaped plate of bone, the dorsum sellae, ending at its superior angles in two tubercles, the posterior clinoid processes, the size and form of which vary considerably in different individuals. The posterior clinoid processes deepen the sella turcica, and give attachment to the tentorium cerebelli. On either side of the dorsum sellae is a notch for the passage of the abducent nerve, and below the notch a sharp process, the petrosal process, which articulates with the apex of the petrous portion of the temporal bone, and forms the medial boundary of the foramen lacerum. Behind the dorsum sellae is a shallow depression, the clivus, which slopes obliquely backward, and is continuous with the groove on the basilar portion of the occipital bone, it supports the upper part of the pons.

**The Small Wings (alae parvae)/lesser wings:** The small wings or orbito-sphenoids are two thin triangular plates, which arise from the upper and anterior parts of the body, and, projecting lateral wards, end in sharp points.

**Surfaces:** The superior surface of each is flat, and supports part of the frontal lobe of the brain. The inferior surface forms the back part of the roof of the orbit, and the upper boundary of the superior orbital fissure. This fissure is of a triangular form, and leads from the cavity of the cranium into that of the orbit: it is bounded medially by the body; above, by the small wing; below, by the medial margin of the orbital surface of the great wing; and is completed laterally by the frontal bone.

Fig:2

It transmits the oculomotor, trochlear, and abducent nerves, the three branches of the ophthalmic division of the trigeminal nerve, some filaments from the cavernous plexus of the sympathetic, the orbital branch of the middle meningeal artery, a recurrent branch from the lacrimal artery to the dura mater, and the ophthalmic vein.

**Borders:** The anterior border is serrated for articulation with the frontal bone. The posterior border, smooth and rounded, is received into the lateral fissure of the brain; the medial end of this border forms the anterior clinoid process, which gives attachment to the tentorium cerebelli; it is sometimes joined to the middle clinoid process by a spicule of bone, and when this occurs the termination of the groove for the internal carotid artery is converted into a foramen (carotico-clinoid). The small wing is connected to the body by two roots, the upper thin and flat, the lower thick and triangular; between the two roots is the optic foramen, for the transmission of the optic nerve and ophthalmic artery.

Behind the optic canals, on the sides of the tuberculum and undercover of the anterior clinoid processes are the upper ends of the carotid sulci; there are sometimes bordered posteriorly by the mcp, which may even meet the anterior clinoid process and form a carotico clinoid foramen (canal) here<sup>5</sup>

In the sphenoid bone, the posterior border, smooth and rounded, is received into the lateral fissure of the brain; the medial end of this border forms the anterior clinoid process, which gives attachment to the tentorium cerebelli; it is sometimes joined to the

middle clinoid process by a spicule of bone, and when this occurs the termination of the groove for the internal carotid artery is converted into a foramen (carotico-clinoid).<sup>6</sup>

Black and Schener stated, the most common form bridging between different clinoid processes, is between the anterior clinoid process and middle clinoid process, forming the clinocarotid (carotico clinoid) canal through which the ICA passes upwards at the anterior end of the cavernous sinus.<sup>7</sup>

In the study done by Bilodi AKS, in 150 dry human skulls wherein he described four types of sellar brides: In type 1, complete ossified horizontal bar of bone connecting the acp, mcp, pcp was found thus forming a complete osseous ring around sella turcica in one skull only (7.69%) which was a rare variety. Very few literatures have reported about this variation.

In Type 2 variety three skulls showed interclinoid bar of bone on both sides connecting anterior clinoid process with middle clinoid process forming a complete carotico clinoid foramen bilaterally through which the internal carotid artery passes (23.07%), while in one skull, this interclinoid bar of bone was seen only on right side and absent on left side(7.69%),while there was no interclinoid bar connecting anterior clinoid process and posterior clinoid process.

In Type 3, incomplete carotico clinoid foramen on both sides with a gap of 3mm on both sides in four skulls (30.76%). Another skull showed incomplete carotico clinoid foramen on one side (i.e., on right side) only (7.69%).

In Type 4, two skulls showed interclinoid bar of bone connecting anterior clinoid process and posterior clinoid process on both sides (15.38%),and other skull showed on left side



only(7.69%).There was no skull showing horizontal of one connecting anterior clinoid process and middle clinoid process.<sup>8</sup>

Patnaik VVG reported about 2 skulls, in which one skull had bilateral carotico clinoid foramen and in the other one , the anterior clinoid process and pcp were fused bilaterally forming interclinoid bars.<sup>9</sup>

In a case report by Srijit Das, observed the presence of carotico clinoid ligament in a skull bone. The ossified ligament was found to extend between the anterior clinoid process and middle clinoid process bilaterally<sup>2</sup>.

In the study conducted by Seoane et al., on microsurgical anatomy of dural collar(carotid collar) and rings around the clinoid segment of the internal carotid artery, stated that the upper and lower dural rings were best defined along the lateral and anterior margins of the artery, were less distinct medially ,and disappeared posteriorly, where the dura forming the upper and lower rings came together<sup>3</sup>.

In a case report by Skrzat J, the ossified ligament exists as a bony bridge between the anterior clinoid process and posterior clinoid processes on the left side of the skull. The carotico clinoid foramen results from an ossified ligament that unites the anterior with middle clinoid process. Ossification of the ligament that connects tips of the anterior clinoid process and posterior clinoid process produces a solid interclinoid bar.<sup>10</sup>

Omer Ozdogmus et al., study stated that the frequency of ossification of the interclinoid ligament in 50 autopsy cases bilaterally. Bilateral complete ossification of the interclinoid ligament was found only in 3 male autopsy cases (6%) . Statistical analysis showed no correlation between age, side and the frequency of ossification of the interclinoid ligament <sup>11</sup>

Peker T et al., reported about the incidence and types of sella and sphenopetrous bridges. Sella bridges were seen in 34.17% of the overall subjects of total 80 dry skulls. The incomplete and complete types were 3.0 % and 17.5% respectively. <sup>12</sup>

Suazo GIC in a case report regarding the ossification of sella turcica and clinoid ligaments reported about the morphometric characteristics and the morphological analysis of a dry skull with complete ossification of the interclinoid ligaments and partial ossification of the sidewalls of the sella turcica. <sup>13</sup>

Erturk M in his study done on 119 adult dry skulls and 52 adult cadaveric heads in Turkish population, observed carotico clinoid foramen in 35.67% of the specimens. He observed carotico clinoid foramen unilaterally in 23.98% and bilaterally in 11.69%. The complete type carotico clinoid foramen was observed in 4.09% of specimens and incomplete type 14.91%. The incidence of the interclinoid bar was 8.18%. <sup>14</sup>

Lee PH conducted study in thirty-five cadaver heads, and were dissected and the anterior clinoid process regions were examined in 55 skull sides. He observed that in

eight sides the anterior clinoid process had been pneumatized from the sphenoid sinus. The carotico clinoid foramen was revealed in only eight sides. The extra-ocular nerves ran forward to the superior orbital fissure at the inferolateral aspect of the anterior clinoid process, with the oculomotor nerve being closest. The posterolateral area of the carotico-oculomotor membrane was thin and incomplete in nine sides. The study clarified the anatomical relationship between the anterior clinoid process and its surrounding structures, and identified the major variations experienced.<sup>15</sup>

In the study conducted by Jae Min Kim in 70 specimens from 35 formalin fixed cadaveric heads revealed that the narrow space between the inner dural layer and the ICA communicates with cavernous sinus through an incompetent proximal dural ring. Therefore the clinoid ICA should be considered to be the most rostral portion of the cavernous (C4) segment of the ICA. The proximal dural ring is a surgical landmark rather than a true dural ring.<sup>16</sup>

Cargill H Alleyne et al., conducted a study about the clinoidal segment which is important for correctly diagnosing and managing aneurysms; because the risks of aneurysmal rupture vary with the specific location of lesions along this small segment of the ICA as the surgical approach depends on the exact location of the lesion. He also stated about the relationship of the ICA to the anterior clinoid process and dural rings and the risk of rupture associated with each specific type of aneurysm.<sup>17</sup>

Aneurysms of the proximal carotid (paraclinoid) artery is an interesting family of the aneurysms arising from the proximal part of the internal carotid artery.<sup>18</sup>

Ozdogmus et al study reported the ossification state of the carotico-clinoid ligament, the diameter of the internal carotid artery and the carotico-clinoid foramen has been studied on 50 autopsy cases. Of the 100 carotico-clinoid foramina examined, in 27 sides (15 right, 12 left) the carotico-clinoid ligament was completely ossified, in 18 sides (9 right, 9 left) the carotico-clinoid ligament was incompletely ossified and in 55 sides (26 right, 29 left) it was a ligamentous structure. The correlation of the dimensions of the carotico-clinoid foramen and the internal carotid artery showed no statistical significance, except between the carotico-clinoid foramen with a fibrous carotico-clinoid ligament and the internal carotid artery on the right side ( $p=0.007$ ,  $r=0.51$ ). The existence of a bony carotico-clinoid foramen may cause compression, tightening or stretching of the internal carotid artery.<sup>19</sup>

In a study conducted by Gupta N, on anterior clinoid process and optic strut with emphasis on variations of carotico clinoid foramen wherein thirty-five dry skulls were used. Morphology of carotico-clinoid foramen was studied. Out of 70 sides in thirty five skulls examined, carotico-clinoid foramen was observed in 14 (20.0%) cases. Out of which complete foramen was in 3 (right side, 4.3%), partial in 8 (6 right, 2 left, 11.4%) and contact in 3 (left side, 4.3%) respectively.<sup>20</sup>

Narolewski R stated that the anterior clinoid process is a structure of complex architecture. In most cases (70%), at least one bony spicula arises from the tip of anterior clinoid and not infrequently passes in a fold of the dura directly under the internal carotid. Bony bridges were observed joining spiculae with similar protrusions of the middle and/or posterior clinoid thought to be especially dangerous during anterior clinoidectomy. 60% of anterior clinoids were pierced by narrow venous canals arising from the anterior cavernous sinus and running through the clinoid space. They are considered a source of bleeding usually encountered at the very end of anterior clinoid removal. The optic strut seems to be a structure of stable and relatively simple architecture. In 20% of specimens, optic struts were pierced by narrow venous canals arising from the anterior cavernous sinus and running through the clinoid space. The anterior clinoid process and the optic strut happen to be pneumatized.<sup>21</sup>

In a study conducted on Two hundred and fifty adult dried Indian human skulls by Rani Archana on incidence of osseous interclinoid bars in Indian population, observed that the bony bars between the three clinoid processes can be divided into four types (Types I, II, III, IV). Due to the presence of these bars three types of interclinoid foramina were formed. A total incidence of 22% of various types of interclinoid bars was observed, out of which 12% were Type I, 5.6% Type II, 4% type III and only 0.4% were of type IV variety<sup>22</sup>

Azeredo RA, conducted study on 270 human adult skulls of both sexes and concluded that: a) the fusion between the anterior and medium clinoid processes occurred

in 17 cases (6.27%), being that in 11 cases (4.05%) bilaterally; b) between the medium and posterior clinoid processes occurred in six cases (2.22%); c) between the anterior and posterior clinoid processes occurred bilaterally in six cases (2.22%); d) between the three processes occurred in nine cases (3.04%).<sup>23</sup>

The region surrounding the anterior clinoid process was observed in 70 specimens from 35 formalin-fixed cadaveric heads by Kim JM. The outer layer of the dura (dura propria) is a thick membrane that fuses with the adventitia of the ICA to form a competent ring that separates the intradural ICA from the extradural ICA. The thin inner membranous layer of the dura loosely surrounds the ICA throughout the entire length of its clinoid segment. The most proximal aspect of this membrane defines the proximal dural ring. The proximal ring is incompetent and admits a variable number of veins from the cavernous plexus that accompany the ICA throughout its clinoid segment. The narrow space between the inner dural layer and the clinoid ICA is continuous with the cavernous sinus via an incompetent proximal dural ring. This space between the clinoid ICA and the inner dural layer contains a variable number of veins that directly communicate with the cavernous plexus.<sup>24</sup>

Herbert Cares studied the clinical significance of the optic strut and stated that recognition of the optic strut as a landmark may obviate the common error of mistaking other structures for the optic canal. These include a pneumatized anterior clinoid process, a posterior ethmoid air cell, an ectopic sphenoid cellule, a defect in the greater wing of the sphenoid, or a carotico-clinoid foramen.<sup>25</sup>

Jonas P Becktor studied on Profile radiographs from 177 individuals who had undergone combined orthodontic and surgical treatment. A sella turcica bridge was registered in those subjects where the radiograph revealed a continuous band of bony tissue from anterior cranial fossa to posterior cranial fossa across the sella turcica. Two types of sella turcica bridge were identified. A sella turcica bridge occurred in 18.6% of the subjects.<sup>26</sup>

Ghorbani M, in his study observed incomplete two-sided carotico clinoid foramen in nine skulls and complete foramen in two skulls among twelve skulls.<sup>27</sup>

Lee HY in a study done on 73 dry skulls of Korean adults the length, basal width, thickness at the root of the anterior clinoid process and short diameter of the optic strut were measured in 60 skulls. The incomplete carotico clinoid canal was defined by the existence of the bony spine from anterior clinoid process and middle clinoid process or lateral side of the body of the sphenoid. A canal was observed in 4.1% of 146 sides and an incomplete type was observed in 11.6%. Among them was one skull (1.4%) with a bilateral complete carotico clinoid canal, 3 skulls (4.1%) with bilateral incomplete canals and one skull with the right canal complete and the left incomplete. Both complete and incomplete types were more frequent on the right side (9.2%) than on the left side (5.5%).<sup>28</sup>

Shipra Paul studied anomalous posterior clinoid process and its clinical importance and observed an anomalous posterior clinoid process in two human skulls .In one case the upward projected posterior clinoid process was rounded and not pointed, as seen normally. There was a concave depression between the two posterior clinoid processes. Apparently, the depth of the sella turcica seemed to be much more than normal. In the other skull, the posterior clinoid processes were projecting upwards, very close to each other and displayed spicules on either sides. It was, as if two vertical projections were representing the posterior clinoid processes. Apparently, the depth of the sella turcica seemed to be much more than normal.<sup>29</sup>

McLachlan stated that occasionally middle clinoid processes form prominent projections on the lateral part of the anterior wall and may fuse with the anterior clinoids to form the carotico-clinoid foramina through which pass the carotid arteries<sup>30</sup>

Yang studied intracranial structures pertinent to pterional craniotomy extradural anterior clinoidectomy in 10 dry craniums and 10 cranial bases with dura mater. Stepwise dissections simulating pterional craniotomy extradural anterior clinoidectomy were performed in 20 cadaver heads bilaterally and concluded that Pterional craniotomy extradural anterior clinoidectomy is a promising new alternative approach for optic nerve decompression in patients with traumatic optic neuropathy.<sup>31</sup>



Keyes observed 34.84% incidence of clinocarotid canal (carotico clinoid foramen) in American population. He observed that this canal was more common bilaterally (23.41%).<sup>32</sup>

Suba Ananthi K conducted study on 73 adult skulls and 2 adult sphenoid bones and observed bilateral complete sellar bridge with bilateral carotico clinoid foramen in one skull, unilateral left complete sellar bridge in another skull and an incomplete right sellar bridge with left carotico clinoid foramen in a sphenoid bone.<sup>33</sup>

Tobenas Dujardin AC study done by examining a collection of histological sections, representing a continuous series of 48 embryologic and foetal specimens, covering the period of the first 6 months of intra-uterine life. Neurological and vascular elements develop during the embryologic period; the internal carotid artery is recognizable in the various sections of its course and acquires a histological adult parietal constitution. The foetal period corresponds to the development of the meningeal structures. The superior, medial and lateral walls appear on the fifteenth week of amenorrhoea and do not change after that. The internal carotid artery enters subarachnoid space accompanied by a sleeve of mesenchymatous cells, which fixes it to the anterior clinoid process.<sup>34</sup>

Shahin Hunnargi conducted a study on 25 dry adult south Indian skulls to investigate the dimensions and variation in the shape of anterior clinoid process and observed that anterior clinoid processes of South Indian skulls are highly variable and are marginally thicker than anterior clinoid processes of Nepalese and Korean origin.<sup>35</sup>

## METHODOLOGY

### SOURCE OF DATA

For the present study, dry unknown human skull were obtained from north interior Karnataka region collected in the department of Anatomy of BLDEU's Shri B.M.Patil Medical College Hospital and Research Centre Bijapur.

### METHOD OF DATA COLLECTION

Sample Size: 223 dry unknown human skull were taken for the study.

Sampling procedure: The carotico-clinoid foramen were studied in the dry human skull and were observed for the following parameters

1. Whether the foramen is present or absent
2. Whether the foramen is complete or incomplete
3. Whether the foramen is unilateral or bilateral
4. To check the type of sellar bridge:

Type 1

Type 2

Type 3

Type 4

**Statistical Analysis:** The data was analysed statistically with chi square test. Graphs and tables were generated using Microsoft office word and excel software

**Duration of study:**

One and half years, from November 2008 to April 2010

**Inclusion criteria:**

For the present study dry unknown human skull which were well ossified were taken

**Exclusion criteria:**

Fragmented, Broken skull bones were excluded from the study.

Fig 3

Fig :4

## RESULTS

For the present study, dry unknown human skull were obtained from north interior Karnataka region collected in the department of Anatomy of BLDEU's Shri B.M.Patil Medical College Hospital and Research centre Bijapur.

The human skull were studied for the carotico clinoid foramen with various parameters.

The data was analyzed statistically with chi square test. Graphs and tables were generated using Microsoft office word and excel software.

### **Carotico clinoid foramen present or absent**

The presence or absence of carotico clinoid foramen was observed in 223 skulls and it was found that in 83(37.19%) skull bones the carotico clinoid foramen was found.

**Table - 1**

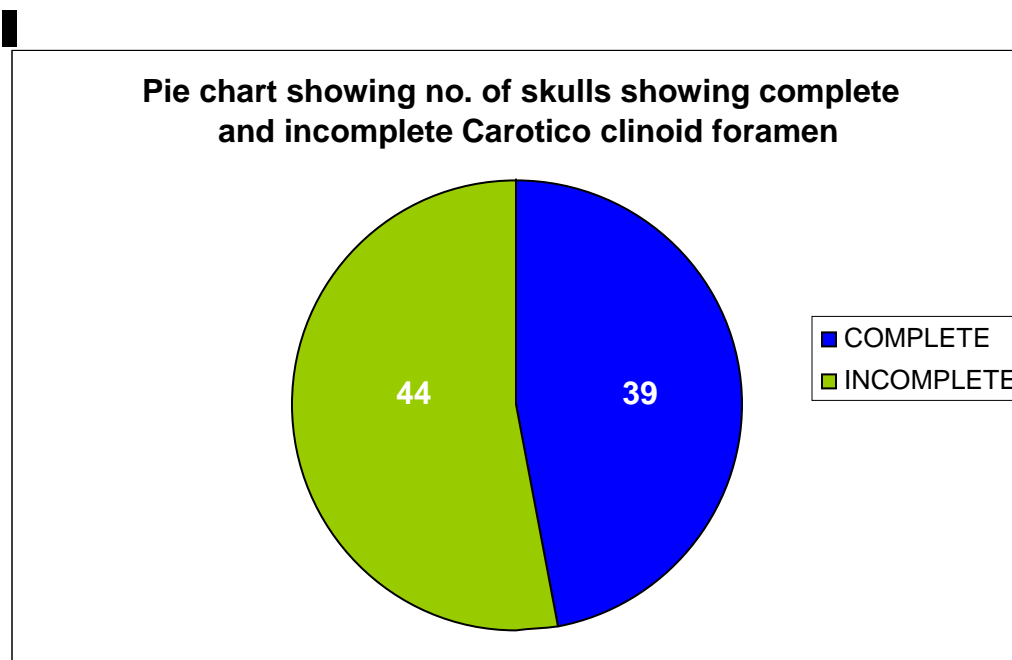
### **Incidence of the complete and incomplete type of carotico clinoid foramen**

	Side	Complete	Incomplete	Total
Unilateral	Right	9 (4.03%)	20 (8.96%)	29 (12.99%)
	Left	7 (3.13%)	17 (7.62%)	24 (10.75%)
Bilateral		23 (10.31%)	7 (3.13%)	30 (13.44%)

### **Carotico clinoid foramen complete or incomplete**

It was found that amongst 223 skull bones, in 39 (17.47%) skulls the carotico clinoid foramen was forming a complete foramen; and in 44 (19.71%) skulls the carotico clinoid foramen was forming incomplete foramen.

**Graph -1**



### Carotico clinoid foramen bilateral or unilateral

Bilateral carotico clinoid foramen was found in 30 (13.45%) skull bones.

Unilateral carotico clinoid foramen was found in 53 (23.74%) skull bones, amongst these, 29(12.99%) was found on right side and 24 skulls ( 10.75%) was found on the left side .

**Graph - 2**

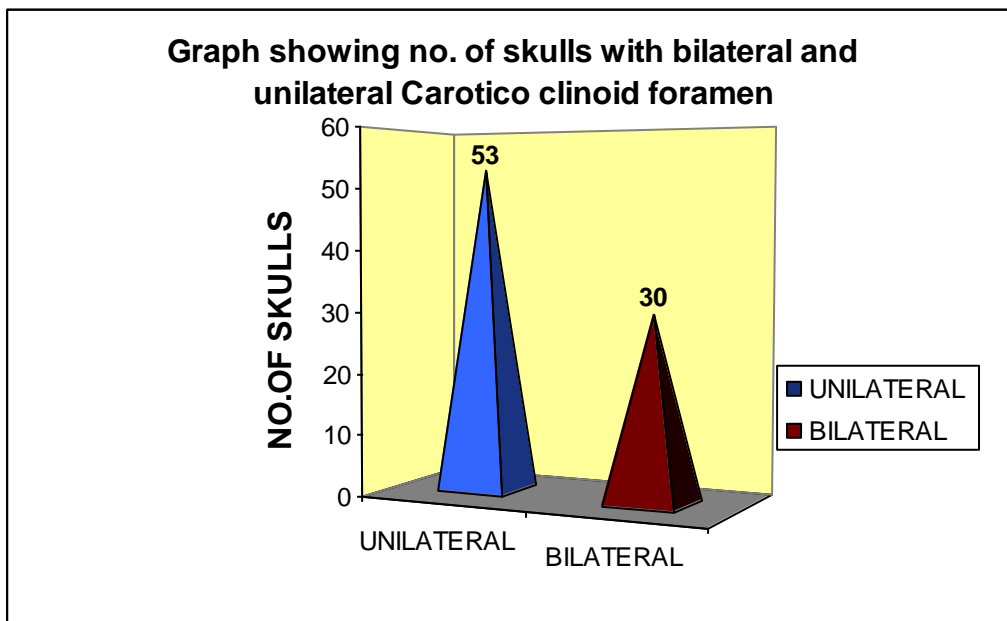




Fig:5,6,7

### Carotico clinoid foramen complete bilateral and complete unilateral

Complete bilateral carotico clinoid foramen was found in 23 skulls (10.31%) and complete unilateral was found in 16 skulls (7.16%).

Graph - 3

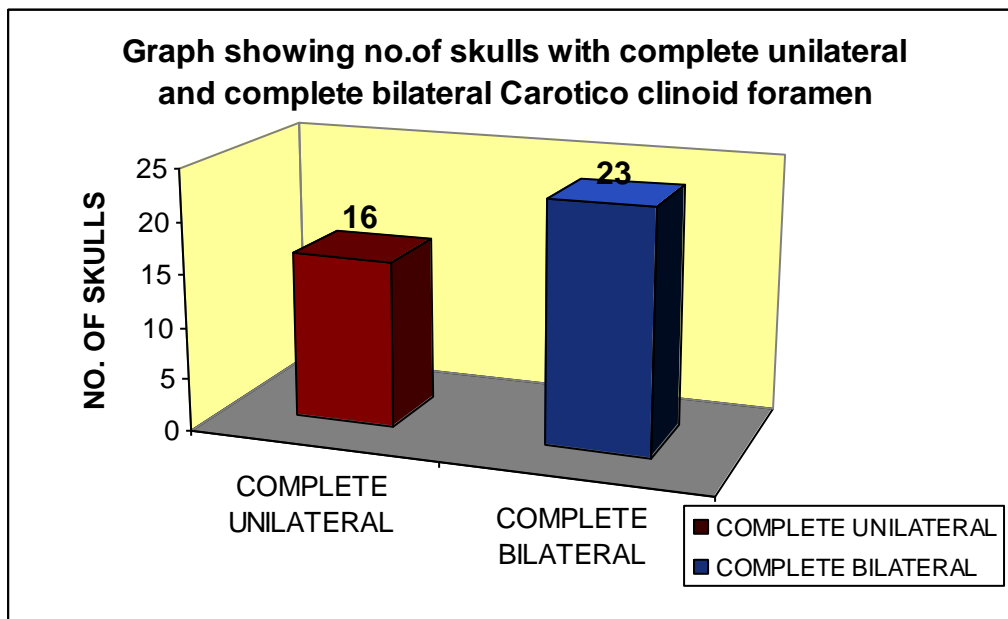


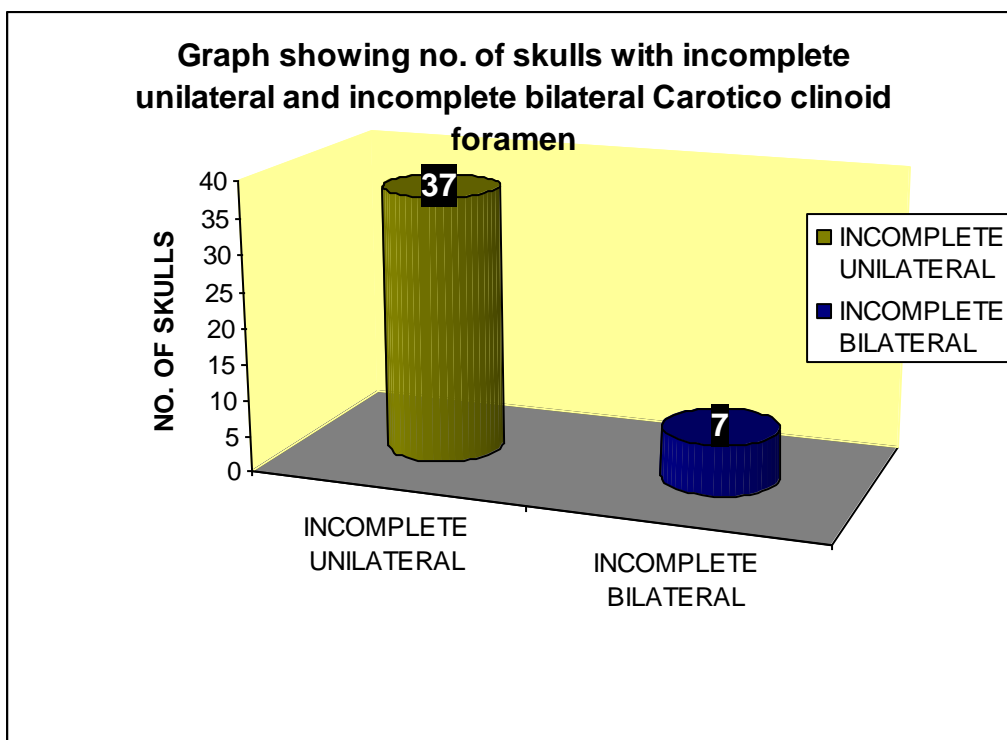
Fig:8,9,10

## Carotico clinoid foramen incomplete bilateral and incomplete unilateral

Incomplete bilateral carotico clinoid foramen was found in 7 skulls (3.13%).

Incomplete unilateral carotico clinoid foramen was found in 37 skulls (16.58%); amongst these, 20 skulls(8.96%) right side and 17 skulls (7.62%) left side.

**Graph - 4**



## Type of sellar bridge

### Sellar Bridge Type 1:

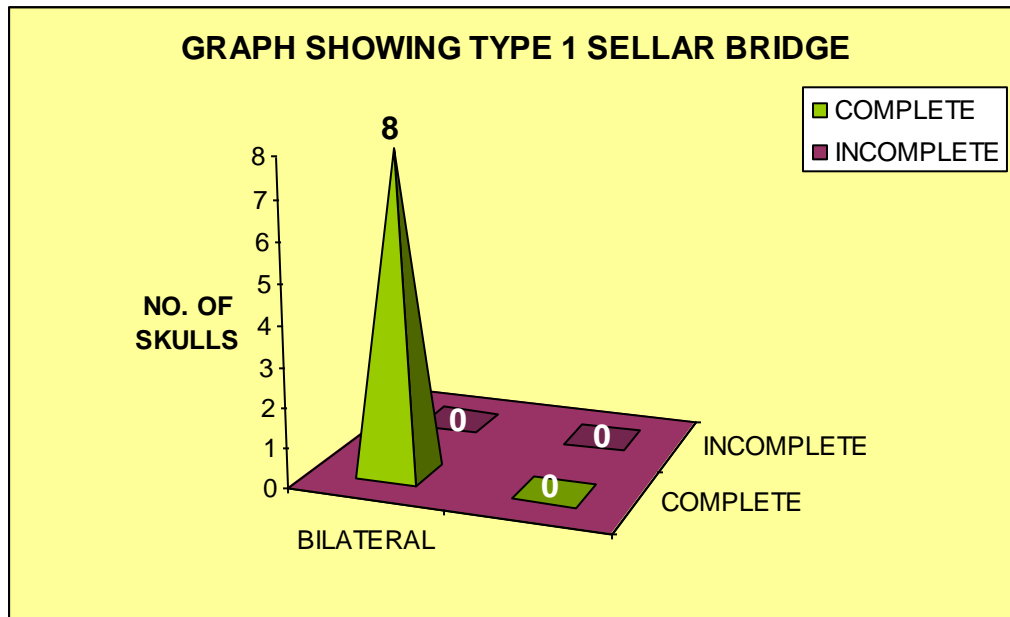
The skull showed complete ossified clinoid bar of bone connecting all anterior clinoid process, posterior clinoid process and middle clinoid process, forming a complete osseous ring around the sella turcica . In the present study 8 skulls (3.58%) showed sellar bridge connecting all the clinoid process bilaterally thus forming a complete osseous ring around the sella turcica.

**Table – 2**

#### Type 1 cases by complete, incomplete & bilateral, unilateral

	Bilateral	Unilateral		Total
		Right	Left	
Complete	8 (3.58%)	0	0	8 (3.58%)
Incomplete	0	0	0	0
Total	8 (3.58%)	0	0	8 (3.58%)

**Graph – 5**



### Sellar Bridge Type 2:

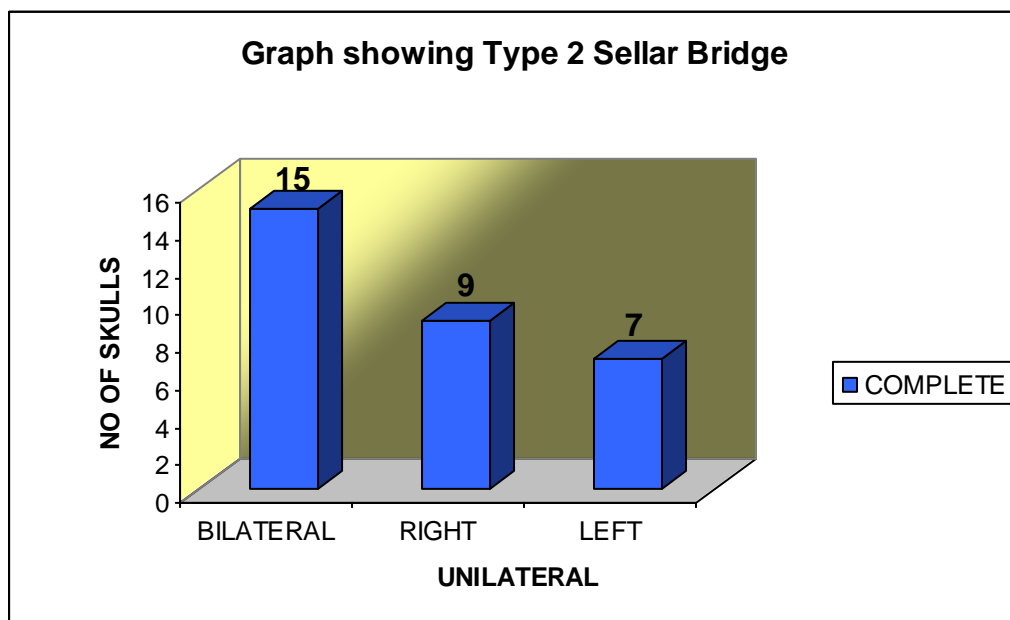
The interclinoid bar of bone on both sides connecting anterior clinoid process with middle clinoid process forming a complete carotico clinoid foramen through which the internal carotid artery passes. Complete foramen was observed in 31 skulls (13.90%)

In the present study bilateral complete carotico clinoid foramen was found in 15 skulls (6.73%), unilateral complete on right side in 9 skulls (4.03%), complete foramen on left side in 7 skulls(3.13%)

**Table – 3**  
**Type 2 cases by complete, incomplete & bilateral, unilateral**

	Bilateral	Unilateral		Total
		Right	Left	
Complete	15 (6.73%)	9 (4.03%)	7 (3.13%)	31 (13.90%)
Total	15 (6.73%)	9 (4.03%)	7 (3.13%)	31 (13.90%)

**Graph -6**



**Sellar Bridge Type 3 :**

A bony spicule arising from the middle clinoid process towards the anterior clinoid process forming an incomplete carotico clinoid foramen.

Present study showed incomplete foramen in 44 skulls (19.73%). Bilateral incomplete foramen was found in 7 skulls (3.13%), unilateral incomplete foramen was found in 20 skulls(8.96%) on right side and on left side in 17 skulls(7.62%)

**Table- 4**

	Bilateral	Unilateral		Total
		Right	Left	
Complete	0	0	0	0
Incomplete	7 (3.13%)	20 (8.96%)	17 (7.62%)	44 (19.73%)
Total	7 (3.13%)	20 (8.96%)	17 (7.62%)	44 (17.93%)

**Graph -7**

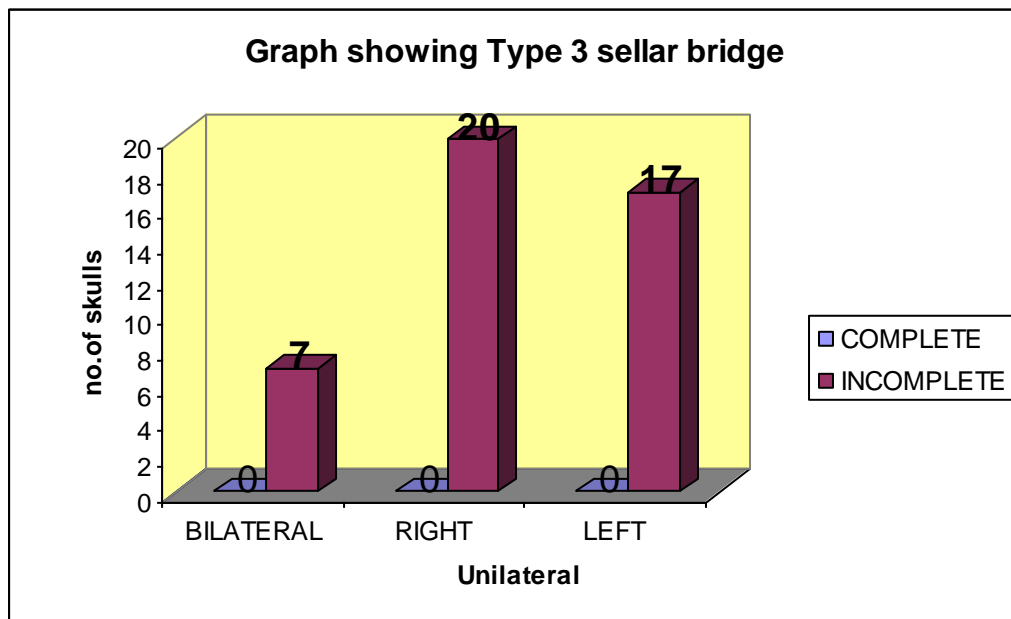


fig:11,12



**Type 4:**

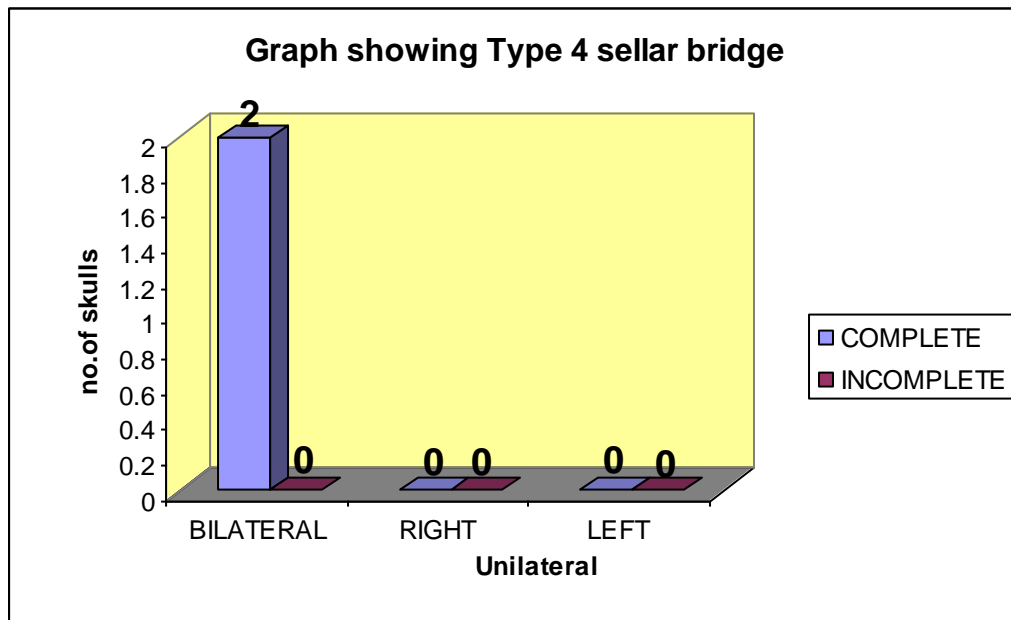
It is the Sellar bridge between anterior clinoid process and posterior clinoid process.

Only 2 skulls (0.85%) showed sellar bridge between anterior and posterior clinoid processes bilaterally.

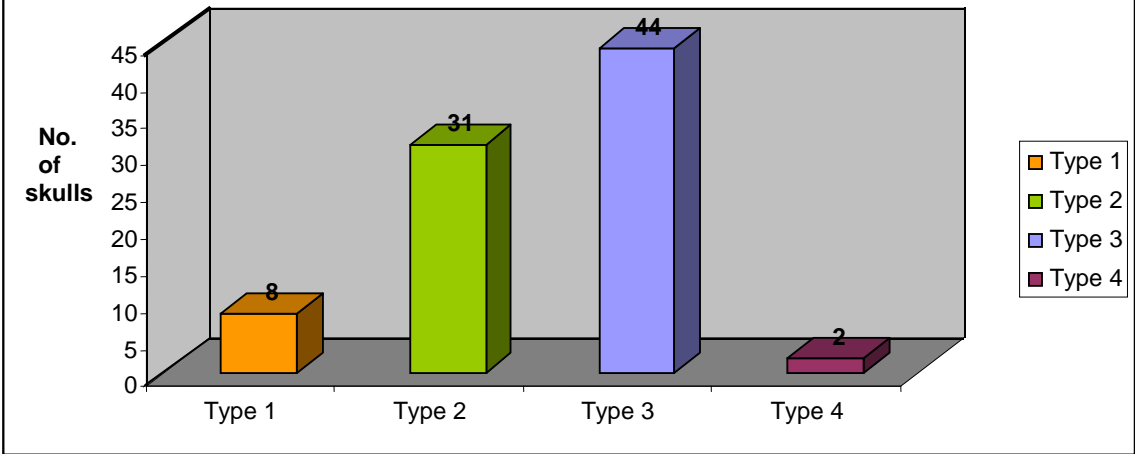
**Table - 5**

	Bilateral	Unilateral	
		Right	Left
Complete	2	0	0
Incomplete	0	0	0
Total	2	0	0

**Graph - 8**



**Graph 9 showing different types of sellar bridges**



**Table – 6**

**Chi – Square Test for testing the presence of association between sides of CCF**

	Complete	Incomplete	Total	%
Right	9	20	29	54.71
Left	7	17	24	45.28
Total	16	37	53	

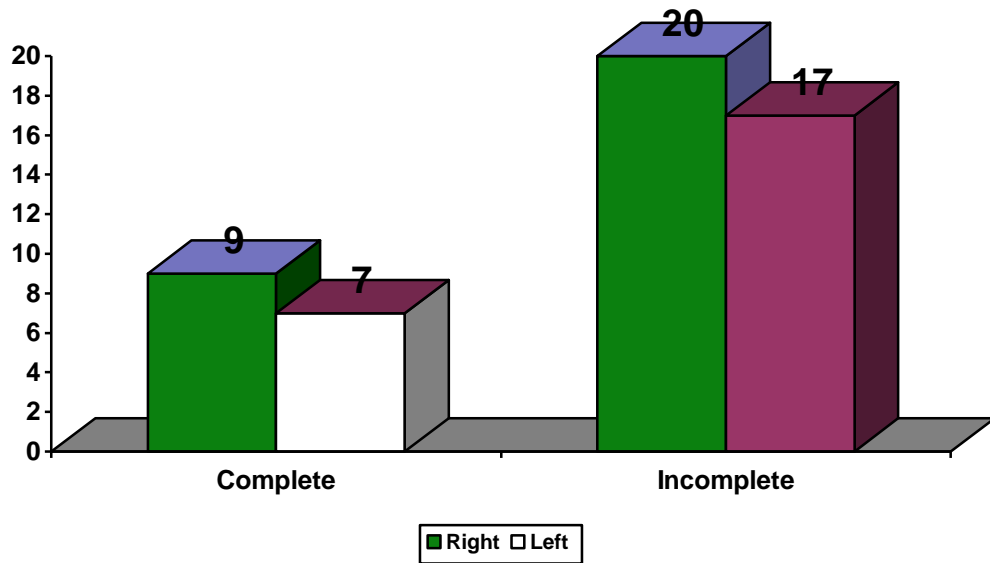
**Table - 7**

Observed Values – Oi	Expected Values – Ei	Chi – Square Value	P – Value
9	8.75	0.99	< 0.05*
20	20.24		
7	7.24		
17	16.75		

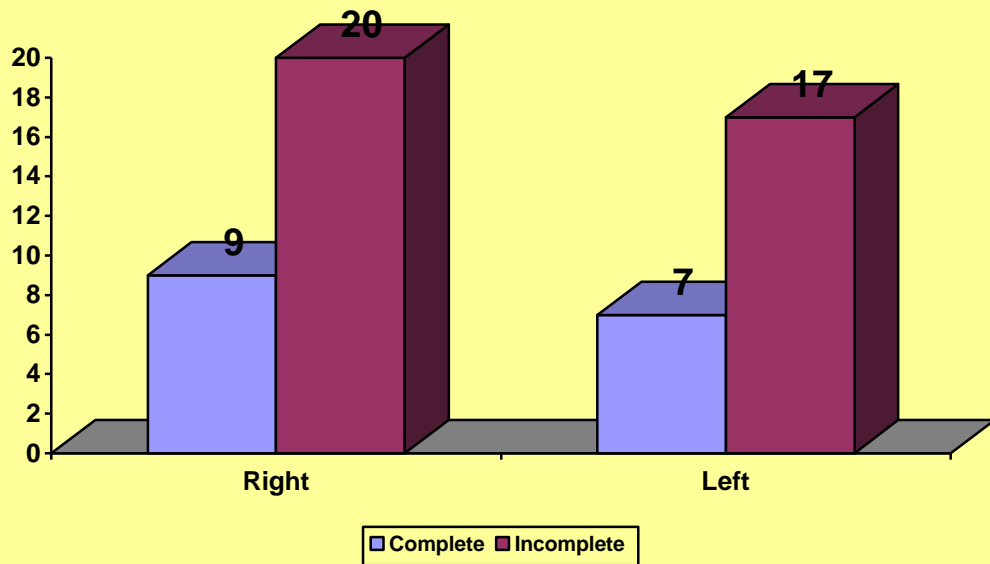
NS : Not significant ( $p > 0.05$ ), \*Significant: ( $p < 0.05$ )

Statistically significant increase in the number of incomplete carotico clinoid foramen was observed on the right ( $p < 0.05$ ) compared to the left side. Similarly Statistically significant increase in the number of complete carotico clinoid foramen on the right ( $p < 0.05$ ) compared to the left side. Hence the total observation of carotico clinoid foramen was more on the right side compared to the left side.

**Graph-10 Bar Chart Representing Sella Bridges by Side**



**Graph 11 - Bar Chart Representing Sella Bridges by Side**



## DISCUSSION

The ossification of ligamentous structures in various parts of the body is frequently observed. This may result in a clinical problem such as compression of neighboring structures and complications in regional surgery. Certain parts of the sphenoid bone are connected by ligaments, which occasionally ossify, such as the pterygospinous (between the spine and the upper part of the lateral pterygoid plate), the interclinoid (joining the anterior and posterior clinoid process), and the carotico clinoid (connecting the anterior and middle clinoid process).

The carotico-clinoid foramen is the result of ossification either of the carotico-clinoid ligament or of a dural fold extending between the anterior and middle clinoid processes of the sphenoid bone.<sup>36</sup> The anterior and middle clinoid processes are united by a bony bridge, which converts the distal end of the carotid sulcus into an ostium called the carotico-clinoid foramen (canal). Through the carotico clinoid foramen passes the internal carotid artery<sup>19</sup>.

The existence of a bony carotico clinoid foramen may cause compression, tightening or stretching of the internal carotid artery. Further, removing the anterior clinoid process is an important step in regional surgery; the presence of a bony carotico-clinoid foramen may have high risk. Therefore, detailed knowledge of the type of ossification between the anterior and middle clinoid processes can be necessary to increase the success of regional surgery.

Parasellar interclinoid bars are significant in surgical management while dealing with the vascular, neoplastic or traumatic lesions of the central skull base and can also compress the surrounding structures giving rise to various clinical symptoms. Du Boulay mentioned that this ligamentous ossification occurs in the early age and is possibly an extension of the normal ossification of the anterior and posterior clinoid processes.<sup>22</sup>

Ossification of the interclinoid ligament usually leads to so-called, “bridging” of the sella, which can be complete or partial.<sup>10</sup> Sella and sphenopetrous bridges have been studied as cranial discrete traits by various authors. The bridge between the anterior and the middle clinoid processes could cause structural and physiological disorders in the cavernous part of the internal carotid artery by changing the anatomical structure of the terminal part of the carotid groove.

The presence of a fibrous or osseous bridge between the anterior clinoid process and the middle or the posterior clinoid process makes the approach to the internal carotid artery more difficult and increases the risk in the removal of the sella bridges, especially if an aneurysm is present.

Various authors have reported that several endocrinological and neurological disorders are associated with such variations. Sella bridges were demonstrated roentgenologically to a 25% extent in idiots, to 20% in criminals, to 15% in epileptics, and to 38% in other cases with mental disorders. Bergerhoff presented exhaustive anatomic–roentgenographic studies about the anatomy and the topography of the sella, and finally Lang investigated the structure and postnatal organization in infrequent ossifications of the sella turcica region.<sup>12</sup>

The anterior clinoid fold is a very significant landmark for safe extradural clinoidectomy. Removal of the ACP is one of the most critical procedures to the successful and safe management of ophthalmic segment aneurysms and tumors located in the paraclinoid region and cavernous sinus. Special attention should be paid to the anatomic landmarks indicating the relationship between the anterior clinoid process and adjacent structures. Beside that, pneumatization of the anterior clinoid process should be evaluated preoperatively with computed tomography to avoid complications such as rhinorrhea and pneumocephalous. Knowledge of the complex architecture of the anterior clinoid process has surgical importance. Problems with this procedure may arise from either the need to be familiar with the complex anatomy of the clinoid region or the variable anatomy of the anterior clinoid process, like extensive pneumatization of the sphenoid bone.<sup>3</sup>

The presence or absence of carotico clinoid foramen was observed in 223 dry human skulls and it was found that in 83 skull bones (37.19%) the carotico clinoid foramen was found. Erturk et al., reported in Turkish population in a study involving 119 dry skulls and 52 cadaveric heads. It was found that carotico clinoid foramen was observed in 36.97% and 32.69% respectively, together the total incidence was 61(35.67%)<sup>14</sup>, Keyes observed 34.84% incidence of clinocarotid canal (carotico clinoid foramen) in American population<sup>32</sup> which were similar to present study. Rani Archana in out of the 250 dried Indian human skulls 30 (12%) skulls showed Carotico clinoid foramen<sup>22</sup> which is less when compared to the present study.

In the present study it was found that amongst 223 skull bones, in 39 (17.47%) skulls the carotico clinoid foramen was forming a complete foramen; and in 44 (19.71%) skulls the carotico clinoid foramen was forming incomplete foramen. Erturk M in 119 dried human skulls and 52 cadaver observed the complete-type carotico clinoid foramen in 14 (4.09%) of the specimens, and the incomplete type in 51(14.91%)<sup>14</sup> which was less when compared to the present study. Lee HY in 73 dried Korean skull study<sup>28</sup>, complete carotico clinoid foramen was observed in 4.1% of 146 sides and an incomplete type was observed in 11.6% which was less when compared to present.

In the study of Ozdogmus et al., out of the 50 autopsies examined, 27 sides (9 bilateral, 9 unilateral) had complete ossification of the carotico-clinoid ligament, Incomplete ossification of the carotico-clinoid ligament was observed in 18 sides (3 bilateral, 12 unilateral) .<sup>19</sup>

In the present study Bilateral carotico clinoid foramen was found in 30 (13.45%) skull bones and unilateral carotico clinoid foramen was found in 53 (23.74%) skull bones. In study of Erturk M, evaluating bony and cadaver specimens together, the total incidence of carotico clinoid foramen was 35.67%, and 20(11.69%) for bilateral carotico clinoid foramina and 41 (23.98%) for unilateral<sup>14</sup>, which was similar to the present findings. In 270 dry human skull study by Azeredo RA, the fusion between the anterior and middle clinoid processes occurred in 17 cases (6.27%), being that in 11 cases (4.05%) occurred bilaterally.<sup>23</sup>



In the Present study, unilateral carotico clinoid foramen in 29 skulls (12.99%) on right side ,and in 24 skulls ( 10.75%) was found on the left side. The incidence of foramen was little higher on the right side than on the left side Similar results were found in Turkish study, by Erturk M showing the incidence of unilateral carotico clinoid foramen higher on the right side 24 (12.28%) than the left side 21 (11.7%).<sup>14</sup>

Ozdogmus et al, out of the 27 complete ossifications, 15 were observed on the right and 12 were observed on the left. Of the 18 incompletely ossified carotico clinoid ligaments, 9 were observed on the right and 9 were on the left.<sup>19</sup>

In the present study complete bilateral carotico clinoid foramen was found in 23 skulls (10.31%) and complete unilateral was found in 16 skulls (7.16%) in which, 9 (4.03%) were on right side and 7 (3.13%) on left side. Incomplete bilateral carotico clinoid foramen was found in 7 skulls (3.13%) and incomplete unilateral carotico clinoid foramen was found in 37 skulls (16.58%); amongst these, 20 skulls (8.96%) was incomplete right side and 17 skulls (7.62%) was incomplete left carotico clinoid foramen.

Gupta N in his study of 70 sides in thirty five skulls examined, carotico clinoid foramen was observed in 14 (20.0%) cases. Out of which complete foramen was in 3 (right side, 4.3%) and partial in 8 (6 right, 2 left, 11.4%).<sup>20</sup>

**Table- 8 Comparative studies on the incidence of the carotico clinoid foramen**

Author	No.of specimens	Carotico clinoid Foramen		
		Unilateral	Bilateral	Total
Keyers (1935)	2187	-	-	27.46%
Azeredo et al. (1988)	270	6 (2.22%)	11 (4.05%)	17 (6.27%)
Inoue et al. (1990)	50	11 (22%)	7 (17%)	18 (36%)
Kee et al. (1997)	73	15.7%	1.4%	17.1%
Cireli et al. (1990)	50	3 (6%)	-	3 (6%)
Deda et al. (1992)	88	6 (6.82%)	7 (7.95%)	13 (14.77%)
Gurun et al. (1994)	198	16 (8.08%)	11 (5.55%)	27 (13.63%)
Erturk et al. (2002)	171	41 (23.98%)	20 (11.69%)	61 (35.67%)
Turkish Population (2004) Results presented for the Turkish population are averages of the results of Turkish authors (Cireli et al. 1990, Deda et al. 1992, Gurun et al. 1994 & Erturk et al. 1999)	507	66 (13.02%)	38 (7.5%)	104 (20.51%)
Present study (2010)	223	16 (7.16%) Complete	23 (10.31%) Complete	39 (17.47%) Complete
		37 (16.58%) Incomplete	7 (3.13%) Incomplete	44 (19.71%) Incomplete
		<b>53 (23.74%) Total</b>	<b>30 (13.45%) Total</b>	<b>83 (37.19%) Total</b>

**Table- 9 Comparison of sellar bridges of present study with other study**

SL NO	SAMPLE SIZE	NO. OF SKULLS SHOWING SELLAR BRIDGES			
		TYPE 1	TYPE 2	TYPE 3	TYPE 4
AKS BILODI	115	1	4	5	3
PRESENT STUDY	223	8	31	44	2

**Table- 10 Comparison of sellar bridges of present study with other study**

SL NO	Total no. of skulls showing sellar bridges	PERCENTAGE OF SKULLS SHOWING SELLAR BRIDGES			
		TYPE 1	TYPE 2	TYPE 3	TYPE 4
AKS BILODI	13	7.69%	30.76%	38.46%	23.07%
PRESENT STUDY	85	9.41%	36.47%	51.76%	2.35%

#### TYPE 1 SELLAR BRIDGE:

The skull showed complete ossified clinoid bar of bone connecting all anterior clinoid process, posterior clinoid process and middle clinoid process, forming a complete osseous ring around the sella turcica.

In the present study 8 skulls (3.58%) showed sellar bridge connecting all the clinoid process bilaterally thus forming a complete osseous ring around the sella turcica , was less when compared to the study by Rani Archana which had 14 skulls (5.6%) with interclinoid osseous bridge connecting all anterior clinoid process, posterior clinoid process and middle clinoid process. In the study done by Bilodi AKS, in 150 dry human skulls wherein he described four types of sellar bridges: In type 1, complete ossified horizontal bar of bone connecting the anterior clinoid process, middle clinoid process and posterior clinoid process was found thus forming a complete osseous ring around sella turcica in one skull only (7.69%) which was a rare variety.<sup>8</sup>

Present study has higher value of bilateral incidence of 3.58%, compared to the study of Rani Archana which noted bilateral incidence in 2(0.8%) of crania, and unilateral in 12(4.8%) crania [3.2% ( $n = 8$ ) Rt; 1.6% ( $n = 4$ ) Lt]. Present study didn't have unilateral type 1 interclinoid bar. Keyes described interclinoid bar, connecting all the three clinoid processes with an incidence of 7.82% in Americans, which was higher when compared to present study. This type of sellar bridge gave rise to two foramina, an anterior interclinoid foramen popularly known as carotico clinoid or arterial foramen through which the internal carotid artery passes, and a posterior interclinoid foramen, called as venous foramen which gives way to the lateral part of circular sinus<sup>22</sup>.

## TYPE 2 SELLAR BRIDGE

The interclinoid bar of bone connecting anterior clinoid process with middle clinoid process forming a complete carotico clinoid foramen through which the internal carotid artery passes.

In Type 2 variety of Bilodi AKS study, three skulls showed interclinoid bar of bone on both sides connecting anterior clinoid process and middle clinoid process forming a complete carotico clinoid foramen bilaterally through which the internal carotid artery passes (23.07%), while in one skull, this interclinoid bar of bone was seen only on right side and absent on left side (7.69%), while there was no interclinoid bar connecting anterior clinoid process and posterior clinoid process.<sup>8</sup> The total Complete foramen was observed in 31 skulls (13.90%), which is higher to the study of Rani Archana and Erturk M with 9 (3.6%) and 14 (4.09%) respectively. Ozdogmus observed 27% complete carotico clinoid foramen which is higher compared to the present study.

In the present study bilateral complete carotico clinoid foramen was found in 15 skulls (6.73%), which is higher than the study of Rani Archana showing 2 (0.8%) bilaterally; and in present study, unilateral complete on right side in 9 skulls (4.03%) and on left side in 7 skulls (3.13%), 4 skulls (1.79%) shown incomplete foramen on right side which was higher to study of Rani Archana 5 (2.0%) on right side and 2 (0.8%) on left side.

### TYPE 3 SELLAR BRIDGE

In the present study, 44 skulls (19.73%) showed incomplete foramen. Bilateral incomplete foramen was found in 7 skulls (3.13%), unilateral incomplete foramen was found in 20 skulls (8.96%) on right side and on left side was found in 17 skulls (7.62%). The incomplete foramen incidence was slightly higher on right side than on left side.

In Type 3, incomplete carotico clinoid foramen on both sides with a gap of 3mm on both sides in four skulls (30.76%). Another skull showed incomplete carotico clinoid foramen on one side i.e., on right side only (7.69%).<sup>8</sup>

Incomplete carotico clinoid foramen was observed in 18 sides (3 bilateral, 12 unilateral) Of the 18 incompletely ossified carotico clinoid ligaments, 9 were observed on the right and 9 were on the left by Ozdogmus.<sup>19</sup>

### TYPE 4 SELLAR BRIDGE

In the present study only 2 skulls showed sellar bridge between anterior clinoid process and posterior clinoid process bilaterally.

In study of Bilodi AKS, Type 4 variety, two skulls showed interclinoid bar of bone connecting anterior clinoid process and posterior clinoid process on both sides (15.38%), and other skull showed on left side only (7.69%). There was no skull showing horizontal bar of bone connecting anterior clinoid process and middle clinoid process.<sup>8</sup>

Various theories have been postulated to explain the formation of these interclinoid osseous bridges. Dyke found the ossification in the dura between the anterior, middle and posterior clinoid processes in 2–3% of skulls. Schaeffer stated that a bony bridge connecting the anterior and posterior clinoid processes is a persisting vestige of the primitive cranial wall. Du Boulay mentioned that ligaments around the sella may get calcified at an early age. Possibly the ossification of the ligament is only an extension of the normal ossification of the anterior and posterior clinoid processes and not an ossification of the type that sets in the hyaline cartilage of the larynx, late in life. Kier postulated that osseous interclinoid ligament was a developmental anomaly and showed the existence of the foramen that is formed by this ligament in fetus and infant skull. Lang reported that sellar bridges are laid down in cartilage at an early stage of development and ossify in early childhood. According to Cederberg et al. the degree of calcification of the interclinoid ligament does not vary with gender but shows a weak positive correlation with age.<sup>22</sup>

The sphenoid bone is composed of pre-sphenoidal and post-sphenoidal parts until the eighth month of intrauterine life. The pre-sphenoidal part is located at the rostral side of the tuberculum sellae. The post-sphenoidal part is composed of a sella turcica, a greater wing and a pterygoid process of sphenoid bone. In approximately the fourth month of fetal life, ossification centers appear on both sides of the sella turcica. Hochstetter's conjecture that the carotico-clinoid foramina are already present in the embryological development concurs with that of Bergerhoff. Bergerhoff's view, that the foramina ossify during the first year post-natally, can be contradicted, because

completely ossified carotico clinoid foramina as well as sella bridges have been demonstrated in new-born infants . The presence of sella bridges during intracartilaginous ossification have been reported in embryos whose crown–rump length (CRL) was between 21.4 mm and 104.0 mm. Lang also reported the presence of sella bridges in embryos and described them as the fusion of the distal parts of the bony projections that were ossified from the cartilaginous tissue, but not because of the ossification of dura mater in that location.<sup>12</sup>



## CONCLUSION

The variations in clinoid processes of the sphenoid bone should be carefully studied by all neurosurgeons, especially for approaches to the cavernous sinus. The presence of an osseous bridge between the tip of the anterior clinoid process and the middle or posterior clinoid process makes removal of the anterior clinoid process difficult and increases the risk of rupturing or tearing the ICA, leading to fatal cerebral infarction, especially when aneurysm is present. It also makes it impossible to retract or mobilize the cavernous segment of the ICA even after releasing the proximal and distal dural rings. Therefore, preoperative recognition of the carotico clinoid foramen by imaging studies has great clinical significance when approaching surgical lesions in the region.

For the present study, 223 dry unknown human skull were obtained from north interior Karnataka region collected in the department of Anatomy of BLDEU's Shri B.M.Patil Medical College Hospital and Research centre Bijapur.

The human skull were studied for the carotico clinoid foramen with various parameters. Values were obtained and statistically analyzed.

In the present study, 83 skulls (37.19%) showed carotico clinoid foramen which was higher compared to previously done studies. Bilateral and unilateral carotico clinoid foramen in the present study showed higher values compared to previously done Indian studies.

Complete or partial removal of the anterior clinoid process is an important step in the superior approach to the cavernous sinus, management of carotid-ophthalmic, giant internal carotid artery and paraclinoid aneurysms. In the case of an aneurysm extending into the cavernous sinus or over the anterior clinoid process combined with a completely ossified carotico clinoid foramen, removing the anterior clinoid process may have high risk. Therefore, detailed knowledge of the type of ossification of the carotico clinoid ligament can be necessary to increase the success of surgery.

This study presents various features of the clinoidal region with special emphasis on the carotico clinoid foramen on bony specimens of north interior Karnataka population as a guide for neurosurgeons to provide information which is immensely beneficial to reduce mortality and morbidity in surgical approaches.

:

## SUMMARY

In the present study we tried to determine the prevalence of carotico clinoid foramen in the sample size taken. For the present study 223 dry unknown human skull were taken from north interior Karnataka region collected in the department of Anatomy of BLDEU's Shri B.M.Patil Medical College Hospital and Research centre Bijapur.

Carotico clinoid foramen was found in 83 skulls (37.19%), amongst these, 39 (17.47%) skulls the carotico clinoid foramen was forming a complete foramen and in 44 (19.71%) skulls the carotico clinoid foramen was forming incomplete foramen, which is high compared to previously done studies and knowledge of the prevalence of this foramen will help the neurosurgeons for pre-operative scanning and precautions to be taken to prevent fatal complications during surgery.

The osseous carotico clinoid foramen is an underestimated structure which has important neuronal and vascular relations and is both clinically and surgically important. Knowledge of the detailed anatomy of the carotico clinoid foramen and its content can increase the success of diagnostic evaluation and surgical approaches to the region.

## BIBLIOGRAPHY

1. Avci E, Bademci G, Ozturk A. Microsurgical Landmarks for Safe Removal anterior clinoid process. *Minim Invas Neurosurg* 2005; 48: 268-72
2. Das S, Suri R, Kapur V .Ossification of caroticoclinoid ligament and its clinical importance in skull based surgery. *Sau Paulo Med J* 2007 ;125:351-3
3. Seoane E, Rhoton AL, Oliveira E .Microsurgical anatomy of the dural collar (carotid collar) and rings around the clinoid segment of the internal carotid artery. *Neurosurgery* 1998;42:869–86.
4. [http://en.www.bartleyby.com/bartley/osteology,the skull-the sphenoid bone](http://en.www.bartleyby.com/bartley/osteology,the%20skull-the%20sphenoid%20bone) accessed on 9 Aug 2010.
5. Henry Hollinshead W, Cornelius Rosse . The cranium.In: *The head and neck*. Philadelphia :Harper & Row Publishers;1985;p 46-7.
6. [http://en.wikipedia.org/wik/anterior clinoid process](http://en.wikipedia.org/wik/anterior%20clinoid%20process) accessed on 9 Aug 2010.
7. Scheuer L, Black S. The head, neck and dentition.In:*Developmental Juvenile Osteology*. California: Academic press; 2000;p188-200.

8. Bilodi AKS. Study of sella turcica and associated anomalies in human skulls, Journal of Institute of Medicine 2005;27: 3-6.
9. Patnaik VVG, Singla RK, Bala S .Bilateral foramen clinoido- caroticum and interclinoid bars-a report of 2 cases. J Anat Soc India 2003;52:69–70.
10. Skrzat J, Szewczyk R, Walocha J .The ossified interclinoid ligament. Folia Morphol 2006;65:242–5.
11. Ozdogmus O, Saka E, Tulay C, Gurdal E, Uzun I, Cavdar S .Ossification of interclinoid ligament and its clinical significance. Neuroanatomy 2003;2:25–7.
12. Peker T, Anıl A , Gülekon N, Turgut HB, Pelin C , Karaköse M.The incidence and types of sella and sphenopetrous bridges. Neurosurg Rev 2006;29: 219–23.
13. Suazo GIC, Zavando MDA ,Smith RL. Ossification of the Sella Turcica and Clinoid Ligments, Case Report, Morphological Study and Literature Review .Int. J. Morphol 2008; 26:799-801.
14. Erturk M, Kayalioglu G, Govsa F .Anatomy of the clinoidal region with special emphasis on the caroticoclinoid foramen and interclinoid osseous bridge in a recent Turkish population. Neurosurg Rev 2004;27:22–6.

15. Huynh LP, Natori Y, Sasaki T. Surgical anatomy of the anterior clinoid process. J Clin Neurosci 2004 ;11:283-7.
16. Kim JM, Bak KM, Kim CH, Kim NK. Clinical Implication of the Clinoid(C5) Internal Carotid Artery and Dural Rings-A Microsurgical Anatomy J Korean Neurosurg Soc 1998; 27:1337-43.
17. Alleyne CH, Coscarella E, Spetzler RF, Walker MY, Patel AC,Wallace RC.Microsurgical Anatomy of the Clinoidal Segment of the Internal Carotid Artery, Carotid Cave, and Paraclinoid Space. Barrow Quarterly 2002;18: 63-9.
18. Rengachari SS, Ellenbogen RE .Intracranial aneurysm. In: Principles of Neurosurgery . 2<sup>nd</sup> ed. USA :Elsevier Mosby ;2005.p 222-5.
19. Ozdomuos O, Saka E, Tulay C, Gurdal E, Uzun I, Cavdar S. The anatomy of the carotico-clinoid foramen and its relation with the internal carotid artery. Surg Radiol Anat 2003; 25:241–6.
20. Gupta M, Ray B, Ghosh S . A study on anterior clinoid process and optic strut with emphasis on variations of caroticoclinoid foramen. Nepal Med Coll J 2005;7:141–4.

21. Narolewski R. Significance of anatomic variants of bony surroundings of the internal carotid artery and their significance for lateral surgical approaches to the cavernous sinus. *Ann Acad Med Stetin* 2003;49:205-29.
22. Archana R, Anita R, Jyoti C, Punita M, Rakesh D. Incidence of osseous interclinoid bars in Indian population. *Surg Radiol Anat* 2010;32:383–7.
23. Azeredo RA, Liberti EA, Watanabe IS. Anatomical variations of the clinoid process of the human sphenoid bone. *Arq Cent Estud Curso Odontol* 1989;26:9-11.
24. Kim JM, Romano A, Sanan A, Loveren VHR, Keller JT .Microsurgical anatomic features and nomenclature of the paraclinoid region. *Neurosurgery* 2000;46:670,682.
25. Cares HL, Bakay L. The clinical significance of the optic strut. *J. Neurosurg* 1971;34:355-64.
26. Becktor JP, Einersen S, Kjaer I. A sellar turcica bridge in subjects with severe craniofacial deviations. *European Journal of Orthodontics* 2000; 22:69-74.
27. [http://en.wikipedia.org/wiki/caroticoclinoid\\_foramen](http://en.wikipedia.org/wiki/caroticoclinoid_foramen) accessed on 9 Aug 2010.

28. Lee HY, Chung IH, Choi BY .Anterior clinoid process and optic strut in Koreans. Yonsei Med J 1997;38:151-4.
29. Paul S, Das S. Anomalous posterior clinoid process and its clinical importance.Colomb Med 2007; 38: 301-4.
30. McLachlan, Williams ED, Doyle FH. Applied anatomy of the pituitary gland and fossa.A radiological and histopathological study based on 50 necropsies. Br. J. Radiol 1968; 41: 782-8.
31. Yang Y, Hongjie W , Yi S, Zenghua W, Shugan Z , Jiangang W. Extradural Anterior Clinoidectomy as an Alternative Approach for Optic Nerve Decompression: Anatomic Study and Clinical Experience. Neurosurgery 2006 ;59:253,262.
32. Keyers JEL .Observations on four thousand optic foramina in human skulls of known origin. Arch Ophthalmol 1935; 13:538-68.
33. Ananthi KS, Agarwal R, Kothandaraman U. Sellar bridge. J Anat Soc India 2010;59:24-6.
34. Dujardin TAC, Duparc F, Ali N, Laquerriere A, Muller JM, Freger P. Embrology of the internal carotid artery dural crossing: apropos of a continuos series of 48 specimens. Surg Radiol Anat 2005; 27:495-501.



35. Hunnargi S, Ray B, Pai SR, Siddaraju KS. Metrical and non-metrical study of anterior clinoid process in South Indian adult skulls. *Surg Radiol Anat* 2008; 30:423-28.

36. Mc Minn RMH. Osteology of skull. In: *Last's Anatomy Regional & Applied*. 9th Edn. Edinburgh, London, Churchill Livingstone;1994;p 643-66.

# ETHICAL CLEARANCE CERTIFICATE

BLDE UNIVERSITY's  
SHRI B.M.PATIL MEDICAL COLLEGE,HOSPITAL AND  
RESEARCH CENTRE  
BIJAPUR

**PROFORMA**

**OBSERVATIONS OF CAROTICO CLINOID FORAMEN**

S.NO	COMPLETE CAROTICO CLINOID FORAMEN		INCOMPLETE CAROTICO CLINOID FORAMEN		PERCENTAGE
	RIGHT	LEFT	RIGHT	LEFT	

Signature of P.G

Signature of Guide

## Master Chart

SKULL NO	NORMAL	NORMAL	IC	IC	C	C	SB TYPE
	RIGHT	LEFT	RIGHT	LEFT	RIGHT	LEFT	
Skull 1	A	A	A	A	A	P	TYPE 2
2	A	A	A	A	A	P	TYPE 2
3	A	A	P	A	A	A	TYPE 3
4	A	A	A	A	A	A	
5	A	A	A	A	A	A	
6	A	A	A	A	A	A	
7	A	A	A	A	A	A	
8	A	A	A	A	A	A	
9	A	A	A	A	A	A	
10	A	A	A	A	A	P	TYPE 2
11	A	A	A	A	P	P	TYPE 2
12	A	A	A	A	P	P	TYPE 2
13	A	A	A	A	A	A	
14	A	A	A	A	A	A	
15	A	A	A	A	A	A	
16	A	A	A	A	A	A	
17	A	A	A	A	A	A	
18	A	A	A	A	A	A	
19	A	A	A	A	P	A	TYPE 2
20	A	A	A	A	A	A	
21	A	A	A	P	A	A	TYPE 3
22	A	A	A	P	A	A	TYPE 3
23	A	A	A	A	P	P	TYPE 2
24	A	A	A	P	A	A	TYPE 3
25	A	A	A	A	P	P	TYPE 2
26	A	A	A	P	A	A	TYPE 3
27	A	A	A	A	A	A	
28	A	A	A	A	A	A	
29	A	A	A	A	A	A	
30	A	A	A	A	A	A	
31	A	A	A	A	A	A	
32	A	A	A	A	A	A	
33	A	A	A	P	A	A	TYPE 3
34	A	A	A	P	A	A	TYPE 3
35	A	A	A	A	A	A	

36	A	A	A	A	A	A	
37	A	A	A	A	A	A	
38	A	A	A	A	A	A	
39	A	A	A	A	A	A	
40	A	A	A	A	P	P	TYPE 2
41	A	A	A	A	P	P	TYPE 2
42	A	A	A	A	A	A	
43	A	A	A	A	P	P	TYPE 2
44	A	A	A	A	A	A	
45	A	A	A	A	A	A	
46	A	A	A	A	A	A	
47	A	A	A	A	A	A	
48	A	A	P	A	A	A	TYPE 3
49	A	A	A	A	A	A	
50	A	A	A	A	A	A	
51	A	A	P	A	A	A	TYPE 3
52	A	A	A	A	A	A	
53					P	P	TYPE 1
54	A	A	A	A	A	A	
55	A	A	A	A	A	A	
56	A	A	A	A	A	A	
57	A	A	A	A	A	A	
58	A	A	A	A	A	A	
59	A	A	A	A	A	A	
60	A	A	A	A	A	A	
61	A	A	A	A	A	A	
62	A	A	P	A	A	P	TYPE 2,3
63	A	A	A	A	A	A	
64	A	A	A	A	A	A	
65	A	A	A	A	A	A	
66	A	A	A	A	P	A	TYPE 2
67	A	A	A	A	A	A	
68	A	A	A	A	A	A	
69	A	A	A	A	A	A	
70	A	A	A	A	A	A	
71	A	A	A	A	P	P	TYPE 2
72	A	A	A	A	A	A	
73	A	A	A	A	A	A	
74	A	A	A	A	A	A	

75	A	A	A	A	A	A	
76	A	A	A	A	A	A	
77	A	A	A	A	A	A	
78	A	A	A	A	A	A	
79	A	A	A	A	A	A	
80	A	A	A	A	A	A	
81	A	A	A	P	A	A	TYPE 3
82	A	A	A	A	A	A	
83	A	A	A	A	A	A	
84	A	A	A	A	A	A	
85	A	A	P	A	A	P	TYPE 2,3
86					P	P	TYPE 1
87	A	A	P	P	A	A	TYPE 3
88	A	A	A	A	A	A	
89	A	A	A	A	A	A	
90	A	A	A	A	A	A	
91	A	A	A	A	A	A	
92	A	A	A	A	A	A	
93	A	A	A	A	A	A	
94	A	A	A	A	A	A	
95	A	A	A	A	A	A	
96	A	A	A	A	A	A	
97	A	A	A	A	P	P	TYPE 2
98	A	A	A	A	A	A	
99	A	A	A	A	A	A	
100	A	A	A	A	A	A	
101	A	A	A	A	A	A	
102	A	A	A	A	A	A	
103	A	A	A	A	A	A	
104	A	A	A	A	A	A	
105	A	A	A	A	A	A	
106	A	A	A	A	A	A	
107	A	A	P	A	A	A	TYPE 3
108	A	A	A	A	A	A	
109	A	A	A	A	A	A	
110	A	A	A	A	A	A	
111	A	A	A	P	A	A	TYPE 3
112	A	A	A	P	A	A	TYPE 3
113	A	A	P	P	A	A	TYPE 3

114	A	A	A	A	A	A	
115	A	A	P	A	A	P	TYPE 2,3
116	A	A	A	A	A	A	
117					P	P	TYPE 1
118	A	A	A	A	A	A	
119	A	A	A	A	P	A	TYPE 2
120	A	A	A	A	P	A	TYPE 2
121	A	A	A	A	P	P	TYPE 2
122	A	A	P	A	A	A	TYPE 3
123	A	A	A	A	A	A	
124	A	A	A	P	A	A	TYPE 3
125	A	A	A	A	A	P	TYPE 2
126	A	A	A	A	A	A	
127	A	A	A	A	A	A	
128	A	A	A	A	A	A	
129	A	A	A	A	A	A	
130	A	A	A	A	A	A	
131	A	A	A	A	A	A	
132	A	A	P	A	A	A	TYPE 3
133	A	A	A	A	A	A	
134	A	A	A	A	A	A	
135	A	A	P	P	A	A	TYPE 3
136	A	A	A	A	A	A	
137	A	A	A	A	A	A	
138					P	P	TYPE 1
139	A	A	A	A	A	A	
140	A	A	A	A	P	P	TYPE 2
141	A	A	P	P	A	A	TYPE 3
142	A	A	A	A	A	A	
143	A	A	A	A	A	A	
144	A	A	A	A	A	A	
145	A	A	A	A	A	A	
146	A	A	A	A	A	A	
147	A	A	A	A	A	A	
148	A	A	A	A	A	A	
149	A	A	A	A	A	A	
150	A	A	P	P	A	A	TYPE 3
151	A	A	A	P	A	A	TYPE 3
152	A	A	P	A	A	A	TYPE 3

153	A	A	A	P	A	A	TYPE 3
154	A	A	A	A	P	A	TYPE 2
155	A	A	A	A	A	A	
156	A	A	A	A	A	A	
157	A	A	A	A	A	A	
158	A	A	A	A	A	A	
159	A	A	A	A	A	A	
160	A	A	A	A	A	A	
161	A	A	A	A	A	A	
162	A	A	A	A	A	A	
163	A	A	A	A	A	A	
164	A	A	A	A	A	A	
165					P	P	TYPE 1
166	A	A	A	A	A	A	
167	A	A	A	A	P	A	TYPE 2
168	A	A	A	A	A	A	
169	A	A	A	A	A	A	TYPE 4
170	A	A	A	A	A	A	
171	A	A	A	A	A	A	
172	A	A	A	A	A	A	
173	A	A	P	A	A	A	TYPE 3
174	A	A	A	P	A	A	TYPE 3
175	A	A	A	A	A	A	
176	A	A	P	A	A	A	TYPE 3
177	A	A	A	A	A	A	
178	A	A	P	A	P	A	TYPE 2/3
179	A	A	A	A	P	P	TYPE 2
180					P	P	TYPE 1
181	A	A	A	A	A	A	
182	A	A	A	A	P	P	TYPE 2
183	A	A	A	A	A	A	
184	A	A	A	A	A	A	
185	A	A	A	P	A	A	TYPE 3
186	A	A	A	A	A	A	
187	A	A	A	P	A	A	TYPE 3
188	A	A	A	A	A	A	
189	A	A	A	A	P	P	TYPE 2
190	A	A	A	A	A	A	
191	A	A	A	A	A	A	



192	A	A	A	A	P	P	TYPE 2
193	A	A	A	A	P	A	TYPE 2
194	A	A	P	A	A	A	TYPE 3
195	A	A	A	A	A	A	
196	A	A	P	A	A	A	TYPE 3
197	A	A	A	A	A	A	
198	A	A	A	A	A	A	
199					P	P	TYPE 1
200	A	A	P	A	A	A	TYPE 3
201	A	A	A	A	A	A	
202	A	A	A	A	A	A	
203	A	A	P	P	A	A	TYPE 3
204	A	A	A	A	A	A	
205	A	A	A	A	A	A	
206	A	A	P	A	A	A	TYPE 3
207	A	A	A	A	A	A	
208	A	A	A	A	A	A	
209	A	A	A	A	P	A	TYPE 2
210	A	A	P	P	A	A	TYPE 3
211	A	A	A	P	A	A	TYPE 3
212	A	A	A	A	A	A	
213	A	A	P	A	A	A	TYPE 3
214					P	P	TYPE 1
215	A	A	A	P	A	A	TYPE 3
216	A	A	A	A	A	A	
217	A	A	A	A	A	A	
218	A	A	A	A	A	A	
219	A	A	P	A	A	A	TYPE 3
220	A	A	P	A	A	A	TYPE 3
221	A	A	A	A	A	A	
222	A	A	A	A	A	A	
223	A	A	A	A	A	A	TYPE 4