

**“CORRELATION OF FINDINGS OF MRI WITH ARTHROSCOPIC
FINDINGS IN INTERNAL DERANGEMENT OF KNEE JOINT – A
STUDY”**

By

DR. NAVEEN SHEELVANT M.B.B.S

Dissertation submitted to the

B.L.D.E. UNIVERSITY VIJAYAPUR, KARNATAKA



In partial fulfillment of the requirements for the degree of

DOCTOR OF MEDICINE

IN

RADIO-DIAGNOSIS

Under the guidance of

Dr. R. C. PATTANSHETTI M.D.

PROFESSOR, DEPARTMENT OF RADIO-DIAGNOSIS

DR O B PATANSHETTI MS

PROFESSOR & HEAD, DEPARTMENT OF ORTHOPAEDICS.

B.L.D.E.U'S SHRI B. M.PATIL MEDICAL COLLEGE

HOSPITAL & RESEARCH CENTRE, VIJAYAPUR

KARNATAKA

2017

B.L.D.E. UNIVERSITY'S
SHRI B. M. PATIL MEDICAL COLLEGE, HOSPITAL & RESEARCH
CENTRE, VIJAYAPUR

DECLARATION BY THE CANDIDATE

I, **Dr. NAVEEN SHEELVANT**, hereby declare that this dissertation entitled "**CORRELATION OF FINDINGS OF MRI WITH ARTHROSCOPIC FINDINGS IN INTERNAL DERANGEMENT OF KNEE JOINT – A STUDY**" is a bonafide and genuine research work carried out by me under the guidance of **Dr. R C PATTANSHETTI** Professor, Department of Radiodiagnosis, & **Dr. O B PATTANSHETTI** Professor & Head, Department of orthopaedics, B.L.D.E.U's Shri B. M. Patil Medical College Hospital and Research Centre, Vijayapur.

Date:

Place: Vijayapur

Dr. NAVEEN SHEELVANT

Post Graduate Student,

Department of Radiodiagnosis,

B.L.D.E.U's Shri B. M. Patil

Medical College, Hospital &

Research Centre, Vijayapur.

B.L.D.E. UNIVERSITY'S
SHRI B. M. PATIL MEDICAL COLLEGE, HOSPITAL &
RESEARCH CENTRE, VIJAYAPUR

CERTIFICATE BY THE GUIDE

This to certify that the dissertation entitled **“CORRELATION OF FINDINGS OF MRI WITH ARTHROSCOPIC FINDINGS IN INTERNAL DERANGEMENT OF KNEE JOINT – A STUDY”** is a bonafide research work done by **Dr. NAVEEN SHEELVANT**, under my overall supervision and guidance, in partial fulfilment of the requirements for the degree of M. D. in Radiodiagnosis.

Date:

Place: Vijayapur

Dr.R.C.PATTANSHETTI_{M.D.}

Professor

Department of Radiodiagnosis,
B.L.D.E.U's Shri B. M. Patil Medical
College, Hospital & Research Centre,
Vijayapur.

B.L.D.E. UNIVERSITY'S
SHRI B. M. PATIL MEDICAL COLLEGE, HOSPITAL & RESEARCH
CENTRE, VIJAYAPUR

CERTIFICATE BY THE CO-GUIDE

This to certify that the dissertation ENTITLED “**CORRELATION OF FINDINGS OF MRI WITH ARTHROSCOPIC FINDINGS IN INTERNAL DERANGEMENT OF KNEE JOINT – A STUDY**” is a bonafide research work done by **Dr. NAVEEN SHEELVANT**, under my overall supervision and guidance, in partial fulfilment of the requirements for the degree of M. D. in Radiodiagnosis.

Date:

Place: Vijayapur

Dr.O.B.PATTANSHETTY_{M.S.}

Professor and Head

Department of Orthopaedics,

B.L.D.E.U's Shri B. M. Patil Medical

College, Hospital & Research Centre,

Vijayapur.

B.L.D.E. UNIVERSITY'S
SHRI B. M. PATIL MEDICAL COLLEGE, HOSPITAL & RESEARCH
CENTRE, VIJAYAPUR

ENDORSEMENT BY THE HEAD OF DEPARTMENT

This to certify that the dissertation entitled “**CORRELATION OF FINDINGS OF MRI WITH ARTHROSCOPIC FINDINGS IN INTERNAL DERANGEMENT OF KNEE JOINT – A STUDY**” is a bonafide research work done by **Dr. NAVEEN SHEELVANT** under the guidance of **Dr. R C PATTANSHETTI** Professor, Department of Radiodiagnosis & **Dr. O B PATTANSHETTI** Professor & head, Department of orthopaedics, at B.L.D.E.U's Shri B. M. Patil Medical College Hospital and Research Centre, Vijayapur.

Date:

Place: Vijayapur

Dr. BHUSHAN. N. LAKHKAR_{M.D.}

Professor and Head

Department of Radiodiagnosis,

B.L.D.E.U's Shri B. M. Patil Medical

College, Hospital & Research Centre,

Vijayapur.

B.L.D.E. UNIVERSITY'S
SHRI B. M. PATIL MEDICAL COLLEGE, HOSPITAL & RESEARCH
CENTRE, VIJAYAPUR

ENDORSEMENT BY THE PRINCIPAL

This to certify that the dissertation entitled "**CORRELATION OF FINDINGS OF MRI WITH ARTHROSCOPIC FINDINGS IN INTERNAL DERANGEMENT OF KNEE JOINT – A STUDY**" is a bonafide research work done by **Dr. NAVEEN** under the guidance of **Dr.R C PATTANSHETTI** Professor and Head, Department of Radiodiagnosis & **DR O B PATTANSHETTY** Professor and Head, Department of orthopaedics at B.L.D.E.U's Shri B. M. Patil Medical College Hospital and Research Centre, Vijayapur.

Date:

Place: Vijayapur.

Dr. S.P. GUGGARIGUDAR M.S.(ENT)

Principal, B.L.D.E.U's

Shri B. M. Patil Medical College,

Hospital & Research Centre,

Vijayapur.

B.L.D.E. UNIVERSITY'S
SHRI B. M. PATIL MEDICAL COLLEGE, HOSPITAL & RESEARCH
CENTRE, VIJAYAPUR

COPYRIGHT

DECLARATION BY THE CANDIDATE

I hereby declare that the B.L.D.E. UNIVERSITY, VIJAYAPUR, Karnataka shall have the rights to preserve, use and disseminate this dissertation/thesis in print or electronic format for academic/research purposes.

Date:

Place: Vijayapur

Dr.NAVEEN SHEELVANT.

Post Graduate Student,

Department of Radiodiagnosis,

B.L.D.E.U's Shri B. M. Patil Medical

College, Hospital & Research Centre,

Vijayapur.

© BLDE UNIVERSITY VIJAYAPUR, KARNATAKA

ACKNOWLEDGEMENT

I express my deep sense of gratitude and heart felt thanks to & Dr Ramesh pattanshetti. Department of Radio-Diagnosis, Shri B M Patil medical college, Vijapura for therevaluable guidance and constant encouragement in bringing out this dissertation.

I also express my thanks to Dr O.B Pattanshetty. Professor & HOD, Department of orthopedics, Shri B M Patil medical college, Vijapura for his valuable guidance and constant support in bringing out this dissertation.

I express my sincere thanks to Dr Bhushan N Lahakar, Professor & HOD, Department of Radio-Diagnosis, Shri B M Patil medical college, Vijapura for his timely advice and valuable suggestion in preparing this dissertation.

I sincerely thank to Dr. Bhushita Guru, Veeresh. Hanchinal & Satish Patil Assistant Professor, Shri B M Patil medical college, Vijapura for valuable advice in preparing this dissertation.

I also express my thanks to Dr Nayak, Dr Puneet Chamakeri, Dr Rohit Dept of PSM & Mujawar, (Biostatistics) for helping in statistical analysis of this research work. I devote my thesis work to all my respected teachers, colleagues, my wife, parents, Brother and friends with out their help it would have not been possible for me to complete the thesis work successfully.

Lastly my sincere thanks to all the patients, who with their excellent cooperation became the backbone of this dissertation.

Date

Dr Naveen Sheelavant^{MBBS}

Place: Vijayapura

LIST OF ABBREVIATIONS USED

1. ACL	-	Anterior Cruciate Ligament
2. IDK	-	Internal Derangement of Knee
3. LCL	-	Lateral Collateral Ligament
4. LM	-	Lateral Meniscus
5. MM	-	Medial Meniscus
6. MRI	-	Magnetic Resonance Imaging
7. MR	-	Magnetic Resonance
8. MCL	-	Medial Collateral Ligament
9. NMR	-	Nuclear Magnetic Resonance
10. NPV	-	Negative Predictive Value
11. PCL	-	Posterior Cruciate Ligament
12. PD	-	Proton density
13. PPV	-	Positive predictive value
14. RF	-	Radio frequency
15. STIR	-	Short tau inversion recovery
16. T	-	Tesla
17. T1	-	Longitudinal relaxation
18. T2	-	Transverse relaxation
19. TE	-	Time to echo
20. TI	-	Inversion time
21. TR	-	Repetition time

TABLE OF CONTENTS

1. Introduction	1
2. Objective	11
3. Review of literature	12
4. Methodology	49
5. Results	53
6. Discussion	64
7. Summary	79
8. Conclusion	81
9. Bibliography	82
10. Annexures	89

Ethical clearance certificate

Proforma

Consent form

Cases

	LIST OF TABLES	Page No
1	Table No1 Demographic details	2
2	Age wise distribution of various ligament injury in correlation of MRI with arthroscopy.	53
3	Duration of injury in weeks for investigation of MRI & arthroscopy.	54
4	Joint effusion	55
5	Multiple response in injuries of ACL	56
6	Multiple responses of PCL injuries in MRI and arthroscopy.	57
7	Multiple responses in bar diagram with various grade of injury in correlation of MRI with arthroscopy	58
8	Multiple responses of LCL in correlation of MRI with arthroscopy.	59
9	Multiple responses in MM in correlation with arthroscopy.	60
10	Various grades of LM injuries in correlation with MRI and arthroscopy.	61
11	Multiple responses showing osseous lesions.	62
12	Multiple associated knee injuries in MRI and arthroscopy.	63

	LIST OF FIGURES.	Page No
1	MRI knee coil	9
2	Normal Anatomy Of Knee	13
3	Cross sectional anatomy of knee	13
4	Proton density coronal image of anterior vertical portion of the medial collateral ligament.	26
5	Coronal fast spin-echo T2-weighted image of lateral collateral ligament	28
6	Sagittal image of normal meniscus & torn meniscus.	34
7	Normal meniscus in coronal anterior and posterior & meniscal injuries	
8	Hyperintense cystic lesion in medial meniscus.	42
9	Age wise distribution of various ligament injury in correlation of MRI with arthroscopy.	53
10	Duration of injury in weeks for investigation of MRI & arthroscopy.	54
11	Pie diagram shows patients presented with arthroscopy	55
12	BAR Diagram with multiple response in injuries of ACL	56
13	Multiple responses of PCL injuries in MRI and arthroscopy.	57
14	Multiple responses in bar diagram with various grade of injury in correlation of MRI with arthroscopy	58
15	Shows multiple responses of LCL in correlation of MRI with arthroscopy.	59
16	Bar diagram with multiple responses in MM in correlation with arthroscopy.	60
17	Bar diagram showing various grades of LM injuries in correlation with MRI and arthroscopy.	61

18	Pie diagram with multiple responses showing osseous lesions.	62
19	Shows multiple associated knee injuries in MRI and arthroscopy.	63

ABSTRACT

The aim of this study is to compare and correlate magnetic resonance imaging (MRI) and arthroscopic findings in cases of ligament injuries. MRI is currently available means of diagnosis in acute injured painful knee were clinical examination is non conclusive. Because of high negative value and exclude arthroscopy. The purpose of study was to correlate results of MRI in internal derangement of knee with arthroscopy findings, so as to determine the efficacy of MRI in different intrarticular knee injuries.

Aim & Objective of study

- To observe sensitivity and specificity of MRI in detecting cruciate ligament tears, confirmed subsequently with arthroscopy.
- To observe the sensitivity and specificity of MRI in detecting meniscal tears.
- To categorize discrepancies in finding of menisci and cruciate ligament between arthroscopy and MRI.

Methods Of Collection Of Data

- All patients who are clinically suspected of internal derangement of knee presented in department of orthopedics will be evaluated with clinical history and MR imaging in Radio diagnosis dept.
- A surface coil is used, MRI will be performed using a 1.5 tesla MRI scanner (Philips MRI System).Axial, coronal & sagittal T1 ,T2 ,PD & STIR images will be taken.
- Strykararthroscope.

Result

Out of total 33 patients evaluated, most common injury were ACL and PCL injury least Common. Medial meniscus injury is most common than lateral meniscus and grade II & III common in both. MCL outnumbered LCL tear. Osseous lesion & joint effusion were most common associated with injuries. On arthroscopy most of findings correlated very well, however with ACL mid-substance & inferior surface of medial meniscus showed negative predictive value.

Conclusion

MRI is non invasive and reliable investigation for ligament pathologies, It helps in accurate diagnosis of ligament injuries, there by helping in proper management by conservative and surgical treatment.

However arthroscopy still remains gold standard for diagnosis and treatment of the same. False negative cases have been reported in meniscal injuries. So, MRI can be helpful to diagnose the knee injuries reducing there by invasive procedure and assist further management.

Keywords: Medial Meniscus (MM), Lateral Meniscus (LM), Anterior Cruciate Ligament (ACL), Posterior Cruciate Ligament (PCL), lateral collateral ligament (LCL), Medial collateral ligament (MCL).

INTRODUCTION

Trauma to knee joint is significant cause of morbidity in young active individuals especially among athletes, road traffic accidents, military and police recruits. The knee takes a lot of stress, especially when bending. Studies have shown that the forces at the knee joint can reach three times body weight when the knee is bent during activities such as going up stairs, and up to six to seven times body weight when in a full squatting position. Internal derangement of the knee refers to a variety of damaged structures that can be injured within the knee, including meniscal cartilage tears and loose bodies. Ligament tears often present with pain and instability during function. The higher the degree of tearing in the ligament, the greater the amount of instability symptoms. Early detection is vital for proper treatment of intraarticular ligaments, meniscal injury and articular cartilage to prevent further degeneration and mechanical instability by available surgical options. Internal derangement can be diagnosed by various imaging techniques.

USG ultrasonography can detect effusion of knee. It has advantages of being non invasive, readily available and allows good visualization of superficial structures. CT provides valuable information about co-existing joint effusion, chondral and osseous fractures, and CT can locate loose bodies; however it has the disadvantages. Arthroscopy is considered to be gold standard for diagnosis of traumatic intraarticular knee lesions, having accuracy as high as 95% to 98%, however arthroscopy is non-invasive and costly. It requires hospitalization & anaesthesia. Initially arthroscopy was used for diagnosis of various knee pathology. Including diagnosis of meniscal pathology, articular cartilage injury and other pathologies.

MRI is considered to be ideal for primary diagnosis of traumatic knee lesions, as it is non-invasive, fast & can be done on OPD basis. It is free of complications

because of unique ability to demonstrate the nature and extent of injury(3). It has ability of any place without moving patient and a wide variety of MRI pulse sequence can be performed to produce diagnostic quality images.

The objective of present study is to determine accuracy, sensitivity, specificity and concordance of findings of MRI and correlating with arthroscopy in our hospital establishment. Our hospital is 700 bedded tertiary care hospital where daily 10-15 trauma cases are admitted.

Proforma

Table No1 Demographic details

Sl no	OPD/IPD	NAME	AGE/SEX	UNIT	DATE

Clinical parameters

1. Mechanism of injury.
2. Duration of injury.

Clinical findings.

Examination ⁽⁴³⁾

The most common knee complaints typically involve the patellofemoral joint. The knee takes a lot of stress. The higher the degree of tearing in the ligament, the greater the amount of instability symptoms. The knee serves as an important transmission between the ankle and the hip. As such, knee injuries are among the most common complaints encountered in sports medicine.

Palpation

During the examination, it is important to feel the anatomical structures of the knee to see if they have been injured. Damaged structures around the knee are

typically tender to direct pressure. Such structures include the joint surfaces of the knee cap, the femur, the tibia, and the muscles and tendons around the knee.

Patellar mobility is determined by passive medial and lateral movement. The patella can be divided into quadrants. A patella is considered to be hypomobile when it moves less than one quadrant on medial or lateral glide. A hypermobile patella is illustrated by a glide of more than two quadrants (one half of patellar width). Any tilting or rotation of the patella when it is pushed medially or laterally should also be noted. If the medial structures are too tight, the patella will tilt up when pushed laterally. If the lateral structures are too tight, the patella will tilt up when pushed medially.

Range of Motion

Examination of the range of motion at the knee is most easily performed with the patient in lying position. Full knee flexion is considered to be approximately 135° (Range 120-150°).

Hyperextension may occur, especially in women (Range 0° to 15°). A goniometer is a useful joint angle measuring tool that can be used to measure range of motion. The greater trochanter (hip reference), lateral joint line (knee), and lateral malleolus (ankle) are typically used as reference landmarks to check for the range of motion of the knee.

Worrisome signs while testing range of motion include a “locked” knee, which lacks full extension when compared to the contralateral side. This suggests internal derangement may be present, such as a large meniscus tear, a ligament tear, or a loose body/bone chip. Another concerning sign is the inability to extend the knee against gravity while in the lying position.

This is indicative of an injury to the extensor mechanism of the knee. Examples include a quadriceps tendon tear, a patellar fracture, or an injury to the patellar tendon.

Anterior Drawer

Description: The Anterior Drawer test examines for any tearing or laxity of the anterior cruciate ligament (ACL).

Maneuver: Have the patient lying on their back with their knee bent as close to 90° as possible, with the foot resting on the table. Place both hands behind tibia and pull the tibia forward, using a force between 15-20 lbs. The test can also be performed with the foot externally rotated (turned out) to 15°.

Positive Findings: Increased anterior movement of the tibia on the injured side compared to the non-injured side is considered to be a positive test. Up to 3 mm of forward movement of the tibia is considered normal. The Grading for the test is as follows: Grade 1 = 5 mm, Grade 2 = 5 to 10 mm, Grade 3 > 10 mm.

Valgus Test

Description: The valgus stress test checks for medial joint laxity, which usually represents an injury to the medial collateral ligament (MCL).

Maneuver: Have patient lie on their back. Position one hand at the joint line on the outer part of the knee. Have the other hand fixed on the ankle of the affected side. Flex the knee between 20° and 30° and apply a medial or valgus force to the knee. Approximately, 15 to 20 lbs of force should be applied during the test. In order to test the MCL, as well as the posterior medial capsule, the test can be repeated at 0° with the knee in full extension.

Positive Findings: A positive test demonstrates increased medial joint laxity compared to the unaffected side. A Grading system from 1 to 3 can be used which is

based on the amount of joint space opening (Grade 1 = 5 mm, Grade 2 = 5 to 10 mm, Grade 3 > 10 mm).

Varus Test

Description: The varus stress test checks for joint laxity on the outside of the knee, which usually represents an injury to the lateral collateral ligament (LCL).

Maneuver: With the patient lying on their back, position one hand at the joint line on the outer part of the knee. Fix the other hand on the ankle of the affected side. Flex the knee between 20° and 30° and apply a lateral or varus force to the knee. This can be done either by reaching over the top of the knee, or by approaching the patient from the inside aspect of the knee with the leg off to the side. Approximately, 15 to 20 lbs of force should be applied during the test. The test can also be repeated at 0° with the knee in full extension.

Alternate Angle:

Positive Findings: A positive test demonstrates increased lateral joint laxity compared to the unaffected side. A Grading system from 1 to 3 can be used which is based on the amount of joint space opening (Grade 1 = 5 mm, Grade 2 = 5 to 10 mm, Grade 3 > 10 mm).

Posterior Drawer

Description: The posterior drawer test is used to examine the Posterior Cruciate Ligament (PCL).

Maneuver: Have the patient lying on their back with their knee bent as close to 90° as possible with their foot resting on the table. Place both hands behind the tibia, and push backwards on the proximal shin/tibia looking for instability backwards. Use a force between 15-20 lbs

Positive Findings: Upon application of a posterior force to the upper shin, an increase in backwards motion (posterior translation of the tibia) in comparison to the other side is indicative of a positive test.

McMurray's Test

Description: This test checks for meniscal tears and other internal derangement in the knee.

Maneuver: With the patient supine, and their hip and knee bent to 90°, grasp the heel in one hand. Place the other hand over the knee, with the thumb and fingers on the joint line. Gently rotate the tibia with the heel internally rotated with a mild valgus force (for the lateral compartment) and externally rotated with a mild varus force (for the medial compartment).

Alternate View:

Positive Findings: Painful clicking along the joint line or any pain over the joint line that reproduces the patient's symptoms is considered to be a positive test.

Thessaly's Test

Description: This functionally tests meniscus tears in the standing position. Since bending and twisting movements while weight bearing often reproduce pain from meniscus tears, this test recreates the exacerbating movements.

Maneuver: Have the patient stand on one foot with the foot flat on the floor. Hold the patient's hand for support and have them initially bend on the standing knee to 5° of flexion.

Ask the patient to twist at the knee, making sure they are internally and externally rotating at the knee rather than at the pelvis or back. Check for any reproduction of pain symptoms.

Next, have the patient bend the knee deeper to 20°degrees and again actively twists on knee.

Deeper Bend:

Positive Findings: The twisting movement will reproduce pain of a meniscal injury. The pain is typically localized to joint line, and patients typically have more pain with the knee bent at 20° rather than 5°.

MRI evaluation.

- Joint effusion: present/absent.
- Anterior cruciate ligament tear: present/absent, partial/complete.
- Posterior cruciate ligament tear: present/absent, partial/complete.
- Medial collateral ligament tear: present/absent, grade I/II/III.
- Lateral collateral ligament tear: present/absent. Grade I/II/III.
- Medial meniscal tear: present/absent location & type.
- Lateral meniscal tear: present/absent location & type.
- Osseous/osteochondral lesions: present/absent location & type.

Methods and material

Inclusion Criteria⁸⁰

- Patients who had recent knee injuries (within 2 months) to either or both knee joints.

Exclusion Criteria

- Knee injuries other than internal derangement.
- Patients with contraindication to MRI like intracerebral aneurysmal clips, cardiac pacemaker, metallic foreign body in eye, implants in middle ear.

- Patients who had recent knee injury but who on clinical examination had no instability in any plane and negative McMurray test.
- Those patient who refused to undergo arthroscopy.
- Peadiatric patients because of general anaesthesia required for MRI study.
- Claustrophobic patients.

Study sample

32 cases of internal derangement of knee will be evaluated with MRI and arthroscopy to asses diagnostic accuracy.

Method

Each patient of knee injury will be evaluated clinically for evidence internal derangement knee by clinical test.

- These patients where subject to MRI
- Name of MRI unit Philips acheiva 1.5T
- Strength of MRI unit position of patient.
- Planes of MRI study/evaluation.
- Sequence used.

Knee protocol

- Fast spin echo PD and T2W in saggital plane (meniscal and cartilage).
- STIR sequence in coronal plane (marrow)
- T1W coronal images.
- T2W axial images.

Coils : Slightly externally rotate the foot by about 10-15 degrees to stretch the anterior cruciate ligament.

Pack some cushions around the knee to help it stay motion-free. A small cushion under the ankle helps to keep the leg straight.

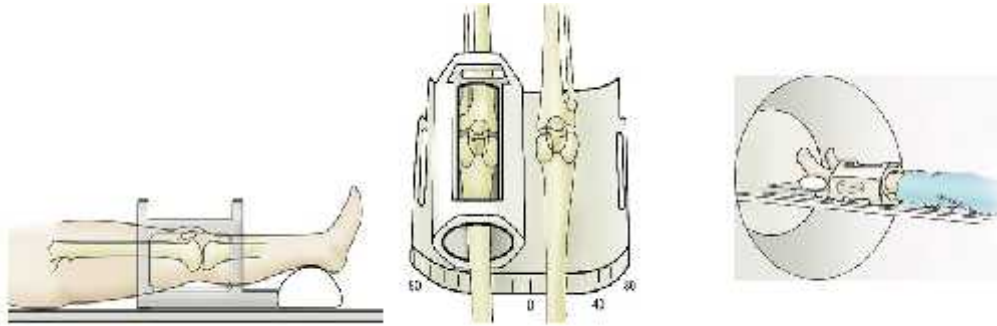


Fig 1 Shows MRI knee coil

Slice thickness 3 mm

Series 1: Axial Proton Density

Enter left or right offset corresponding to distance from centerline of magnet.

Then scan.

Right knee:	offset	R 75
Left knee:	offset	L 75

Series 2: Sagittal Proton Density

- Oblique to the intercondylar notch
- Include all of medial and lateral menisci. Subcutaneous fat medial and lateral to knee joint may be excluded. If more slices are required, increase TR.

Series 3: Coronal Proton Density

- Oblique perpendicular to series 2.
- If more slices are required, increase TR.
- Keep TR > 3000 and ETL < 16
- If there is bone abnormality or soft tissue mass then it may be necessary to increase FOV.

Series 4: Coronal T2 Fat Sat (same as series 3 above)

- Average time required for each patient 45 minutes
- Following the MRI study each patient was subject.
- Preparation of part under aseptic precaution.
- Position: standard position of the knee arthroscopy.
- Anaesthesia: As decided by the anaesthetist and patient.
- Arthroscope stykerarthroscope unit. Instruments punches, scissors and graspers to perform arthroscopic surgery procedure

Portals: Standard Anterolateral and Anteromedial portals. Accessory portals are made according to the need and site of the lesion.

Procedure: Diagnostic arthroscopic evaluation of the knee is a must and should be carried out thoroughly to identify and to know the morphology of the lesion.

Diagnosis :

With above mentioned examination method a double blind study was carried out to assess sensitivity & specificity of diagnosing ligamentous injuries.

AIM OF THE STUDY

1. To compare and correlate the MRI appearances of meniscal and ligamentous injuries with arthroscopy
2. To find out the specificity, sensitivity, positive and negative predictive values of MRI in diagnosing different injuries.
3. To know the role of different sequences in diagnosing these injuries
4. To study limitation of MRI in detecting injuries of the knee

REVIEW OF LITERATURE

NORMAL ANATOMY OF KNEE JOINT

The knee is the largest joint in the body. It is a complex 'hinge' joint made up of the lower end of the femur, the upper end of the tibia and the patella, which slides in a groove on the end of the femur.

The knee joint has three components, the lateral tibio-femoral, medial tibio-femoral and patella-femoral joints. Four bands of tissue, the anterior and posterior cruciate ligaments, and the medial and lateral collateral ligaments connect the femur and the tibia and provide joint stability. Strong thigh muscles give the knee, strength and mobility. The surfaces where the femur, tibia and patella touch are covered with articular cartilage, a smooth substance that cushions the bones and enables them to glide freely. Semicircular rings of tough fibrous-cartilage tissue called the lateral and medial menisci act as shock absorbers and the bones of the knee are surrounded by a thin, smooth tissue capsule lined by a thin synovial membrane which releases a special fluid that lubricates the knee, reducing friction to nearly zero in a healthy knee. It is a synovial modified hinge joint, which also permits a small degree of rotation. In the knee joint, the femoral and tibial condyles articulate, as does the patella and patellar surface of the femur. Fibula does not contribute to the knee joint.

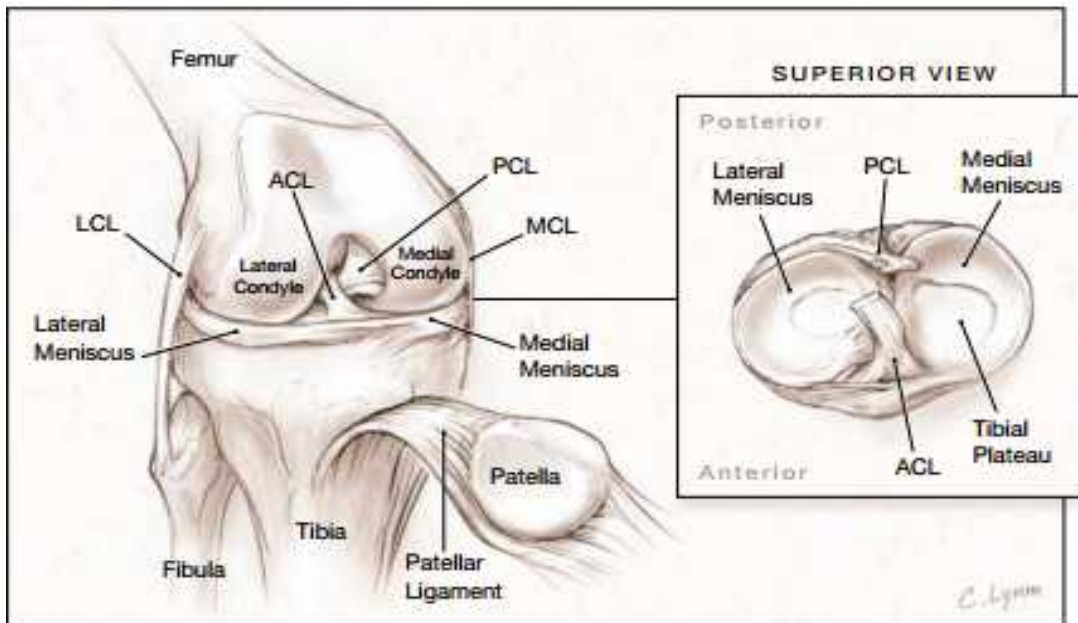


Fig 2 normal anatomy of knee ⁵⁸

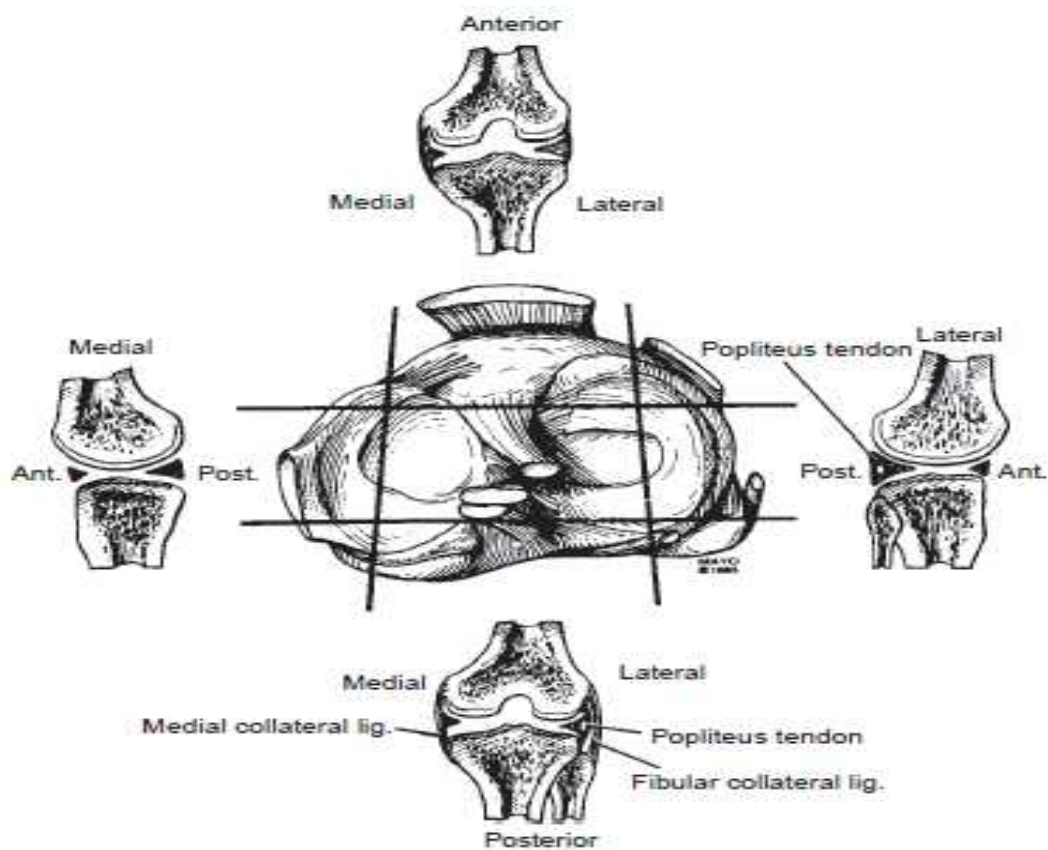


Fig 3 cross sectional anatomy of knee ⁴²

Fibrous capsule: It is attached superiorly to the femur about 1 cm above the articular margin with three special features. It is attached to the margins of the articular surfaces except anteriorly, where it dips downwards. In the anterior part of the capsule there is a large opening through which the synovial membrane is continuous with the suprapatellar bursa.

This bursa extends superiorly three finger breadths above the patella between the femur and quadriceps. Posteriorly, the capsule communicates with another bursa under the medial head of gastrocnemius and often, through it, with the bursa of semimembranosus. Posterolaterally, another opening in the capsule permits the passage of the tendon of popliteus. The lateral expansions extend backwards on each side and downwards to the tibia forming medial and lateral patellar retinacula. On its deep surface, it is attached to periphery of each meniscus and connects it to adjacent margin of head of tibia; this connection is termed as coronary ligament(13).

Ligamentum patellae: It is strong, flat, ligamentous band, about 8 cm in length(13). It is the central portion of common tendon of the quadriceps femoris, which is continued from the patella to the tuberosity of the tibia. The ligamentumpatellae is related to the superficial and deep infrapatellar bursa and also to the infrapatellar pad of fat.

Extra capsular ligaments:

The oblique popliteal ligament: This is an expansion from the tendon of semimembranosus. It runs upwards and laterally blending with the posterior surface of the fibrous capsule. It gets attached to the intercondylar line and the lateral condyle of femur.

- The arcuate popliteal ligament: It has Y shaped fibers, the stem of which is attached to the head of fibula. The posterior limb arches medially over tendon of popliteus to be attached to the posterior border of intercondylar area of tibia. The anterior limb, which is sometimes absent, extends to lateral epicondyle of femur where it is connected with lateral head of gastrocnemius. It is often termed short lateral ligament.
- The fibular collateral ligament: It is a strong, rounded cord, attached above, to the lateral epicondyle of the femur, immediately above the groove for the tendon of the popliteus and below, to the head of the fibula, in front of the apex. The greater part of it is hidden by the tendon of biceps femoris, which embraces and is attached to the ligament. The ligament has no attachment to the lateral meniscus.

Bursae around the Knee Joint: As many as thirteen bursae have been described around the knee joint- four anterior, four lateral and five medial ⁽¹²⁾. These are as under;

Anterior

1. Subcutaneous prepatellar bursa
2. Subcutaneous infrapatellar bursa
3. Deep infrapatellar bursa
4. Suprapatellar bursa

Lateral

- 1) A bursa deep to the lateral head of gastrocnemius.
- 2) A bursa between the fibular collateral ligament and the biceps femoris.
- 3) A bursa between the fibular collateral ligament and the tendon of popliteus.
- 4) A bursa between the tendon of popliteus and the lateral condyle of tibia.

Medial

1. A bursa deep to the medial head of gastrocnemius
2. The anserine bursa is a complicated bursa which separates the tendons of sartorius, gracilis and semitendinosus from one another, the tibia and from the tibial collateral ligament.
3. A bursa deep to the tibial collateral ligament
4. A bursa deep to the semimembranosus.
5. Occasionally a bursa is present between the semimembranosus and the semitendinosus.

RELATIONS OF KNEE JOINT:

Anteriorly: Quadriceps femoris, patellar retinacula and supra patellar retinacula and suprapatellar bursa^(12,13).

Posteriorly: Oblique popliteal ligament, popliteus, popliteal artery with vein posterior and tibial nerve posterior to both; lymph nodes; heads of gastrocnemius, lower end of semimembranosus and semitendinosus^(12,13).

Posteromedially: Sartorius and gracilis tendons^(12,13).

Posterolaterally: Biceps femoris with the common peroneal nerve on its medial side^(12,13).

MOVEMENTS OF KNEE JOINT:

Flexion and extension are the principle movements at the knee. Some rotation is possible when the knee is flexed but is lost in extension. During the terminal stages of extension the large medial tibial condyle screws forwards onto the femoral condyle to lock the joint.

Conversely, the first stage of flexion is unlocking the joint, by internal rotation of the medial tibial condyle, an action performed by popliteus.

The principal muscles acting on the knee are,

Extension: Quadriceps femoris.

Flexion: Predominantly the hamstrings but also gracilis, gastrocnemius and sartorius.

Medial Rotation: Popliteus, semitendinosus and semimembranosus bring about medial rotation of the flexed leg assisted by the sartorius and gracilis.

Lateral Rotation: Lateral rotation of the flexed leg is brought about by the biceps femoris.

During the last 30 degrees of extension, medial rotation of the femur occurs so that the articular surfaces of femur and tibia are completely used up. This is called locking of the knee. Similarly during initial stages of flexion, lateral rotation takes place, which unlocks the knee joint. This is brought about by the action of popliteus. Locking of knee helps the knee to remain in the position of full extension without much muscular effort⁽¹³⁾

MRI ANATOMY AND APPEARANCE OF INJURED LIGAMENTS.

Routine MRI sequences for the evaluation of the knee vary among institutions and scanners. The knee should be imaged in all 3 planes—sagittal, coronal, and axial. At a minimum, scans should include sequences to define anatomy, edema, and cartilage.

Sequences for anatomic definition include spin-echo (SE) and fast spin-echo (FSE), proton-density (PD) sequences. Fluid-sensitive sequences, such as SE/FSE PD fat-suppressed or short tau inversion recovery (STIR), detect edema. Cartilage may be characterized by fat-suppressed FSE PD sequences; fat-suppressed, gradient-echo (GRE) sequences; or spoiled gradient, fat-suppressed sequences.

Coronal images with anatomy-defining and fluid-sensitive sequences optimally demonstrate the medial and lateral supporting structures. Additional useful information may be gleaned from sagittal and axial images of these structures.⁽⁵³⁾

i) THE CRUCIATE LIGAMENTS^(34,46,47).

Anterior Cruciate Ligament is attached to posteromedial aspect of lateral femoral condyle, it extends inferiorly and medially to anterior tibial intercondylar region. It inserts between anterior attachments of menisci. Its function is to prevent anterior displacement of tibia and posterior displacement of femur. The ACL is 11-12 mm thick and appears straight and taut without angulation. On MRI, it appears intermediate to hypointense. ACL is best seen on sagittal images.

Most common mechanism of injury to anterior cruciate ligament is external rotation of femur on a fixed tibia with a valgus force. Other less common mechanisms include hyperextension, internal rotation with maximal extension or anterior translation of tibia produced by a direct force against the back of calf. Clinically, the patients present with hemarthrosis and an audible pop at the time of injury. The anterior cruciate ligament has limited healing capacity, possibly related to heterogeneity of collagen fibers or fibroblast function within a synovial environment. Acute rupture of the ACL ranges from low grade, partial thickness to full thickness and are located most commonly in the mid- to proximal aspect of the ligament. ACL tears occur up to eight times more commonly in females than in males. Indertalwaret al., 1998. A torn ACL fiber has increased T2-weighted signal and an abnormal contour. In some full-thickness tears, an amorphous mass replaces the discrete ACL fibers. Fluid can fill the gap between the fibers of a full-thickness tear. The location of

the tear can be described as proximal, midsubstance, distal, or involving the femoral or tibial attachment.

On MR imaging there are both direct and indirect signs of anterior cruciate ligament injury.

The direct signs include **Inder talwar et al.,⁷¹**

- i. Discontinuity of the fibers of anterior cruciate ligament
- ii. An abnormal contour of anterior cruciate ligament.

The indirect signs include **Inder talwar et al.,⁷¹**

The knee John Haaga 5th edition 2009⁷⁵

Angulation of the posterior cruciate ligament of less than 105 degree,

- i. Anterior tibial translation exceeding 6mm
- ii. Overhanging posterior horn of the lateral meniscus by 2.5mm
- iii. Deep lateral femoral notch exceeding 2 mm in depth
- iv. Second fracture of the lateral tibia involving the middle portion of the lateral fibrous capsule at the menisconfemoral attachment
- v. Chip fracture of the posterior tibia
- vi. Rotary bone contusion pattern.
- vii. Irregularity of the free concave edge of Hoffa's fat pad suggestive of synovitis.

Jamal Yaqoob et al., 2015⁽⁴⁸⁾

The arthroscopic characterization of partial tear is variable and ranges from the presence of some interrupted fibers to a sub totally ruptured ACL. In this study they adopted the approach used by Rubin et al., that is to distinguish complete ACL tear from the rest. Therefore a complete ACL tear on MRI was seen in 11 patients (20%) Discontinuity and non-visualization of ACL fibres were considered predictors

of a complete ACL tear. Only 5% of ACL tears were identified in isolation, while 15% were associated with meniscal tears. ACL tear with midsubstance hyperintense signal was seen in 5 patients (9.2%) while non-visualization of the ACL was identified in 6 patients (11%). They found sagittal T2- weighted images evaluating ACL abnormality with great degree of accuracy, while coronal T2-weighted and PD sequences were helpful in the evaluation of the proximal and distal ACL attachment sites.

In patients with ACL tear subtle peripheral tears may be present in both lateral and medial menisci which should be carefully looked for on imaging, especially posterior horn of medial meniscus. The specificity decreases if a tear is diagnosed when there are only equivocal or probable findings on MRI because these findings usually do not represent a tear at arthroscopic examination.

Amreenbariet al.,2014 Dec ⁽⁴⁹⁾ Out of total 230 patients, ACL tear was most common finding affecting 172 patients (74.8%). According to them diagnosis of partial tears of ACL may not be accurate due to overlying synovial reaction. Anterior tibial subluxation was found in 82 patients, with 34 patients categorized under grade 1 and 48 patients showed a subluxation of grade 2 or more.

Patients with complete ACL tear showed grade 2 or higher ATS, thus suggesting that significant ATS is existent with complete ACL tears. In a study done by Chan et al.,, [16], the presence of torn ACL was established on the basis of measurements of the position of the lateral tibial plateau relative to the lateral femoral condyle on a sagittal image. Proper use of this sign requires little experience yet it provides sensitivity for identifying complete ACL tear.

F. Rayan *et al.*, 2007⁷²

The objective was to compare and correlate clinical, MRI, and arthroscopic findings in the diagnosis of anterior cruciate ligament (ACL) injuries. Out of 26 cases where ACL was found damaged on MRI scan, 22 cases had arthroscopic evidence of ACL injury (84.6%). MRI scan has much better negative predictive value than positive predictive value in anterior cruciate ligament injury diagnosis. When clinical signs and symptoms are inconclusive, performing an MRI scan is likely to be more beneficial in avoiding unnecessary arthroscopic surgery.

Ketan Gupta *et al.*, 2013⁽⁵⁰⁾

Case of ACL study shows MRI has very good sensitivity (100%) which may be due to fact that ACL is relatively easy structure to see on MRI and because of ACL injuries are most common injuries in internal derangement of knee, radiologists are very keen to see whether ACL is injured or not. So there are less chances of interobserver errors in case of ACL injuries.

There was not a single false negative case of ACL in this study.

This study found that the accuracy of the MRI scan in diagnosing internal derangement of knee in decreasing order of ACL, PCL, MM and LM. The routine use of MRI scan to confirm diagnosis is not indicated, as the positive predictive value of the scan is low for all lesions. In the presence of positive clinical signs, proceeding to arthroscopy is recommended. The negative predictive value of a scan was found to be high for all structures of the knee joint and hence a 'normal' scan can be used to exclude pathology, thus sparing patients from expensive and unnecessary surgery and also freeing up valuable theatre time. In this scenario the accurate and careful clinical examination remains the primary necessity in diagnosing internal derangement of knee. From this study, we believe that routine interaction of arthroscopist and

radiologist with retrograde introspection about the diagnosis should be encouraged, In the everyday practice, based on clinical examination that comes first, surgeons decide whether he must proceed to further laboratory tests, MRI, conservative or surgical treatment. In India routine use of MRI for diagnosing every knee injury is not acceptable considering the cost effectiveness of treatment. So in patients with obvious clinical diagnosis by experienced orthopaedic surgeon and role of MRI is debatable.

Dr D S SHETTY *et al*,⁸³ The main indication of MRI is in assessment ligament injuries. However it is useful in demonstrating other knee joint abnormalities involving articular cartilage, bone marrow, synovium, patellofemoral joint and adjacent soft tissue. ACL tear accounted for the major number of cases (36.5%) Hyperintensity in the ligament was noted in 28 cases, discontinuity in 10 cases and nonvisualization of ACL was seen in six cases. In this study ACL tear was the commonest condition accounting for 42 patients (36.5%). Mid substance tear in the form of hyperintensity was noted in 30 patients (71.4%). Hyperintensity in the ligament was seen in 28 patients (61.9%) and discontinuity in 10 patients (23.8%). Six patients (14.3%) with ACL tear showed non-visualisation of ACL. Secondary signs such as PCL buckling, anterior tibial displacement, uncovered meniscus sign and bone contusions assisted in diagnosis in indeterminate case. Associated meniscal tear was seen in 32 patients (76.2) and PD and T2WI revealed abnormality with great degree of accuracy.

John Haaga. *et al*,⁷⁵

Posterior cruciate ligament is intracapsular and extrasynovial. Posterior cruciate ligament originates at lateral aspect of medial femoral condyle, crosses the anterior cruciate ligament and attaches to posterior intercondylar portion of tibia. posterior cruciate ligament is central stabilizer of knee, resisting posterior

displacement of tibia when knee is flexed. The PCL is generally 15-20 mm thick, uniformly hypo intense (black), more curved than the ACL and is in shape of hockey stick appearance when knee is extended on sagittal images⁴⁷.

The PCL is injured by three mechanisms.³⁶

1. Knee hyperextension
2. Kneehyperflexion.
3. Posterior displacement of tibia with knee flexed.

The PCL most commonly tears at the mid portion of the ligament. PCL injuries have a high association with other injuries. Trabecular microfractures, or bone bruises are seen associated commonly. PCL tears are also associated with posterolateral corner injuries

Sonin *et al*, 1995³²

Posterior cruciate ligament; normal and abnormal injury pattern. Acute tear of PCL are usually manifested by thickening of middle portion of ligament with increased signal intensity on both T1WI and T2WI. The mass like quality that an acutely torn ACL exhibits is not seen in acute PCL tear. Also, unlike acute ACL tears, continuity of ligament is maintained in PCL with acute trauma.

Chronic tears of the PCL are difficult to diagnose and image. Because most PCL injuries heal without surgery, the ligament will form fibrous scar in the place of normal ligament. This scar generally has the same signal intensity of native tissue. Secondary signs such as a lax ligament or persistent increased signal may help diagnose chronic PCL tears

JP Singh *et al*, 2004⁶ in there study 10 patients of PCL tears were detected accurately both by MRI and Arthroscopy. The use of MRI to identify PCL tears has proven to be extremely accurate. This might be expected in light of the fact that the

PCL is usually very easily visualized as a homogenous, continuous low-signal structure. Several studies have reported sensitivity, specificity, accuracy, positive predictive value and negative predictive value to be 99-100%. In this study too the sensitivity, specificity, accuracy, positive predictive value and negative predictive value was 100%.

Gupta MK *et al.*,jan 2014⁵¹

MRI showed tears of PCL in 14 cases, out of which only 13 cases showed tears during arthroscopy. MRI showed no tears of PCL in rest 26 cases, out of which tears was found in one during arthroscopy.

These tears were within the vascularized red zone of the meniscus. It is possible that these MRI findings that had the appearance of a tear were healed tears. This area can also be difficult to visualize at arthroscopy, so it is also possible that meniscal tears were present in these areas but were not seen during arthroscopy. Timing of MRI may also be an issue. A substantial delay between injury and MRI may allow the meniscus to heal, but intrameniscal signal may persist, leading to false positive MRI reading. Similarly a delay between MRI and arthroscopic evaluation could allow healing and a false positive result- 17, In the present study, all subjects were symptomatic and MRI was done on average of 10 days before arthroscopic procedure.

Manoj MK *et al.*,January 2014⁴⁶

PCL is usually very easily visualised as a homogenous, continuous low signal structure in MRI all PCL tears were accurately detected and the same confirmed in arthroscopy.

Posterior Cruciate Ligament No of tears identified by Arthroscopy : 4 No of tears identified by MRI : 4 Accuracy of MRI in diagnosing PCL injuries : 100%

MRI should be done in all patients suspected of ligamentous injury, thus preventing unwanted arthroscopies. The orthopedic surgeon must be able to associate the findings on MRI in the decision making before and during arthroscopy. When one menisci or ligament is injured, always look diligently for other derangements. which is producing definite mechanical symptoms will need arthroscopic surgery whatever is shown on MRI.

Jamal Yaqoob *et al*,2015⁴⁸

PCL tear was identified in only 2 patients (3.7%) appearing as hyperintense signal in one patient and ligament discontinuity in the other patient. PCL is difficult to visualize during arthroscopy with intact ACL, and in such cases physical examination is often performed under cover of anesthesia to determine rupture of PCL. MRI findings preceding arthroscopic evaluation are often helpful in PCL evaluation.²² In our study PCL rupture was identified in both patients by arthroscopy.

THE COLLATERAL LIGAMENTS

MEDIAL COLLATERAL LIGAMENTS^{52,53, 75}

The anterior vertical component and the posterior oblique component of the MCL are depicted consistently on coronal T1-weighted or SE/FSE T2-weighted sequences. As seen on the image below, the MCL is seen as a thin, taut, well-defined, low T1/T2-signal structure extending from the medial femoral epicondyle to the medial tibial metaphysis. Surrounded by high T1-weighted signal – fibrofatty tissue throughout its full extent, the MCL is parallel to and closely applied to the medial femoral epicondyle and medial tibial metaphysis. The anterior vertical or superficial component is best visualized at the level of the intercondylar notch in the vicinity of the distal insertion of the ACL.

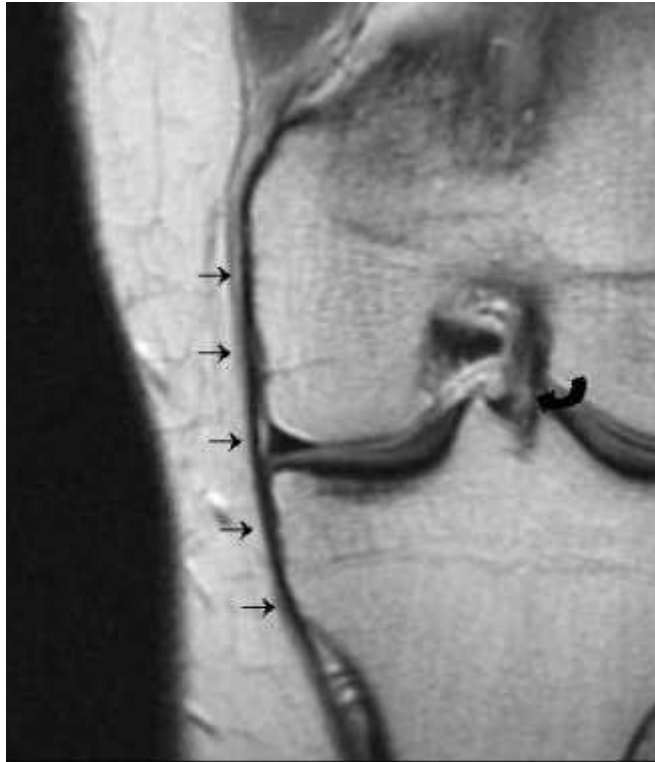


Fig 4 Proton density coronal image shows the anterior vertical portion of the medial collateral ligament as a thin, taut, well-defined, low-signal structure extending from the medial femoral epicondyle to the medial tibial metaphysis (straight arrows). Distal insertion of the anterior cruciate ligament is visualized (curved arrow)⁵³.

Medial collateral ligament are usually caused by valgus stress and are often associated with other derangements. The combination of ACL tear, MCL tear and medial meniscus tear occurs with valgus stress to knee while foot is fixed on ground and is also known as “unhappy triad” or O donoghue’s triad.

The traditional classification of MCL tear is to grade the damage as first through third degree sprain/ tear injuries.

Grade I Lesions are defined as signal intensity superficial to MCL representing edema, with intact MCL fibres.

Grade II lesions in which fluid signal extend partially through MCL, although some fibres remain intact.

Grade III lesions with complete discontinuity of MCL fibres seen along with surrounding edema consistent with a complete rupture⁵⁴.

A chronic MCL tear is seen as an ill-defined, thickened ligament with low T1-weighted and T2-weighted signals.

Lateral collateral ligament (LCL)

The lateral supporting structures are seen on posterior coronal and far lateral sagittal T1-weighted or SE/FSE T2-weighted sequences. The arcuatepopliteofibular and fabello-fibular ligaments are visualized.

Because of its posterior course, the entire LCL rarely is visualized on a single coronal image.

Specialized coronal oblique (parallel to typical course of normal LCL) and sagittal, 1-mm, 3-dimensional, volume-rendered sequences depict the LCL and posterior lateral corner (PLC) structures particularly well. The LCL is seen as a thin, taut, well-defined, low – T1/T2-signal structure extending laterally and posteriorly from the lateral femoral epicondyle to the fibular head.

An acute LCL tear is seen as a serpiginous or lax ligament with discontinuous fibers (or avulsed fibular head), often without significant thickening of the ligament. As previously discussed, LCL tears rarely are isolated, and an LCL tear becomes more likely as associated PCL and cruciate ligament injuries increase in severity.

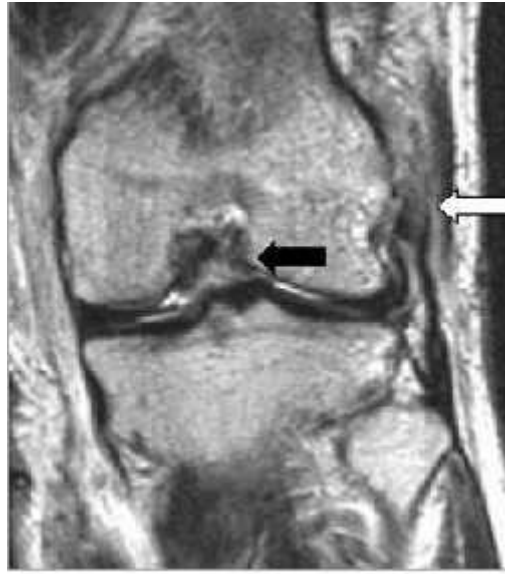

Fig 5 The lateral collateral ligament is lax and its fibers are interrupted at its origin (white arrow) on this coronal fast spin-echo T2-weighted image. Note the associated anterior cruciate tear (black arrow)⁽⁵³⁾.

A chronic LCL tear (seen below) appears as a thickened, low – T1/T2-weighted signal ligament.

Almost all tears of LCL are associated postero-lateral corners of knee. The injuries include damage to structures within the region of LCL, such as capsule, the biceps femoris and the popliteus, as well as to structures else where in the knee, such as cruciate ligaments or lateral tibial rim (segond fractures) ^(47, 53)

The Menisci: The sagittal plane is most important plane in assessing the menisci, with coronal plane providing supportive rather than new information and the axial plane increasing the accuracy of the sagittal and coronal planes when combined. In general, sagittal images optimally show anterior and posterior horns of the medial and the lateral menisci, coronal images help in evaluating the Meniscal bodies and thin axial sections provide an additional view of menisci and their free edges ^(25,30).

Sagittal image: The anterior and the posterior horns of menisci appear as isosceles triangles.

The posterior horn of medial meniscus is twice the size of anterior horn. The anterior and posterior horns of lateral meniscus are of same size. The posterior horn of either menisci should never appear smaller than the anterior horn. On both sides, the menisci appear as flat bands. On lateral side, the more central the slices take on bowtie configuration because of smaller radius of curvature.

Coronal images: Mid portion of the knee produce best images of bodies of both menisci.

They appear triangular and slightly larger laterally than medially. The capsular attachment on the medial side is incorporated in the tibial and medial collateral ligament. A small amount of fat may be interposed between the body of the medial meniscus and the capsule. On posterior coronal cross sections, the posterior horns appear as flat bands. On lateral cross sections, the popliteal tendon courses upward and laterally at 45 degrees. More anteriorly, the anterior horn of lateral meniscus appears as a band like structure. The anterior horn of medial meniscus extends more anteriorly than lateral meniscus^{25,30}.

The medial and lateral menisci, the transverse ligament, and the meniscomfemoral ligament appear homogeneously dark on all pulse sequences. The vascular and avascular zones cannot be distinguished on MRI. The vascularized zone does not demonstrate enhancement with intravenous gadolinium.

TR Madhusudhan et al., 2008⁵⁷

Data from 565 knee arthroscopies performed between 2002 and 2005.

Patients were categorised into three groups on objective clinical assessment:

Those who were positive for either meniscal or cruciate ligament injury [group 1]

Both meniscal and cruciate ligament injury [group 2]

Those with highly suggestive symptoms and with negative clinical signs [group 3].

MRI was requested for confirmation of diagnosis and for additional information in all these patients. Two experienced radiologists reported MRI films.

Clinical and MRI findings were compared with Arthroscopy as the gold standard. A thorough clinical examination performed by a skilled examiner more accurately correlated at Arthroscopy.

MRI added no information in Group 1 patients, valuable information in Group 2 and equivocal in group 3 patients.

A negative MRI did not prevent an arthroscopy. In this study, specificity positive and negative predictive values were more favourable for clinical examination though MRI was more sensitive for meniscal injuries.

De smet and mukherjee *et al.*, 2008 Clinical, MRI and arthroscopic findings with associated with failure to diagnose a lateral meniscus tear on knee MRI performed the study to determine why lateral meniscus tears are missed on MRI. 36 of 189 lateral meniscus tears found at arthroscopy were not diagnosed on original MR interpretation, In recent study sensitivity of 79% for lateral meniscus tear. Because failing to diagnose a lateral meniscal tear did not correlate with failure to diagnose a medial meniscal tear, poor quality MR examination due to patient size or motion are not likely to account for some of missed tears.

Lateral meniscal tear are more likely to be missed if tear involves only one third of meniscus or posterior horn. Longitudinal peripheral tear of posterior horn were most commonly missed tears that could be seen in retrospect

Amreen Abdul Bari *et al.*,⁴⁹

MRI of 230 patients with 71 arthroscopic co-relation. Sensitivity, specificity, PPV and NPV was calculated for ACL it was 87.87, PCL 81.57, MM 93.54, 87.50, LM 77.77, 81.81.

MRI is helpful in diagnosing meniscal and cruciate ligament injuries, arthroscopy still remains gold standard for definitive diagnosis.

Ketan Gupta *et al.*,⁵⁰

Positive predictive value and negative predictive value of ACL was 60% and 100%, Of PCL was 30% and 82%, Of MM was 38% and 100% and of LM is 28% and 77% respectively.

Routine use of MRI scan to confirm diagnosis is not indicated, as the positive predictive value of the scan is low for all lesions. In the presence of positive clinical signs, proceeding to arthroscopy is recommended. The negative predictive value of a scan was found to be high for all structures of the knee joint and hence a 'normal' scan can be used to exclude pathology. Reporting of MRI is dependent on the technician and the Radiologist. It has a long learning curve

Ruth Crawford *et al.*,⁷⁸

MRI is highly accurate in diagnosing meniscal and ACL tears. It is the most appropriate screening tool for therapeutic arthroscopy. It is preferable to diagnostic arthroscopy in most patients because it is faster. From the review, it is clear that the diagnostic performance results of MRI differ for the medial and lateral meniscus and the ACL, although all were above 85% accuracy. The diagnosis of meniscal tears was more difficult due to small peripheral tears. The improved results in the diagnosis of ACL tears in response to 30° flexion and in particular in response to 55° flexion were based on the fact that the anterior cruciate ligament moved further away from the

intercondylar roof with increased knee flexion. MR Imaging of the knee at 55° of flexion and less at 30° of flexion allow an improved diagnosis of injuries to the anterior cruciate ligament as compared to MRI examinations at extension. The diagnosis of meniscal injuries, however, was not superior at either flexion positions compared to commonly performed examinations at knee extension.

Manoj MK *et al*, ⁴⁶

This was a prospective study of 80 patients to compare and correlate the MRI appearances of meniscal and ligamentous injuries and its various types with arthroscopy.

Out of the 80 patients 35(43.75%) showed ACL injury, 23(28.75%) showed medial meniscus tear, 11(13.75%) showed lateral meniscus tear, 4 (5%) showed PCL injury, 4(5%) showed MCL injury and 3(3.75%) showed LCL tear.

MRI is a very useful non-invasive modality having high sensitivity and specificity in detecting IDK. MRI can be considered at par with arthroscopy in the diagnosis of meniscal and cruciate ligament tears.

Is MRI Essential Prior to Arthroscopic Management of Internal Derangement of the Knee?

Khan R.A *et al*, 2010 ³⁴

This study was designed to compare the accuracy of clinical examination and MRI by arthroscopic examination in patients with knee meniscal and ACL injuries. If clinical diagnosis could be as accurate as MRI, the need for this expensive and time consuming investigation could be avoided.

In case of meniscal injuries, clinical examination had sensitivity of 91%, specificity of 22%, positive predictive value of 73%, negative predictive value of 50%

and accuracy of 70% and MRI had sensitivity of 94%, specificity of 9%, positive predictive value of 64%, negative predictive value of 50% and accuracy of 63%.

The accuracy of diagnosis of meniscal and ACL injuries by clinical examination and MRI were arthroscopically compared and found to be fairly matched. It is suggested that routine use of MRI just to confirm the clinical diagnosis of these injuries should be reconsidered.

D. J. DANDY *et al.*,¹¹ The accuracy of the clinical diagnosis of meniscal tears is about 75% to 80%, compared with 88% to 90% for MRI. For lesions of articular cartilage, both the sensitivity and accuracy of MRI are low. MRI is a considerable advance and may well preserve patients from unnecessary operations. A knee which is producing definite mechanical symptoms will need arthroscopic surgery whatever is shown on MRI. If there are no mechanical symptoms MRI may be indicated to exclude any treatable pathology.

Surgeons who are less expert in this specialist field are well advised to request MRI in preference to arthroscopy for a doubtful case, but those who are confident about their management of knee disorders may need neither. MRI is very useful but, as was once said of arthroscopy, it is no substitute for clinical acumen.

iii) THE MENISCI

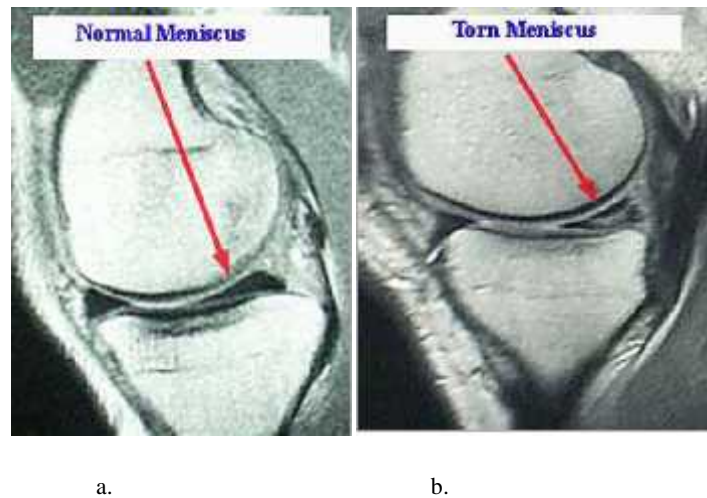


FIG 6 Magnetic resonance imaging scan showing a normal meniscus & torn meniscus.

Abnormal shearing forces may be generated during compression and rotation of knee resulting in meniscal damage. The rotation of femur on a fixed tibia during flexion and extension places the menisci at risk for injury. Clinical signs of meniscal injury include joint pain along the joint line, giving way, clicking, locking of knee in fixed flexion and effusions.

Before embarking upon the pathological states, it is worthwhile considering normal anatomic variants which should not be mistaken for pathological conditions⁽⁴²⁾.

Before embarking upon the pathological states, it is worthwhile considering normal anatomic variants, which should not be mistaken for pathological conditions

NORMAL MENISCAL VARIANTS:

The Discoid Meniscus: It is a congenital anomaly found usually in lateral meniscus. It has a reported incidence of 0.4 to 16.6%(43) . A meniscus is said to be discoid if there is continuity between anterior and posterior side [bow tie appearance]

on five or more contiguous 3mm sagittal MRI section. It presents with symptoms of joint line tenderness, “snapping”, and locking of the knee. The three types of discoid lateral meniscus are complete, incomplete, and the Wrisberg variant. Some investigators include a ring-shaped meniscus’s a fourth type. The complete and incomplete types have a firm, normal posterior tibial attachment and are stable.

Symptomatic patients who have these types of discoid menisci usually are treated with a partial meniscectomy. In contrast, the Wrisberg variant has no posterior coronary or capsular attachments and increased T2signal is present between the meniscus and the capsule, simulating a peripheral tear or a fascicular injury. The Wrisberg variant has the most notable symptoms, with a “snapping” sensation occurring when the posterior horn moves across the femoral condyle during flexion and extension.

A discoid medial meniscus is much less common, with the incidence reported to be 0.12% to 0.6%. On MR, the diagnosis of a discoid meniscus is suggested by identifying either meniscal tissue on three continuous sagittal 5-mm-thick slices, or a meniscal body on coronal images greater than 15 mm wide or extending into the intercondylar notch. The discoid meniscus has an increased incidence of tears and degeneration, likely caused by its abnormal shape, resulting in increased stress on the meniscus. Intrasubstance “grade 2” signal, or abnormal signal not extending to an articular surface, is noted in 24% of discoid menisci and is more common in complete discoid menisci. Typically, this abnormal signal is not considered clinically significant. However, in the population with discoid menisci, some investigators report that this Intrasubstance signal may be significant clinically^(25,44).

Meniscal Ossicles: They are reported in 0.15% of patients and are thought to be either developmental or posttraumatic. These small, ossific foci are found typically in the posterior horn of the medial meniscus and are associated with meniscal tears. They can be symptomatic, or associated with pain and a sensation of locking, clinically simulating a torn meniscus with a flap component. The ossicle follows the signal of bone marrow on MRI^(25,44).

Meniscal frounce: It is a wavy appearance along the free edge of the meniscus. Previously, meniscal frounce was thought to be identified only at arthroscopy, in the presence of joint fluid in the setting of an ACL or medial collateral ligament (MCL) tear. However, a frounce can be seen without a ligament injury. Recently, the Meniscal frounce has been identified with MR imaging when the knee is in 10 degrees of flexion.. The frounce can appear truncated on coronal images and can simulate a tear or degeneration. The incidence at MR is reported to be from 0.2% to 6%. A frounce-like appearance can be seen with meniscal Tears^(25,44).

Meniscal Extrusion: It is measured from the outer meniscal edge to the proximal tibial margin. Extrusion of the medial meniscus more than 3 mm is considered abnormal. This degree of extrusion can be seen in patients who have advanced Meniscal degeneration, and various types of meniscal tears. Although extrusion of the anterior horn or body of the lateral meniscus sometimes is considered a normal variant, others consider extrusion of the lateral meniscus more than 1 mm to be abnormal⁽⁴⁵⁾.

MENISCAL TEARS

The cause of meniscal tears can be divided into two categories.

- a. Increased force on a normal meniscus, usually resulting in longitudinal or radial tears, and

- b. Normal forces on a degenerative meniscus, usually producing horizontal tears in the posterior half of the meniscus.

Tears are more common in the medial meniscus, possibly because the medial meniscus is less mobile, and it bears more force during weight bearing than the lateral meniscus, with 56% of tears involving the posterior horn of the medial meniscus. Tears isolated to the anterior two thirds of the meniscus are uncommon, representing only 2% of medial and 16% of lateral meniscal tears⁴².

Lateral meniscal tears are more common in younger patients (under 30 years old), who have a higher incidence of tears related to sporting events than do older patients. It is likely that this is related to the higher incidence of concomitant ACL tears in this population.

Diagnostic Criteria:

Two criteria for diagnosing a meniscal tear are commonly used⁴

- i. An intrasubstance area of intermediate or high signal intensity that unequivocally extends to the articular surface,
- ii. Abnormal meniscal morphology

Intrasubstance signal: It is graded as follows:

Grade 1: Intrameniscal high signal intensity of irregular or globular appearance that is confined within the meniscus and does not extend to the articular surface.

Grade 2: The signal is linear and does not intersect the inferior or superior articular surface. It may, however, contact the capsular margin at the posterior aspect of the meniscus.

Grade 3: Tears characterized by linear high or intermediate signal intensity that extends to the superior and/or inferior articular surface.

Grade 4: It is sometimes added to indicate a complex tear with multiple components or fragmentation.

Both grade 1 and grade 2 lesions do not represent a tear, but indicate mucinous and mucoidintrasubstance degenerative change and are usually encountered after the third or fourth decade. In children and adolescents, prominent vascularity may resemble grade 1 or grade 2 lesions.

Abnormal Meniscal morphology:

Morphologic changes of the meniscus associated with meniscal tears include blunting of tip of the inner free meniscal edges of the meniscus, displacement of a portion of the meniscus, interrupted appearance of the meniscus and abnormal size of a segment of the meniscus is detached (a bucket handle tear), the remaining peripheral portion appears small and often truncated. The displaced portion usually lies within the intercondylar notch beneath the PCL.

Coronal views are helpful in further identifying such displaced fragments. An abrupt change in contour of the meniscus, known as the ‘notch’ sign, is an important indicator of a meniscal tear. Although the normal meniscal flounce can simulate it, the presence of abnormal intrameniscal signal makes the notch sign a more definite indicator of a meniscal tear⁽⁴⁶⁾.

Classification of tears:

1. Horizontal tears
2. Vertical tears
3. Complex tears

1.Horizontal Tears: Horizontal tears are parallel to the tibial plateau and divide the meniscus into upper and lower segments. The Cleavage type extends to the apex and divides the menisci into upper and lower halves. They are referred to as ‘fish mouth’

tears. In the Non cleavage type, tear extends to the superior and inferior articular surface of the meniscus.

Horizontal tears are most common within the posterior horn of the medial meniscus. Linear horizontally oriented grade II signal intensity is sometimes mistaken for complete horizontal tears⁴⁴.

2. Vertical Tears:

They are perpendicular to the tibial plateau, A vertical longitudinal tear occurs between the circumferential collagen fibers parallel to the long axis of the meniscus. Longitudinal tears can be obliquely oriented, but are not parallel to the tibial plateau. Vertical grade III signal intensity located within the peripheral third of the meniscus is considered a peripheral longitudinal tear A vertical radial tear occurs perpendicular to the circumferential collagen fibers and long axis of the meniscus. Radial tears are also known as free edge tears because they involve inner edge of the meniscus. MR images obtained perpendicular to the orientation of radial tear easily demonstrates tear as a small gap or cleft in the meniscus (Cleft sign), which sometimes can be observed to move across the meniscus on successive images (Margin Cleft sign). If the orientation of the imaging plane is in the same direction as a full thickness radial tear, a section through the same plane of the tear will demonstrate the absent meniscus or high signal intensity not representative of meniscus because of volume averaging, which results in the so called Ghost sign. A partial thickness radial tear will demonstrate blunting or abrupt truncation of the apex of the meniscus (truncated triangle sign). The term parrot beak tear has been frequently used to describe a vertical radial tear at the inner edge of the meniscus that curves obliquely across the circumferential collagen fibers⁴⁴.

Root tears: They are full thickness radial tears at the central tibial attachment sites of the menisci & are called the root ligaments. A root tear is reportedly difficult to diagnose because meniscal tissue is noted only on one side of the tear. The diagnosis is easier to make medially because of the close anatomic relationship between the posterior horn of the meniscus and the tibial attachment of the PCL. Normally, on 3-mm sagittal images, the meniscus should be seen on the image medial to the PCL attachment; otherwise, a root tear is suspected and the coronal images can confirm. Lateral meniscal root tears are diagnosed when the posterior horn of the lateral meniscus does not cover the most medial aspect of the posterior lateral tibial plateau on at least one coronal image⁴⁴.

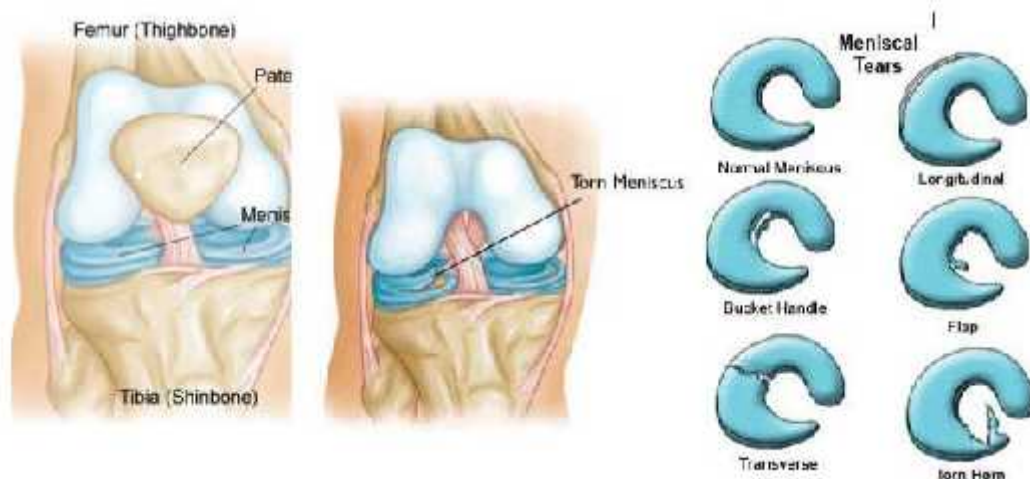


Fig 7 shows normal meniscus in coronal anterior and posterior & meniscal injuries.

Bucket-handle tears: These are displaced longitudinal tears. The displaced fragment often has the appearance of a handle, and the remaining peripheral segment attached to the tibia resembles a bucket – hence the name. Confirmation of this tear is mandatory and can be made by identification of the displaced fragment. The most reliable sign is the finding of a displaced fragment of meniscus in the intercondylar notch,

which can be better seen on coronal images. This sign is associated with a truncated or shortened meniscus on coronal images. On sagittal images, the displaced fragment can be seen lying anterior and parallel to the PCL. This is known as the double PCL sign. These tears may also result in the flipped meniscus sign, double delta sign, or double anterior horn sign, in which the displaced meniscal segment of the posterior horn is located anterior to, on top of posterior to the anterior horn. Helpful clues in these cases include non visualization of the posterior horn of the meniscus, the appearance of a larger anterior horn than posterior horn, or an anterior horn taller than 6mm^{4,44}.

Flap Tears: A flap tear or a displaced flap tear is a term that is used often to describe a short segment, horizontal meniscal tear with fragments either displaced into the notch or into the superior or inferior gutters. Flap tears are the most common type of meniscal tears and may develop following only minimal meniscal trauma of the degenerative meniscus from chronic shear stress. They involve the inner one third to one half of the meniscus with a superior or inferior leaf extension that creates the flap⁽⁴⁶⁾.

3. Complex tears: They either have two or more tear configurations or are not categorized easily into a certain type of tear⁴⁶.

MRI grading of meniscal tears and degenerations:

A grading system based on the signal abnormality correlated with histopathological abnormalities has been developed to understand the significance of increased signal intensity patterns in meniscal abnormalities^{4,44}.

Grade I: Non-articular focal or globular intrasubstance increased signal intensity in the nonarticular portion of the meniscus.

Grade II: Horizontal linear intrasubstance increased signal intensity usually extends from the capsular periphery but does not involve an articular surface.

Grade III: Region of abnormal signal intensity extends or communicates to at least one of the articular surfaces.

MENISCAL CYST

A meniscal cyst is a fluid-filled structure adjacent to a meniscus, which appears as intermediate signal intensity mass on T1-weighted images and hyperintense on T2-weighted images, sometimes lobulated or septated. Meniscal cysts are strongly associated with a horizontal cleavage tear of the meniscus and often a connecting neck between the tear and the cyst can be visualized. The cysts may become fairly large, which is thought to be caused by a ball valve mechanism. They can become symptomatic usually on the medial side, since they may impress on the medial collateral^(4,44).

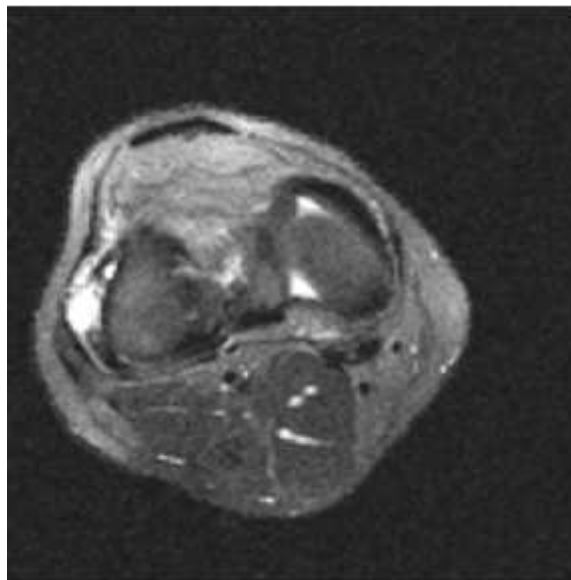


FIG 8 Hyperintense cystic lesion in medial meniscus.

MENISOCAPSULAR SEPERATION

Meniscocapsular separation occurs when the meniscus detaches from the capsular attachments, which is more common medially and usually is associated with other injuries.

Meniscocapsular separation is evaluated best on coronal and sagittal T1- or proton density– weighted sequences for anatomy, and fat-saturated T2-weighted or STIR sequences for pathology. Signs that have been described in meniscocapsular separation include displacement of the meniscus relative to the tibial margin, extension of the tear into the superior or inferior corner of the peripheral meniscus, and an irregular outer margin of the meniscus body on coronal images. Additional signs include increased distance between the meniscus and the MCL, or fluid between the meniscus and the MCL. Overall, the presence of perimeniscal fluid and an irregular meniscal outline are the best predictors of meniscocapsular separation^(4,44).

IV) EXTENSOR MECHANISM AND PATELLAR TENDON

The extensor mechanism of the knee consists of the quadriceps muscle group, quadriceps tendon, patella, patellar retinaculum, patellar ligament, and adjacent soft tissues. Injuries to the extensor mechanism are common and consist of chronic degenerative injuries, overuse injuries, and acute trauma. Overuse injuries typically are seen in high performance athletes, most commonly in sports requiring long distance running or jumping. Cumulative micro trauma produced by repetitive kneeflexion and extension results in focal inflammation⁽⁴⁷⁾.

Acute traumatic injuries occur secondary to direct blunt trauma or excessive tension applied to the extensor mechanism through quadriceps contraction. Patellar fractures are the most common traumatic injury of the knee extensor mechanism⁽⁴⁷⁾

Patellar tendinopathy

Patellar injuries can result from chronic overuse injuries or as a result of acute trauma. Patellar tendonosis, or ‘jumper’s knee’ results from chronic overload on the patellar tendon because of strain from the quadriceps muscle group. Chronic overload results in microtears and focal degeneration, which is characterized histologically by pseudocyst formation, increased fibrocartilage, and myxomatous and hyaline metaplasia. Patellar tendonosis frequently is seen in participants in sports associated with jumping and is associated with mal-alignment^(48,49).

MRI findings consist of focal thickening of the proximal patellar tendon, with increased signal on T1-weighted and T2-weighted images. Edema in the paratenon, infrapatellar fat pad, and subcutaneous adipose tissue is associated with acute patellar tendonitis, which is defined as symptoms of less than 2-week duration and patellar tendon tears. Acute patellar tendonitis is associated with increased intrasubstance signal on T1-weighted and T2-weighted images without tendon thickening⁽⁴⁹⁾.

Patellar tendon tears

They may be partial or complete, and most frequently occur in the proximal inferior patellar tendon. A patellar sleeve fracture represents a cartilaginous avulsion from the lower pole of the patella and is often associated with patellar tendon tears. With complete inferior patellar tendon tears, the patella retracts proximally as a result of the pull of the superior patellar tendon^(5,49).

MRI shows discontinuity of the tendon, demonstrated on fluid-sensitive sagittal T2-weighted and STIR images. MRI findings in partial patellar tendon tears can resemble acute patellar tendonitis. Correlation with a history of acute trauma is useful for specific diagnosis^(5,49).

Quadriceps tendon tear

A tear of the quadriceps tendon is the second most common acute injury to the extensor mechanism. Injury to the quadriceps mechanism (rectus femoris, vastus medialis, vastus intermedius, vastus lateralis, and quadriceps tendon) may be the result of acute trauma caused by rapid deceleration, such as running when the foot is planted, or it may be caused by chronic micro-trauma. In elderly patients or patients who have gout, diabetes, connective tissue diseases, or other systemic conditions, minor trauma may result in quadriceps injury.

MRI is useful in differentiating complete from partial quadriceps tendon tears. With complete tears, discontinuity of the tendon with associated retraction of the proximal remnant usually is visualized best using T2-weighted images. Often, an associated hematoma is seen with heterogeneous signal intensity on T1-weighted images.

Myotendinous strain

Myotendinous strain is a common injury in athletes. The most commonly injured muscles are fusiform muscles that cross two joints. In these muscles, high tensile stress develops when the muscle is forced to lengthen during active contraction, a process termed eccentric contraction. Because the rectus femoris muscle is the only component of the quadriceps muscle group that crosses two joints, it is the most common site for myotendinous strain injuries in the knee extensor mechanism⁴⁹.

MRI findings of strain injuries consist of focal edema centered on the central tendon of the rectus femoris. The presence of a focal hematoma is indicative of a partial myotendinous tear.

Complete myotendinous tears often are recognized clinically, and these patients less frequently undergo MRI⁽⁴⁹⁾.

V) OSSEOUS AND OSTEOCHONDRAL LESIONS

Bone bruise or marrow edema pattern. Bone bruises or marrow edema may be identified with numerous conditions, including trauma, infection, and osteoporosis. Bone bruises related to trauma may be caused by a direct blow, articular compression forces, or avulsion injuries. The extent of marrow edema tends to be more dramatic with compression or direct trauma, compared with avulsion injuries.

Typically, bone bruises are not visible on radiographs. However, these injuries are detected easily on MR images using T1- weighted sequences and either short T1 inversion recovery (STIR) or fat-suppressed T2-weighted sequences. Specific edema patterns are also useful in predicting the mechanism of injury and the associated ligament, tendon, or meniscal involvement⁴⁹.

Tibial plateau fractures

Subtle tibial plateau fractures are overlooked easily on radiographs. The only finding may be a lipohemarthrosis, which can be detected on the cross table lateral radiograph. Displaced tibial plateau fractures are detected easily on radiographs. However, further imaging with CT or MR imaging is required to evaluate fragment position and associated soft-tissue injuries.

CT is adequate for the evaluation of fracture position, articular step-off, and separation of fragments. MR imaging, especially with subtle fractures, can assess the bony injury and associated ligament and meniscal injury more easily⁴⁹.

Segond and reverse Segond fractures

The Segond fracture is a small, avulsion fracture proximal and posterior to the insertion of the iliotibial band on Gerdy's tubercle. The avulsion may occur with

internal rotation and the knee flexed, or with internal rotation and varus stress. The fracture is caused by avulsion of the meniscotibial portion of the middle third of the lateral capsular ligament, with possible associated fractures of the fibular head or Gerdy's tubercle. In the case of severe varus stress, such as in a motor vehicle accident, the entire lateral ligament complex may be disrupted.

Segond fractures have a high incidence of anterior cruciate ligament tears and meniscal injury. MR imaging is ideal for the detection of osseous, meniscal, and ligament injuries. The reverse Segond fracture, much less common, is a medial avulsion of the deep medial collateral ligament attachment on the tibia. The mechanism of injury is felt to be valgus stress with external rotation and is associated with disruption of the posterior cruciate ligament and peripheral medial meniscus tears. When this avulsion is detected on radiographs, MR imaging should be performed to evaluate the associated ligament and meniscal injuries⁽⁴⁹⁾.

Osteochondral lesions

Osteochondral lesions in the knee may be acute or chronic. Acute lesions result from impaction, or rotational or shearing forces. The fracture may involve only cartilage, or cartilage and underlying bone. The fracture line is parallel to the joint line, unlike more conventional fractures that enter the joint vertically or obliquely. Fractures may be impacted, elevated partially or displaced completely and free in the joint^[49]. When imaging osteochondral lesions, radiographs may be useful, but detection and appropriate classification are accomplished more effectively with MR imaging using T1- and T2-weighted or STIR sequences. The axial and sagittal planes are most useful for femoral lesions. Lesions that are minimal (softening, fibrillation, or fissuring) show abnormal signal intensity without elevation or separation. MR signs of unstable lesions include a high signal intensity line between the native bone

and the osteochondral fragment, focal defects, articular fracture, and adjacent subchondral cysts⁽⁴⁹⁾

Spontaneous osteonecrosis of the knee:

Spontaneous osteonecrosis of the knee (SONK): Spontaneous osteonecrosis of the knee was considered classically a condition of vascular insufficiency, leading to bone infarction of the weight bearing surface of the femoral condyle. The condition was seen in older adults. The condition almost always was unilateral and involved most commonly the medial femoral condyle. growing base of knowledge in the literature suggests that a subchondral insufficiency fracture leads to focal osteonecrosis. Similar features have been described in the medial tibial plateau as well⁽⁴⁹⁾.

METHODOLOGY

SUBJECTS:

The objective of present study is to determine accuracy, sensitivity, specificity and concordance of findings of MRI and correlating with arthroscopy in our hospital establishment. Our hospital is 700 bedded tertiary care hospital where daily 10-15 trauma cases are admitted.

MATERIALS AND METHODS:

1. Source of Data:

All cases referred from orthopedic department of shri B M PATIL MEDICAL COLLEGE,VIJAYAPUR for evaluation of traumatic knee.

2. Method of data collection

- Duration of study
- Sample size : 33 cases.

INCLUSION CRITERIA

1. Patient in age group of 18-45 years.
2. Patients who had recent knee injuries (within 2 months) to either or both knee joints.

EXCLUSION CRITERIA

- 1) Patients with contraindication to MRI like intracerebral aneurysmal clips, cardiac pacemaker, metallic foreign body in eye, implants in middle ear.
- 2) Patients who had recent knee injury but who on clinical examination had no instability in any plane and negative McMurray test .
- 3) Patients who had prior arthroscopy or surgical intervention to knee joint.
- 3) Imaging protocols

Each MRI was performed using the MR protocol of 1.5 Tesla on PHILIPS GYROSCAN.

ACHIEVA 1.5T MRI. T1 & T2 weighed sequences were done on coronal and sagittal planes MR films were be read by a senior radiologist. The status of menisci, cruciate ligament, cartilage and subchondral bone were registered.

Study will be evaluated for:

Joint effusion	:	Present/Absent
Anterior Cruciate Ligament tear	:	Present/Absent
Partial/Complete		
Posterior Cruciate Ligament tear	:	Present/Absent,
Partial/Complete		
Medial Collateral Ligament tear	:	Present/Absent
Grade- 1/2/3		
Lateral Collateral Ligament tear	:	Present/Absent
Grade- 1/2/3		
Medial Meniscal Tear	:	Present/Absent
Location & Type		
Lateral Meniscal Tear	:	Present/Absent
Location & Type		
Osseous /Osteochondral lesions	:	Present/Absent

5. Arthroscopy/ Surgery:

Will be carried out in OT by orthopedic surgeon in all cases where indicated for diagnostic or therapeutic purposes.

6. Research hypothesis

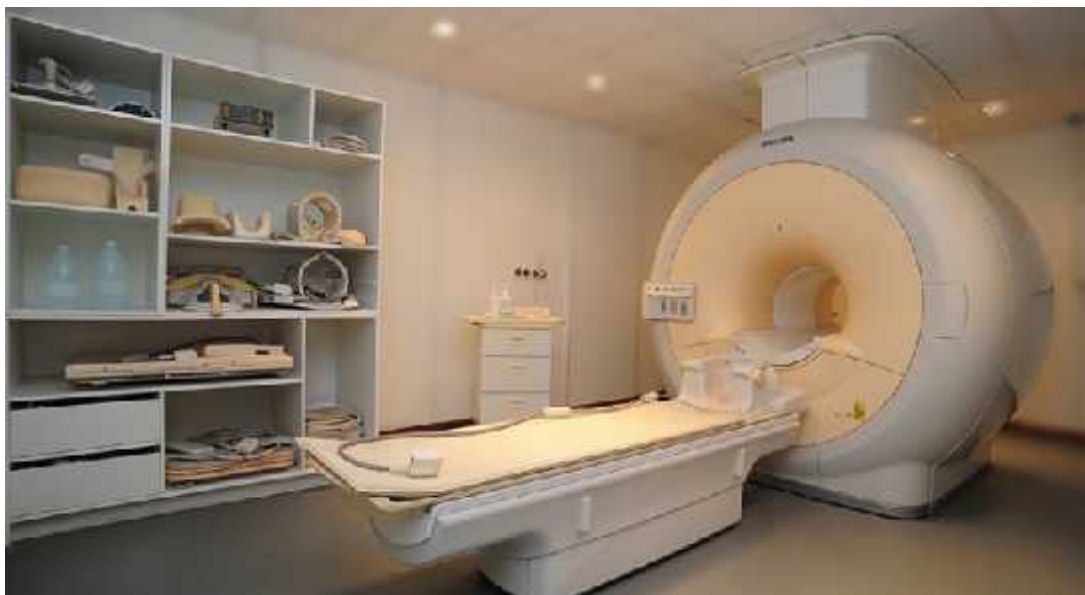7. Findings of MRI of the Knee are well correlated with the arthroscopic findings in patients of trauma to the Knee.

8. Statistical Methods:

- Descriptive Statistical analysis
- 90% confidence interval of findings of MRI and Arthroscopy



Arthroscopy equipments.



MRI Gantry

RESULTS

Table 2 Age wise distribution with multiple responses.

Age	ACL	PCL	MCL	LCL	MM	LM	TOTAL	% of the cases
10-20	1	0	0	0	0	0	1	3.03
20-30	6	0	4	2	2	0	14	42.4
30-40	9	3	1	2	2	1	18	54.5
Above 40	3	0	2	0	2	1	8	24.24

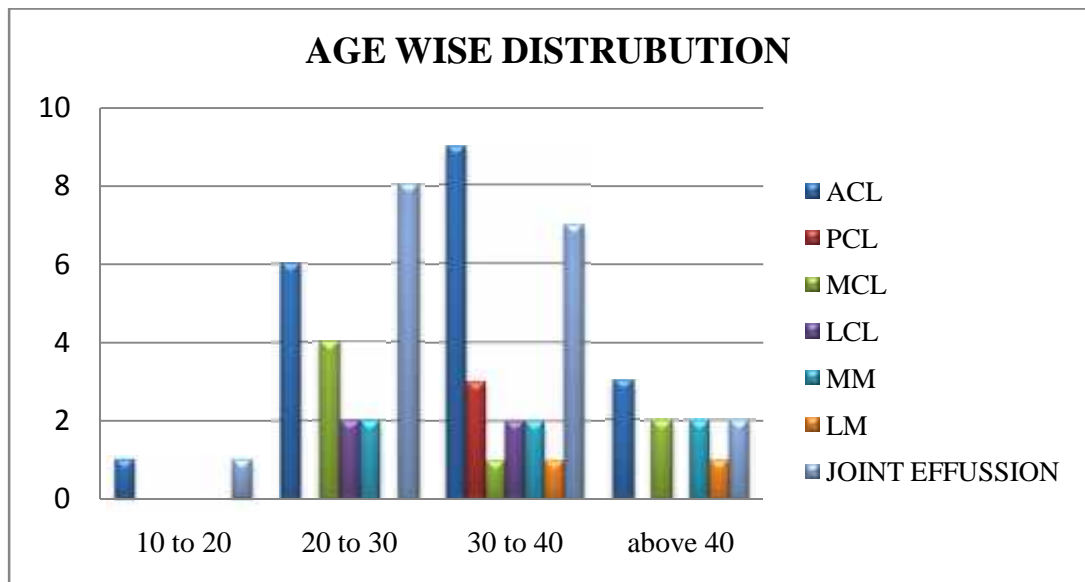


Fig 9 shows age wise distribution of various ligament injury in correlation of MRI with arthroscopy.

Table 3 Duration of injury of patients studied.

Duration of injury	Number	Percentage
Upto 1 week	6	18.1
1 week to 2 week	8	24.24
3 week to 4 week	9	27.27
4 week to 5 week	4	12.12
5 weeks	6	18.1
Total	33	100

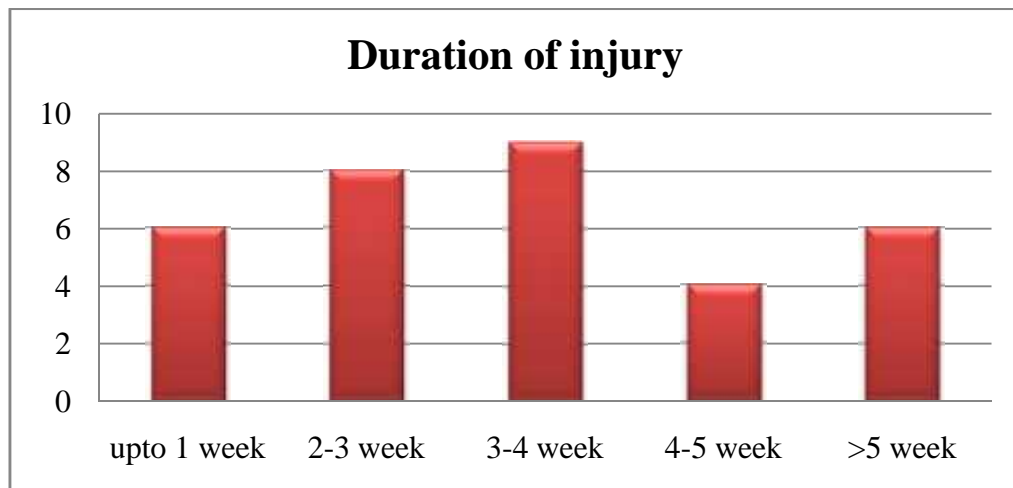


Fig 10 shows duration of injury in weeks for investigation of MRI & arthroscopy.

Table 4: Joint effusion

Joint effusion	n-33	Percentage
No	12	36.3
Yes	21	63.7

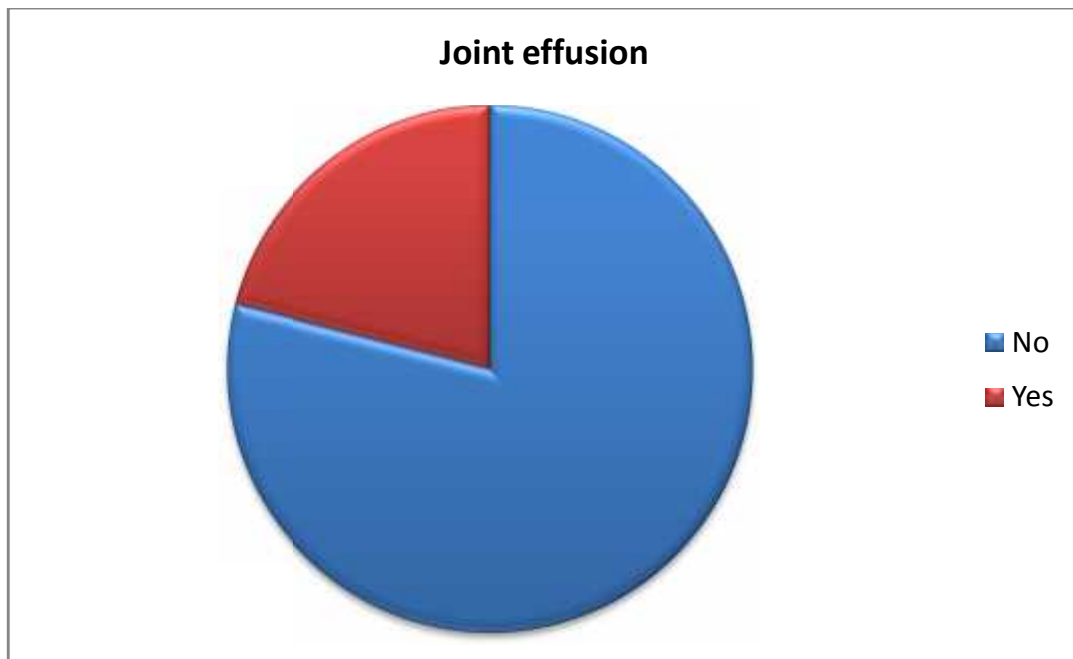


FIG 11 pie diagram shows patients presented with arthroscopy.

Table no 5 location wise multiple responses

Location of ACL tear	MRI	% of the cases	Arthroscopy	% of cases
Mid substance	10	30.3	9	27.27
Femoral attachment	5	15.1	5	15.15
Tibial attachment	3	9.09	3	9.09
Total	18	54.9	17	51.51

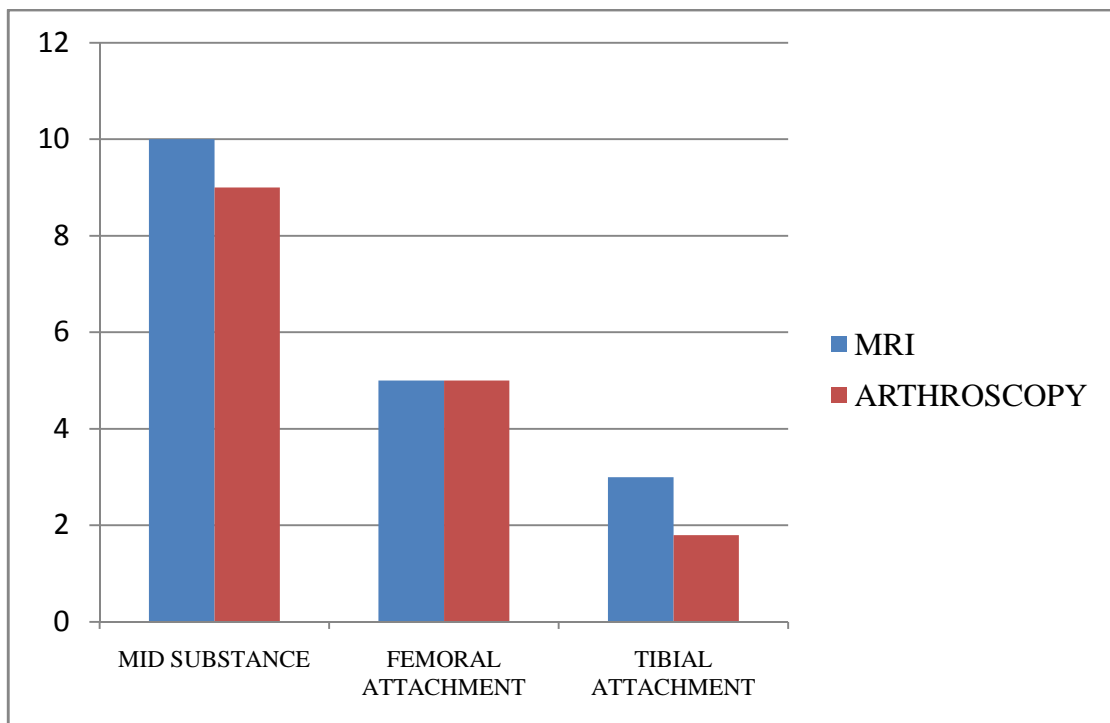


Fig 12 Bar Diagram with multiple response in injuries of ACL.

Table No 5 Cases with multiple responses.

PCL	MRI	% of cases	Arthroscope	% of cases
	3	9.09	3	9.09

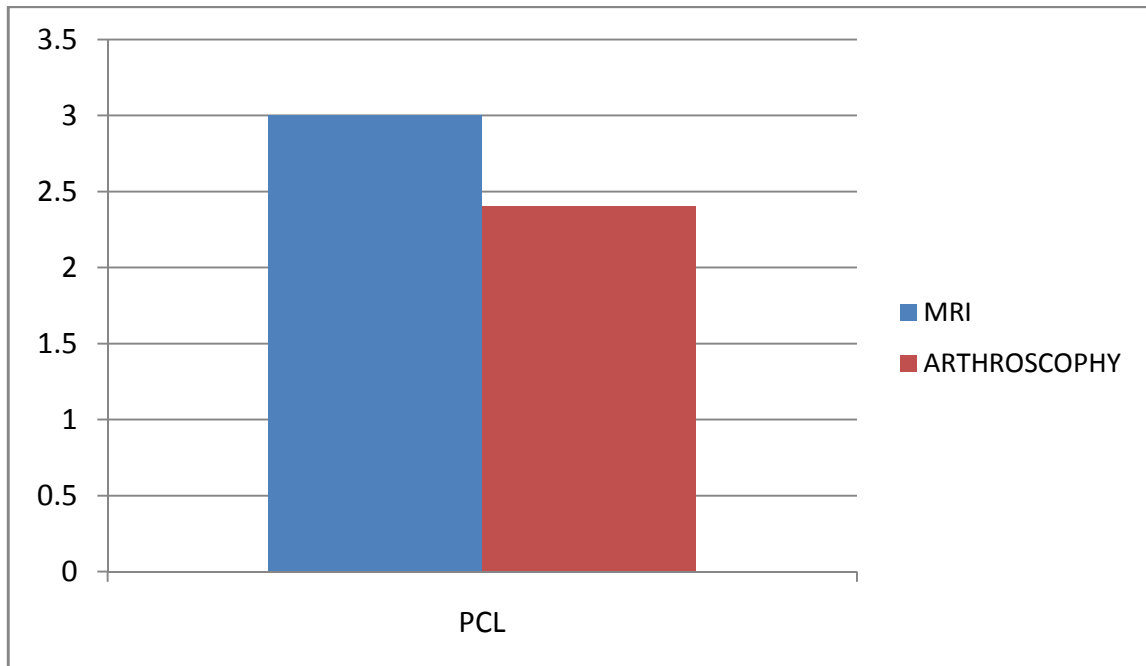


Fig 13 shows multiple responses of PCL injuries in MRI and arthroscopy.

Table no 7 Grade wise distribution with multiple responses.

MCL Tear	MRI	% of cases	Arthroscopy	% of cases
Grade I	1	3.03	1	3.03
Grade 2	2	6.06	2	6.06
Grade 3	1	3.03	1	3.03

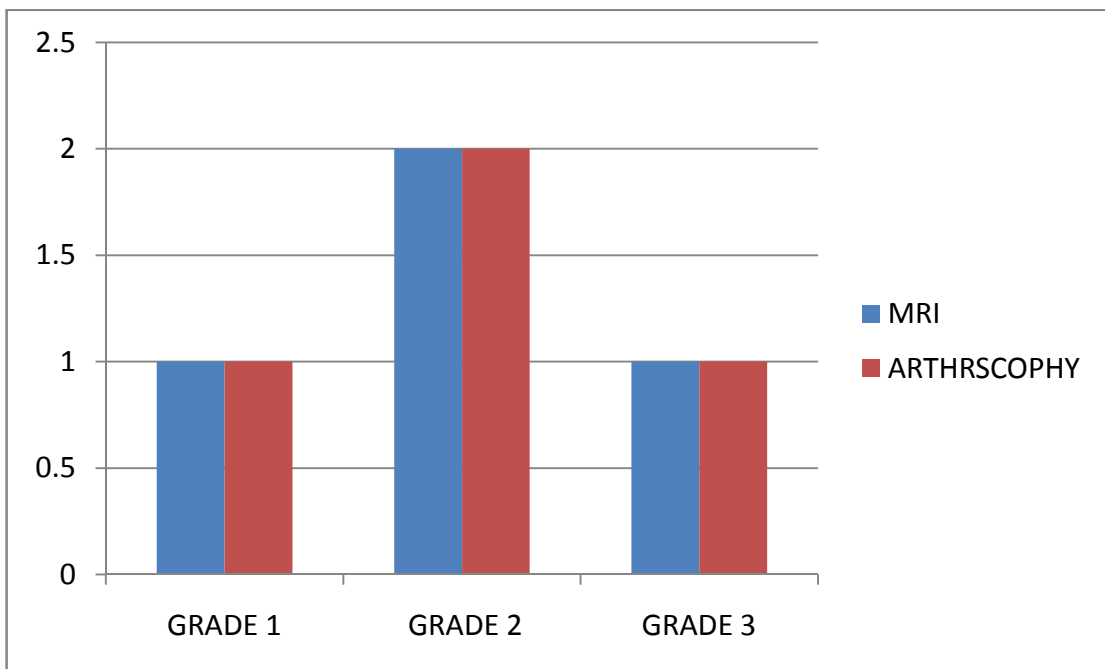


Fig 14 shows multiple responses in bar diagram with various grade of injury in correlation of MRI with arthroscopy.

Table no 8 With multiple responses.

LCL	MRI	% of cases	Arthroscopy	% of cases
Grade I	1	3.03	1	3.03
Grade II	2	6.06	2	6.06
Grade III	1	3.03	1	3.03

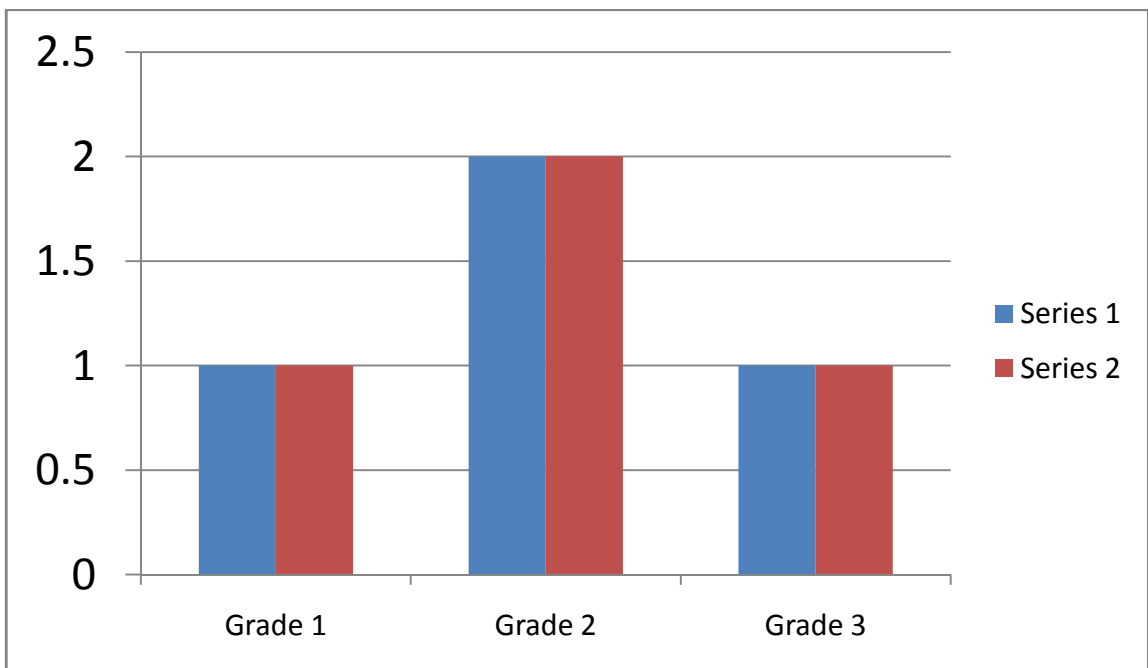


Fig 15 shows multiple responses of LCL in correlation of MRI with arthroscopy.

Table no 9 With multiple responses

MM	MRI	% OF CASES	ARTHROSCOPHY	% OF CASES
GRADE I	1	3.03	0	0
GRADE II	2	6.06	2	6.06
GRADE III	3	9.09	3	9.09

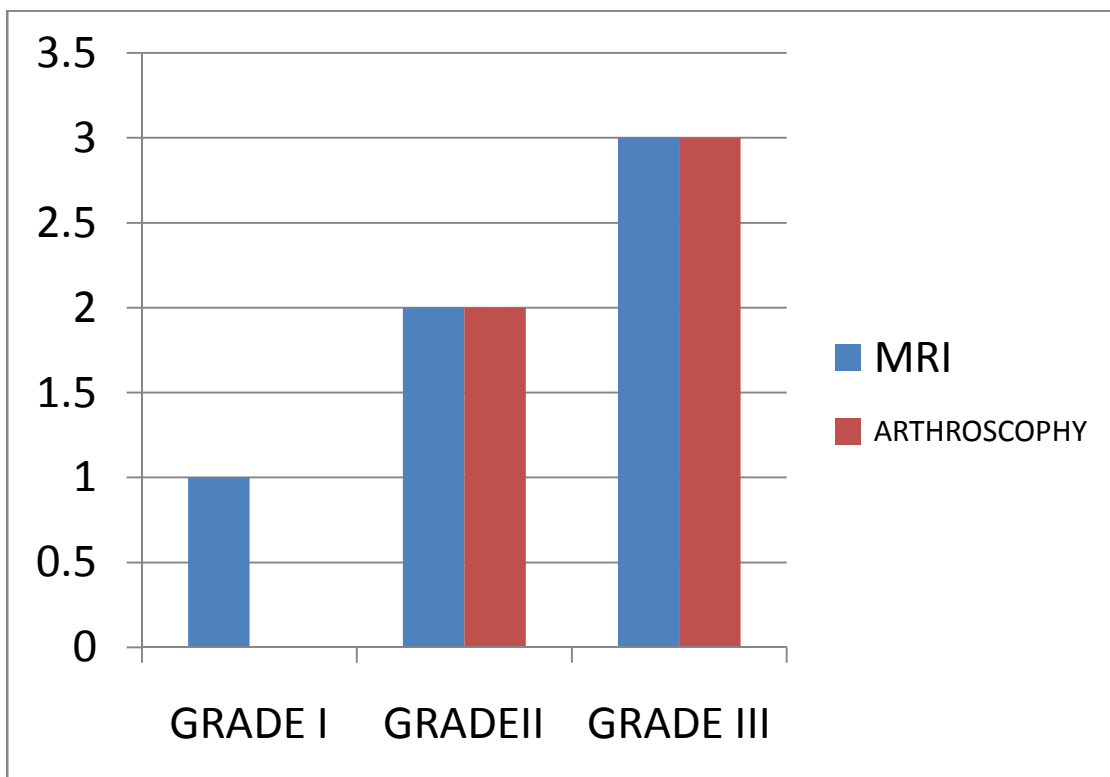


Fig 16 Bar diagram with multiple responses in MM in correlation with arthroscopy.

Table No 9 With multiple responses

LM	MRI	% of cases	ARTHROSCOPE	% of cases
GRADE I	0	0	0	0
GRADE II	1	3.03	1	1
GRADE III	1	3.03	1	1

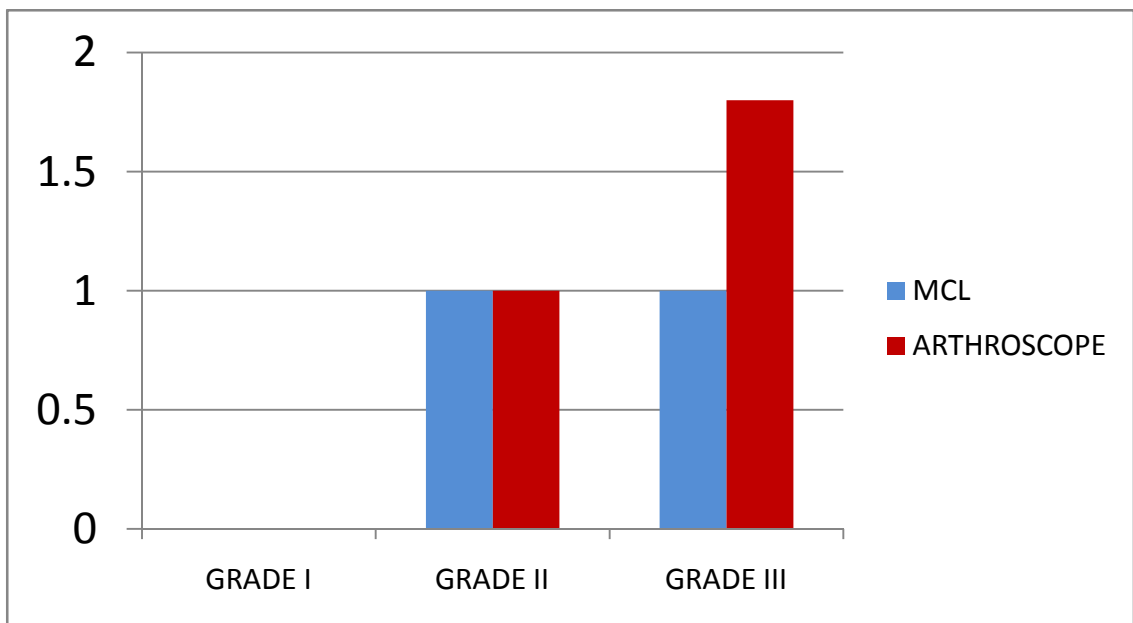


Fig 17 Bar diagram showing various grades of LM injuries in correlation with MRI and arthroscopy.

Table No 11 Osseous/osteochondral lesions.

Osseous/osteochondral lesions	Number	%
Absent	22	67
Present	11	33

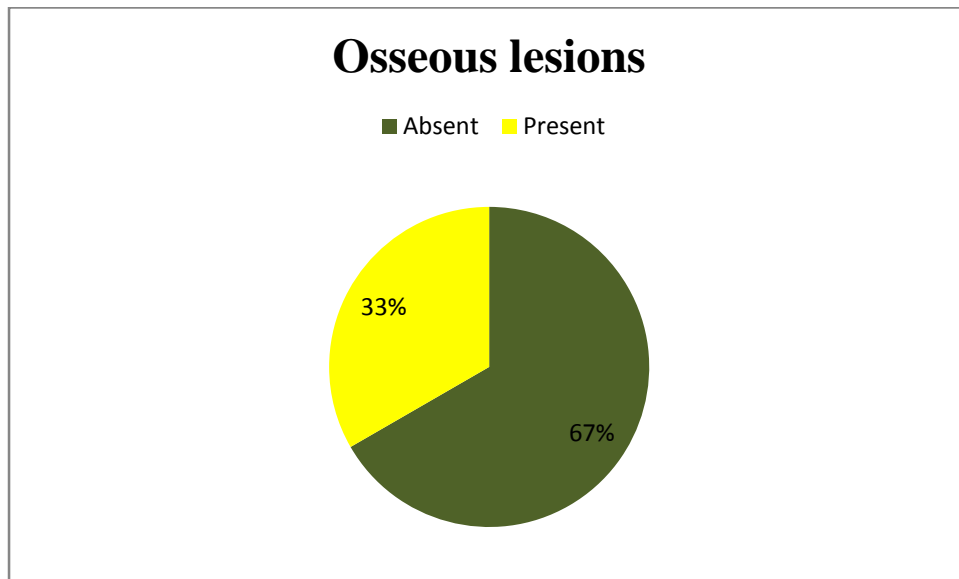


Fig 18 Pie diagram with multiple responses showing osseous lesions

Table no 12 with multiple responses.

Combined injuries	Frequency	Percentage
Isolated injuries	17	52
Two injuries	9	27
Three injuries	5	15
Four injuries	1	3
Five injuries	1	3

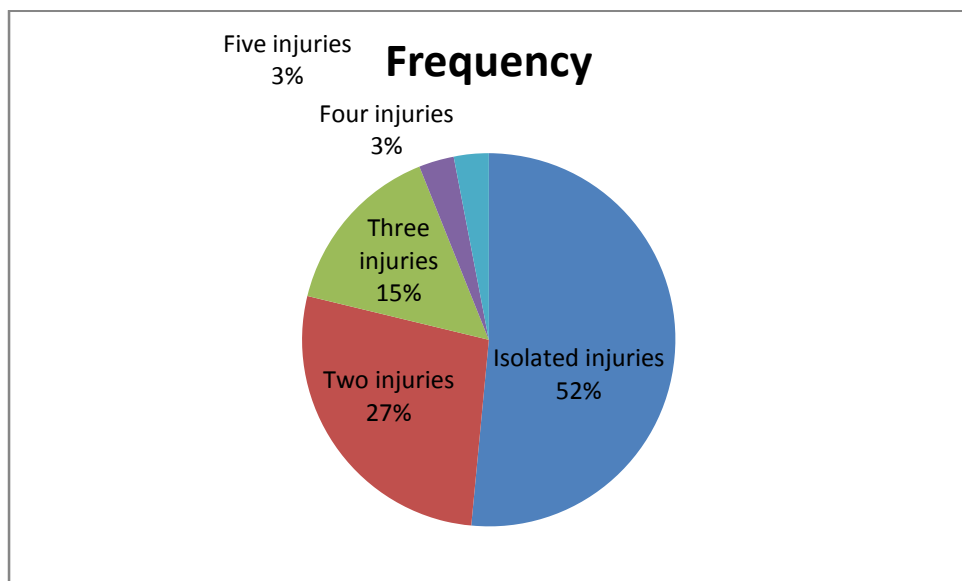
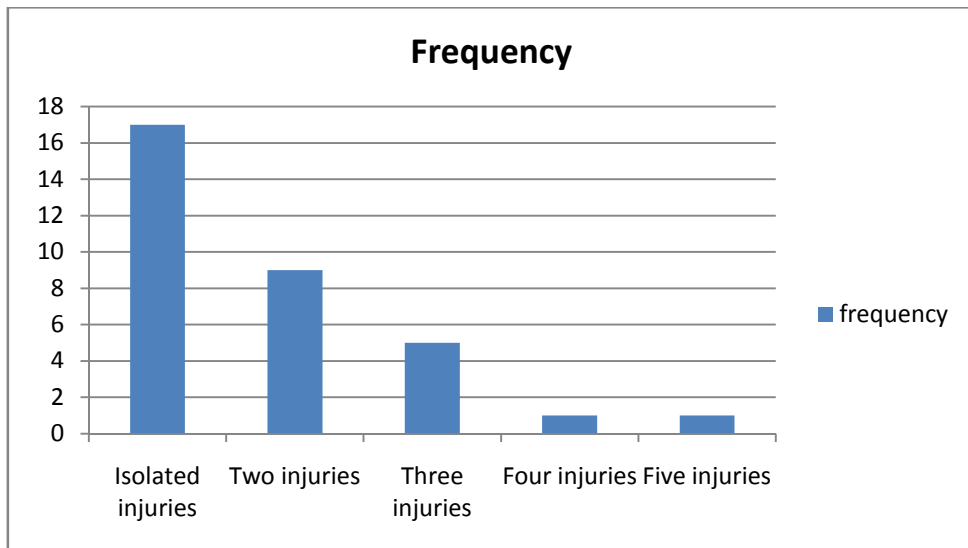


Fig 19 shows multiple associated knee injuries in MRI and arthroscopy.

DISCUSSIONS

The role of MRI has steadily increased and is now investigation of choice for internal derangement of knee. It is also being used for pre and post operative evaluation. It is a non invasive technique that that does not require contrast administration and is not operator dependent. Complete evaluation of internal structures of the knee is not possible with modalities like radiography, arthrography and ultrasonography. Even with arthroscopy lesions such as peripheral meniscal tears, inferior surface tears and osteochondrans dessicans without articular damage are most commonly detected.

AGE OF PATIENT.

Manoj MK et al 2014 ⁴⁶, A total 40 cases with age ranged between 15-61 years. 12.5 % were below 20 years, 63.7% were between 21-40 years, 18.75% were between 41-60 years. More than 60 years 5%. The mean age was 30 years and the maximum number of patients affected belongs to the age group of 21-40 years. which is correlating our study with clinical history, They found mean age group of younger generation with acute history such as road traffic accident and sports injury.

Gupta R et al 2015 studied ⁵¹ Role of MRI in delineation of internal derangement of knee in trauma patients in there study a total of 44 patients with 37 males and 7 females. Males comprised of 84.1% and females comprised of 15.9% of the total study group. Male patients exceeded the number of female patients in all the age groups. The age group ranged from 20 to 60 years with mean age being 32.2 years. 20-30 year was the commonest age group in there study. They also found knee injuries are common in mainly in younger generation and active individuals. Even in

our study we found mean age of injuries are from 30-40 yrs (54.3%) which is very well correlating.

Bashir Ahmed Mir 2015 ⁵⁹ in there study there weretotal of 50 patients were included in the study in the age group of 18 to 50 years with a mean age of 38.5 years. Out of 50 patients in our study, 35(70%) were males and 15(30%) were females. Left knee was predominantly involved in 64% of the cases with 36% involvement of right knee for all pathologies diagnosed on arthroscopy, in our study also we found similar finsg with mean age 30-40 yrs which is similar to this study.

Ali Akbar esmaili jah et al,, 2005 ⁴⁵, They conducted a prospective, single blind study, to compare diagnostic accuracy of clinical examination with MRI findings in assessing patients with acute traumatic internal derangement of the knee. A total of 57 males (81.4%) and 13 females (18.6%), ranging in age from 17 to 51 years (mean = 27.9). The right knee was involved in thirty cases (42.9%) and the left knee in 40 (57.1%). Most of cases in there study were non-professional sports injury in 55 patients, a motor car accident in 10 patients and a fall in 5 patients, however in contradiction we found most of cases were due to sports and recruits and road traffic accident injuries, our study mean age is correlating with study.

Rajpal Yadav et al,, 2013 ⁷⁶ they conducted study on Role of MRI in evaluation of painful knee. A total of 50 patients and mean age of patients in this study was 36.70± 13.14. The maximum numbers of patients were seen in 40-50 years age group, which is contradicting our study since in our study we found mean age group ranging from 30-40 and patients presented with acute history of trauma, however rajpalyadav studied patients of traumatic origin or non traumatic origin like infection or inflammation. Since old aged patients presents with nontraumatic cases with we have

excluded in our study. Analysis of demographic characteristics shows that in this present study of 50 patients, 17 were females (34%) and 33 were males (66%). This is because males are generally more active than females and travel a lot. Hence their knees are exposed to more wear and tear. Also they are at more risk of injury.

Madhusudan et al 2008 ⁵⁷ A total of 109 patients with 68 males and 41 female patients in the age group of 18–70 years with a mean age of 52 yrs. Patients in groups 1 and 2 were in the age group of 18 and 50 years and group 3 consisted of 62 patients in the age group of 51–70 years. There were three identified groups: Those who were clinically positive for meniscal or cruciate ligament injury [group 1], combined meniscal and cruciate ligament injury [group 2], and patients with highly suggestive symptoms but with negative clinical tests [group 3]. 82 patients in the study had treatment in the form of a knee support device or physiotherapy prescribed by their general practitioner before their first visit to the orthopaedic consultation. Our protocol of study included only patients of acute trauma on visit to orthopaedic OPD most of patients were positive for clinical tests since most patients presented with acute trauma.

Liem 1. Bui-Mansfield *et al.*, In this study. The male-to-female ratio was 9: 1, and the mean age was 31 years old, These demographics reflect a military population. In our study we found many of our patients from police training school, vijayapura these patients were managed conservatively for 2 weeks, however later on surgery were planned.

Rakesh Gujjar et al., 2015 ⁷⁶ They found knee injuries represent roughly 6% of all acute injuries treated at emergency department and between 27% and 48% of these have been reported to be sports related in their study, in there study found that mean

age was 2 weeks. Acute injuries were taken immediately for surgery within 1 week, and patients with non-sports injured patients were given 2-3 weeks of time for conservative management in our study.

In our study included around 33 patients suspected having internal derangement of knee. Maximum were young and middle aged group mean age from 30-40 yrs (54.3%) with below studies quoted shows mean age group is younger age due to trauma and sports injury.

MODE OF INJURY

Gupta R *et al*, 2015⁵¹ The common mechanism of injury noted was road traffic accident with 20 patients (45.5% of the total population) followed by sports related injuries with 13 patients (29.5% of the total population) Forty of these patients presented with pain, 23 patients presented with painful swelling of the knee, and the remaining 22 patients presented with leg instability.

A. A. ESMAILI JAH *et al* 2005⁴⁵ They found mechanism of trauma was a non-professional sports injury in 55 patients, a motor car accident in 10 patients and a fall in 5 patients. In our study we found 20 patients of non professional sports injury and 10 cases of road traffic accidents and 3 cases of police recruits due to sports injuries.

Rakesh Gujjar *et al*, 2015⁷⁶ They found knee injuries represent roughly 6% of all acute injuries treated at emergency department and between 27% and 48% of these have been reported to be sports related in their study. In our study we found most of injury due to non professional injury, road traffic accident & sports injury.

A total of 33 patients presented in OPD. Out of these injuries patient presented with various mode of injury, Some were due to sports injury, road traffic accidents, some were police recruits from police training centre, Vijayapur.

DURATION OF INJURY

TR Madhusudhan *et al*, 2008 ⁵⁷

Arthroscopy is inevitable considering the load in the National Health Service (NHS) , however waiting time for the MRI from the point of definite clinical diagnosis was 3–7 weeks [average 4.1 weeks] and the waiting time for arthroscopy following the MRI was a further 5–8 weeks [average 5.8 weeks]. 3 patients were examined directly by the orthopaedic team following an acute episode and the rest were seen by the emergency medicine department at the time of injury to be followed by Orthopaedic consultation, In our study most of injuries were due to acute injury & sports person and recruits, since patient was given appointment for MRI and arthroscopy, mean duration was from 1-4 weeks (54.27%), and however due to load of patients most of patients were given 2 weeks of appointment for arthroscopy & few patient were managed conservatively initially and later advised surgery.

Peleg Ben-Galim, MD et al 2006 ⁶⁸ The interval between MRI and arthroscopic surgery had to be no longer than 3 months. Soldiers included in our study were those excused from physical activity between MRI and arthroscopy. In our study few patients were given time for rest from physical activity, police recruits are given excuse of 3 weeks, patient with partial tear were managed conservatively

Solomon et al 2003 ⁵⁸ stated “While most meniscal or ligamentous knee injuries heal with non-operative treatments, a subset should be treated with arthroscopic or open

surgery”. We believe that our clinical protocol including a second examination after 3 weeks of splinting can reduce the number of unnecessary MRI’s or arthroscopic procedures, and should be particularly considered when the patient is not a professional sportsman, or is willing to wait for three weeks. However, in case of a high clinical suspicion of osteochondral damage and/or bony lesion, early MRI, or arthroscopy may be required.

William Rodriguez, Jr 2008⁶¹ in there study found The mechanism of injury was dashboard type in 35%, fall on a flexed knee (blow to the anterior proximal tibia) with the foot plantar-flexed in 24%, and hyperextension in 12% of cases. Hyperflexion injury has been described as a less-common mechanism of PCL injury. Sports-related PCL injuries are significantly more likely to be isolated and more likely to be diagnosed in the acute phase, similarly in our study showed mode of injury due to dash board injury and sports related injury were noted in 3 cases.

In our study patient presented with different age of injuries with mean week/duration of injury 1 to 4 weeks(52%), due to most of injury were due to acute internal derangement of knee, so most of the patients present in acute stage with associated injury. These patients under went clinical examination and MRI followed by arthroscopy on appointment.

ANTERIOR CRUCIATE LIGAMENT

Monoj k et al,, 2014⁴⁶ studied 98% in mid substance and 100% in femoral &tibial attachment out of total cases of 35. Most common sign of ACL Injury in MRI was hyperintensity. A critical review of false positive and false negative findings in MRI showed 1 false positive and 1 false negative case. False positive case had both primary and secondary findings. Cause of primary finding was non visualisation of

ACL and the causes for the secondary findings is unclear; they may have reflected the physiological ligamentous laxity. In the false negative case that had a partial tear as seen in arthroscopy the MR image showed a linear band of intact fibers normally oriented in expected location of the ACL. Studies have show that MR imaging has low sensitivity (40- 75%) but moderate to high specificity (62-94%) in diagnosis of partial tears

Singh et al.2004 ⁶ Out of 78 patients of ACL tears, 53 patients (67.94%) had mid substance tears, 15 patients (19.23%) had tears at the femoral attachment and 10(12.8%) at the tibial attachment were detected, on MRI. In our study, the most common tear location was at mid-substance. On Arthroscopy, mid substance tears were seen in 52 patients (66.67%), femoral attachment tears in 15 cases (19.23%) and tibial attachment tears in 11 patients (14.1%) were detected. In there hyper intensity in the ligament as the most common sign which was seen in 52 patients (66.67%), 16(20.51%) patients showed discontinuity and 10(12.82%) patients showed non visualization of ACL, Our study midsubstance tear of ACL had similar findings.

Laxman Prasad Ahirwar et al., 2013 ⁶⁶ Out of 100 patients of IDK. Out of 32 ACL tear, 25 (78%) were classified as complete tear and 7 (22%) as partial tear. 11(34.3%) of ACL tears were located in proximal segment, 17 (53.2%) in mid substance and 4 (12.5%) in distal segment of ligament. Arthroscopy was performed in 31 patients. Preoperative MRI reported ACL tear in 14, and 13 patients proven as tear on arthroscopy. 1 was normal on arthroscopy (false positive) and 1 case which were normal on MRI found to be torn on arthroscopy (false negative). MRI abnormal signal intensity was seen within the ligament with intact fibers. Mean while in our study had a similar findings on MRI findings of abnormal hyperintense signal in mid substance partial tear of ACL tear. On arthroscopy had a false negative case.

Anton M Allen M.D et al 2014 ⁶⁵ . Meanwhile ACL ligament showed hyperintense signal in one of cases in midsubstance tear of ACL tear similarly in this study , they studied two manifestation in partial tear (1) an anteriorly angled ACL stump or (2) a heterogeneous variable-signal nodule projecting anteriorly from the ACL. Histologic evaluation of the nodules has revealed disorganized ACL fibers, fibrosis, inflammation, and hemorrhage, they came to conclusion as MRI adds some value in the evaluation and management of partial tears, and positive MRI findings should not be ignored, even in the setting of a negative Lachman test. In most cases. Partial ACL tears are evolving. Factors favoring conservative treatment include advanced age, a normal or near-normal Lachman result, low athletic demands, and less than 50% involvement of the ACL fibers on arthroscopy. Most young and highly active patients, patients with a clearly abnormal Lachman result, and patients with greater than 50% or posterolateral band involvement on arthroscopy are best treated with ACL reconstruction. Similarly our showed a false negative cases. On discussion with orthopaedic surgeon we went ahead with arthroscope for further evaluation.

In our study we found hyperintensity as most common in mid substance tear and few cases showed discontinuity of femoral and tibial attachment.

Out of total 33 cases, ACL tear was common finding affecting total of 18 cases (54%) with injuries commonly seen in mid substance 10 cases (30.03%), 3 & 5 cases in respective femoral and tibial attachment where detected on MRI and showing one case negative on arthroscopy due to mid substance tears (27.2%). Due to hyperintense signals on partial tear which is correlating to studies.

POSTERIOR CRUCIATE LIGAMENT.

JP Singh et al 2014 ⁶

The PCL is usually very easily visualized as a homogenous, continuous low-signal structure which is noted on various sequences. In the study a total of 10 cases of PCL injury, on arthroscopy correlation were 100% positive predictive value. In our study results are similar to JP Singh et al due to easy visibility of PCL and homogenous structure.

Laxman Prasad Ahirwar et al., 2013 ⁶⁶, Out of 7 PCL tear, 3(42.8%) were classified as complete ligament tear, 1 (14.4%) as partial ligament tear and 3(42.8%) tibial avulsion (Fig. 4). Arthroscopy was performed in 31 patients. Preoperative MRI revealed posterior cruciate ligament tears in 2 patients, both of them found torn on arthroscopy. The PPV, NPV, sensitivity, specificity and accuracy in our study for detecting PCL tears were 100%.

Michael R Aiello et al 2015 ⁶⁰ The sensitivity and specificity of MRI in making the diagnosis of PCL tears is high. Sensitivity has been reported to be as high as 100% & associated injury were about 14%, in our study we reported sensitivity of 100% which is similar to this study and no cases were 3 (9.09%) which is less has compared to this study.

William Rodriguez, Jr et al., 2008 ⁶¹ in this study PCL usually is injured as a result of a stretching deformation, similarly in our study 2 cases resulted due to fall and one case with dash board injury. Whereby the ligament maintains continuity as a thickened structure, rather than frank rupture. Apparent ligamentous continuity was seen in 62% of our cases of surgically proven tears. Abnormally increased signal intensity within the PCL on proton-density images is highly suggestive of PCL tear

and was seen in all of the patients in this study who had a surgical diagnosis of PCL tear. With use of sagittal T2-weighted images, a 7-mm or greater anteroposterior measurement of the vertical portion of the PCL can be considered evidence of a torn PCL with a high degree of certainty. With above mentioned sequences our diagnosing ability has improved and we measured PCL ligament thickness.

Collateral ligament

Venkateshwaran Arumugam *et al.*, 2015⁶² they studied Lateral collateral injury total no cases were 12 (10%) The main findings in there study was collateral ligament injuries were adjacent fascial oedema and increased signal intensity of ligament and associated with ACL injuries due to sports related injuries. In our study total of 4 cases were detected they were most commonly associated with ACL injury in corroboration with above study findings are similar.

Adil Ismail Nasir *et al.*, (2013)⁶³ In there study a total of 12 cases were registered in MCL & LCL injuries showed those injuries demonstrated increased signal intensity on T2- weighted images because of edema and hemorrhage and others demonstrated displacement or complete loss of continuity of ligamentous fibers, depending on the severity of the injury. In our study no cases reported are similar and showed discontinuity and loss of signals on sequences.

Mink JH *et al.*⁵⁶ Occult cartilage and bone injuries of the knee: detection, classification, and assessment with MR imaging They observed that out 11 patients who had ACL tear and 7 patients had MCL associated injuries and 4 patients had lateral meniscus injuries and 1 patient had medial meniscus injury.

Thomas H. Berquist *et al*, ⁴²

Tears of the ACL are frequently noted in association with MCL tears (30%). O'Donahue's triad (medial meniscal tear, ACL tear, and MCL tear) is a frequently described injury pattern. MRI criteria in two image planes can be graded by the extent of fiber involvement (grade 1 sprain: a few fibers torn; grade 2 sprain: about 50% of the fibers torn; grade 3 sprain: complete disruption of the MCL) or signal intensity changes in and about the ligament. Grade 1 injuries show increased signal intensity medial to the ligament with normal signal intensity in the ligament. Grade 2 injuries demonstrate increased signal intensity medial to and within the ligament without complete disruption. Grade 3 injuries are complete similar to that defined by a grade 3 sprain. Reported 87% accuracy for MRI in classifying MCL injuries. Minor injuries are particularly easy to detect due to the high sensitivity of MRI. Partial or grade 2 tears are more difficult to correctly classify with MRI, however we have reported 100% correlation with arthroscopy.

8 cases had collateral ligament injury, out of it 4 had MCL (12%) and 4 cases had LCL (12%) and cases showed 100% accuracy with arthroscopy. These cases were associated with multiple injuries such as ACL injuries with medial meniscus injury and fractures in few cases.

In our study we had grade II (12%) injuries were common in both lateral and medial collateral ligament.

Mensical injury.

Manoj k et al 2014 ⁴⁶ in their study only grade 3 tears were compared as grade 1 / 2 do not reach up to the articular surface and hence invisible to arthroscopic

surface evaluation. Out of 80 patients 23 (28.75%) showed medial meniscal and 11 patients (13.75%) showed lateral meniscal tears on MRI. 18 patients (78.95%) had posterior horn tear and 5 patients (21.05%) had anterior horn tear of medial meniscus. On arthroscopy posterior horn tears were seen in 17 patients (73.91%), anterior horn tears in 4 patients (17.4%) and middle one third tears in 2 patients. (8.7%). In our study we had similar findings 4 cases with posterior horn tear and 2 cases with anterior horn tear in medial meniscus & Lateral meniscus injury counting to total of 2 cases (6.06%) with each in anterior horn and posterior horn respectively.

Singh et al 2004 ⁵¹ In this study detection of Lateral Meniscal tears the sensitivity, specificity and accuracy was 87%, 99.29% and 97.11%. The accuracy of MRI in identifying medial meniscal tear has been reported to range from 72%-98%, with sensitivity of 77%-97.5% and a specificity of 37%-100%. The occurrence of the false positive meniscal tears at MRI imaging has been noted earlier. There are explanations for this apparent discrepancy between findings at MR Imaging and arthroscopy.

Misinterpretation of normal anatomy like Menisocofemoral ligaments etc.

The presence of intrasubstance tears which are not seen on arthroscopy.

The operator dependence of Arthroscopy. The presence of loose bodies.

Out of 57 Medial Menisci tears, there were two false positive (3.51%) and two false negative (3.51%) observations. In our study, the 2 false positive MRI involved the posterior horn of the meniscus. The exact cause of the false positives in detection of tears of the posterior horn of the medial meniscus in our study was not apparent. It may be attributed to the presence of intra-meniscal tears not communicating with the articular surface of the meniscus or misinterpretation of normal anatomy or operator/

procedure dependant drawback of arthroscopy. however this finding is noted in our study due inferior surface injury.

De Smet *et al*, 2012 ⁶⁴ How I Diagnose Meniscal Tears on Knee MRI, MRI is a highly accurate imaging method for diagnosing meniscal tears. To avoid errors in diagnosing meniscal tears, those interpreting MR examinations of the knee need to be aware of the attachments of the menisci and the normal variations in meniscal anatomy that may resemble a meniscal tear. In addition, by being aware of the patterns of meniscal tears, it is easier to diagnose the less common tears. In my recent experience, a definitive diagnosis of an intact or a torn meniscus can be made in 95% of knee MR examinations. In the remaining 5% of patients, it is not possible to be definitive but a diagnosis of a possible tear or a probable lateral posterior root tear or a differential diagnosis of meniscal fraying or tear should be given. In our study grade I tear were diagnosed were diagnosed.

Out of total 9 cases (25%) meniscal injury were detected, In our study showed medial meniscus were more common than lateral meniscus. We found 4 cases with posterior horn tear and 2 cases with anterior horn tear in medial meniscus. Grade III tear were common with total of 3 cases(9.09%).Out of 6 cases showed 5 horizontal tears and 1 radial tears were detected. Grade I tear could not be identified by arthroscope due to inferior surface tear of meniscus could not be visualized by arthroscope due to limited field of vision. Lateral meniscus injury counting to total of 2 cases (6.06%) with each in anterior horn and posterior horn respectively. Grade II & III injury in meniscus respectively. Radial tears were detected in LM injury in both cases.

Osseous osteochondral lesions.

In our study Osseous/Osteochondral lesions were seen in 11 patients (33 %). Most of these were bony contusions involving the femoral and tibial condyles. Osteochondral lesions are seen in nine patients. In our study we found a case of Comminuted bicondylar fracture of proximal end of Tibia with intra-articular and intracondylar extension. There is also fracture of medial tibial condyle in 4 cases anterolateral. A case of Second fracture of the lateral tibial rim with bony contusion of the lateral femoral condyle was also seen. These findings were correlated with findings described by Thomas H. Berquist . The finding of hemarthrosis and lipohemarthrosis was associated in two cases with presence of intercondylar fractures. These findings were correlated with findings described by **Thomas H.Berquist**⁴²

In our study, a correlation of MRI findings with arthroscopic / surgical findings was performed in 11 patients (33 %). Among which in 09 patients (84%) MRI findings are well correlated with arthroscopic / surgical findings with 95% Confidence interval. Correlation between MRI and arthroscopic /surgical findings are statistically significant with 95% CI (70.04-95.83%)

Bekir Yavuz Uçar et al, 2012⁵⁹ Determining Bone Bruises of the Knee with Magnetic Resonance Imaging

Type I lesions showed a signal intensity loss that was primarily located within the medullar cavity of the bone, without cortical interruption. A Type II lesion was defined as a loss of signal intensity associated with interruptions in the black cortical line; such an abnormality was defined in the present study as a fracture combined with bone bruise. On short TE images, a type III lesion was defined as a loss of signal

intensity without definite cortical interruption in the bone regions adjacent to the cortex.

They reported that MR imaging performed before arthroscopy of the knee reduced costs. In their study, positive results were obtained *via* MR images of the patients in whom radiographs showed no pathological findings, and these patients were classified as Type I, based on the arthroscopic findings. Therefore, it can be assumed that using MR imaging in acute minor knee traumas might prevent unnecessary diagnostic arthroscopy.

However in our study there were cases reported with bone contusion, however we went ahead with surgery, there associated injuries.

Arthroscopy and MRI findings

In our study MRI findings were very well correlated, however in few cases such as mid-substance tear of ACL (grade I) could not be correlated because of hyperintensity on PD/T2WI sequences appeared to be grade I (tear), On arthroscopy it was false negative.

Mensical injury showed grade I showed inferior surface of meniscus and arthroscopy these findings could not be correlated, However MRI were well correlated with arthroscopy

SUMMARY

The present study attempts to determine the role of magnetic resonance imaging in the evaluation of internal derangements of the knee joint. Knee joint being the largest and most complex weight bearing joint of the body is subject to damage because of its inherent structural complexity and the various types forces it is subjected to.

Magnetic resonance imaging has emerged as the frontline investigation for evaluation of internal derangements of the knee joint. It is noninvasive, does not involve ionizing radiation and has multiplanar capability with excellent soft tissue demonstration. Arthroscopy gives excellent visualization of the interior of the joint, but is invasive and can evaluate only the surface abnormalities.

In the present study, 111 patients with knee joint symptoms, referred for magnetic resonance imaging of the knee joint were evaluated.

Most common presenting symptoms were knee joint pain either acute or long standing and swelling.

The most common age group to be involved was between 30-40 years. The following patterns of knee injuries were seen:

1. Most common injury was ACL tear of which complete tears were more common. Posterior cruciate ligament tears were less common.
2. Among the Meniscal injuries medial Meniscal tears are more common than lateral meniscus and grade 3 tears are more common in both.
3. Medial collateral ligament tears outnumbered Lateral ligament tears and grade 2 tears are more common in MCL

4. Osseous/Osteochondral lesions were seen in 11 patients (33%). Most of these were bony contusions involving the femoral and tibial condyles.
5. Other abnormalities like hemarthrosis, joint effusions, and other myotendinous tears were accurately detected and characterized with the help of magnetic resonance imaging.

The ligamentous & meniscal and associated injuries are of increased severity compared to the available literature that can be attributable to the severity of RTA and injuries involved in young individuals.

CONCLUSION

MRI is non invasive and reliable investigation for ligament pathologies, which helps in accurate diagnosis of meniscal and ligament injuries, which achieve good results helps proper management by conservative and surgical treatment. However arthroscopy still remains gold standard for diagnosis and treatment at same time. Since false negative cases have been reported such meniscal injuries. So, MRI can diagnose the knee injuries can reduce invasive procedure and assist further management decision.

BIBLIOGRAPHY

1. DW Polly, JJ Callaghan, RA Sikes, JM McCabe, K McMahon and CG Savory. The Accuracy of Selective Magnetic Resonance Imaging Compared with the Findings of Arthroscopy of the Knee. *Am J Bone Joint Surg* 1988;70:192-198.
2. Vaz CES, Camargo OP de, Santana PJ de, Valezi AC. Accuracy of magnetic resonance in identifying traumatic intraarticular knee lesions. *Clinics* 2005;60(6):445-50.
3. Keith Winters, Russell Tregonning. Reliability of magnetic resonance imaging for traumatic injury of the knee. *NZMJ* [serial online] 2004 Feb [cited 2005 Feb 11]; 118 (1): [1209 screen]. Available from
4. Edwin H G Oei, Jeroen J Nikken, Antonia C M Verstijnen, Abida Z Ginai, M G Myriam Hunink. MR Imaging of the Menisci and Cruciate Ligaments: A Systematic Review. *Radiology* 2003;226:837–848.
5. Edwin H G Oei, Abida Z Ginai, M G MyriamHunink. MRI for Traumatic Knee Injury: A Review. *Semin Ultrasound CT MRI* 2007;28:141-157.
6. Singh JP, Garg L, Shrimali R, Setia V, Gupta V. MR Imaging of knee with arthroscopic correlation in twisting injuries. *Indian J Radiol Imaging* 2004;14: 33-40.
7. David K B Li, Mark E Adams, J Pat McConkey. Magnetic Resonance Imaging of Ligaments and Menisci of the Knee. *RadiolClin North Am* 1986;24(2):209-227.
8. S Bryan, GWeatherburn, H Bungay, C Hatrick ,C Salas, D Parry, et al. The role of MRI in the diagnosis of knee injuries-Health Technology Assessment 2001; 5 (27):11-1782
9. Jill E Langer, Susan J F Meyer, Murray K Dalinka. Imaging of the knee. *RadiolClin North Am*1990;28(5):975-990
10. Douglas P. Bell, J. David Googe, Jason T .Moss, Justin Q. Ly, Barry J. Greer, Annette M. Stapp,et al. Magnetic Resonance Imaging of the Collateral Ligaments and the Anatomic Quadrants of the Knee. *Radiolclin N Am* 2007;45:983-1003.
11. D. J. Dandy, K. Arthroscopy and MRI for the knee. *J Bone Joint Surg [Br]* 1997;79-B:520.
12. Omar Faiz, David Moffat. The knee joint and popliteal fossa. In: Omar Faiz, David Moffat, editor. *Anatomy at a glance*. 5th ed. University of Cardiff:Blackwell Science Ltd, 2002:109-112.

13. A Newman-Sanders, A L Hine. The musculoskeletal system 2: lower limb. In: Paul Butler.
14. Adam WM Mitchell, Harold Ellis editor. Applied Radiological Anatomy of knee. 1st ed. India Cambridge university press, 2005:363-366.
15. David W Stroller, W Dilworth Cannon Jr, Lesley J Anderson. The Knee. In: David W Stroller,editor. Magnetic Resonance Imaging in Orthopaedic & Sports Medicine. 2nd ed. Philadelphia:Lippincott-Raven, 1997: 203-442.
16. Martin L Schwartz. Magnetic Resonance Imaging of knee Ligaments and Tendons. Operative Techniques in Sports Medicine 1995;1:27-34.
17. Michael G. Fox, MR Imaging of the Meniscus: Review, Current Trends, and Clinical Implications; radiolclin N Am 2007;45:1033-1053
19. A. Frick, Doris E. Wenger, Mark Adkins. .MR Imaging of synovial disorders of knee; an update Matthew.Radiolclin N Am, 2007;45:1017-1031.83
20. Wang C-Y, Wang H-K, Hsu C-Y, Shieh J-Y, Wang T-G, Jiang C-C. Role of sonographic examination in traumatic knee internal derangement. Arch Phys Med Rehabil 2007;88: 984 -987
21. Friedman L, Finlay K, Jurriaans E. Ultrasound of the knee. Skeletal Radiol 2001;30:361-377.20 Jill E Langer, Susan J F Meyer, Murray K Dalinka. Imaging of the knee. RadiolClin North Am 1990; 28(5):975-990
22. D Rickards, J A Chapaman. Computed tomography of anterior cruciate ligament. Clinical Radiology 1984;35:327-329
23. Knee arthroscopy. 1st report. University of Maryland: Craig H Bennett, Director of Sports Medicine and Orthopedic Resident, Advanced Medical Technologies; 2004
24. Rangger C, Klestil T, Kathrein A, Inderster A, Hamid L. Influence of magnetic resonance imaging on indications for arthroscopy of the knee. ClinOrthop 1996; 330:133–142.
25. Vaz CES, Camargo OP de, Santana PJ de, Valezi AC. Accuracy of magnetic resonance in identifying traumatic intraarticular knee lesions. Clinics. 2005; 60(6):445-50.
26. Romulo Balthzar, Calvin Ma, Steven Shankman, Javiar Beltran. The Knee. In: John R Haga,Vikram S Dogra, Michael forsting, Robert C Gilkeson, Hyun Kwon

- Ha, MuraliSundaram, editor. CT and MRI of the whole Body. 5th edition. Philadelphia: Elsevier Mosby, 2009:2317-2368.
27. Lee K Siegel MJ, Lau DM. ACL Tears: MR imaging based diagnosis in a pediatric population. *Radiology* 1994; 213:697-704.84
 28. Catherine C. Roberts, Jeffrey D. Towers, Mark J. Spangehl, John A. Carrino, William B. Morrison. Advanced MR Imaging of the Cruciate Ligaments. *Radiolclin N Am* 2007;451003-1016
 29. David A. Turner, Chadwick C. Prodromos, Jerry P. Petasnick, John W. Clark. Acute Injury of the Ligaments of the Knee: Magnetic Resonance imaging. *Radiology* 1985; 154:717-722
 30. Douglas P. Beall, J. David Googe, Jason T. Moss, Justin Q. Ly, Barry J. Greer, Annette M. Stapp, RN, et al. Magnetic Resonance Imaging of the Collateral Ligaments and the Anatomic Quadrants of the Knee. *Radiolclin N Am* 2007; 45:983-1002
 31. Magee T, Williams D. Detection of Meniscal tears and marrow lesions using coronal MRI. *AJR Am J Roentgenol* 2002; 179:641-644
 32. Chung CB, Skaf A, Roger B. Patellar tendon- lateral femoral condyle friction syndrome. MR Imaging in 42 patients. *Skeletal Radiol* 2001;30:697
 33. Tung GA, Davis LM, Wiggins ME. Tears of the anterior cruciate ligament: Primary and secondary signs at MR imaging. *Radiology* 1993;188:661-667
 34. Inder Talwar, Meher Ursekar, Santosh Gupta. Post-traumatic knee-MR Imaging. In: Rajesh Sharma, J P Singh, editors. Proceedings of the 62nd Research Meeting Of Medical Research Centre on medical informatics; 1998 Dec 14; Bombay: India; 1998. p.34-41.
 35. Marc A. Camacho. The Double Posterior Cruciate Ligament Sign. *Radiology* 2004; 233:503-504
 36. Sonin AH, Fitzgerald SW, Friedman H: MR imaging of Posterior cruciate ligament; normal, abnormal and associated injury pattern. *Radiographics* 1995; 15: 551-56185
 37. Grover JS, Bassett LW, Gross ML. Posterior cruciate ligament: MR imaging. *Radiology* 1990;
 38. Akisue T, Kurosaka M, Yoshiya S. Evaluation of healing of the injured posterior Cruciate ligament: analysis of instability and magnetic resonance imaging. *Arthroscopy* 2001;17(3): 264-269.46.

39. Bruno C. Vande Berg, Jacques Malghem, Pascal Poilvache, BaudouinMaldague, Fre´de´ricE.Lecouvet. Meniscal Tears with Fragments Displaced in Notch and Recesses of Knee: MR Imaging with Arthroscopic Comparison. *Radiology* 2005; 234:842–850.
40. Sonin AH, Fitzgerald SW, Bresler ME. MR imaging appearance of the extensor mechanism of the knee: functional anatomy and injury patterns. *Radiographics* 1995; 15:367-375
41. Khan KM, Bonar F, Desmond PM, et al. Patellar tendinosis (Jumper’s knee): findings at histopathologic examination, US, and MR imaging. *Radiology* 1996; 200:821–827.
42. Thomas H. Berquist. Osseous and Myotendinous Injuries About the Knee. *Radiolclin N Am*2007;45: 955-968.
43. Bernard Rosner, Fundamentals of Biostatistics. In: Bernard Rosner, editor. Fundamentals of Biostatistics. 5th ed. Duxbury: Blackwell, 2000; 80-240.
44. M. Venkataswamy Reddy, Statistics for Mental Health Care Research. In: SubbaRao, S Jingar editors, NIMHANS, INDIA 2002.
45. Ali Akbar Esmaili Jah, SohrabKeyhani, Reza Zarei, Ali KalhorMoghaddam. Accuracy of MRI in comparison with clinical and arthroscopic findings in ligamentous and meniscal injuries of the knee: *ActaOrthop. Belg.*, 2005; 71:189-196.
46. Manoj MK, brijesh ray R S, Josenfrancis. Correlation between MRI and arthroscopic findings in injuries of knee joint.2014;18:21.
47. Terry R Yochum, Lindsay j rowe. *Essentials of skeletal radiology*. 2005
48. Jamal Yaqoob,¹ Muhammad Shahbaz Alam,² and Nadeem Khalid³Diagnostic accuracy of Magnetic Resonance Imaging in assessment of Meniscal and ACL tear: Correlation with arthroscopy. *Pak J Med Sci*. 2015 Mar-Apr; 31(2): 263–268.
49. Amreen Abdul Bari, ShivaliVaibhavKashikar, Bhushan Narayan Lakhkar, and Mohammad SaleemAhsan, Evaluation of MRI Versus Arthroscopy in Anterior Cruciate Ligament and Meniscal Injuries *J ClinDiagn Res*. 2014 Dec; 8(12): RC14–RC18.
50. Ketan Gupta, P. N. Kulkarni, NitinPatil. Comparison of MRI Findings with Arthroscopy Findings in Internal Derangement of Knee 2013 pp 159-163.

51. Gupta MK, Rauniyar MK, Karn NK, Sah PL, Dhungel K, Ahmad K¹MRI evaluation of knee injury with arthroscopic correlation. 2014 Jan;12(26):63
52. J C Hughston; G R Barrett .Acute anteromedial rotatory instability. Long-term results of surgical repair. 1983 Feb; 65 (2): 145 -153.
53. Alex Freitas, MD; Chief Editor: Felix S Chew, MD, MBA, Collateral Ligament Injury MRI.Updated: Nov 11, 2015
54. Edwin H.G. Oei, MD, MSc , Abida Z. Ginai, MD, PhD, M.G. MyriamHunink, MD, PhD MRI for Traumatic Knee Injury: A Review April 2007Volume 28, Issue 2, Pages 141–157
55. J Hatch MD, Knee Pain – Diagnosis, Treatment & Surgery JPH 2014-6
56. Mink JH¹, Deutsch AL, Magnetic resonance imaging of the knee. 1989 Jul;(244):29-47
57. Madhusudhan TR¹, Kumar TM, Bastawrous SS, Sinha A, Clinical examination, MRI and arthroscopy in meniscal and ligamentous knee Injuries - a prospective study. 2008 May 19;3:19. doi: 10.1186/1749-799X-3-19.
58. D.H.Solomon MD, MPH, David I Simel MD, MSC Does this patient have a torn meniscus or ligament of knee?.2001 volume 256 no 13
59. BekirYavuzUçar,SerdarNecmio lu,Mehmet Bulut, brahim Azboy, Abdullah Demirta , and HaticeGümü , Determining Bone Bruises of the Knee with Magnetic Resonance Imaging 2012; 6: 464–467
60. Michael R Aiello, MD; Chief Editor: Felix S Chew, MD, MBA, MEd MRI for Posterior Cruciate Ligament Injuries.Updated: Sep 22, 2015
61. Michael R Aiello, MD; Chief Editor: Felix S Chew, MD, MBA, MEd MRI for Posterior Cruciate Ligament Injuries. Updated: Sep 22, 2015
62. William Rodriguez, Jr. Emily N. Vinson Clyde A. Helms Alison P. Toth, MRI Appearance of Posterior Cruciate Ligament Tears AJR 2008; 191:W155–W159
63. Venkateshwaran Arumugam, Ganesan Ram Ganesan, Paarthipan Natarajan MRI Evaluation of Acute Internal Derangement of Knee. Open Journal of Radiology, 2015, 5, 66-71
64. Adil Ismail Nasir. The Role of Magnetic Resonance Imaging in the Knee Joint Injuries Vol. 1(5), 1-7, June (2013)
65. Arthur A. De Smeth, How I Diagnose Meniscal Tears on Knee MRI. AJR:199, September 2012

66. Anton M Allen, MD; Chief Editor: Felix S Chew, MD, MBA, MEd **MRI for Anterior Cruciate Ligament Injury** Jan 24, 2016
67. Laxman Prasad Ahirwar, Chandraprakash Ahirwar, Can MRI Replace Diagnostic Arthroscopy In Evaluation Of Internal Derangement Of Knee Joint – A Prospective Study *Journal of Evolution of Medical and Dental Sciences* 2013; Vol2, Issue 40, October 07; Page: 7621-7631
68. Peleg Ben-Galim, MD et al., Accuracy of Magnetic Resonance Imaging of the Knee and Unjustified Surgery *Clinical Orthopaedics and Related Research* 447(447):100-4.
69. Ruth Crawford, Gayle Walley, Stephen Bridgman, and Nicola Maffulli Magnetic resonance imaging versus arthroscopy in the diagnosis of knee pathology, concentrating on meniscal lesions and ACL tears: a systematic review *Med Bull* (2007) 84 (1): 5-23.doi: 10.1093/bmb/ldm022First published online: September 3, 2007.
70. Kamini Gupta, Munish Guleria, Parambir Sandhu¹, Ritu Galhotra, Correlation of clinical, MRI and arthroscopic findings in diagnosing meniscus and ligament injuries at knee joint: A prospective study.
71. S Gupta, R Sharma, A Sachar, Y Saini, N Saini, Comparison Of Clinical Examination, MRI And Arthroscopy In Knee Injuries. *The Internet Journal of Orthopedic Surgery*. 2012 Volume 19 Number.
72. Inder Talwar, Meher Ursekar, Santosh Gupta, Post-traumatic knee - MR imaging, 62nd Research Meeting Of The Medical Research Centre Of Bombay Hospital On Monday, 14th December 1998.
73. F. Rayan,¹ Sachin Bhonsle,² and Divyang D. Shukla³ Clinical, MRI, and arthroscopic correlation in meniscal and anterior cruciate ligament injuries., 2008 Feb 23. doi: 10.1007/s00264-008-0520-4.
74. DS Shetty, BN Lakhkar, GK Krishna, Magnetic resonance imaging in pathologic conditions of knee Year : 2002 | Volume : 12 | Issue : 3 | Page : 375-381.
75. Romulo Balthazar, Calvin Ma, Steven Shankman, Javier Beltran. *The Knee*. In: John R Haga, Vikram S Dogra, Michael forsting, Robert C Gilkeson, Hyun Kwon Ha, Murali Sundaram, editor. *CT and MRI of the whole Body*. 5th edition. Philadelphia: Elsevier Mosby, 2009:2317-2368.

76. Dr Rajpal Yadav, Dr Devidas S Kulkarni , Dr Siddappa G Gandage , Dr V.N. Marathe , Dr Sushil G Kachewar Radiological Evaluation of Painful Knee
December 2013: Vol.-3, Issue-1, P.136-141

ANNEXURES



**B.L.D.E. UNIVERSITY'S
SHRI.B.M.PATIL MEDICAL COLLEGE, BIJAPUR-586 103
INSTITUTIONAL ETHICAL COMMITTEE**

INSTITUTIONAL ETHICAL CLEARANCE CERTIFICATE

The Ethical Committee of this college met on 22-11-2014 at 3-30pm to scrutinize the Synopsis of Postgraduate Students of this college from Ethical Clearance point of view. After scrutiny the following original/corrected & revised version synopsis of the Thesis has been accorded Ethical Clearance.

Title co-relation of findings of MRI with arthroscopic findings in internal derangement of Knee Joint - A Study

Name of P.G. student Dr. Naveen G. Sheelavant
Dept of Radiology

Name of Guide/Co-investigator Dr. R. C. Pattanshetty prof & HOD.
Dept of Radiology

for 
**DR. TEJASWINI VALLABHA
CHAIRMAN
INSTITUTIONAL ETHICAL COMMITTEE
BLDEU'S, SHRI.B.M.PATIL
MEDICAL COLLEGE, BIJAPUR.**

Following documents were placed before E.C. for Scrutinization

- 1) Copy of Synopsis/Research project.
- 2) Copy of informed consent form
- 3) Any other relevant documents.

Table 13 Demographic details

MR No.	Name	OPD/ Inpatient	Age	Sex	Unit	Date

1. Clinical Parameters.

- a) Mechanism of injury:
- b) Duration of injury:
- c) Clinical findings:

2. Investigation Results

MRI Findings

- a) Joint effusion: Present/Absent
- b) Anterior Cruciate Ligament tear: Present/Absent,
Partial/Complete
- c) Posterior Cruciate Ligament tear: Present/Absent,
Partial/Complete
- d) Medial Collateral Ligament tear : Present/Absent
Grade- 1/2/3
- e) Lateral Collateral Ligament tear: Present/Absent
Grade- 1/2/3
- f) Medial Meniscal Tear : Present/Absent
Location & Type
- g) Lateral Meniscal Tear: Present/Absent

Location & Type

h) Osseous / Osteochondral lesions: Present/Absent

Location & Type

Final MRI Diagnosis.

Arthroscopic findings.

CONSENT FORM

B.L.D.E.U'S SHRI B.M.PATIL MEDICAL COLLEGE HOSPITAL AND

RESEARCH CENTER, BIJAPUR-586103

RESEARCH INFORMED CONSENT FORM

TITLE OF THE PROJECT: "Correlation of findings of MRI with arthroscopic findings in internal derangement of knee joint – A study"

PRINCIPAL INVESTIGATOR: Dr. NAVEEN SHEELAVANT.MBBS

POST GRADUATE

DEPARTMENT OF RADIO DIAGNOSIS

Email: sheelvant.n@gmail.com

P.G.GUIDE:

PROFESSOR

Dr R C Pattanshetti_{MD}

DEPARTMENT OF RADIO DIAGNOSIS

PURPOSE OF RESEARCH:

I have been informed that this study is "Correlation of findings of MRI with arthroscopic findings in internal derangement of knee joint – A study".

I have been explained about the reason for doing this study and selecting me/my ward as a subject for this study. I have also been given free choice for either being included or not in the study.

PROCEDURE:

I/my ward have been explained that, I/my ward will be subjected to MRI scan and arthroscopy.

RISKS AND DISCOMFORTS:

I/my ward understand that necessary measures will be taken to reduce these complications as and when they arise.

BENEFITS:

I/my ward understand that my participation in this study will help to MRI knee with arthroscopy.

CONFIDENTIALITY:

I/my ward understand that medical information produced by this study will become a part of this Hospital records and will be subjected to the confidentiality and privacy regulation of this hospital. Information of a sensitive, personal nature will not be a part of the medical records, but will be stored in the investigator's research file and identified only by a code number. The code key connecting name to numbers will be kept in a separate secure location.

If the data are used for publication in the medical literature or for teaching purpose, no names will be used and other identifiers such as photographs and audio or video tapes will be used only with my special written permission. I understand that I may see the photograph and videotapes and hear audiotapes before giving this permission.

REQUEST FOR MORE INFORMATION:

I understand that I may ask more questions about the study at any time. Dr. Naveen S is available to answer my questions or concerns. I/my ward understand that I will be

informed of any significant new findings discovered during the course of this study, which might influence my continued participation.

If during this study, or later, I wish to discuss my participation in or concerns regarding this study with a person not directly involved, I am aware that the social worker of the hospital is available to talk with me and that a copy of this consent form will be given to me for careful reading.

REFUSAL OR WITHDRAWAL OF PARTICIPATION:

I/my ward understand that my participation is voluntary and I may refuse to participate or may withdraw consent and discontinue participation in the study at any time without prejudice to my present or future care at this hospital.

I/my ward also understand that Dr. Naveen will terminate my participation in this study at any time after he has explained the reasons for doing so and has helped arrange for my continued care by my own physician or therapist, if this is appropriate.

INJURY STATEMENT:

I understand that in the unlikely event of injury to me/my ward, resulting directly to my participation in this study, if such injury were reported promptly, then medical treatment would be available to me, but no further compensation will be provided.

I understand that by my agreement to participate in this study, I am not waiving any of my legal rights.

I have explained to _____ the purpose of this research, the procedures required and the possible risks and benefits, to the best of my ability in patient's own language.

Date:

Dr.R C Pattanshetti
(Guide)

Dr. Naveen S
(Investigator)

STUDY SUBJECT CONSENT STATEMENT:

I/my ward confirm that Dr. Naveen S. has explained to me the purpose of this research, the study procedure that I will undergo and the possible discomforts and benefits that I may experience, in my own language.

I/my ward have been explained all the above in detail in my own language and I understand the same. Therefore I agree to give my consent to participate as a subject in this research project.

(Participant)

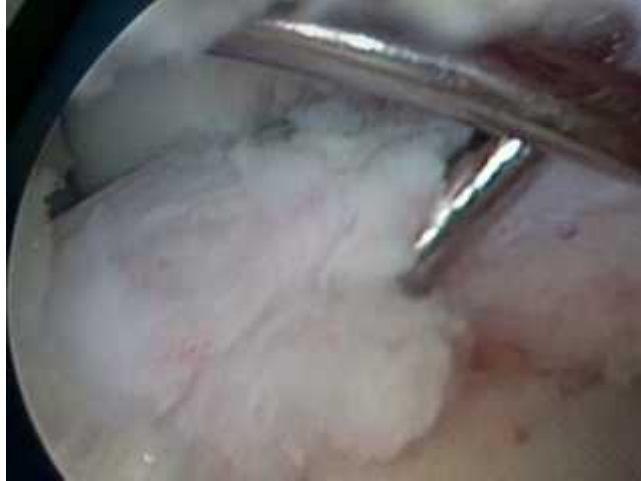Date

(Witness to above signature)

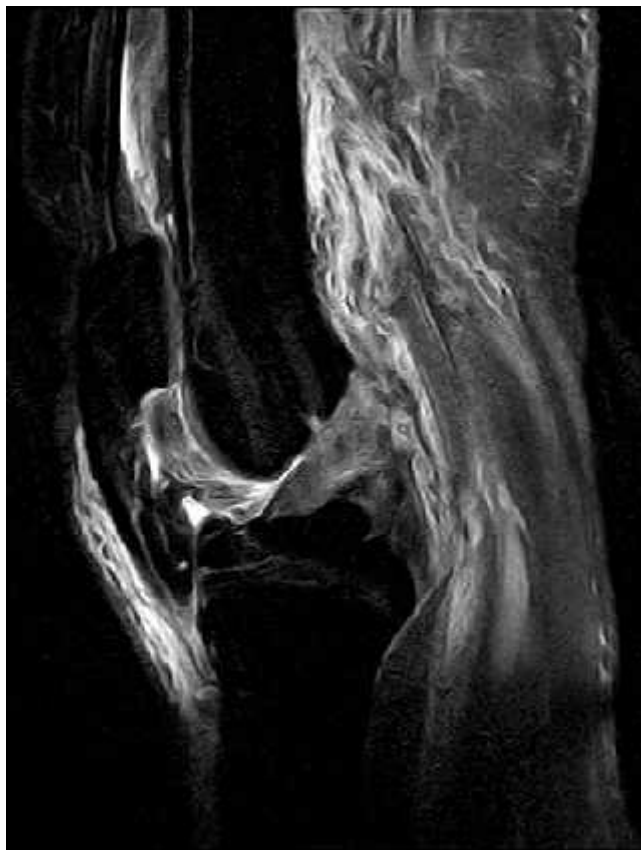Date

CASES

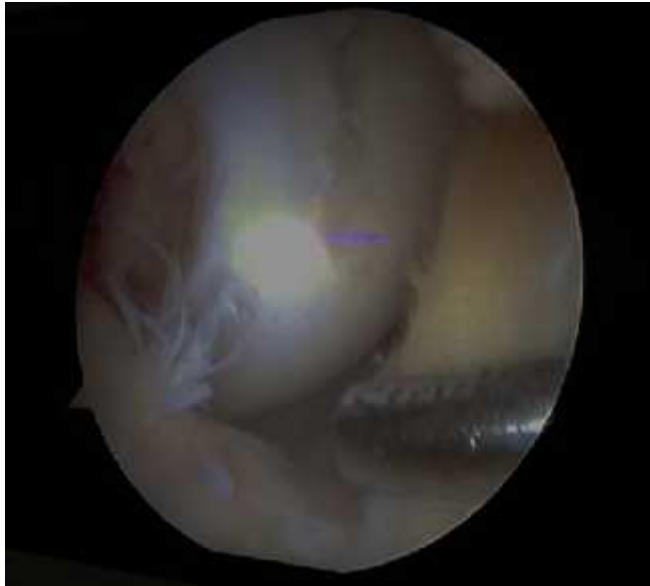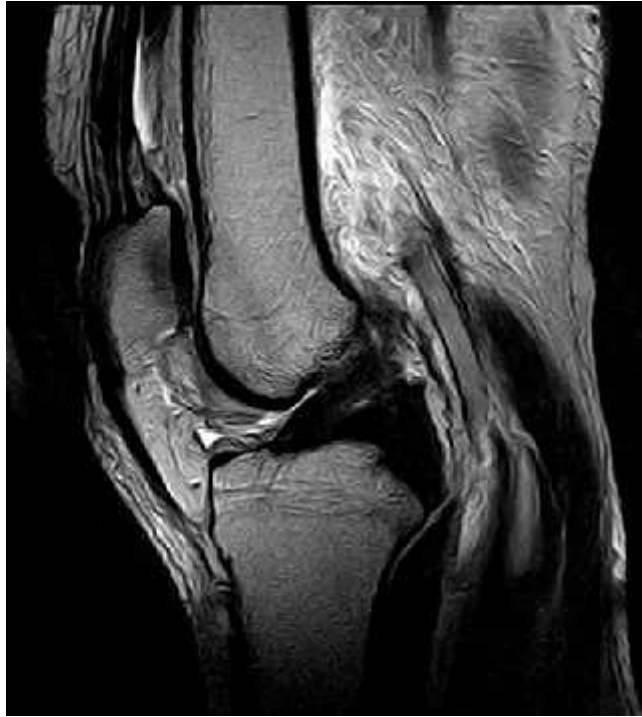History and presentation a 32 year old male presented with knee pain.



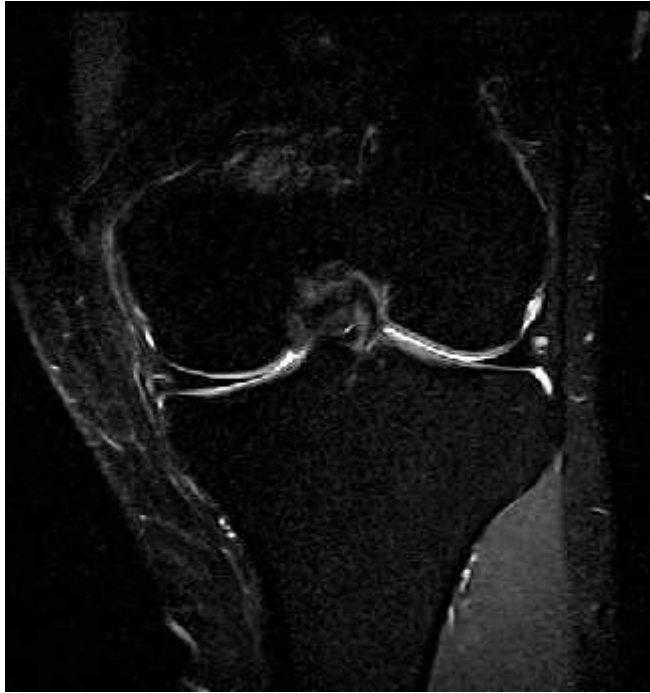Arthroscopy shows mid substance tear.



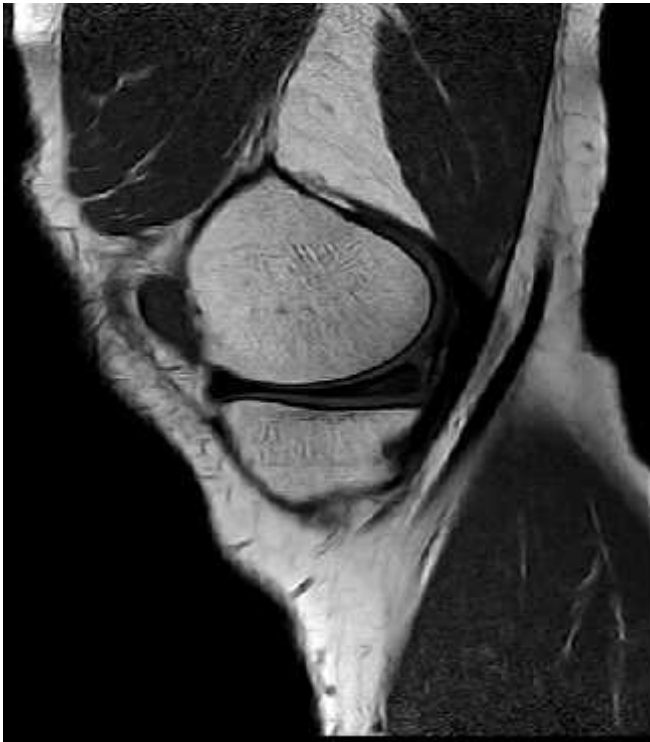MRI on PD sequences shows altered signal changes in ACL.

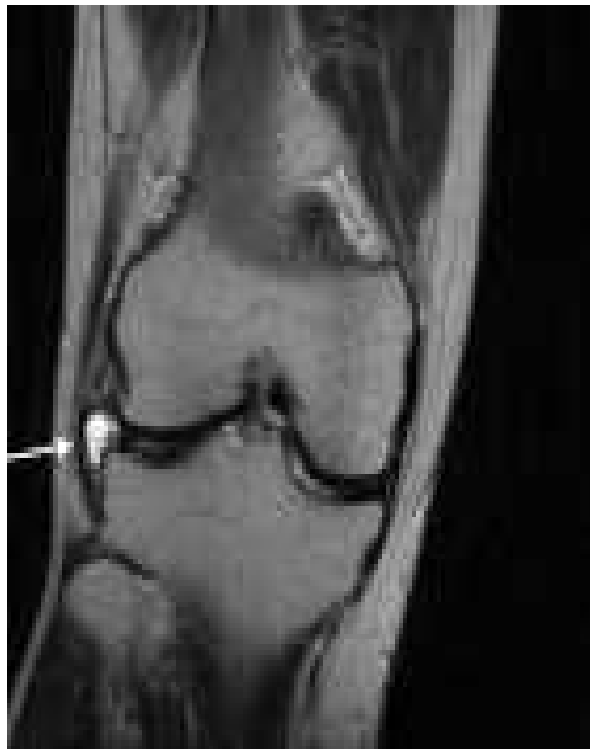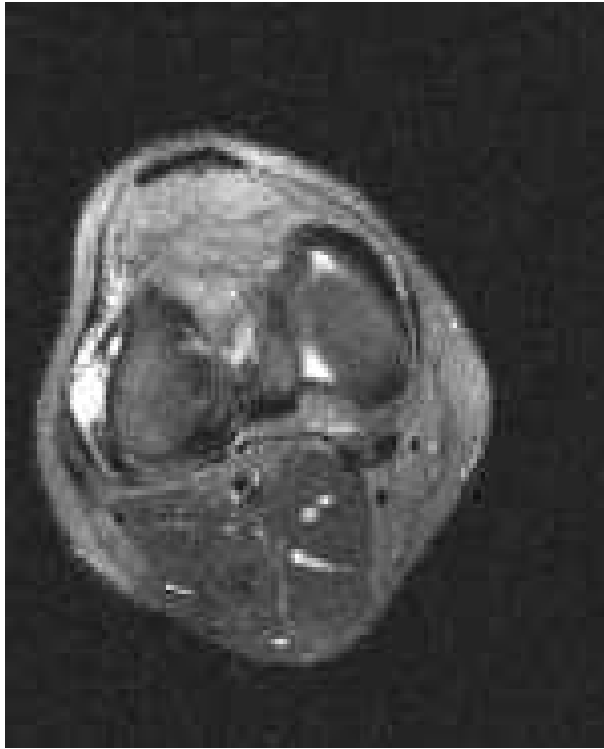


Arthroscopy shows meniscal tear on lateral meniscus.

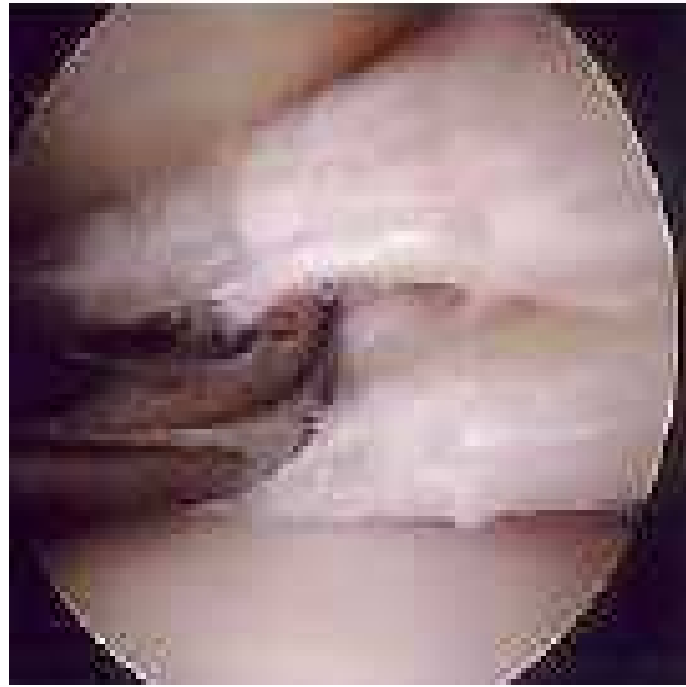

PD/T1WI shows horizontal tear on lateral meniscus.





MRI on axial/sagittal section on PD/T2WI sequence shows small cystic lesion lateral meniscus.



Arthroscopy shows small cystic lesion lateral meniscus.

MASTER CHART

Sl No	Age	Duration of injury	Joint effusion	ACL tear	PCL tear	MCL tear	LCL tear	MM tear	LM tear	Oseous /osteochondral lesions	Final diagnosis	Arthroscope
1	46 years	1week	Yes with popliteal cyst	yes, partial	No	No	No	Yes, grade 3	No	No	Partial tear Lt ACL, Grade 3 tear of medial meniscus and popliteal cyst.	Yes partial tear with grade 3 medial meniscus tear.
2	27 year	5 years	No	yes, partial	No	No	No	No	No	Yes	Osteoarthritis, ACL tear	No
3	29 years	3 week	yes	No	No	No	No	No	No	No	partial tear right PCL.	Yes partial tear of PCL
4	32 years	2 week	No	yes, partial	No	No	No	No	Grade 2 paramenisc	No	partial tear of ACL,Parameniscal cyst of lateral meniscus.	Partial tear of ACL
5	24 years	5 days	yes	No	No	No	No	No	No	No	fracture of lateral condyle with joint effusion	No
6	33 years	2 days	yes with lipohemarthrosi	yes,partial tear	No	Yes grade 3	Yes	No	No	No	comminuted bicondylar tibial #right lipohemarthrosis, partial ACL tear, grade 3 tear	yes partial ACL tear with grade 3 LM, Grade 3 tear of
7	29 years	3 years	Yes	Partial tear	No	yes grade 1	No	Yes, grade 3	No	No	partial tear ACL with grade 3 MM tear and grade 1 tear MCL.	Yes partial tear of ACL, Medial meniscus tear.
8	24 years	1 week	Yes	Complete tear	No	No	No	yes grade 2	No	Yes	Complete tear of ACL,Grade 2 tear MM with bony contusions.	Complete ACL tear
9	39 years	10 days	Yes	Complete tear	No	No	No	No	No	yes	Complete ACL tear and bone contusion	Complete ACL tear
10	31 years	2 weeks	No	Complete tear	No	No	No	No	No	No	Complete ACL Tear at its femoral attachment	Complete ACL tear
11	26 years	1 week	No	No	No	yes grade 2	No	No	No	yes	Grade 2 MCL Tear	Yes MCL tear
12	20 years	2 weeks	Yes	Yes complete	No	No	No	No	No	yes	Complete tear of ACL with bony contusions.	Complete ACL tear
13	31 years	3 weeks	Yes	Yes complete	No	No	No	No	No	No	Complete ACL tear its femoral attachment.	Complete ACL tear
14	30 years	4 weeks	Yes	No	No	Yes, grade 2	No	No	No	Yes grade 3 with parameniscal cyst	Grade 2 MM with parameniscal cyst,grade 2 tear of MCL with contusion medial femoral condyle.	MM tear
15	32 years	1 week	Yes	No	No	No	No	Grade 3 MM	No	No	Grade 3 MM	MM tear
16	43 years	2 weeks	No	No	No	Grade 3 MCL Tear	No	Grade 3 MM	No	Yes	Grade 3 MCL, Grade 3 tear of medial meniscus & bony contusions.	MCL Tear with no MM Tear
17	52 years	1 weeks	No	No	No	No	No	No	Grade1	Yes	Grade 1 LM tear with grade II osteochondral fracture lateral condyle of tibia.	LM Tear
18	35 years	1 weeks	No	Yes complete tear	No	No	No	grade 3 MM tear	No	No	Complete tear ACL and grade 3 tears of MM	Complete ACL tear with associated MM tear
19	32 years	6 weeks	No	Partial tear	No	No	No	No	No	No	Partial tear of ACL	Partial tear of ACL
20	23 years	4 weeks	Yes	No	No	No	Grade 3 LCL tear	No	No	No	Grade 3 LCL tear with joint effusion.	LCL tear with MM
21	28 years	2 weeks	No	Partial tear	No	No	grade 2 tear	No	No	No	Grade 2 tear of LCL with partial tear of ACL Tear.	Partial tear ACL
22	34 years	3 weeks	Yes	No	Partial tear	No	No	No	No	No	partial tear of PCL Tear.	Partial tear of PCL
	32 years	3 weeks	Yes	No	Partial tear	No	grade 2 tear	No	No	No	Partial tear of PCL tear with grade 2 tear of LCL	Partial tear of PCL

24	45 years	5 weeks	Yes	partial tear	No	No	No	No	No	No	joint effusion with partial tear ofACL.	Partial tear of ACL.
25	42 years	5 weeks	No	patial tear	No	Partial tear	No	Partial	No	No	Partial tear of ACL with partlal tear of medial meniscus	Partial tear ACL with partial tear of MM
26	40 years	4 weeks	No	No	partial tear	No	No	No	No	No	partial tear of PCL Tear.	Partial tear of PCL Tear.
27	36 years	3 weeks	Yes	Partial tear	No	No	No	No	No	No	partial tear of ACL	Partial tear of ACL
28	32 YEARS	1 Weeks	No	No	Yes	No	No	No	No	No	Partial tear of PCL	Partial tear ofPCL
29	22 years	2 weeks	Yes	No	No	No	No	No	No	No	Joint effusion.	Synovitis
30	26 years	3 weeks	Yes	No	No	Yes	No	No	No	yes	Joint effusion with partial tear of MCL with contusions of medial condyle.	Partial tear of MCL
31	38 Years	2 weeks	Yes	Yes	No	No	No	No	No	Medial condyle contusions	Joint effusion with Partial ACL tear with medial condyle contusions	Complete tear of ACL
32	39 years	3 weeks	Yes	Yes	No	No	No	No	No	paramenical cyst.	Joint effusions with Complete ACL tear and paramensical cyst.	Complete ACL tear
33	36 Years	2 weeks	Yes	No	No	No	Grade 1 tear	No	No	No	Grade 1 tear of LCL.	