

Original Research Article

Functional outcome of fenestration discectomy in discogenic lumbar canal stenosis

Nitin Lalbabu Singh, Raghavendra Kembhavi*, R. Vijayakumaran

Department of Orthopedics, Sri Lakshmi Narayana Institute of Medical sciences, Pondicherry, India

Received: 27 June 2019

Revised: 13 August 2019

Accepted: 14 August 2019

*Correspondence:

Dr. Raghavendra Kembhavi,

E-mail: kembhavi.raghavendra@gmail.com

Copyright: © the author(s), publisher and licensee Medip Academy. This is an open-access article distributed under the terms of the Creative Commons Attribution Non-Commercial License, which permits unrestricted non-commercial use, distribution, and reproduction in any medium, provided the original work is properly cited.

ABSTRACT

Background: Annual incidence of significant disc herniation causing sciatica ranges from 14% to 15%. In spite of various treatment modalities available, fenestration discectomy still remain treatment of choice for discogenic lumbar canal stenosis. The objective of our study is to assess functional outcome and complications associated with fenestration discectomy in patients of discogenic lumbar canal stenosis.

Methods: Thirty two patients who had unilateral radicular pain with clinicoradiologically confirmed posterolateral disc herniation and who failed to respond to conservative management were treated surgically by fenestration discectomy. Outcome was assessed using Oswestry disability index at 6 months follow up.

Results: Patients with neurological deficits underwent fenestration discectomy with complete relief of radicular pain in 17 patients and mild reduction in 5 patients on follow up. 23 patients had recovery from motor symptoms and 25 patients had recovery from sensory symptoms whereas 9 patients still had motor weakness and 7 patients still had sensory deficit. Oswestry disability index (ODI) score used for functional outcome at 6 months postoperatively showed 63% of the patients were having 0 to 20 ODI score with minimal disability, 34% of the patients had score of 21 to 40% with moderate disability, and 3% were having 41 to 60% ODI score with severe disability. One patient had dural tear and two patients had post-operative discitis.

Conclusions: Fenestration discectomy is an excellent surgical option for discogenic lumbar canal stenosis. Fenestration discectomy is an easy, economical and effective means of treating lumbar disc prolapse with minimal acceptable complications.

Keywords: Disc degeneration, Laminectomy, Spinal instability, Radicular pain, Oswestry disability index

INTRODUCTION

Lumbar disc disease is one of the most common cause of low back pain through the world especially in the age group of more than 45 years and single most common cause of disability in that age group.¹⁻³ Other causes of back pain being facet joint hypertrophy, prolapsed disc, spondylosis and spondylolisthesis. Along with causing disability, low back pain is major cause of economic burden particularly when it is chronic back problem, that is back pain of more than 12 weeks duration.⁴ It causes

lot of disability and distress to the patient along with suffering associated with the clinical symptoms. As the disease is mostly chronic or acute superimposed on a chronic back pain it leads to severe depression to the patient and the family members.

Spinal canal stenosis can be classified primary or secondary wherein primary canal stenosis are due to congenital abnormalities and secondary canal stenosis are due to degenerative changes, trauma, infection or following surgery.⁵ Degenerative disc disease are leading

causes of disc herniation, facet joint arthropathy and spinal canal stenosis. Disc degeneration leads to reduced height of disc space which in turn leads to increased stress on facet joint resulting in facet joint arthropathy.⁶ Spinal canal stenosis which are most commonly due to degenerative causes can be classified anatomically into central, lateral recess, foraminal or combination of either of these.⁷ Central canal stenosis results from reduced anteroposterior or transverse diameter of canal due to reduced disc space along with thickened ligamentum flavum, hypertrophy of facet joint and disc bulges. On the other hand foraminal stenosis are nerve root exit narrowing caused by reduced intervertebral disc height, facet joint arthropathy, cephalad subluxation of the superior articular process of the inferior vertebra or soft tissue compressions in the form of buckled ligamentum flavum or protruded annulus fibrosus.¹⁰

Symptomatology in spinal canal stenosis includes low back pain, neurological claudication, weakness, fatigue, paraesthesia, nocturnal leg cramps and bladder symptoms.⁷⁻⁹ Neurological claudication due to central canal stenosis are often bilateral whereas radicular symptoms due to foraminal or lateral recess are generally unilateral.

Even though various conservative treatment modalities including patient education, rest, traction, physiotherapy and epidural steroid are available, surgical removal of offending disc offers a simple and effective means to get relieved from symptoms of lumbar disc herniations.

Laminectomy is most commonly performed surgery for degenerative lumbar canal stenosis first described by Dr. Victor Alexander Haden Horsley in 1887 is an effective procedure to relieve symptoms.¹¹ However extensive laminectomy was associated with significant instability and the advent of newer technique by Love who devised inter-laminar fenestration for treatment of lumbar disc prolapsed, laminectomy is no longer surgery of choice for disc herniation.¹²

Advantages of fenestration discectomy includes decrease incidence of post-operative spinal instability, least manipulation of normal anatomical structures thus preventing post-operative peri-neural fibrosis. Studies like Mishra et al, which compared laminectomy and fenestration for disc excision concluded the superiority of latter approach in respect to early postoperative mobilization, early return to work and low incidence of postoperative backache as it is less extensive.¹³

Even though newer techniques like microdiscectomy and endoscopic discectomy has better advantages in terms of duration of surgery, amount of blood loss, need of analgesics and post-operative hospital stay, it needs lot of expertise, experience and expensive equipment's which are not available at every centres. Also long term outcome in terms of improvement in signs and symptoms has found to be same as compared to fenestration discectomy which can be done by majority of Orthopaedic surgeons and can be carried out even at peripheral centre. In this study we studied functional outcome of discogenic lumbar canal stenosis managed by fenestration discectomy.

METHODS

This prospective study was conducted at Sree Lakshmi Narayana Institute of Medical Sciences, Pondicherry between August 2014 to August 2016 after receiving clearance from ethical committee. All the patients with failed conservative treatment for 6 weeks, acute unilateral radicular pain, progressive neurological deficit, single disc level involvement, clinic-radiological documented lumbar disc herniation by magnetic resonance imaging (MRI) and patients with cauda equina syndrome were included in the study. Patients with unstable spine, disc prolapse with discitis, central canal stenosis, congenital narrow canal, recurrent disc herniation and failed back syndrome were excluded from the study. Data were statistically evaluated with SPSS Software (IBM Version-20).

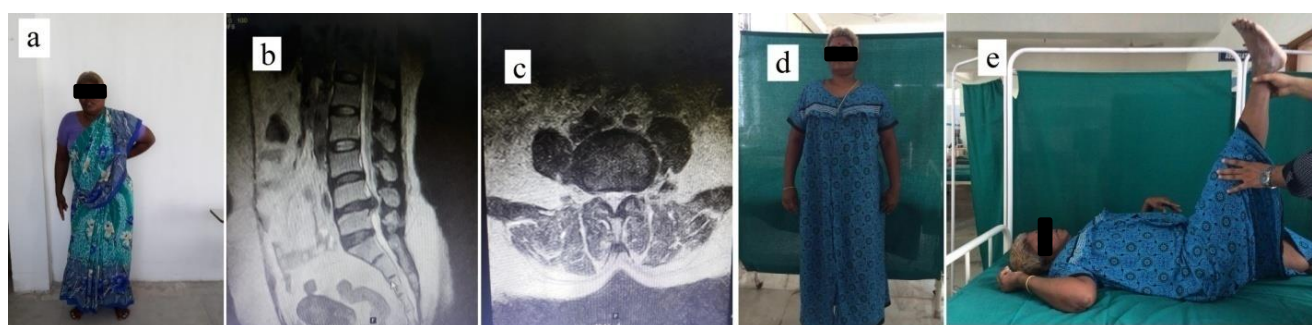


Figure 1: (A) Preoperative sciatic list due to nerve root irritation; (B and C) MRI sagittal and axial T2W images of L4-L5 disc prolapsed; (D and E) postoperative pictures showing disappearance of sciatic list and negative SLRT following fenestration discectomy.

Patients who consulted our outpatient and casualty for radicular low back pain with were thoroughly examined and those satisfying inclusion criteria were included in

the study. Most patients presented with sciatic list due to nerve root irritation (Figure 1). Radiological examination with plain radiography of lumbo sacral spine

anteroposterior and lateral view, flexion- extension lateral view, MRI of lumbosacral spine and if needed computed tomography (CT) of lumbosacral spine(to rule out any bony stenosis) were done to confirm clinical diagnosis, to identify the level and to know type of herniation along with its anatomical location in the canal.

After confirmation, relevant investigation was done and fitness was obtained for surgery. After required consent patient were treated by open fenestration and discectomy.

All patients were operated in prone modified kneeling position under general anaesthesia. Bolsters were placed longitudinally under patient's side so that the abdomen hangs freely thus allowing free abdominal movements during breathing and also leading to reduced venous plexus filling around spinal cord which leads to collapse of epidural venous plexus hence blood loss is reduced during surgery. Adequate padding of elbow and wrist is done to prevent injury to ulnar and median nerve respectively. Level of discectomy is confirmed under fluoroscopic guidance. Midline longitudinal incision is made extending one spinous process above and one spinous process below the pathological level. After incising superficial fascia, lumbodorsal fascia & supraspinous ligament paraspinal muscles are elevated. Haemostasis is maintained using bipolar electrocautery. The level is re-confirmed, ligamentum flavum excised upper 3rd or lower 3rd of lamina nibbled. Nerve root retracted and underlying disc visualized. An incision is made over annulus and disc fragments are removed. The exiting nerve root is checked for free mobility within foraminal canal & any adhesion. Free movement of nerve injury signifies that the nerve root is adequately decompressed and procedure is complete. The exposed dural surface is covered with gel foam. Incision is closed in layers with suction drain.

Postoperatively core strengthening is started between 1st and 3rd post-operative weeks provided that pain is minimal. Lifting, bending, and stooping are gradually restarted after 3 weeks. Increased sitting is allowed as pain permits, but long drives are to be avoided for at least 4 to 6 weeks. Patients with jobs requiring much walking without lifting are allowed to return to work within 2 to 3 weeks. Patients with jobs requiring prolonged sitting are allowed to return to work within 4 to 6 weeks. Patients with jobs requiring heavy labor or long periods of driving are not allowed to return to work until 6 to 8 weeks.

Functional outcome was analyzed based on ODI (Oswestry disability index) score at 6 months.

RESULTS

The present prospective study consisted of 32 patients with 19 male patients and 13 female patients. Patients were grouped as performing heavy work (n=21) and normal work (n=11) based on their profession. Patients presented with symptoms of back pain, radicular pain,

sensory motor deficit wherein radicular pain was predominant (n=22) than back pain (n=10). 12 patients had left sided radicular pain while 20 had right sided (Table 1).

Table 1: Profile of patients with respect to age, sex and symptomatology.

Variable		No. of cases	Percentage (%)
Sex	Male	19	59
	Female	13	41
Occupation	Heavy work	21	66
	Normal work	11	34
Pain	Back>radicular	10	31
	Radicular>back	22	69
Side	Left	12	62
	Ride	20	38

Table 2: Preoperative sensory deficits.

Dermatome	No. of cases	Percentage (%)
L4	4	12.5
L4 & L5	5	15.6
L5	17	53.1
L5 & S1	2	6.2
No deficit	4	12.5
Total	32	100

Table 3: Preoperative motor deficits.

Root value	Power	No. of cases	Percentage (%)
L4	3/5	2	6
L4	4/5	4	12
L5	3/5	12	38
L5	4/5	12	38
S1	3/5	2	6
S1	4/5	0	0
Total		32	100

Table 4: Preoperative SLRT (straight leg rising test).

SLRT	No. of cases	Percentage (%)
0-35	23	72
36-70	8	25
>70	1	3
Total		100

All the patients had sensory motor deficits in which L5 dermatomal sensory loss was seen in most patients (53.1%) and combined L5 S1 dermatomal sensory loss were least (6.2%). Similarly most patients showed motor weakness in L5 nerve root with maximum weakness of 3/5 (Table 2 and 3). Straight leg rising test (SLRT) too was elicited in all the patients with most patients showing SLRT at around 35° (72%) (Table 4).

All the patients underwent fenestration discectomy on the involved level without any wrong level surgery. Mean operative time was 105.2 mins. Average blood loss was 96.7 ml.

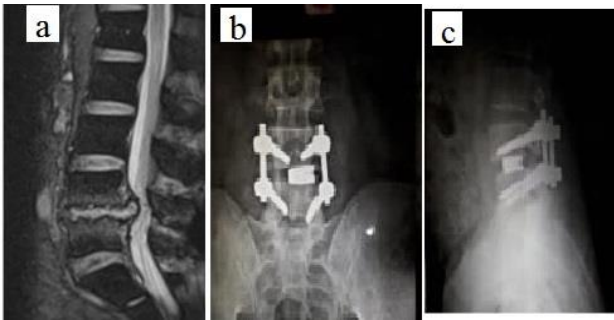


Figure 2: (A) Discitis following fenestration discectomy; (B and C) patient was operated with curettage, stabilization with fusion.

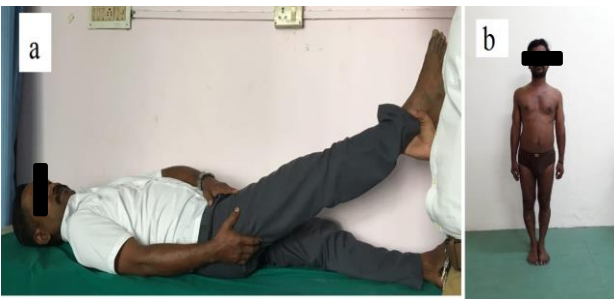

Figure 3: (A) Patient with discitis preoperative and (B) postoperative with curettage stabilization and fusion.

One patient had dural tear and was repaired with 4-0 simple running stitch whereas two patients had post-operative discitis. Out of two patient with discitis one patient recovered well with conservative management and antibiotics while other patient failed conservative management and was treated with curettage, stabilization with fusion (Figure 2 and 3).

On follow up 17 out of 22 patients having radicular pain had complete relief of symptoms (Figure 1) whereas 5 patients had mild reduce in radicular pain as compared to preoperative pain. Also 5 patients out of 10 had complete relief of back pain whereas 5 patients still had mild to moderate degree of back pain. 23 patients had recovery from motor symptoms and 25 patients had recovery from sensory symptoms whereas 9 patients still had motor weakness and 7 patients still had sensory deficit. On follow up 23 patients had negative SLRT (Figure 1), 6 patient had SLRT within 30° to 70°, 2 patient had more than 70 SLRT whereas 1 patient had less than 30 SLRT.

ODI score was used to calculate the functional outcome at 6 months postoperatively wherein 63% of the patients were having 0 to 20 ODI score and found to have minimal disability, 34% of the patients were having 21 to

40% ODI score and found to have moderate disability, 3% were having 41 to 60% ODI score and found to have severe disability. None of the patients were having 61 to 80% ODI score or Crippled and none of the patients were having 81 to 100% ODI score and were bed bound (Figure 4).

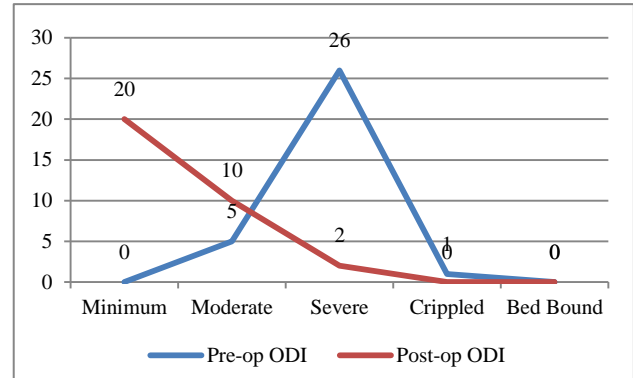


Figure 4: Improvement in ODI score done at 6 months postoperatively.

All the patients resumed their work after 3 months postoperatively. One patient with severe disability was advised for change of heavy job to lighter occupation permanently.

DISCUSSION

Low back pain is one of the major debilitating condition leading to significant morbidity. According to Damian et al, estimates from global burden of disease 2010 study low back pain ranked highest in terms of disability and sixth in terms of overall burden.¹⁴

Although various factors has been associated for low back pain which leads to excessive stress over lumbar spine which includes work associated with repeated bending and twisting, lifting heavy weight, long duration standing and sitting in wrong posture, travelling long distances which leads to over stress of paraspinal muscles, ligaments joints and disc and may act as pain generators in low back ache. Lumbar degenerative disc disease being major cause of low back pain results from multiple risk factors like increase in age, torsional stress on back, cigarette smoking, obesity, lifting heavy weight, vibration on spine due to travelling in jerky roads, injury, immobilization, hereditary and genetic factors, occupations which demand heavy weight lifting or prolonged sitting.¹⁵⁻¹⁷

Age and gender variations in the presentations of degenerative disc diseases are quite obvious. Consistent with other studies, our study too showed higher number of disc bulges and canal stenosis in male patients compared to female patients considering increased mechanical stress and injury in male patients.¹⁸ Few studies have shown that lower level disc bulges are

commoner in younger patients compared to elderly people where disc bulges are seen in higher levels.¹⁹ Similarly in our study too, disc degenerations were predominantly seen in lower levels (L4, L5, S1) considering younger group of population in our study.

The relationship between disc herniation and radicular or back pain is still incompletely understood, although various suggested mechanism have been postulated from time to time by different authors. Radicular pain is produced by irritation or inflammation of nerve roots. Inflammation may be produced by prolonged neuroischaemia of the microvasculature of the nerve root from mechanical compression.²⁰ However recent studies shows that sciatica is not only due to mechanical factors but it is also due to bio chemical factors like tumour necrosis factor (TNF- α).²¹

When conservative treatment fails surgical management is next line of option. Most commonly done surgery in failed cases symptomatic degenerative disc disease include decompressive laminectomy. However considering the extensive nature of surgery, laminectomy frequently leads to spinal instability due to disruption of posterior stabilizing structures.²² This spinal instability has to be managed spinal fusion particularly in the cases of preexisting spinal instability. However such fusion severely restricts spinal mobility and can be functionally incapacitating to patients.²³

Therefore minimally invasive procedures like fenestration discectomy have evolved over the years to combat instability associated with extensive procedures like laminectomy. It also carries added advantage like minimal blood loss during surgery, less operative time, faster recovery and rehabilitation and fewer complications like adhesions and arachnoiditis.²⁴

ODI was used to analyse functional outcome by comparing pre-operative and post-operative ODI score. Mean pre-operative ODI value was 44.91 with standard deviation of 6.86 which was reduced significantly to 19.19 with standard deviation of 11.50 ($p < 0.0001$). The finding correlates well with the other studies like Ranganath et al.²⁵

CONCLUSION

Fenestration discectomy for discogenic lumbar canal stenosis is effective and safe procedure with excellent functional outcome for properly selected cases in discogenic lumbar canal stenosis with advantage of less operative time, minimal blood loss, less extensive and its devoid of instability compared to laminectomy.

Funding: No funding sources

Conflict of interest: None declared

Ethical approval: The study was approved by the institutional ethics committee

REFERENCES

1. Choi YS. Pathophysiology of degenerative disc disease. *Asian Spine J.* 2009;3:39–44.
2. Quint U, Wilke HJ. Grading of degenerative disk disease and functional impairment: imaging versus patho-anatomical findings. *Eur Spine J.* 2008;17:1705–13.
3. Palepu V, Kodigudla M, Goel VK. Biomechanics of disc degeneration. *Adv Orthop.* 2012;2012:726210.
4. Balagué F, Mannion AF, Pellisé F. Non-specific low back pain. *Lancet.* 2012;379(9814):482–91.
5. Ciricillo SF, Weinstein PR. Lumbar spinal stenosis. *West J Med.* 1993;158(2):171–7.
6. Saleem S, Aslam MH, Khan Rehmani MA, Raees A, Alvi AA, Ashraf J. Lumbar Disc Degenerative Disease: Disc Degeneration Symptoms and Magnetic Resonance Image Findings. *Asian Spine J.* 2013;7(4):322–34.
7. Genevay S, Atlas SJ. Lumbar Spinal Stenosis. *Best Pract Res Clin Rheumatol.* 2010;24(2):253–65.
8. Matsumoto M, Watanabe K, Tsuji T, Ishii K, Takaishi H, Nakamura M. Nocturnal leg cramps: a common complaint in patients with lumbar spinal canal stenosis. *Spine.* 2009;34(5):E189–94.
9. Inui Y, Doita M, Ouchi K, Tsukuda M, Fujita N, Kurosaka M. Clinical and radiologic features of lumbar spinal stenosis and disc herniation with neuropathic bladder. *Spine.* 2004;29(8):869–73.
10. Hasegawa T, An HS, Houghton VM, Nowicki BH. Lumbar foraminal stenosis: critical heights of the intervertebral discs and foramina: a cryomicrotome study in cadavera. *J Bone Joint Surg Am.* 1995;77:32–8.
11. Slatys P, Malmivaara A, Heliovaara M, Sainio P, Herno A, Kankare J, et al. Long-term results of surgery for lumbar spinal stenosis: Arandomised controlled trial. *Eur Spine J.* 2011;20(7):1174–81.
12. Chen HT, Tsai CH, Chao SC, Kao Th, Chen YJ, Hsu Hc, et al. Endoscopic discectomy of L5- S1 disc herniation via an interlaminar approach: Prospective controlled study under local and general anaesthesia. *Surgical Neurology Int.* 2011;2:93.
13. Mishra SK, Mohapatra NC, Pradhan NK, Mohapatra MK. Lumbar disc excision: comparative study of laminectomy and interlaminar fenestration. *Indian J Orthop.* 1998;32(3):153-5.
14. Hoy D, March L, Brooks P, Blyth F, Woolf A, Bain C. The global burden of low back pain: estimates from the global burden of disease 2010 study. *Ann Rheum Dis.* 2014;73:968–74.
15. Baldwin NG. Lumbar disc disease: the natural history. *Neurosurg Focus.* 2002;13:2.
16. Katz JN. Lumbar disc disorders and low-back pain: socioeconomic factors and consequences. *J Bone Joint Surg Am.* 2006;88(2):21–4.
17. Luoma K, Vehmas T, Riihimaki H, Raininko R. Disc height and signal intensity of the nucleus pulposus on magnetic resonance imaging as

- indicators of lumbar disc degeneration. *Spine* 2001;26:680–6.
18. de Schepper EI, Damen J, van Meurs JB, Ginai AZ, Popham M, Hofman A, et al. The association between lumbar disc degeneration and low back pain: the influence of age, gender, and individual radiographic features. *Spine* 2010;35:531–6.
 19. Wang YX, Griffith JF. Effect of menopause on lumbar disc degeneration: potential etiology. *Radiology*. 2010;257:318–20.
 20. Cornefjord M, Sato K, Olmarker K, Rydevik B, Nordborg C. A model for chronic nerve root compression studies: presentation of a porcine model for controlled, slow-onset compression with analyses of anatomic aspects, compression onset rate, and morphologic and neuro-physiologic effects. *Spine*. 1997;22:946–57.
 21. Mulleman D, Mammoub S, Griffoulb I, Watier H, Goupille P. Pathophysiology of disk-related sciatica. I.--Evidence supporting a chemical component. *Joint Bone Spine*. 2006;73:151–8.
 22. Chakrabarty PS. Excision of lumbar disc through fenestration: A Prospective study to analyse functional results. *Ind J Med Res Pha Sci*. 2015;2(1):10–3.
 23. Thomsen K, Christensen FB, Eiskjaer SP, Hansen ES, Fruensgaard S, Bunger CE: Volvo Award winner in clinical studies. The effect of pedicle screw instrumentation on functional outcome and fusion rates in posterolateral lumbar spinal fusion: a prospective, randomized clinical study. *Spine*. 1997;22:2813-22.
 24. Garg M, Kumar S. Interlaminar discectomy and selective foraminotomy in lumbar disc herniation. *J Orth Surg*. 2001;9:15–8.
 25. Ranganath HD, Sridhara Murthy JN, Prabu M. Effectiveness of open discectomy for IVDP- A prospective study. *J Evol Med Dental Sci*. 2014;3(6):1346-53.

Cite this article as: Singh NL, Kembhavi R, Vijayakumaran R. Functional outcome of fenestration discectomy in discogenic lumbar canal stenosis. *Int J Res Orthop* 2019;5:xxx-xx.