



# International Journal of Orthopaedics Sciences

E-ISSN: 2395-1958  
P-ISSN: 2706-6630  
IJOS 2020; 6(1): 658-662  
© 2020 IJOS  
[www.orthopaper.com](http://www.orthopaper.com)  
Received: 06-11-2019  
Accepted: 10-12-2019

**Abhinav Kumar**  
Shri B. M. Patil Medical College  
and Research Center,  
Vijayapura, Karnataka, India

**Dr. Ashok R Nayak**  
Professor and H.O.D, Dept of  
orthopaedics S.B.M.P.M.C.,  
Vijayapura, Karnataka, India

**Dr. Dayanand BB**  
Professor, Unit Head, Dept of  
orthopaedics, S.B.M.P.M.C.,  
Vijayapura, Karnataka, India

**Dr. Rajkumar M Bagewadi**  
Assistant professor, Dept of  
orthopaedics, S.B.M.P.M.C.,  
Vijayapura, Karnataka, India

**Dr. Srikant Kulkarni**  
Senior Resident, Dept of  
orthopaedics, S.B.M.P.M.C.,  
Vijayapura, Karnataka, India

## Study the functional outcome of Barton's fracture treated with open reduction and internal fixation by volar plating: A prospective study

**Abhinav Kumar, Dr. Ashok R Nayak, Dr. Dayanand BB, Dr. Rajkumar M Bagewadi and Dr. Srikant Kulkarni**

DOI: <https://doi.org/10.22271/ortho.2020.v6.i11.1939>

### Abstract

**Aims:** To study the functional outcome and duration of union of surgical management of Barton's fracture of distal radius with volar locking compression plate fixation.

**Settings and Design:** Prospective study.

**Methods and Material:** 56 cases presenting with Barton's fracture which satisfies inclusion and exclusion criteria admitted in Shri B.M. Patil college, hospital and research centre vijayapura from 2017-2020 who are treated with volar locking plate.

**Results:** In our study 56 cases, there were 29 males, 27 females with mean age of 39.52 years. 85.7% were admitted due to fall on outstretched hand, left side was more common according to 57.1% cases, associated ulnar fractures were found in 76.8% cases. 89.3% cases didn't have any co-morbidity. 89.3% of the patient had no complication following surgery. Most common complication was wrist stiffness in 7.1% cases followed by surgical site infection 1.8% and complex regional pain syndrome in 1.8% cases according to Disability of Arm, Shoulder and Hand (DASH) score.

**Conclusions:** Initial reduction and stable fixation is the key in prevention of late collapse of distal radius fractures. Stabilizing the fracture fragments with volar locking compression plate and screws in the management of fractures of distal radius is an effective method to maintain reduction and prevent collapse of the fracture fragments. The technique emphasizes that open reduction and internal fixation with volar plating has excellent functional and satisfactory radiological outcome with minimal complications. Hence volar approach and locking compression plate should be the preferred implant for treatment of intra-articular unstable, comminuted fractures of distal end radius.

**Keywords:** Barton's fracture, volar locking plate, DASH

### Introduction

The supremacy of the human race in the animal kingdom lies in its grey matter and the meticulous use of fingers for finer work with assistance of the wrist. Since first mentioned in modern medicine by Colles in 1814 and despite being so prevalent, fractures of distal end of radius continue to pose a therapeutic challenge to orthopedicians.

Distal radius fractures are among the most prevalent fractures representing one sixth of all fractures treated in emergency departments <sup>[1]</sup>, constitute 17% of all fractures and 75% among all forearm fractures <sup>[2]</sup>. Intra and extra-articular malalignment may lead to complications like post traumatic osteoarthritis, decreased grip strength and endurance as well as limited motion and carpal instability <sup>[3]</sup>. Three peaks occur in fracture distribution: 5-14-year children, males under 40 years, females above 50 year. In older age group it accounts for 18% of all fractures due to osteoporosis. Road traffic accidents are a major cause of fracture in young adults. In elderly fall on outstretched hand becomes a major cause <sup>[4]</sup>.

Optimum results are achieved by understanding the proper fracture pattern and achieving anatomical reduction and early mobilization <sup>[2]</sup>. The treatment for the diverse spectrum of the distal radius fracture relies mainly upon strict definition of specific fracture configuration. Different types of classifications were introduced to explain different fracture configuration to aid in the treatment. Intra articular distal radius injury typically has intra-articular fracture displacement with joint subluxation. Hence perfect articular alignment and stability become

**Corresponding Author:**  
**Abhinav Kumar**  
Shri B. M. Patil Medical College  
and Research Center,  
Vijayapura, Karnataka, India

necessary as recommended by AO. The extent of displacement of fracture fragment, the degree of articular disruption, the stability and reducibility of each fracture, as well as any concurrent injury to adjacent neurovascular structures must be assessed carefully in the planning of treatment.

Casting and external fixations have been tried but are not able to reduce and/or maintain comminuted /intra-articular distal end radius fractures [5]. They have problems of prolonged immobilisation. Casting is associated with swelling and stiffness and inability to treat and maintain comminuted and intra-articular fractures. External fixation addresses some comminution but has problems of pin tract infections, tethering of muscles, tendons and capsule, immobilisation and difficulty to reduce and maintain intra-articular fractures.

Open reduction internal fixation with dorsal plating has been tried to address intra-articular fractures and above-mentioned problems, with better outcomes but this procedure has hardware complications like irritation of tendons and even tendon ruptures at times [6]. Hence volar plating was introduced ease of lesser dissection per operatively and reduce hardware impingement problems post operatively.

Volar plating provides the benefits of stable anatomical reduction and early mobilisation with reduce hardware complications. Volar aspect is a better choice for implant application for the following reasons: more space is available, because flexor tendons are located far from the volar radial surface and pronator quadratus is conveniently interposed; the concave surface of distal radius protects flexor tendons from hardware irritation; blood supply is less likely to be disrupted; volar cortex is less likely to be comminuted, facilitating volar

osteosynthesis; and finally volar scars are better tolerated [7]. Under 100N axial load, the palmar locking compression T-plate restores stability comparable to that of an intact radius, and is superior to conventional palmar or dorsal T-plates [8]. The development of fixed angular stable fixation techniques theoretically improves stability to maintain the reduction of fractures in osteoporotic bones and fractures considered to be unstable [9].

This study evaluates the functional and radiological outcomes of intra articular distal radius fractures treated by open reduction and volar locking compression plate fixation.

### Materials and Methods

Prospective analysis was done for the functional outcome of patients treated with volar locking plate fixation for intra articular distal radius fractures operated by five different consultants in Shri B.M. Patil Medical college and research centre during the period of Nov-2017 to May-2019 in the Dept. of Orthopaedics.

Functional outcomes were measured during follow-up visit of the patients and radiological parameters of distal radius were measured in radiographs collected from institutional picture archiving and communication system (PACS). Clinical data like mode of injury, duration of surgery from injury etc. were collected from hospital medical records. The decision to operate was made by the operating surgeon after assessing initial x ray.

The operating surgeon determined the best device for fixation of the particular fracture type. We classified each patient's fracture using the AO classification system.

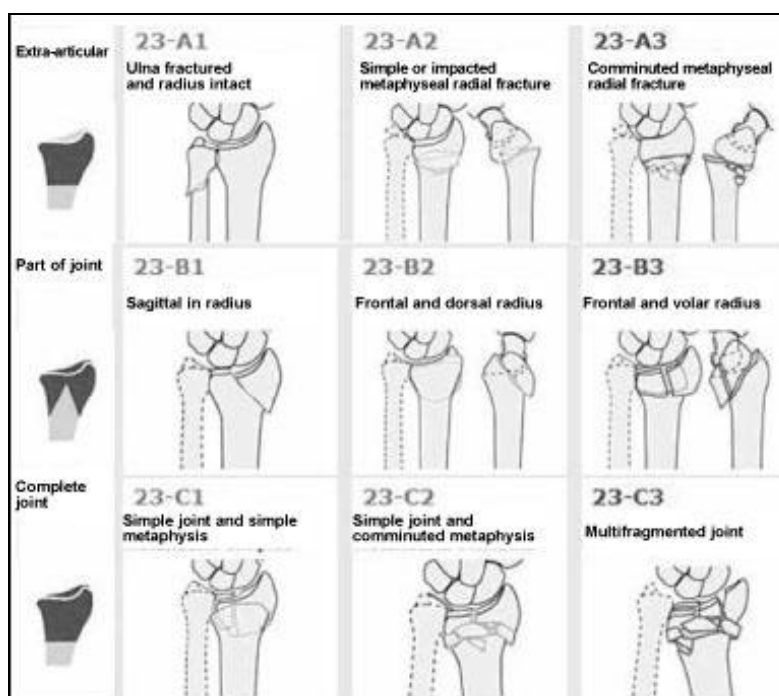


Fig 1: AO Classification of distal end of radius fracture.

### Inclusion criteria

1. Patients aged 18-50yrs
2. Both male & female
3. Closed Intra articular distal radius fractures with & without ulnar styloid fracture.

### Exclusion criteria

1. Associated neurovascular injury

2. Pathological fractures
3. Ipsilateral both bone forearm fracture
4. Patients medically unfit for surgery
5. Associated carpal injuries
6. Open fractures
7. Patients unwilling to provide consent.

**Follow-up assessment was as follows:**

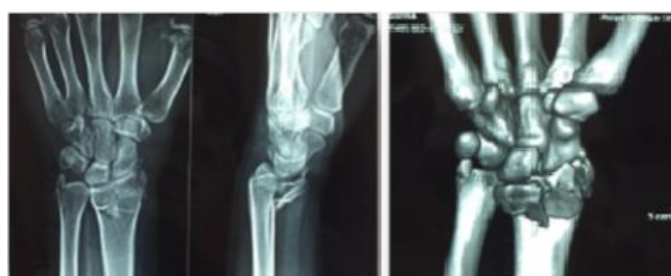- **Assessment at 1 Month:** Clinical assessment of pain
- **Assessment at 3 Month:** Clinical assessment of pain, range of motion Clinical and radiological assessment of union
- **Assessment at 6 Month:** Clinical assessment of pain, range of motion, Clinical and radiological assessment of union, Clinical & functional capabilities with regard to activities of daily living. Assessment of any complications.

**Statistical analysis**

Data was entered in Excel sheet, analyzed and interpreted with appropriate bar diagrams & pie charts and functional outcome was assessed with Disabilities of Arm, Shoulder & Hand (DASH) Score.

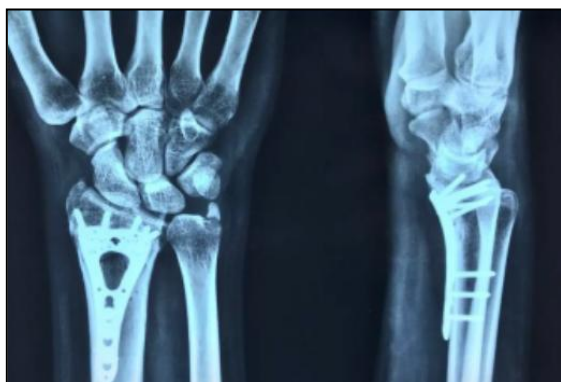**Case Illustration**

**Case: 1 (Excellent Result)**



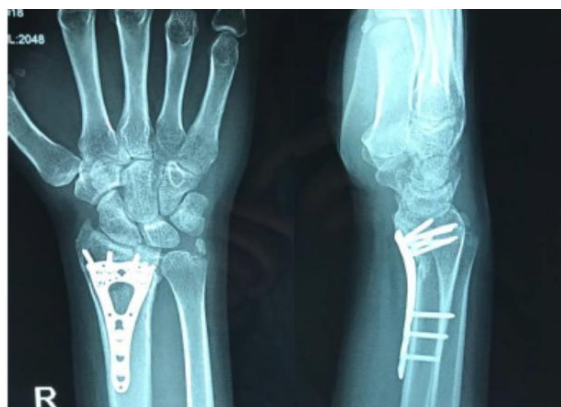**Fig 2:** Radiographs of Case 1

**Pre-Operative**




**Fig 3:** Pre-Operative

**Immediate post OP**



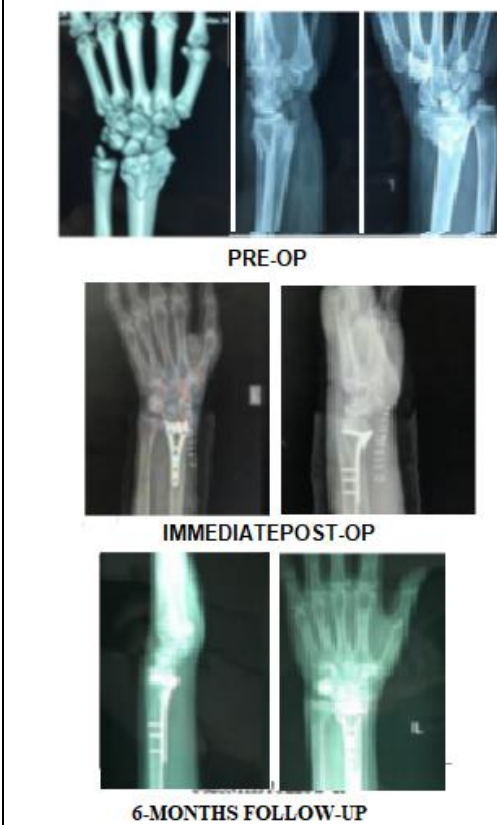**Fig 4:** Immediate Post OP

**6-Months follow-up**

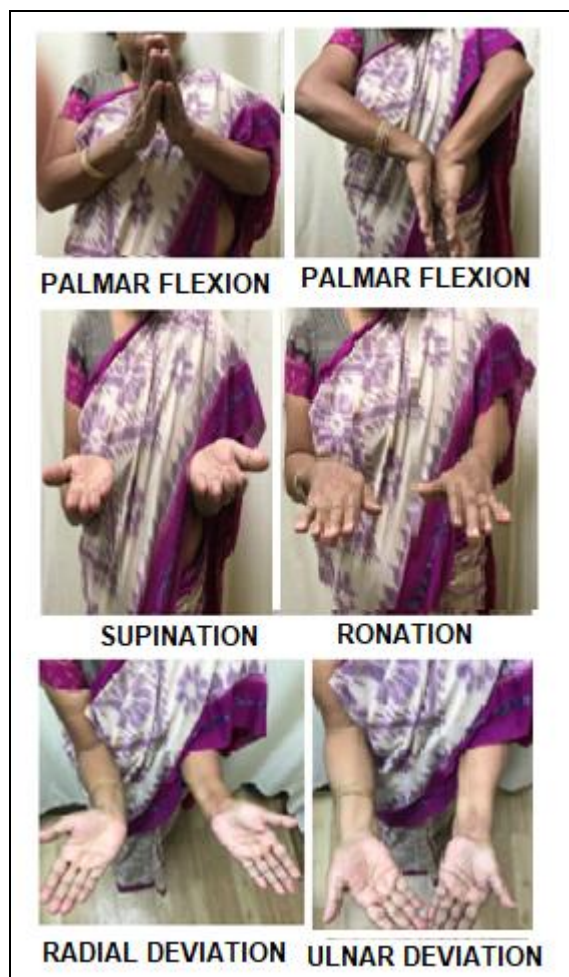

**Fig 5:** post-operative clinical pictures of case 1.

**Case 2 (Excellent Result)**



**Fig 6:** Radiographs of Case 2.



**Fig 7:** Fig 7- post operative clinical pictures of case 2.

### Results and Analysis

The present study consists of 56 cases of intra articular distal radius fractures.

All the cases were operated using volar locking compression plate fixation. The study period was from Nov-2017 to May-2019.

Functional outcome were evaluated based on Disabilities of Arm, Shoulder and Hand (DASH) score. All Patients were followed up at regular interval i.e. 1month, 3months and 6months. Out of 56 patients, 29 (51.8%) were male and 27(48.2%) were females. Age ranges from 20 years to 49 years, hence Mean age being 39.52 years.

**Table 1:** Distribution of patients according to Age (Years)

Age (year)	No. of Patients	Percentage
< 30	7	12.5
30-30	16	28.6
40+	33	58.9
total	56	100.0

Most of the participants were more than 40 years age group which accounted for 58.9 % of the study population.

In our series of 56 patients, there were 29 males (51.8%) and 27 females (48.2%).

Minimum age was 22 years, maximum 49 years with mean age of 39.52 years. FOOSH (fall on outstretched hand) was most common mode of injury accounted for 85.7 % of cases.

Left side was more common, accounted for 57.1 % of cases. 89.3 % of the patients were having no comorbidities, while 7.1 % were having Diabetes mellitus (DM) and 3.6 % were

having Hypertension (HTN).

In accordance with AO/OTA classification- AO Type B1 (39.3%) and type C1 (32.1%) was more common followed by type C2 (25.0 %) and type C3(3.6%).

Associated ulnar styloid fractures were found in 76.8 % of cases. 89.3 % of the patients had no complications following surgery.

Most common complication was wrist stiffness in 7.1 % of cases followed by surgical site infection (SSI) in 1.8 % and Complex regional pain syndrome (CRPS) in 1.8 %.

In current study, functional outcome of the fracture fixation were evaluated using Disabilities of Arm, Shoulder and Hand (DASH) score questionnaire at 3 months post op follow up and same has been graded as Excellent (in 17.9 % cases), Good (in 67.9 % cases), Fair (in 14.2 % cases) and Poor (nil).

### Discussion

More than 200 years have passed since 1814 Sir Abraham Colles described the fracture of the distal end of the radius. It is remarkable that this common fracture remain one of the most challenging of the fractures to treat. Though there is no consensus regarding the description of the condition and the appropriate outcome, still effective method for the fixation of distal radius fractures is demanding due to complex fracture patterns.

Intra articular distal radius fracture is an unstable fracture of distal radius, commonly accompanied by subluxation or luxation of wrist joint. The primary goal in treatment of this type injury is to provide good reduction and immediate stability to achieve anatomic fracture union, allow the quick return of hand function and avoid complications. Fracture healing depends on a minimal gap, adequate stability and sufficient blood supply. It has been shown that residual intra-articular incongruity leads to posttraumatic arthritis in the long term. In theory, the locking plate minimizes the compressive forces exerted on the bone to achieve stability, which may prevent periosteal compression and associated impairment in blood supply, and it is favoured for fracture healing. In unstable intra-articular fractures, re-establishment of inter-articular integrity of the wrist and maintaining the radial length are often not possible with closed methods. In such cases, where an open positioning is required, various surgical methods and fixation materials can be used. A better understanding of wrist anatomy and functioning through the studies conducted in the recent years as well as the increasing expectations of the patients have expanded the indications of surgical management. Besides, improvements in fixation materials have provided new opportunities.

The current trend of management for irreducible compression fractures of the joint surface has shifted from bridging external fixation, pins, and bone grafting to open reduction and stable internal fixation and functional aftertreatment.

Many studies have shown that the long-term functional results are equivalent, but the earlier functional results favour open reduction and internal fixation (ORIF) over external fixation.

Unlike the dorsal approach, by using the volar approach, large volar fragments from the lunate fossa are reduced by direct manipulation and stabilized with the plate's buttressing surface. Use of a volar approach and plating avoids irritation of the extensor tendons and late tendon rupture provided that threaded screws do not perforate the dorsal cortex.

The present study was undertaken to assess the functional and radiological outcome of operative management of intra articular distal radius fractures using a volar locking plate.

## Conclusion

Initial reduction and stable fixation is the key in prevention of late collapse of distal radius fractures.

Stabilizing the fracture fragments with volar locking compression plate and screws in the management of fractures of distal radius is an effective method to maintain reduction and prevent collapse of the fracture fragments.

The technique emphasizes that open reduction and internal fixation with volar plating has excellent functional and satisfactory radiological outcome with minimal complications.

Hence volar approach and locking compression plate should be the preferred implant for treatment of intra-articular unstable, comminuted fractures of distal end of radius.

## References

1. Ilyas AM, Jupiter JB. Distal Radius Fractures—Classification of Treatment and Indications for Surgery. *Hand Clin.* 2010; 26(1):37-42.
2. Colles A. On the fracture of the carpal extremity of the radius. *Edinb Med Surg J* 1814; 10:181. *Clin Orthop.* 2006; 445:5-7.
3. Fitoussi F, Ip WY, Chow SP. Treatment of displaced intra-articular fractures of the distal end of the radius with plates. *J Bone Joint Surg Am.* 1997; 79(9):1303-12.
4. Nellans KW, Kowalski E, Chung KC. The Epidemiology of Distal Radius Fractures. *Hand Clin.* 2012; 28(2):113-25.
5. Pattanashetty OB, Bhavi S, Bami M, Daultani D, Mapari Y. Outcome of fracture of distal end of radius in adults treated by open reduction and internal fixation with buttress plate. *Kerala J Orthop.* 2013; 26(2):87-92.
6. Mandalia DM, Gajjar DS, Anand DT, Saxena DS. Results of distal end radius volar plating. *Int J Orthop Sci.* 2017; 3(1):395-401.
7. Baratz ME, Des Jardins J d, Anderson DD, Imbriglia JE. Displaced intra-articular fractures of the distal radius: the effect of fracture displacement on contact stresses in a cadaver model. *J Hand Surg.* 1996; 21(2):183-8.
8. Leung F, Zhu L, Ho H, Lu WW, Chow SP. Palmar plate fixation of AO type C2 fracture of distal radius using a locking compression plate--a biomechanical study in a cadaveric model. *J Hand Surg Edinb Scotl.* 2003; 28(3):263-6.
9. Chen NC. Management of Distal Radial Fractures. *J Bone Jt Surg Am.* 2007; 89(9):2051.