

Original Research Article

Clinical outcome of treatment of intra-articular distal humerus fracture with open reduction and internal fixation by orthogonal locking plate: a prospective study

Deepak Vasishtha, Sandeep Naik*, Santosh Nandi, Shreepad Kulkarni

Department of Orthopaedics, BLDEU Shri BM Patil Medical College, Vijayapura, Karnataka, India

Received: 23 January 2020

Revised: 12 February 2020

Accepted: 21 February 2020

***Correspondence:**

Dr. Sandeep Naik,

E-mail: sandipkmc@gmail.com

Copyright: © the author(s), publisher and licensee Medip Academy. This is an open-access article distributed under the terms of the Creative Commons Attribution Non-Commercial License, which permits unrestricted non-commercial use, distribution, and reproduction in any medium, provided the original work is properly cited.

ABSTRACT

Background: The aim of the study was to study the clinical outcome and complications of surgical management of intra-articular fractures of distal humerus.

Methods: A prospective study included 23 consented patients with intra-articular distal humeral fractures who underwent osteosynthesis by orthogonal locking compression plating using posterior approach with olecranon osteotomy between November 2017 to May 2019 at BLDE(DU's) Shri BM Patil Medical College, Vijayapura, Karnataka.

Results: In our study there were 15 male patients and 8 female patients with mean age of 38.5 years. 65.2% of the cases admitted were due to motor vehicle accident, 21.7% due to accidental fall and 13% due to fall from height with right side (73.9%) being the more commonly affected side. The mean operative time was 100 minutes. Mayo Elbow Performance Score was 83.3% post operatively and the mean arc of motion was 117°. 82% of cases fared excellent to good results.

Conclusions: Orthogonal locking plate construct provides stable rigid fixation for allowing early mobilisation and allows predictable healing both clinically and functionally in these complicated fractures. Absence of implant failure and non-union may be attributed to the highly stable construct system achieved by orthogonal locking plating. Majority of our cases had good functional outcome and return to pre injury status.

Keywords: Distal humerus, Intra-articular fracture, Orthogonal locking plating, Olecranon osteotomy

INTRODUCTION

Fracture of the distal humerus accounts for 2-6% of all fracture and 1/3 of all humeral fracture. Intraarticular distal humerus fracture is rare accounting 0.5% of all fracture.¹ In this growing elderly population and an extremely active young population, the incidence of distal humeral fracture is increasing and is seen to have a bimodal distribution.

In young adults, most distal humerus fracture occur from high-energy trauma like side-swipe injuries, motor vehicle

accidents (MVA) etc. In elderly persons with more osteoporotic bone, these injuries occur from simple falls.²

Intra-articular bicondylar fracture of distal humerus (type C, AO classification) are difficult to manage. Malunion, stiffness and osteoarthritis are common. In the last few decades, the popularity of internal fixation of this fracture is growing fast. Surgical treatment gives a chance for accurate anatomical reduction of the joint surface. Most of the recent reports emphasize that accurate restoration of the articular surface anatomy, stable fixation and early mobilization gives the best result. Composite problems in

distal humerus fracture management include frequent articular involvement, metaphyseal comminution, bone loss and osteopenia. Poor outcomes like contracture, non-union, high failure rate are noted with old internal fixation techniques. Attempt to achieve painless, stable yet mobile elbow requires a systematic approach for open reduction and internal fixation (ORIF) with plates and screws.⁶⁻¹¹

Two-plate fixation recommended by majority of authors provide adequate stability and allow for adequate restoration of anatomy.

The guidelines proposed by the AO/ASIF group for fixation of distal humeral fracture are the gold standard till now. Using these fixation techniques, different authors have reported unsatisfactory results in 20% to 25% of patients due to implant failure occurring, if mobilized early.⁶⁻¹³

As a result of ongoing search for a more secure technique, later evolved the concept of orthogonal locking plating, which involves placing one plate along the medial column of the distal humerus and the other plate along the lateral column, with the screws in the distal fragment interdigitating with each other, restoring the 'tie-beam arch' of the distal humerus. Several biomechanical studies have proven the superiority of orthogonal locking plating over traditional plating methods, yet there are only fewer clinical studies to analyse the functional outcome of orthogonal plating in distal humerus fracture fixation.^{14,15}

According to O'Driscoll this can be achieved by following a set of eight technical objectives.

Every screw should pass through a plate, each screw should engage a fragment on the opposite side that is also fixed to a plate, as many screws as possible should be placed in the distal fragments, each screw should be as long as possible, each screw should engage as many articular fragments as possible, the screws should lock together by interdigitation within the distal fragment, thereby creating a fixed-angle architecture that provides stability to the entire distal humerus, plates should be applied such that compression is achieved at the supracondylar level for both columns, plates used must be strong enough and stiff enough to resist breaking or bending before union occurs at the supracondylar level.

Initially these fractures were classified based on the concept that the distal end of the humerus was made up of condyles. The term supracondylar, condylar, transcondylar and bicondylar fractures were utilized. Currently, fracture of the distal humerus are more commonly described based on the columnar structure of the distal humerus. This include describing fractures as single columnar, bicolunar, and transcolumar fractures.

AO/OTA used classification is the most widely used.¹⁷ Extra-articular (AO type A), Partial articular (AO type B),

complete articular (AO type C). In our study we included AO type C fractures.

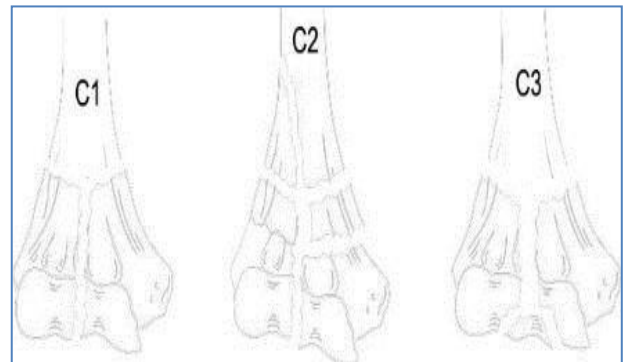


Figure 1: Type C intraarticular fracture distal end humerus.

The sole purpose of this study is to study the clinical outcome and complications of surgical management of intra-articular fractures of distal humerus.

METHODS

Study design

A prospective study was done to evaluate the clinical outcome of orthogonal locking plating technique in treatment of distal humeral fracture and to analyse the results.

Study group

The study group consists of 23 patients with distal humeral fracture, who underwent osteosynthesis with orthogonal locking plating technique between 1st November 2017 to 31st May 2019 at BLDE (DU's) Shri BM Patil Medical College, Vijayapura, Karnataka.

Follow up period was 6 weeks, 3 months and 6 months

The study was done with clearance from hospital ethical committee. Those who fulfilled the inclusion criteria given below were invited to participate in the study. Informed consent was obtained from all the patients willing to take part in the study. Data were analysed using SPSS software v.23.0. on microsoft office 2007.

Inclusion criteria

Patients with intra-articular fracture of the distal humerus, patient aged more than 18 years, patients who give consent for surgery.

Exclusion criteria

Patient not fit for surgery, open fracture, pathological fracture, immunocompromised status, non-union or malunion and those with associated neurovascular injury.

Surgical technique

The patient is placed in the lateral decubitus position. Under tourniquet control, midline posterior skin incision is utilized with or without a slight curvature medial or lateral to the olecranon to avoid incising directly over it. Ulnar nerve identified and mobilized to avoid damage to this structure. Proximally the intermuscular septum and Arcade of Struthers are resected. The ulnar nerve is then transposed anteriorly, with the intention to later perform a formal anterior subcutaneous transposition. The olecranon osteotomy is thought to provide optimal exposure to the intra-articular surface of the distal humerus. The olecranon osteotomy is started with the use drilling Kirschner wire but it is not completed. An osteotome is utilized to complete the osteotomy. Once the fracture fragments are identified and reduced, provisional fixation is performed with Kirschner wires. Care must be taken here to pay attention to neurovascular structures around the elbow as the provisional Kirschner wires can injure these structures if left too long or too sharp. The orthogonal plates are then applied to the bone with the medial one being placed along the medial column of the distal humerus and the second plate being placed along the posterolateral aspect of the lateral column. The fixation should ideally have at least three screws proximal and three screws distal to the fracture site through each plate and thus through each column. Once the plates are secured to the distal humerus, the elbow range of motion is assessed to ensure adequate stability is present without a mechanical block. Utilizing a tension band technique, fixation of the olecranon osteotomy was done.

Post-operative treatment

Postoperatively, a well-padded above elbow slab is applied and patients are encouraged to keep the arm elevated in order to minimize swelling. After removal of the drain, motion exercises are initiated within the first week after surgery including active assisted and gentle passive motion for elbow flexion/extension and pronation or supination. Patients were followed up at intervals of 6 weeks, 3 months and 6 months.

Post-operative assessment

Post-operatively the patients were assessed radiographically and clinically using Mayo elbow performance score (MEPS).¹⁸ The overall clinical outcome was graded as follows: excellent: >90, good (satisfactory): 75-89, fair: 60-74 and poor: <60.

RESULTS

The mean age of the patients was 38.5 years ranging from 19 to 65 years. Nearly 26.1% patients belong to 3rd decade (Table 1). Males (2:1) predominated our study group (Table 2 and 3). Right limb injuries were more common. Motor vehicle accidents and accidental simple falls were the common mechanisms of injury (Table 4). Motor

vehicle accidents were major form of injury in younger males whereas simple fall from standing height had been the most common mode of violence in elderly females. Intra-articular fracture constituted 100% of cases in our study. Of the complete articular (intra-articular) types, the order of most common types was C2 (43.5%) > C1 (39.1%) > C3 (17.4%) (Table 5). All patients were operated by Chevron osteotomy approach (23 Patients). In our study, the average surgical time delay was 4 days ranging from 2 to 7 days. The average surgical time was 150 minutes ranging from 90 minutes to 3 hours.

Table 1: Age distribution.

Age (in years)	N	%
≤25	4	17.4
26-30	3	13
31-40	6	26.1
41-50	7	30.4
51-60	3	13
Total	23	100

Table 2: Distribution of cases according to sex.

Sex	N	%
Male	15	65
Female	8	35
Total	23	100.0

Table 3: Distribution of cases according to sex.

Age (years)	Male		Female		P value
	N	%	N	%	
≤25	2	13.3	2	18.2	0.696
26-30	2	13.3	1	9.1	
31-40	4	26.7	2	18.2	
41-50	4	26.7	3	27.3	
51-60	3	20.0	0	0.0	
Total	15	100.0	8	100.0	

Table 4: Distribution of cases according to mode of injury.

Mode of injury	N	%
Fall	5	21.7
Fall from height	3	13
MVA	15	65.2
Total	23	100

Table 5: Distribution of cases according to AO type.

AO type	N	%
C1	9	39.1
C2	10	43.5
C3	4	17.4
Total	23	100

Complications encountered in our study were paraesthesia along ulnar nerve distribution, superficial infection, stiffness, heterotopic ossification reducing ROM, non-union at osteotomy site and hardware prominence (Table 6). Twenty-three patients of distal humerus fracture were treated surgically with orthogonal locking plating and analysed with average follow up of 6 months (6 weeks, 3 months, 6 months). In our study, solid radiologic union was achieved primarily in all patients. The average time to union was about 14 weeks. Hardware failure or non-union did not occur in any patient. The mean flexion-extension arc was 107° (Table 7).

Table 6: Distribution of cases according to complications.

Complications	N	%
Decreased elbow ROM due to heterotopic ossification	1	4.3
Hardware prominence	1	4.3
Non-union at osteotomy site	1	4.3
Parasthesia in ulnar n sensory area	2	8.7
Stiffness	2	8.7
Superficial infection	2	8.7

Table 7: Distribution of ROM.

ROM	N	%
10-110	9	39.1
10-120	5	21.7
10-135	1	4.3
10-140	1	4.3
15-95	1	4.3
20-120	1	4.3
20-130	2	8.7
20-140	1	4.3
20-90	2	8.7
Total	23	100

Table 8: Distribution of cases according to MEPS score.

MEPS Score	N	%
55	1	4.3
65	1	4.3
70	2	8.7
80	4	17.4
85	6	26.1
90	6	26.1
95	3	13
Total	23	100

Table 9: Mean of MEPS score.

	Range	Mean	SD
MEPS	55-95	83.3	10.1

The mean MEPS score was 83 in our study (Table 8 and 9). The results were excellent for 9 elbows, good for 10, fair for 3, and poor for 1 patient.

DISCUSSION

Functional elbow is very essential for an individual for social and economic thriving. Fractures of the distal humerus may directly affect the functional movement of elbow especially intercondylar (intra-articular) fracture.

The majority of distal humerus fractures presenting to our centre were resulting from road traffic accidents (65.2%) compared to study by Sanchez-Sotelo et al, where the major mechanism of injury was accidental fall from standing height (56%) and compared to study by Dayanand et al where the most common mechanism of injury were both direct fall and road traffic accidents.^{19,20} This is probably reflective of the fact that several trauma cases are being referred to our centre which is the tertiary referral centre for trauma care of this region.

The male predominance (2:1) was seen in our centre as compared to 1:1 recorded by Sanchez-Sotelo et al is the resultant of the high number of trauma cases treated in our centre and the fact that males are more prone for road traffic accidents compared to females because in our society females travel less.¹⁹

Fracture configuration according to the OTA type had a significant bearing on the outcome in distal humerus patients treated surgically. Group C had a poorer outcome than group A patients. This has again stressed the importance and prognostic significance of the OTA classification. Study by Sanchez-Sotelo et al revealed that the commonest fracture type was OTA class A and C which our study concurs.¹⁹ It is also important to stress on the fact that incidence of type C fractures is more than the type A fractures suggesting that the incidence of high velocity injuries is on the rise.

The restoration of elbow function is dependent on three salient features: exposure, fixation and the post-operative rehabilitation, with later two are of primary consideration. Adequate exposure is necessary for visualization fixation of the fracture fragments. The optimal exposure is provided by the posterior approach with osteotomy of the olecranon.

Olecranon osteotomy was done all our cases. All of them were fixed with modified TBW with K wires. This allowed us complete examination of the articular surfaces of trochlea, capitellum, olecranon and radial head. It also gives access to the medial and lateral supracondylar ridges. Full evaluation of the fragments of the fracture and reduction can then be performed.

Although non-union of the osteotomy may be regarded as a potential complication of this exposure, TBW of the osteotomy has provided sufficient stability of the

olecranon for immediate use of the elbow through a secure range of motion. Only one case in our 23 osteotomized elbows showed a non-union which was reunited with revision osteosynthesis with modified TBW.

23 cases in our study were operated with orthogonal locking plating which provided absolute stability for early mobilisation. The lateral plate placement directly on the lateral column allows for lengthy screw placement which is limited in traditional orthogonal plating due the fear of anterior capitellar breach in the same. The previous concept of using the more malleable 1/3 tubular plate for the medial column which requires heavy contouring is now in question and several authors recommend at least a stronger 3.5 mm plates or precontoured plates for both columns to achieve a more stable and rigid construction to allow for early mobilization. In our study we have not met any implant failures or non-union at the fracture site which is in par with the fact that orthogonal locking plating offers an inherently stable construct in a given clinical situation and in concurrence with studies done on orthogonal locking parallel plating by Sanchez-Sotelo et al and Atalar et al.¹⁹⁻²¹

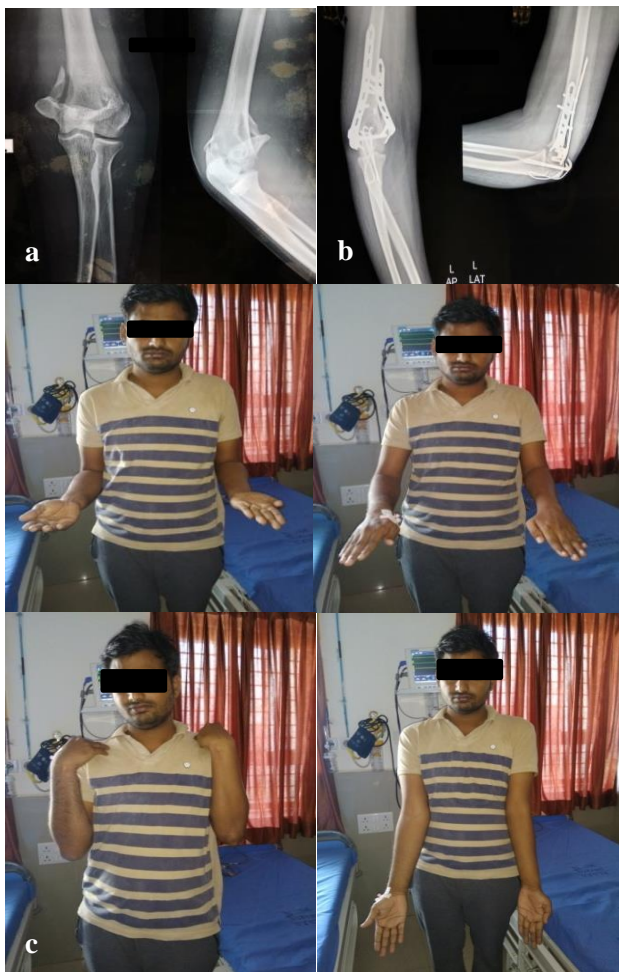


Figure 2: (a) Preoperatively, (b) 3 months postoperatively and (c) range of motion as seen 6 months postoperatively.

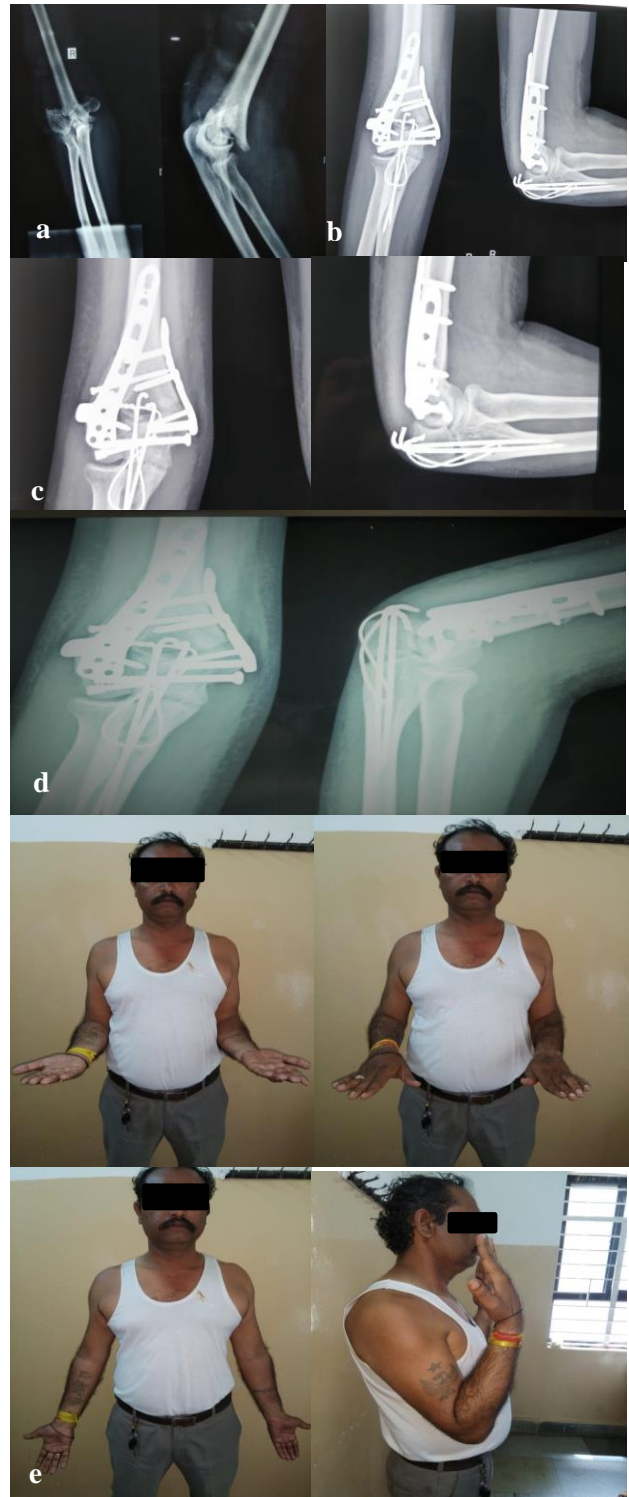

Figure 3: (a) Preoperative, (b) 6 weeks, (c) 3 months, (d) 6 months and (e) Range of motion 6 months postoperatively.

CONCLUSION

Incidence of complex distal humerus fractures among younger population is on the rise due to increasing motor vehicle accidents. Absolute stability of the system allows early post-operative rehabilitation and thence a better

functional outcome. Good to excellent functional outcome was achieved in about 82% of the study group in terms of arc of motion and stability. Absence of implant failure and non-union may be attributed to the highly stable construct system achieved by orthogonal locking plating. Though it appears to be a variant of traditional plate placement, it is completely a different concept providing a greater stability in osteoporotic and comminuted bones. By this study we concluded that orthogonal locking plating can be a successful technique for internal fixation of these complicated fracture, when its principles are strictly adhered to.

Funding: No funding sources

Conflict of interest: None declared

Ethical approval: The study was approved by the institutional ethics committee

REFERENCES

- Rose SH, Melton LJ, Morrey BF, Ilstrup DM, Riggs BL: Epidemiologic features of humeral fractures. *Clin Orthop Relat Res.* 1982;168:24-30.
- Robinson CM, Hill RM, Jacobs N, Dall G, Court-Brown CM. Adult distal humeral metaphyseal fracture epidemiology and results of treatment. *J Orthop Trauma.* 2003;17(1):38-47.
- Gupta R. Intercondylar fractures of the distal humerus in adults. *Injury.* 1996;27(8):569-72.
- Kundel K, Braun W, Wieberneit J, Ruter A. Intra-articular distal humerus fractures. Factors affecting functional out-come. *Clin Orthop.* 1996;332:200-8.
- Zhao J, Wang X, Zhang Q. Surgical treatment of comminuted intra-articular fractures of the distal humerus with double tension band osteosynthesis. *Orthopedics.* 2000;23(5):449-52.
- Henley MB. Intra-articular distal humeral fractures in adults. *Orthop Clin North Am.* 1987;18(1):11-23.
- Jupiter JB, Neff U, Holzach P, Allgower M. Intercondylar fractures of the humerus. An operative approach. *J Bone Joint Surg.* 1985;67:226-39.
- Letsch R, Schmit-Neuerburg KP, Sturmer KM, Walz M. Intra-articular fractures of the distal humerus. Surgical treatment and results. *Clin Orthop.* 1989;241:238-244.
- McKee MD, Wilson TL, Winston L, Schemitsch EH, Richards RR. Functional outcome following surgical treatment of intra-articular distal humeral fractures through a posterior approach. *J Bone Joint Surg Am.* 2000;82(12):1701-7.
- Pollock JW, Faber KJ, Athwal GS. Distal humerus fractures. *Orthop Clin North Am.* 2008;39(2):187-200.
- Zagorski JB, Jennings JJ, Burkhalter WE, Uribe JW. Comminuted intra-articular fractures of the distal humeral condyles. Surgical vs. nonsurgical treatment. *Clin Orthop Relat Res.* 1986;202:197-204.
- Holdsworth BJ, Mossad MM. Fractures of the adult distal humerus. Elbow function after internal fixation. *J Bone Joint Surg Br.* 1990;72(3):362-5.
- John H, Rosso R, Neff U, Bodoky A, Regazzoni P, Harder F. Operative treatment of distal humeral fractures in the elderly. *J Bone Joint Surg Br.* 1994;76(5):793-6.
- Self J, Viegas SF, Buford WL, Patterson RM. A comparison of double-plate fixation methods for complex distal humerus fractures. *J Shoulder Elbow Surg.* 1995;4(1):10-6.
- Stoffel K, Cunneen S, Morgan R, Nicholls R, Stachowiak G. Comparative Stability of Perpendicular Versus Parallel Double-Locking Plating Systems in Osteoporotic Comminuted Distal Humerus Fractures. *J Orthop Res.* 2008;26(6):778-84.
- Ozer H, Solak S, Turanli S, Baltaci G, Colakoglu T, Bolukbasi S. Intercondylar fractures of the distal humerus treated with the triceps-reflecting anconeus pedicle approach. *Arch Orthop Trauma Surg.* 2005;125(7):469-74.
- Fracture and dislocation compendium. Orthopedic trauma association committee for coding and classification. *J Orthop Trauma.* 1996;10(1):1-154.
- Cusick MC, Bonnaig NS, Azar FM, Mauck BM, Smith RA, Throckmorton TW. Accuracy and Reliability of the Mayo Elbow Performance Score. *J Hand Surg Am.* 2014;39(6):1146-50.
- Erpelding JM, Mailander A, High R, Mormino MA, Fehringer EV. Outcomes following distal humerus fracture fixation with an extensor mechanism-on approach. *The J Bone Joint Surg Am.* 2012;94(6):548-53.
- Dayanand BB, Vikrama E, Vell G. Functional outcome of surgical management of distal end humerus fracture in adults: a prospective study. *Int J Orthop Scien.* 2019;5(4):692-97.
- Githens M, Yao J, Sox AH, Bishop J. Open reduction and internal fixation versus total elbow arthroplasty for the treatment of distal humerus fracture: a systematic review and meta-analysis. *J Orthop Trauma.* 2014;28(8):481-8.

Cite this article as: Vasishtha D, Naik S, Nandi S, Kulkarni S. Clinical outcome of treatment of intra-articular distal humerus fracture with open reduction and internal fixation by orthogonal locking plate: a prospective study. *Int J Res Orthop* 2020;6:471-6.