

Case Report

Sialolipoma of parotid gland in a 1-year-old male child: A case report and review of literature

Surekha Ulhas Arakeri, Shilpi Banga

Department of Pathology, BLDEU's Shri B. M. Patil Medical College, Vijayapura, Karnataka, India

Abstract

Sialolipoma is a recently described rare histological variant of lipoma, characterized by well-demarcated proliferation of mature adipocytes with secondary entrapment of salivary gland elements. Less than forty cases of sialolipoma have been reported in English literature. This tumor has been reported both in major and minor salivary glands, with the parotid gland being the most common site. Age incidence in this tumor varies from 0 month to 84 years. However, the occurrence of this tumor in an infant is very rare. In the published literature, the size of this tumor varied from 1 to 7 cm. In the present case, the tumor size was >7 cm. To the best of our knowledge, congenital sialolipoma >7 cm has been rarely reported earlier. Hence, this case is presented because of its rarity and unusual gross appearance.

Keywords: Congenital, parotid gland, sialolipoma

Address for correspondence: Dr. Surekha Ulhas Arakeri, Department of Pathology, BLDEU's Shri B. M. Patil Medical College, Vijayapura, Karnataka, India.
E-mail: drsuarakeri@hotmail.com

Received: 28.07.2016, **Accepted:** 29.08.2016

INTRODUCTION

Sialolipoma is a rare histological variant of lipoma characterized by well-demarcated proliferation of mature adipocytes with the secondary entrapment of the salivary gland elements such as serous acini, ducts and myoepithelial cells. Lipomatous tumors of the parotid gland are very rare, accounting for <0.5% of all parotid tumors.^[1,2] Various histological variants of salivary gland lipoma such as angiolipoma, fibrolipoma, pleomorphic lipoma and spindle cell lipoma have been published.^[2] Nagao *et al.* in 2001, recognized a new histological variant of lipoma called as sialolipoma as a distinct entity. Since 2001, more than 38 cases of sialolipoma have been published in major and minor salivary glands.^[3] Published articles on sialolipoma were either the single-case reports or the reports of small case series.^[1-8] We report a case of congenital sialolipoma

in the parotid gland of the 1-year-old male child. The aim of this article is to report one more new case of sialolipoma in infant and discuss the clinicopathological and morphological features of sialolipoma.

CASE REPORT

A 1-year-old male child presented with swelling in the parotid region which was noticed by his mother when her son was 6 months old. Additional history elicited by the mother was that swelling had gradually increased in size. There was no history of weight loss, fever and increase or decrease in the size of swelling. Swelling was soft in consistency. Based on these features, the clinical diagnosis of benign tumor of salivary gland was made, and superficial parotidectomy with conservation of facial nerve was performed.

This is an open access article distributed under the terms of the Creative Commons Attribution-NonCommercial-ShareAlike 3.0 License, which allows others to remix, tweak, and build upon the work non-commercially, as long as the author is credited and the new creations are licensed under the identical terms.

For reprints contact: reprints@medknow.com

How to cite this article: Arakeri SU, Banga S. Sialolipoma of parotid gland in a 1-year-old male child: A case report and review of literature. *J Oral Maxillofac Pathol* 2018;22:S57-9.

Access this article online	
Quick Response Code:	Website: www.jomfp.in
	DOI: 10.4103/jomfp.JOMFP_38_15

We received multiple, irregular, nodular, tan-yellow, capsulated tissue bits for the histopathology study. The largest tissue bit was 8 cm × 7 cm × 1 cm, and the smallest was 1 cm × 0.5 cm × 0.2 cm. Cut surface in all tissue bits was solid, lobulated and tan-yellow in appearance [Figure 1].

Microscopic examination of section taken from all tissue bits showed large areas of mature adipose tissue admixed with serous acini and ducts of the salivary gland. Fibrocollagenous tissue, congested blood vessels and focal lymphoid tissue were also noted in some sections. Based on these findings, the diagnosis of sialolipoma was rendered [Figure 2].

DISCUSSION

Sialolipoma can occur both in major and minor salivary glands with the majority of cases being reported in the parotid gland. Clinically, it presents as a slowly growing, asymptomatic painless palpable mass with a wide range of patients aged from 0 month to 84 years with predominance seen in male. Duration of the lesion in published literature varied from 2 months to 11 years.^[5] Kidambi *et al.*^[6] reported that in 90% of published cases, sialolipoma occurred in adults older than 18 years of age. In three cases of sialolipoma, age of the patient was <5 years. There were only two case reports of congenital sialolipoma. Of the two cases, in one case, age of the patient was 0 month, and in the other, it was a 6-week-old male child. In both cases, sialolipoma was noted in the parotid gland.^[6,7] A literature search for sialolipoma, where the size of sialolipoma was mentioned, revealed that size of the tumor varied from 0.9 to 7 cm in diameter with only one case of sialolipoma in the parotid gland of an 11-year-old male child with duration of 11 years was 7 cm × 7 cm.^[7] In the present case, 1-year-old male child presented with a painless mass of 6-month

duration, for which superficial parotidectomy was done. Grossly received specimen in the present case consisted of multiple tan-yellow nodular and lobulated tissue bits with the largest tissue bit measuring 8 cm × 7 cm × 1 cm. To the best of our knowledge, this is the third case of congenital sialolipoma and congenital sialolipoma bigger than 7 cm and having duration of 6 months has been reported very rarely.^[9] It is a very rare gross appearance finding in congenital sialolipoma.

Pathogenesis of sialolipoma is not completely understood. According to some authors, pathogenesis of sialolipoma may be associated with salivary gland dysfunction, leading to altered salivary gland configuration which can be explained microscopically by replacement of the normal salivary gland tissue with mature adipose tissue admixed with atrophic salivary glandular elements and chronic ductal epithelial cells changes such as oncocytic metaplasia, fibrosis and lymphocytic infiltrate.^[8] In the present case, we noted fibrocollagenous tissue with sparse lymphocytic infiltration and focal lymphoid aggregates and atrophic salivary gland elements on histology. Hence, in the present case, salivary gland dysfunction may be the possible pathogenic mechanism.

Various morphologic differential diagnoses for sialolipoma are true lipoma, lipoadenoma, lipomatosis and lipomatous pleomorphic adenoma. True lipoma is characterized by mature adipocytes arranged in a lobular pattern which replaces the normal salivary gland parenchyma. However, in sialolipoma, islands of acinar elements with few ductal structures are entrapped in lipomatous mass. Lipomatosis typically occurs in older patients and is associated with medical conditions such as diabetes mellitus, malnutrition, chronic alcoholism and liver cirrhosis. Lipoadenoma

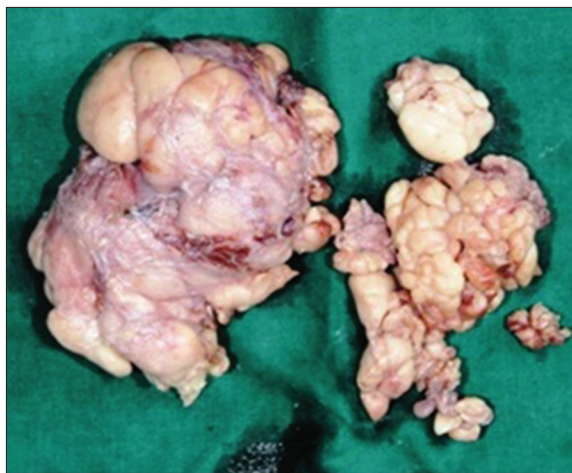

Figure 1: Image of sialolipoma showing multiple, irregular, nodular, tan-yellow, capsulated tissue bits

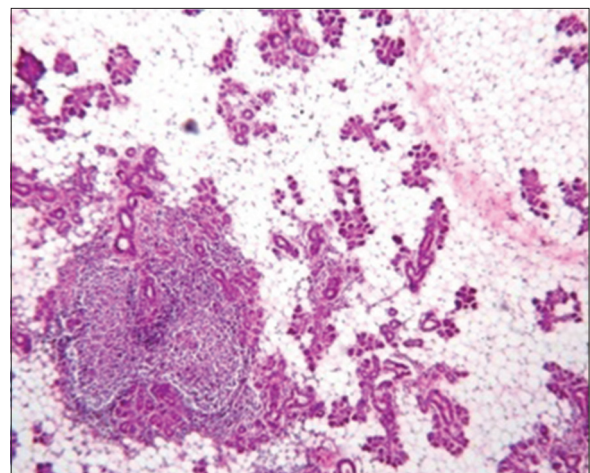


Figure 2: Histology image of sialolipoma showing large areas of mature adipose tissue admixed with serous acini, ducts of salivary gland and focal lymphoid tissue (H&E, ×400)

is composed of adipose tissue and ducts containing eosinophilic proteinaceous material which may show cystic dilatation and are deprived of acinar cells. Adenolipoma also differs from sialolipoma by the lack of organoid arrangement of the ductal type tissue. Pleomorphic adenoma can be distinguished from sialolipoma by the presence of ducts, sheets and strands of epithelial cells intermingled with the fibrous and myxoid element.^[9] In the present case, mature adipose tissue admixed with serous acini and ducts of the salivary gland, fibrocollagenous tissue, congested blood vessels and focal lymphoid tissue were noted. Based on these findings, the diagnosis of sialolipoma was rendered.

Computed tomography (CT) or magnetic resonance imaging can be helpful in narrowing the differential diagnosis and is superior to ultrasonography in defining exact location and texture of the lesion. Fine-needle aspiration, which is the first-line procedure in diagnosing major salivary gland lesions, is of little help as its accuracy is <50% in lipomatous tumors.^[10] Complete excision of the mass with involved salivary glands lobes appears to be adequate for definite management. Most of the tumors in parotid glands are treated with superficial parotidectomy.^[11] There have been no reported cases of recurrence of sialolipoma.^[7]

CONCLUSION

We report a rare but distinct histological variant of lipoma diagnosed in a 1-year-old child in parotid gland on histopathology. This case of congenital sialolipoma is reported because of its rarity and unusual gross morphology. In this case, we received multiple bits of tumor tissue; hence, the possibility of multinodular sialolipoma was also considered. One-month follow-up does not reveal any feature of recurrence. Physicians should be careful of the possibility of sialolipoma, especially when CT scanning shows a well-circumscribed fat-like tissue within the parotid gland and should consider sialolipoma as one of the differential diagnoses. However, histopathology study is a must for the definitive diagnosis of sialolipoma.

Declaration of patient consent

The authors certify that they have obtained all appropriate patient consent forms. In the form, the patient has given his consent for his images and other clinical information to be reported in the journal. The patients understand that name and initials will not be published and due efforts will be made to conceal identity, but anonymity cannot be guaranteed.

Financial support and sponsorship

Nil.

Conflicts of interest

There are no conflicts of interest.

REFERENCES

1. Qayyum S, Meacham R, Sebelik M, Zafar N. Sialolipoma of the parotid gland: Case report with literature review comparing major and minor salivary gland sialolipomas. *J Oral Maxillofac Pathol* 2013;17:95-7.
2. Basak K, Kayipmaz S, Karadayi N. Sialolipoma of minor salivary gland in uvula. *Oral Hyg Health* 2014;2:159.
3. Nagao T, Sugano I, Ishida Y, Asoh A, Munakata S, Yamazaki K, *et al.* Sialolipoma: A report of seven cases of a new variant of salivary gland lipoma. *Histopathology* 2001;38:30-6.
4. Khazaeni K, Jafarian AH, Khajehahmadi S, Rahpeyma A, Asadi L. Sialolipoma of salivary glands: Two case reports and review of the literature. *Dent Res J (Isfahan)* 2013;10:93-7.
5. Ramer N, Lumerman HS, Ramer Y. Sialolipoma: Report of two cases and review of the literature. *Oral Surg Oral Med Oral Pathol Oral Radiol Endod* 2007;104:809-13.
6. Kidambi T, Been MJ, Maddalozzo J. Congenital sialolipoma of the parotid gland: Presentation, diagnosis, and management. *Am J Otolaryngol* 2012;33:279-81.
7. Nonaka CF, Pereira KM, de Andrade Santos PP, de Almeida Freitas R, da Costa Miguel MC. Sialolipoma of minor salivary glands. *Ann Diagn Pathol* 2011;15:6-11.
8. Akrish S, Leiser Y, Shamira D, Peled M. Sialolipoma of the salivary gland: Two new cases, literature review, and histogenetic hypothesis. *J Oral Maxillofac Surg* 2011;69:1380-4.
9. Michaelidis IG, Stefanopoulos PK, Sambaziotis D, Zahos MA, Papadimitriou GA. Sialolipoma of the parotid gland. *J Craniomaxillofac Surg* 2006;34:43-6.
10. Mazlumoglu MR, Altas E, Oner F, Ucuncu H, Calik M. Congenital sialolipoma in an Infant. *J Craniofac Surg* 2015;26:e696-7.
11. Okada H, Yokoyama M, Hara M, Akimoto Y, Kaneda T, Yamamoto H. Sialolipoma of the palate: A rare case and review of the literature. *Oral Surg Oral Med Oral Pathol Oral Radiol Endod* 2009;108:571-6.