



## KLIPPEL-FEIL SYNDROME

## Anatomy

**Dr. Rudragouda S Bulagouda** Associate Professor Department of Anatomy BLDE University's Shri B M Patil Medical College, Hospital & Research Center Vijayapur, Karnataka.

**Dr. Gurushantappa S Kadakol\*** Research Scientist Genetics Laboratory, Department of Anatomy BLDE University's Shri B M Patil Medical College, Hospital & Research Center Vijayapur, Karnataka.  
\*Corresponding Author

## ABSTRACT

We report a rare case of Klippel Feil Syndrome (KFS) having clinical symptoms of webbed neck, low lying hairline, Ectodactyl deformities, left winging of scapula & cardiac anomaly. It is a congenital disorder fusion of two or more cervical vertebrae. The frequency of this syndrome was rare in the world.

## KEYWORDS

Klippel-Feil syndrome, Low Posterior hairline, Ventricular Septal Defects

## INTRODUCTION

Klippel Feil Syndrome was described independently in 1912 by Maurice Klippel and Andre Feil<sup>[1]</sup>. They observed patients with short neck, decreased range of motion in the cervical spine and a low posterior hairline. The syndrome occurs in a heterogeneous group of patients unified only by the presence of a congenital defect in the formation or segmentation of the cervical spine. It results from faulty segmentation along the embryo's developing axis during 3-8 weeks of gestation. The incidence rate of this syndrome is 1 in 40,000 to 50,000 live births<sup>[2]</sup>.

Feil subsequently classified the syndrome into three categories. Type 1 is described as extensive fusion of the cervical and upper thoracic spines. Type 2 is present when there is one or two inter space fusions often associated with hemi vertebrae and atlanto-occipital fusion. Type 3 occurs when thoracic and lumbar spine anomalies are associated with type 1 or type 2 Klippel Feil syndrome. The incidence and prevalence of KFS have not been established and its etiology in spite of a great variety of hypothesis such as genetic, vascular, global fetal insult etc. remains unknown. Various mechanisms of neural complications have been studied in the literature: medullar abnormality, spinal instability, narrowing of the cervical canal, and vascular dysfunction<sup>[3]</sup>.

The most common signs are short neck, low posterior hairline and restricted mobility of upper spine. Deafness or hearing impairment and heart malformations associated abnormalities may include scoliosis, Springer's deformity, hemi vertebrae, basilar impression, spina bifida, anomalies of the kidneys and the ribs, cleft palate, respiratory problems<sup>[4]</sup>. Klippel Feil Syndrome cases needs early recognition and diagnosis of particular guidelines and proper nonsurgical or surgical management. Here we present a case of webbed neck, low lying hairline, and broad chest with winging of scapula in left side, small ventricular septal defect in a 9-year-old baby with Klippel-Feil syndrome.

## CASE REPORT

A 9-year-old baby with a history of Klippel-Feil syndrome was came to our hospital in the outpatient department of pediatrics with symptoms of movement of neck, pain in the left part of the chest, such pain was experienced over a period of three & half years. There was no antenatal history of fever, hypertension, drug intake and any other significant event during pregnancy. The child was born as the second child to healthy non-consanguineous parents. The family history was unremarkable. She was having normal over all physical, mental development & started yearly neck holding, sitting, crawling & standing. She goes to school with satisfactory progress. She is shy, intelligent and understands all exercises herself. She is independent in all her daily activities. When she was near the age of 2 years someone noticed a "funny elevation of the left shoulder" but growth deficiency in stature is noticed.

On physical examination, her weight was 20 kg, her height 113 cm, she was having good built, short in height, head tilted to left side, low lying

hair line, webbed neck (figure 1), the Flexion of neck her and his head circumference 52 cm and low lying hairline were also seen. General examination also showed a remarkable chest asymmetry, left winging of scapula, in her left hand 2<sup>nd</sup> finger shows absence of nail bed & nails, in her right hand 2<sup>nd</sup> & fifth finger shows absence of nail bed & nails, it shows the character of Ectodactyl condition (Figure 2).

Reduction in range of movement at cervical intervertebral joint. Limited lateral flexion on both right & left side, rotation of neck is also limited, partial extension is performed. Patient shows full flexion at cervical intervertebrate joint. Shoulder scapula is elevated on left side. Right shoulder showed normal range of movement whereas left shoulder had limitation of range of movement especially abduction after 90 degree.

Radiological examination of cervical spine revealed blocked vertebrae along with spinal bifida figure (3). Echocardiography test was done in our hospital, report revealed that small Ventricular Septal Defects (VSD) with 3.7 cm. (Figure 4). On her physical examination broad chest revealed high scapula on left side as compared with normal right shoulder joints (Fig 4). Karyotyping analysis performed for baby & her parents, no significant changes were observed in chromosomes (46 XX, XY).

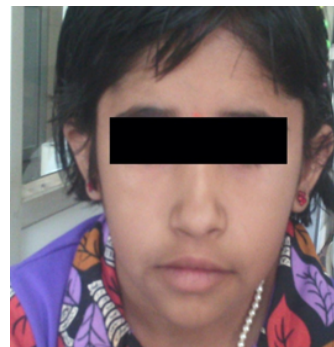

FIGURE 1 Showing webbed neck

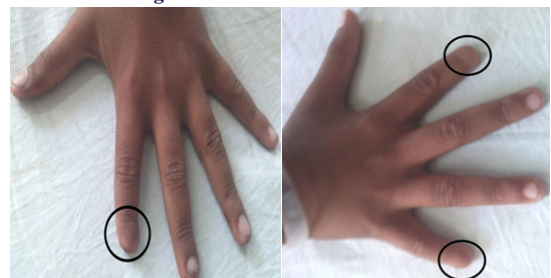
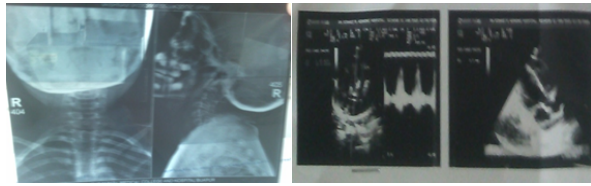

FIGURE 2 Left hand 2<sup>nd</sup> finger nails were absent & Right hand 2<sup>nd</sup> & 5<sup>th</sup> finger nails were absent



**FIGURE 3 Radiological examination of cervical spine revealed blocked vertebrae along With spinal bifida Figure 4 Echo with Small ventricular septal defect**

## DISCUSSION

Klippel-Feil syndrome (KFS) is a complex congenital disorder of improper fusion of at least two cervical vertebrae. The classical clinical trial of KFS, although found in 50 % or less of patients<sup>[5]</sup>, is comprised of a short neck, low posterior hairline, and limited range of cervical motion. Since its first description in 1912<sup>[6]</sup>, a wide range of skeletal and extra-skeletal manifestations have been reported in association with KFS, including scoliosis, cardiac abnormalities, hearing problems, split cervical cord, and Sprengel's deformity, among others<sup>[7]</sup>. The incidence of KFS has been estimated to be anywhere from 1 in 40,000 to 50,000 live births<sup>[8]</sup>, with some studies suggesting a slight female predominance<sup>[9]</sup>. While a number of genes have been described in association with KFS, the exact etiology remains unknown<sup>[8]</sup>. Other studies suggesting a slight female predominance<sup>[9]</sup>.

Feil classified the syndrome into 3 categories: Type 1 includes the cases with fusion of cervical vertebrae, type 2 cases have fusion of cervical and thoracic vertebrae with associated cervical hemi vertebrae (incomplete development of one half of any vertebra) anomaly and abnormal fusion of atlantoaxial joint. Type 3 KFS is characterized by the fusion of cervical, thoracic and/or lumbar vertebrae with associated rib anomalies<sup>[10]</sup>.

Cervical vertebral segmentation anomalies are referred to as the Klippel-Feil anomaly whether they involve fusion of 2 segments or the entire cervical spine Klippel-Feil syndrome appears to be failure of the normal segmentation and fusion processes of mesodermal somites, which occurs between the third and seventh week of embryonic life<sup>[11]</sup>. Klippel feil syndrome is often having other congenital lesions like congenital scoliosis or kyphosis(60%), renal disease(35%), synkinesisor mirror movements(20%), Sprengal deformity(30%) and torticollis, loss of hearing(30%), facial asymmetry and flattening of neck(20%),congenital heart diseases(4% to14%), brainstem lesions, congenital cervical stenosis. Adrenal aplasia, ptosis, facial nerve palsy, syndactylia, diffuse hypoplasia of upper limb may also be seen. Disc degeneration has also been reported in almost all cases<sup>[12]</sup>.

Since the original radiographic classification of KFS by Feil in 1919<sup>[13]</sup>, a wide range of radiographic findings have been reported, such as narrowing of the spinal cord, widening of the spinal canal, osteophyte or disc protrusion, ligament hypertrophy, spinal stenosis, subluxation, and spondylolisthesis<sup>[14]</sup>. In our case radiographic findings shows blocked vertebrae along with spinal bifida and broad chest with winging scapula on left side as compared with normal right shoulder joints.

Congenital heart defects may sometimes (4-14%) accompany KFS. The most common cardiac anomalies associated with KFS are ventricular septal defect and aortic arc anomalies. Zakiet al. reported a KFS case with isolated hypokinesia of the left ventricle. Elumalai et al. reported another KFS case with complete heart block that required pacemaker implantation. Therefore, cardiologic evaluation of KFS cases is essential<sup>[15]</sup>. Echocardiography of our case gives impression of Small Ventricular Septal Defect LV-RV dilatation.

The etiology of KFS and its associations will be unknown. Most of the KFS cases are sporadic. In several genetic studies it has been reported that the mutations of MEOX1 gene that codes for mesenchyme may lead to a recessive subtype of KFS. However, Gray et al. found little correlation with inheritance<sup>[16]</sup>.

In our present case study we have seen low lying hairline, webbed neck & limited cervical range of motion, small ventricular septal defect and we have not seen any renal disease.

## CONCLUSION

Klippel-Feil syndrome is a rare congenital disorder with multiple clinical symptoms like short neck, low posterior hairline, and limited range of cervical motion. Our case was a 9 year-old type KFS case is having above such clinical symptoms. Hence, it requires a systematic clinical trial to diagnose, its complications. Screening should be done for more number of cases to know exact genetic etiology of KFS because it will be helpful to diagnose in early condition.

## CONSENT

Written informed consent was obtained from the patient for publication of this case report and any accompanying images.

## COMPETING INTERESTS

The authors declare that they have no competing interests.

## ACKNOWLEDGEMENTS

Authors are thankful to family members for their participation in this study. We are also thankful to Department of Anatomy, our Hon,ble Vice Chancellor **Dr M S Biradar** BLDE University's Shri B M Patil Medical College Hospital & Research Centre, Registrar, Principal and **Prof. B G Mulimani** Chief Advisor BLDE Association Vijayapur, Karnataka, India for their guidance, support for this study.

## REFERENCES

- Naguib M, Farag H, Ibrahim AEW. Anaesthetic considerations in Klippel- Feil Syndrome, *Can Anaesth Soc J* 1986; 33:66-70.
- Hensinger RN, Lang JE, MacEwen GD. Klippel-Feil syndrome. A constellation of associated anomalies. *J Bone Joint Surg Am.* 1974;56:1246-53.
- Rouvreau P, Glorion C, Langalais J, Noury H, Pouliquen JC. Assessment and neurological involvement of patients with cervical spine congenital synostosis as in Klippel-Feil syndrome: study of 19 cases. *J Pediatr Orthop B* 1998;7(3):179-85.
- Fernandes T, Costa C. Klippel-Feil syndrome with other associated anomalies in a medieval Portuguese skeleton (13th-15th centuries). *J Anat.* 2007;211: 681-5.
- Da Silva EO. Autosomal recessive Klippel-Feil syndrome. *J Med Genet.* 1982; 19:130-4.
- Hensinger RN, Lang JE, MacEwen GD. Klippel-Feil syndrome. A constellation of associated anomalies. *J Bone Joint Surg Am.* 1974;56:1246-53.
- Samartzis D, Lubicky JP, Herman J, Shen FH. Faces of spine care: from the clinic and imaging suite. Klippel-Feil syndrome and associated abnormalities: the necessity for a multidisciplinary approach in patient management. *Spine J.* 2007;7(1):135-7.
- Buonuomo PS, Macchiariolo M, Colafati GS, Rana I, Tomà P, Gonfiantini MV, et al. Persistent neck pain in a girl: Klippel-Feil syndrome. *Arch Dis Child.* 2014;99(3):290-1. doi:10.1136/archdischild-2013-305203.
- Pizzutillo PD, Woods M, Nicholson L, MacEwen GD. Risk factors in Klippel-Feil syndrome. *Spine.* 1994;19(18):2110-6.
- Fedala S, Mahdi HA, Aicha T, Leyla AA, Djamilia M. Klippel Feil Syndrome: A case report and review of literature. *Int J Clin Causes Investig* 2015;6(2): 62-67.
- Vaidyanathan S, Hughes PL, Soni BM, Singh G, Sett P. Klippel-Feil syndrome – the risk of cervical spinal cord injury: A case report. *BMC Fam Pract.* 2002;3:6.
- Sudhakar AS, Nguyen VT AND Chang JB. Klippel-Feil syndrome and supra-aortic arch anomaly: A case report. *Int J Angiol.* 2008; 17(3): 118.
- Feil A. L'absence et la diminution des vertèbres cervicales (étude clinique et pathogénique); le syndrome de réduction numérique cervicales. Theses de Paris; 1919.
- Karasick D, Schweitzer ME, Vaccaro AR. The traumatized cervical spine in Klippel-Feil syndrome: imaging features. *AJR Am J Roentgenol.* 1998; 170(1):85-8.
- Elumalai RS, Nainar MS, Vaidyanathan K, Somasundaram G, Balasubramaniam G. Congenital complete heart block in Klippel-Feil syndrome. *Asian Cardiovasc Thorac Ann* 2013; 21(2): 199-201.
- Bayrakli F, Guclu B, Yakicier C, Balaban H, Kartal U, et al. Mutation in MEOX1 gene causes a recessive Klippel-Feil syndrome subtype. *BMC Genetics* 2013; 14:95-96.