

CASE REPORT

Acrokeratosis Verruciformis of Hopf: A Rare Case Report

R. M. Potekar¹, Bhaswanth. P^{1*}, Ambica.C¹, Swati Arora¹, Katyayani Palur¹

¹Department of Pathology, BLDEU's Shri B.M.Patil Medical College, Hospital & Research Centre, Vijayapur-586 103 (Karnataka), India

Abstract:

Acrokeratosis Verruciformis of Hopf (AKV) is rare autosomal dominant cutaneous dermatosis described by Hopf in 1931. It is presented at birth but may appear in early child hood; sometimes the onset may be delayed until fifth decade of life. It usually presents with multiple planar wart – like lesions, typically observed on the dorsal aspect of the hands and feet but may extend on to knees, elbows, forearms and also on other parts of the body. The main differential diagnosis is Darier disease and seborrheic keratosis which has similar presentation. The unique finding of AKV is Church spire elevation of epithelium which differentiates from Darier disease. Due to the scarcity of the cases here we present a case of AKV in a 29 year old male which was diagnosed on clinical examination and confirmed with histopathological examination. We have made an attempt to describe histologic features of AKV with differential diagnosis of these lesions through review of literature.

Keywords: Acrokeratosis Verruciformis of Hopf, Churchspires, Darier Disease

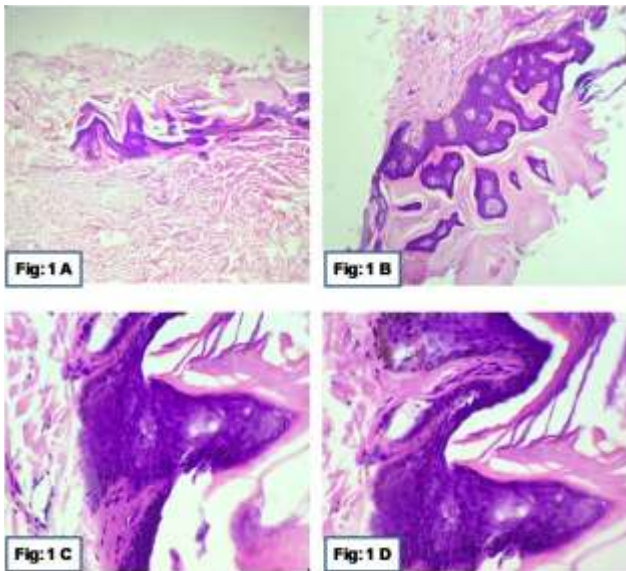
Introduction:

Acrokeratosis verruciformis of Hopf (AKV) is rare autosomal dominant cutaneous dermatosis described by Hopf in 1931[1]. It is presented at birth but may appear in early childhood; sometimes the onset may be delayed until fifth decade of life [2]. Both sexes are affected with a male to female ratio of 5:1[1]. It usually presents with multiple planar warts – like lesions, typically

observed on the dorsal aspect of the hands and feet but may extend on to knees, elbows, forearms and also on other parts of the body [2, 3]. Lesions identical to those of AKV can also be observed in patients with Darier disease and seborrheic keratosis. Presence of church spires and absence of squamous and basaloid cells helps to differentiate from seborrheic keratosis [3].

Case Summary:

A 29 year old male presented with multiple papules since eight years. Patient first noticed these lesions on the dorsum of both the hands which spread symmetrically to the trunk, chest and extremities over the years. The lesions were hyperpigmented and hyperkeratotic flat papules which ranged in size from 0.5– 2cm. No history of any complaints in the form of itching, burning, or pain present. No history of similar complaints in any of the family members. No seasonal variation or any other systemic complaints present. Skin biopsy was performed and histopathological examination showed hyperkeratosis, mild acanthosis, papillomatosis and focal circumscribed elevation of epidermis resembling churchspires (Fig 1: A, B, C, D). Dermis shows fibrocollagenous tissue and normal adnexal structures.



**Fig.1A: Microphotograph showing Epidermis and Dermis (H&E Stain, X100),
Fig.1B: Microphotograph showing Acanthosis and Hyperkeratosis (H&E Stain, X200),
Fig.1C and 1D: Microphotograph showing Circumscribed Elevation of Epidermis Resembling 'Church Spires' (H&E Stain, X400)**

Discussion:

AKV is an autosomal dominant genetic disorder of unknown etiology. There is no sexual predilection for this disorder. The papules are flat, warty and examination may reveal thickening of palmar skin and punctate keratosis on palms and soles. Interruption of the dermal ridges is similar to that seen in Darier disease. Thickened whitish nails with longitudinal ridges may be also observed. Histopathological examination of skin biopsy is confirmatory for AKV [2]. Lesions identical to those of AKV can also be observed in patients with Darier disease and seborrheic keratosis. Presence of church spires and absence of squamous and basaloid cells helps to

differentiate from seborrheic keratosis [3]. The lesions in Darier disease are initially nondyskeratotic with a chance of developing dyskeratosis at a later age, whereas AKV remains nondyskeratotic throughout life. The keratinisation process in AKV is normal and exaggerated, whereas in Darier disease it is accentuated, altered and faulty [2]. The unique finding of AKV is a church spire while of Darier disease is benign suprabasal dyskeratosis with corps rond, which rules out Darier disease from this case [4]. Clinically, the following conditions: epidermodysplasia verruciformis, planar warts should be kept as differential diagnosis. A study done by Dhitavat *et al* has shown that AKV can arise from a missense mutation in ATP2A2, encoding the sarcoendoplasmicreticulum Ca²⁺-ATPase2 pump, which is also defective in Darier disease, thus providing an evidence that AKV and Darier disease are allelic disorders with variable phenotypic expressions [5]. There are two types of AKV based on age of onset. They are classical AKV which is seen in childhood and sporadic AKV which is seen in an older age group. Few authors have reported a P602L mutation within the ATP binding domain of ATP2A2 in classical AKV and A698V codon change in ATP2A2 in sporadic AKV [1].

The effective treatment for AKV is superficial ablation. Applications of retinoic acid have been helpful in some cases. Lesions tend to persist throughout life and become more prominent after prolonged sun exposure [2]. Malignant transformation of the lesions into squamous cell carcinoma has been reported [2, 3]. In our case there was no evidence of malignancy neither

clinical nor histopathological sections studied from various sites. Additional case reports of AKV will help to recognise the risk factors in this

condition. In the future, more cases should be studied and genetic studies of sporadic AKV should be conducted.

References

1. Bang CH, Kim HS, Park YM, Kim HO, Lee JY. Non-familial Acrokeratosis Verruciformis of Hopf. *Ann Dermatol* 2011; 23: S1. S61-3.
2. Rallis M, Economidi A, Papadakis M, Verros L. Acrokeratosis verruciformis of Hopf (Hopfdisease): Case report & review of literature. *Dermatol Online J* 2005; 11:10.
3. RegeVI, Hede RV, Nadkarni NS. Acrokeratosis verruciformis of HOPF. *Indian J Dermatol Venereol Leprol* 1992; 58: 95-98.
4. Nair PA. Acrokeratosis verruciformis of hopf along lines of blaschko. *Indian J Dermatol* 2013; 58:406.
5. Dhitavat J, Macfarlane S, Dode L, Leslie N, Sakuntabhai A, MacSween R, Saihan E, Hovnanian A. Acrokeratosis verruciformis of Hopf is caused by mutation in ATP2A2: evidence that it is allelic to Darier's disease. *J Invest Dermatol* 2003; 120:229-32.

***Author for Correspondence:** Dr. Bhaswanth P, Department of Pathology, BLDEU's Shri B.M.Patil Medical College, Hospital and Research Centre, Vijayapur-586 103, Karnataka, India
Email: anweshkhadgam@gmail.com Cell: 8123259778