

# Multidetector Computed Tomography in Small and Large Bowel Lesions

Ravi Kumar Yeli<sup>1</sup>, Shivanand V. Patil<sup>2</sup>, Nagababu Pyadala<sup>3</sup>

<sup>1</sup>Senior Resident, <sup>2</sup>Assistant Professor, Department of Radiology and Imaging, Shri B M Patil Medical Collage and Research Centre, BLDE University, Ashram Road, Vijayapura, <sup>3</sup>Research Associate, MNR Foundation for research and innovation, Sangareddy, Telangana State, India.

**Corresponding author:** Dr. Shivanand V. Patil, Assistant Professor, Department of Radiology and Imaging, BLDE University's, Shri B M Patil Medical Collage and Research Centre, Ashram Road, Vijayapura -586103, India

**How to cite this article:** Ravi Kumar Yeli, Shivanand V. Patil, Nagababu Pyadala. Multidetector computed tomography in small and large bowel lesions. International Journal of Contemporary Medicine Surgery and Radiology. 2018;3(1):151-154.

## A B S T R A C T

**Introduction:** Technological advances in CT have changed the practice of gastrointestinal radiology. This was a prospective study to evaluate the role of multidetector computed tomography (MDCT) in diagnosis of small and large bowel lesions.

**Material and Methods:** This study was carried out in MNR Medical College and Hospital from March 2015 to April 2017. A total of 52 patients were examined in this study. CT findings were correlated and confirmed by colonoscopy, biopsy, postoperative findings or follow-up CT.

**Results:** 33 (63.5%) were males and 19 (36.5%) were female patients. Most affected age group was 51-60 years (23.1%) followed by 61-70 years (19.2%). Lesions were commonly found in Ileocecal Junction and sigmoid colon (30.4%). Out of 52 cases Asymmetric wall thickening was reported in 45 (86.5%) and Symmetric wall thickening was reported in 7 cases (13.5%). 12 cases (23.1%) had focal involvement of the bowel, 31 cases (59.6%) had segmental involvement and 9 cases (17.3%) had diffuse involvement of the bowel. MDCT diagnosed 28 as neoplastic and 24 as Non Neoplastic, Histopathology confirmed these lesions with 27 as Neoplastic and 25 Non Neoplastic. Among the 27 lesions identified as Neoplastic by MDCT, 19 cases were Malignant and 8 Cases were Benign. Histopathology confirmed 17 cases as Malignant and 8 Cases as Benign.

**Conclusion:** MDCT had a sensitivity of 96.29%, specificity of 92.00% in differentiating Neoplastic and Non Neoplastic Lesions and is the modality of choice.

**Key words:** Gastrointestinal Radiology, Multidetector Computed Tomography, Bowel Lesion

## INTRODUCTION

With the development of high resolution scanners, technical refinements in obtaining better quality studies, and the accumulated clinical experience leading to better interpretation, the role, indications, and accuracy of CT of the gastrointestinal tract have dramatically enlarged and improved.<sup>1,2</sup> Conventional barium examinations remain superior to CT for evaluating intra-luminal and mucosal disease, but CT is far more accurate for evaluating the intramural and extra-intestinal components, including involvement of the mesentery, peritoneal cavity, retro peritoneum and solid organs. Thickening of the bowel wall is the commonly identified abnormality on CT in case of small and large bowel wall pathologies. The differential diagnosis for bowel wall thickening are wide.<sup>3</sup> Michael et al studied the CT characteristics of bowel wall thickening based on pattern of attenuation and enhancement; degree, symmetry, and extent of thickening and associated abnormalities.<sup>4,5,6</sup> Colorectal cancer is the third most common cancer in men and the second in women worldwide. The age adjusted incidence rates of colorectal cancer in all the Indian cancer registries are very close to the lowest rates in the world.

However population based time trend studies show a rising trend in the incidence of colorectal carcinoma in India.<sup>5,7,8</sup> The role of conventional CT in patients with colorectal tumours is controversial. Preoperative staging accuracy has been disappointing, ranging between 48% and 77%.<sup>6,9,10</sup> Hence this study is an attempt to evaluate the role of CT in characterize wall thickening in patients with colorectal lesions as either benign or malignant based on the pattern of attenuation, degree of wall thickening, symmetric versus asymmetric wall thickening, focal, segmental or diffuse involvement and associated peri-enteric abnormalities.

## MATERIAL AND METHODS

This was a prospective correlative study conducted in the Department of Radio Diagnosis, MNR Medical College and Hospital during the period of 2 years from March 2015 to April 2017. Data was collected from patients with symptoms related to gastrointestinal system or diagnosed with bowel wall lesions on other modalities like USG, X-Ray or Barium studies sent for further evaluation with MDCT. Study population includes admitted patients, OPD patients of all age groups from urban or rural Populations. Patients

with bowel lesions were evaluated with MDCT (Siemens 16 Slice Somatom Sensation Cardiac) initially with plain CT scan with patient in supine position. Slice thickness of 5mm with 1mm reconstruction was used. Oral contrast was provided 45 min prior to the contrast enhancing CT image acquisition, (1.5 lit water with 100ml mannitol). Rectal contrast immediately before with 1lit water with 50ml mannitol. Post contrast study was performed in dual triphasic protocol after injecting approximately 1.5 ml /kg of non-ionic water soluble iodinated intravenous contrast 370 mg iodine/ml Iopromide (Ultravist 370). The axial and MPR/MIP images were analyzed and findings were correlated with Histopathological Diagnosis.

### RESULTS

Among 52 patients, 33 (63.5%) were males and 19 (36.5%) were female [Figure 1]. Most affected age group was 51-60 years (23.1%) followed by 61-70 years (19.2%) [Table1]. Most of the patients were complained about abdominal pain and fever (26.9%) and 17.3% patients suffering from altered

Age group	Frequency	Percent
Less than 21	2	3.8%
21 to 30	4	7.7%
31 to 40	5	9.6%
41 to 50	7	13.5%
51 to 60	12	23.1%
61 to 70	10	19.2%
71 to 80	9	17.3%
above 80	3	5.8%
Total	52	100.0%

**Table-1:** Distribution of age group

Symptoms	Frequency	Percentage
ABD	1	1.9%
ABD,ABH	1	1.9%
ABD,ABP	3	5.8%
ABD,ABP,ABH	1	1.9%
ABH	2	3.8%
ABH,ABD	2	3.8%
ABH,ABP	2	3.8%
ABH,BPR	9	17.3%
ABH,WL	1	1.9%
ABH,WL,ABP	1	1.9%
ABH,WL,BPR	1	1.9%
ABP	4	7.7%
ABP,ABD	3	5.8%
ABP,ABD,Fever	2	3.8%
ABP,ABD,WL	2	3.85%
ABP,Fever	14	26.9%
ABP,Fever,ABD	1	1.9%
ABP,WL, fever	2	3.85%
TOTAL	52	100.0%

\* ABD= Abdominal Distension, ABH= Altered Bowel Habits, ABP= Abdominal Pain, BPR= Bleeding Per Rectum, WL= Weight loss.

**Table-2:** Presenting Complaints

Location	Frequency	Percentage
Ac	1	1.9%
Ac, Tc	1	1.9%
Ax, Ca	1	1.9%
Ca, Ac	1	1.9%
Ca, Ac, Sc	1	1.9%
Dc	2	3.8%
Dc, Jc	1	1.9%
Dc, Sc	1	1.9%
IC Jnction (I, C, Ax, Ac)	16	30.4%
Jc	3	5.8%
Ac	5	9.6%
Sc	16	30.4%
Tc, Dc, Sc,	3	5.8%
Total	52	100.0%

\* Ac= Ascending colon, Tc= Transverse Colon, Ax= Appendix, Ca= Carcinoma, Sc= Sigmoid Colon, Dc= Duodenum Junction, Jc= Jejunal Junction, Tc= Transverse Colon.

**Table-3:** Location of the lesions

Luminal narrowing	Frequency	Percentage
Gross	10	19.2%
Mild	13	25.0%
Moderate	28	53.8%
No	1	1.9%
Total	52	100.0%

**Table-4:** Luminal narrowing

Thickness of BI	Frequency	Percentage
Gross	14	26.9%
Mild	8	15.4%
Moderate	30	57.7%
Total	52	100.0%

**Table-5:** Thickness of bowel involved

Symmetry	Frequency	Percentage
Asymmetrical Thickening	45	86.5%
Symmetrical Thickening	7	13.5%
Total	52	100.0%

**Table-6:** Symmetry of bowel wall thickening

Length of bowel involved	Frequency	Percent
Diffuse	9	17.3%
Focal	12	23.1%
Segmental	31	59.6%
Total	52	100.0%

**Table-7:** Length of bowel involved

LYMPH nodes	Frequency	Percent
Distant	1	1.9%
Local	40	76.9%
Local and Distant	5	9.6%
No	6	11.5%
Total	52	100.0%

**Table-8:** Lymph nodes

CT Diagnosis	Frequency	Percent
Neoplastic, Malignant	20	38.5%
Neoplastic, Benign	8	15.4%
Non neoplastic, Infective	3	5.8%
Non neoplastic, Inflammatory	19	36.5%
Non neoplastic, Ischemic	2	3.8%
Total	52	100.0%

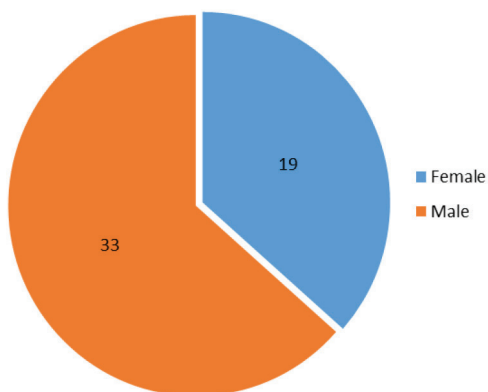
**Table-9: MDCT impression**

Histopath	Frequency	Percent
NeoPlastic,Benign	10	19.2%
Neoplastic, Malignant	17	32.7%
Non Neoplastic,Infective	11	21.1%
Non Neoplastic,Inflammatory	11	21.1%
Non Neoplastic,Ischemic	3	5.8%
Total	52	100.0%

**Table-10: Histopathology findings**

	Neoplastic by Histopathology	Non Neoplastic by Histopathology	Total
Neoplastic by MDCT	26	2	28
Non Neoplastic by MDCT	1	23	24
Total	27	25	52

**Table-11: Overall diagnosis**

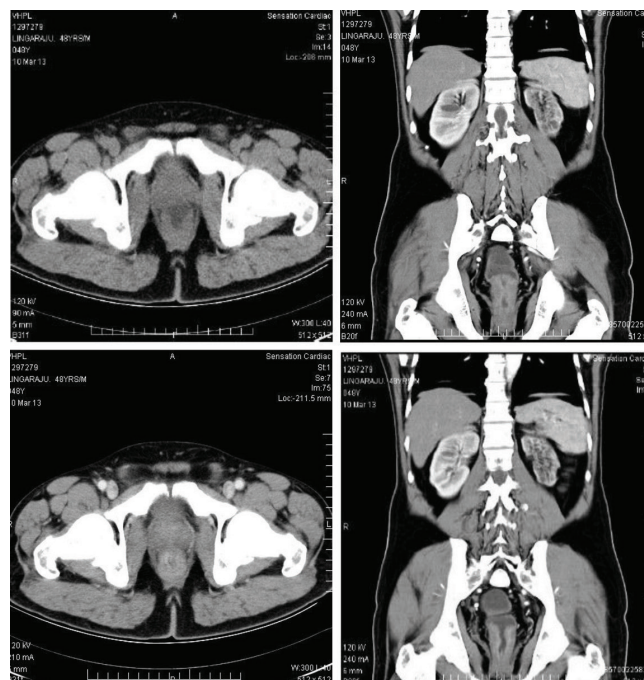

**Figure-1: Gender distribution**

Sensitivity	= 96.30%	95% CI: 80.97% to 99.38%
Specificity	= 92.00%	95% CI: 73.93% to 98.78%
Positive Predictive Value	= 92.86%	95% CI: 76.46% to 98.92%
Negative Predictive Value	= 95.83%	95% CI: 78.81% to 99.30%

**Figure-2: Sensitivity and specificity of MDCT**

bowel habits and bleeding per rectum [Table 2]. Lesions were commonly found in Ileocecal Junction and sigmoid colon (30.4%) [Table3]. There was gross luminal narrowing in 19.2% patients, mild in 25% and moderate in 53.8% patients respectively [Table4]. Moderate wall thickening was most common in patients (57.7%) [Table5]. Out of 52 cases Asymmetric wall thickening 45 (86.5%) Symmetric wall thickening 7 cases (13.5%). Among 45 Asymmetric wall thickening 21 were neoplastic and 24 were Non neoplastic. Among 7 Symmetric wall thickening 6 were neoplastic



**Figure-3: Abdominal distension and bleeding per rectum on CT asymmetric focal hyper dense enhancing mass lesion in the rectum.**

and 1 non neoplastic [Table 6]. 12 cases (23.1%) had focal involvement of the bowel, 31 cases (59.6%) had segmental involvement and 9 cases (17.3%) had diffuse involvement of the bowel [Table 7]. MDCT diagnosed 28 as neoplastic and 24 as Non Neoplastic, Histopathology confirmed these lesions with 27 as Neoplastic and 25 Non Neoplastic. Among the 27 lesions identified as Neoplastic by MDCT, 19 cases were Malignant and 8 Cases were Benign. Histopathology confirmed 17 cases as Malignant and 8 Cases as Benign [Table 9, 10, 11].

## DISCUSSION

This was a Hospital based correlative study to describe the role of MDCT in the evaluation of small and large bowel wall mass lesions. Out of 52 patients, 33 were males (63.5%) and 19 were females. The age group commonly affected were those in the age group of 51-60 yrs (23.1%). Our findings were concordance with the study done by *Laisbram RS et al.* They studied the pattern of colorectal lesions in 54 patients and found that males were more commonly affected (53.71%) and most of the patients were in the age group of 61-70yrs (24.07%).<sup>11</sup> Abdominal pain and Fever was the commonest symptom in patients (26.9%) and followed by altered bowel habits with bleeding per rectum (17.3%). Abdominal pain / Altered Bowel habits with Fever was the commonest symptom in patients with Non Neoplastic(Infective/Inflammatory lesions) and Altered bowel habits with bleeding per rectum was common among Neoplastic (Malignant lesions). Among the 52 cases 33 (63.5%) cases showed heterogeneous enhancement and 19 (36.5%) cases showed homogenous enhancement. Out of 33 Heterogeneous enhancement cases 25 were found in Non-neoplastic lesions. This was in agreement with the study done by Jorge ahuhalli, Jack Wittenberg et al. and Teresa Farnandese et al. who

described that the target sign is a feature of Non Neoplastic lesions seen in cases of Inflammatory, Infectious or Ischemic Ileocolitis.<sup>12,13,14</sup>

Homogenous enhancement was more common with neoplastic lesions and that to commonest among benign lesions benign lesions. Similar findings reported by Macari M et al and Jack Wittenberg who have told that homogenous attenuation is a feature of neoplastic lesions which show gray enhancement more common with benign disease.<sup>4,13</sup> Moderate wall thickening (10-20 mm) was most common among feature with 30 cases corresponding to (57.7%) and Mild wall thickening (4-10mm) with 8 cases (15.4%) which more among Non-Neoplastic (Infective, Inflammatory or Ischemic) and Neoplastic Benign conditions. Gross wall thickening (>20mm) among 14 cases (28.9%) is more common with neoplastic malignant lesions like Adenocarcinoma or Carcinoids. This is in agreement with the study done by Macari M et al who described that mild to moderate wall thickening is a feature of inflammatory and infective lesions of bowel wall and marked wall thickening is a feature of neoplastic malignant lesions of colon such as adenocarcinoma and Carcinoids.<sup>4</sup> Out of 52 cases Asymmetric wall thickening 45 (86.5%) Symmetric wall thickening 7 cases (13.5%). Among 45 Asymmetric wall thickening 21 were neoplastic and 24 were Non neoplastic. Among 7 Symmetric wall thickening 6 were neoplastic and 1 non neoplastic. It had a sensitivity of 22.22%, specificity of 96.0%, positive predictive value of 85.71%, and a negative predictive value of 53.33% with P value of 0.054 which is not statistically significant in differentiating neoplastic and non-neoplastic lesions. Among the 52 cases, 12 cases (23.1%) had focal involvement of the bowel, 31 cases (59.6%) had segmental involvement and 9 cases (17.3%) had diffuse involvement of the bowel. Of the 9 benign cases 3 cases (33.33%) had focal involvement of the bowel. Macari M et al. study has found that focal involvement of bowel is a feature of malignancy which is in concordance with our study. They also found that diffuse involvement of the bowel is a feature of inflammatory/infective etiology which is again in agreement with our study.<sup>4</sup> However out of 12 focal involvement only 8 cases were proved to be malignant (66.67%). Segmental involvement (59.6%) is the most common feature in our study which is feature of both Neoplastic and Non Neoplastic bowel wall lesions. Hence according our study segmental involvement of the colon is not a reliable indicator in differentiating benign from malignant lesions of the colon. Both Neoplastic and Non Neoplastic lesions had multiple enlarged lymph nodes in approximately 88.5% of the cases. Hence according to our study presence of enlarged lymph nodes in patients with colonic wall thickening has no role in differentiating neoplastic v/s non-neoplastic conditions. However et al<sup>2</sup> in their study have described that hypo-attenuating bulky lymphadenopathy is a supportive finding in patients with lymphoma of colon.<sup>15</sup> Macari M et al. have described that low-attenuation lymph nodes with a rim of contrast enhancement or calcified lymph nodes should alert one to the possibility of tuberculosis.<sup>4</sup> Distant metastasis was common with malignant lesions like Adeno carcinomas and Bowel Carcinoids. Liver metastases was common finding followed by lung and Bone metastasis. Harvey CZ et al in their

study have described that liver is the predominant organ to be involved with metastases from colorectal cancer.<sup>16</sup> Among the 52 cases MDCT diagnosed 28 as neoplastic and 24 as Non Neoplastic, Histopathology confirmed these lesions with 27 as Neoplastic and 25 Non Neoplastic.

## CONCLUSION

Hence in our study MDCT had a sensitivity of 96.29%, specificity of 92.00%, positive predictive value of 92.85% and a negative predictive value of 95.83% in differentiating Neoplastic and Non Neoplastic Lesions with P value of 0.001 this association is considered very significant statistically. Hence CT is an excellent modality in differentiating Neoplastic and Non Neoplastic Lesions.

## REFERENCES

- Balthazar EJ. CT of the Gastrointestinal Tract: Principles and interpretation. AJR 1991; 156.
- Almeida MD, Jose J, Oneto J, Restrepo R. Bowel wall thickening in children. CT findings. Radiographics 2008; 28(1):727-746.
- Rockey DC, Halvorsen RA jr, Higgins JL, Cello JP. Prospective evaluation of patients with bowel wall thickening. Am J Gastroentero 1995;90(1):99-103.
- Macari M, Balthazar EJ. CT of bowel wall thickening, significance and pitfalls of interpretation. AJR 2001;176 (2):1105-1116.
- Mohandas KM. Colorectal cancer in india: controversies, enigma and primary prevention. Indian j gastroenterology 2011;30 (3):3-6.
- Filippone A, Ambrosini R, Fuschi M, Marinelli T, Genovesi D, Bonomo L. Preoperative T and N staging of colorectal cancer: Accuracy of contrast enhanced Multi-Detector row CT colonography- Initial experience. Radiology 2004;231 (5): 83-90.
- Isherwood I. Sir Godfrey Hounsfield. Radiology 2005;234 (2):975-976.
- Theoni RF, Cello JP. CT imaging of colitis. Radiology 2006;240 (4):623-638.
- Horton KM, Corl FM, Fishman EK. CT evaluation of colon-Inflammatory disease. Radiographics 2000;20 (3):399-418.
- Gailard F. Ischaemic colitis. www.radiopaedia.org 2008.
- Furukawa A, Kanasaki S, Kono N, Wakamiya M, Tanaka T, Takahashi M, Murataka K. CT diagnosis of acute mesenteric ischemia from various causes. AJR 2009;192 (6):408-416.
- Ahualli j. The Target sign: Bowel wall. Radiology 2005;550.
- Jack Wittenberg, Mukesh G. Harisinghani, Kartik Jhaveri, Jose Varghese and Peter R. Mueller. Algorithmic Approach to CT Diagnosis of the Abnormal Bowel Wall. Radiographics 2002;22 (5):1033-1107.
- Teresa Fernandes, Maria I. Oliveira, Ricardo Castro, Bruno Araujo, Barbara Viamonte and Rui Cunha. Bowel wall thickening at CT: simplifying the diagnosis. Insights Imaging 2014;5(2):195-208.
- Neri E, Glusti P, Battolla L, Vagli P, Boraschi P, Lencioni R, Caramella D, Bartolozzi C. Colorectal cancer: Role of CT colonography in preoperative evaluation after incomplete colonoscopy. Radiology 2002;223 (4):615-619.
- Horton KM, Abrams RA, Fishman EK. Spiral CT of colon cancer: Imaging features and role in management. Radiographics 2000;20 (2):419-430.

**Source of Support:** Nil; **Conflict of Interest:** None

**Submitted:** 12-02-2018; **Published online:** 15-03-2018