

LETTER

Mask-induced psoriasis lesions as Köebner phenomenon during COVID-19 pandemic

Dear Editor,

Universal use of face masks as a means of source control in public places during the COVID-19 pandemic is advocated by all health agencies. A high degree of compliance will maximize the impact of universal masking in public. Here, we describe a case of ear-looped mask-related Köebner phenomenon in a known case of psoriasis at the time of coronavirus disease (COVID-19) pandemic.

1 | CASE REPORT

A 74-year-old male developed mild itchy, well defined erythematous, scaly lesion in the left supra-auricular area and it was extending to the adjoining scalp area also since the past 4 weeks. Cutaneous examination revealed lesions typical of psoriasis—well defined plaque with silvery white scales (Figure 1). He was a known case of psoriasis with prolonged remission after administration of secukinumab. The present visit was almost after 4 months. He gave history of using ear-looped mask (Figure 2) since the start of the COVID-19 pandemic in India since March 2020. He was advised topical corticosteroids and avoidance of use of ear-looped mask.

2 | DISCUSSION

The COVID-19 pandemic forced the exponential use of masks by general population as personal protective equipment (PPE). The prolonged use of

facial masks may result in several skin problems, mostly irritant contact dermatitis (ICD), but also flare-ups of pre-existing dermatoses (eg, rosacea), contact urticaria, allergic contact dermatitis (ACD), and impetigo.^{1,2}

In the index case prolonged use of ear-looped mask-induced Köebner phenomenon in the supraauricular area and adjoining scalp. Interestingly the phenomenon induced the lesions over the left ear, probably due to the common practice that the loop is hooked on the right ear first and then to the left ear. The left ear loop is put not fitting to the postauricular groove perfectly and in the process of talking, etc, with the mask on, puts pressure and the incidental injury more on the left side. The Köebner phenomenon in psoriasis is a common response to skin trauma/injury, may be mild or severe.³

It has been shown that the disruption of a functional and structural permeability barrier is critical for the appearance of psoriasis as Köebner reaction.⁴ Accordingly, the importance of the rupturing of the epidermis in initiating the Köebner response has been well documented. Along

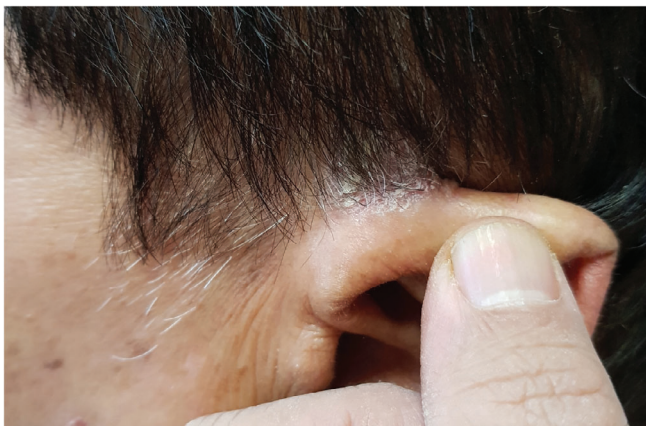

FIGURE 1 Well-defined plaque with silvery white scales

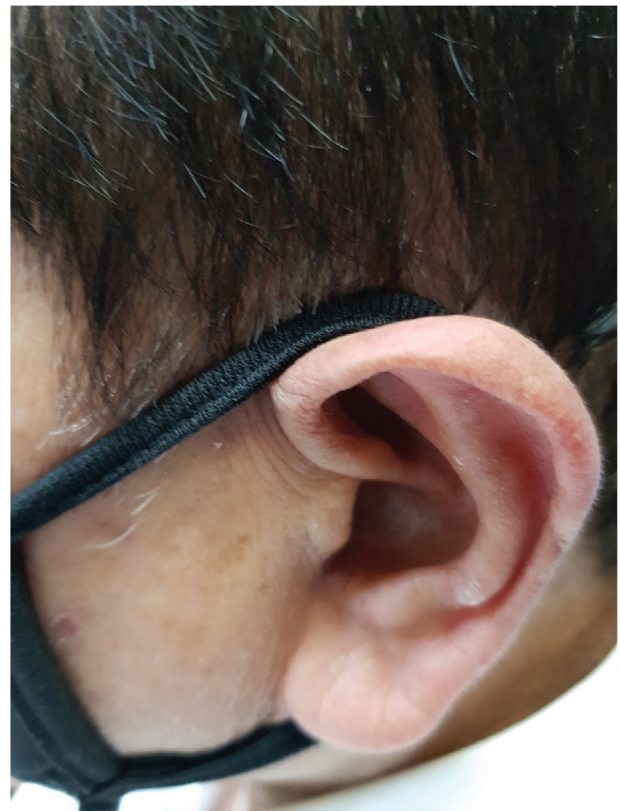

FIGURE 2 Face mask with ear loops

with it, an important role of secondary dermal reactions in the development of psoriatic lesions at the site of injury has also been defined.⁵


The studies show that wearing face masks is linked to development of itch, and scratching can lead to incorrect use of face masks, resulting in reduced protection.⁶

Persons with preexisting dermatoses including psoriasis, who are prone to develop Köebner phenomenon, should be advised not to use ear-looped face masks during this pandemic.

They should be encouraged to use masks without ear-loop or with gaiters of good length which can be tied to scalp bypassing the ear. Another idea to reduce this problem is to tie the mask loop on occipital area with a plastic band.⁷ Face mask with ties or face mask with bands is advocated in such patients.

DATA AVAILABILITY STATEMENT

Data sharing not applicable to this article as no datasets were generated or analysed during the current study.

Sharad D. Mutalik¹
Arun C. Inamdar² 

¹Cutaneous Laser and Aesthetic Surgeon, Planet Skin, Pune, India

²Department of Dermatology, SBMP Medical College Hospital & Research Center, BLDE University, Vijayapura, India

Correspondence

Arun C. Inamdar, MD, FRCP (Edinburgh), Professor and Head,

Department of Dermatology, SBMP Medical College Hospital & Research Center, BLDE University, Vijayapura, 586103, India.

Email: aruninamadar@gmail.com

ORCID

Arun C. Inamdar  <https://orcid.org/0000-0002-8877-3723>

REFERENCES

1. Balato A, Ayala F, Bruze M, et al. European task force on contact dermatitis statement on coronavirus 19 disease (COVID-19) outbreak and the risk of adverse cutaneous reactions. *J Eur Acad Dermatol Venereol*. 2020;34(8):e353-e354.
2. Yu Q, Li W, Yang L. A case of goggle-mask-related impetigo at the time of the COVID-19 pandemic. *Dermatol Ther*. 2020;e13636 [published online ahead of print, May 21, 2020]. <https://doi.org/10.1111/dth.13636>
3. Mohla G, Brodell RT. Koebner phenomenon in psoriasis. A common response to skin trauma. *Postgrad Med*. 1999;106:39-40.
4. Ghadially R, Reed JT, Elias PM. Stratum corneum structure and function correlates with phenotype in psoriasis. *J Invest Dermatol*. 1996; 107:558-564.
5. Hendriks AG, Keijsers RR, Seyger MM, van Erp PE, van de Kerkhof PC. Are newly discovered drivers of immune-mediated skin disorders expressed in normal skin regenerating from standardized surface injury? *Dermatology*. 2014;228:255-260.
6. Szepietowski JC, Matusiak Ł, Szepietowska M, Krajewski PK, Białynicki-Birula R. Face mask-induced itch: a self-questionnaire study of 2,315 responders during the COVID-19 pandemic. *Acta Derm Venereol*. 2020;100(10):adv00152.
7. Jiang W, Cao W, Liu Q. Wearing the N95 mask with a plastic handle reduces pressure 59 injury. *J Am Acad Dermatol*. 2020;82(6):E191-E192. <https://doi.org/10.1016/j.jaad.2020.04.001>