

LUTEMBACHER'S SYNDROME - A CASE REPORT

Biradar SM, Nilesh Malgar

Department of Medicine, BLDEU's Shree B M Patil Medical College & Research Centre, Vijayapur, Karnataka.

ABSTRACT

Lutembacher's syndrome is a rare heart disease comprises ASD secundum with mitral stenosis. Here we will discuss a case of 28 years old man, non-diabetic, non-hypertensive, admitted in BLDE Hospital on 10-04-2017 with complaints of respiratory distress and chest pain for 10 days. On detailed examination and investigation, he was found to be having Lutembacher's syndrome.

Key words: Atrial septal defect, Lutembacher's syndrome, Mitral stenosis.

INTRODUCTION

Lutembacher's syndrome refers to a congenital atrial septal defect complicated by development of acquired mitral stenosis [1,2]. The incidence of MS in patients with ASD is 4 to 6%, where as the incidence of ASD in patients with MS is 0.6 to 0.7% [1,3]. The iatrogenic Lutembacher's syndrome which is rare in the pediatric age group [4]. In patients with MS who had undergone percutaneous balloon mitral valvuloplasty through the Transseptal approach, the latter procedure created an ASD during the procedure.

CASE REPORT

A 28 year male presented with a history of difficulty in respiration, chest pain, for last 8 days. Difficulty in respiration was more during his routine work (NYHA GIII) and in supine position. Difficulty in respiration is gradually progressive in nature. Chest pain is insidious in onset, continuous, retrosternal, non-radiating, not associated with nausea vomiting and sweating. There is no symptoms of cough, palpitation, symptoms of upper respiratory tract infection.

On examination, a conscious thin built young age male patient, weight 55kg with height 153cm, his blood pressure was 100/60mmHg and pulse 86bpm, respiratory rate 20 cycles per minute. No pallor, cyanosis, clubbing, icterus, oedema, splinter haemorrhages, subcutane-

ous nodules or rashes. JVP has elevated at 10 cm of water. Oxygen saturation was 93% on room air.

On precordial examination the apex impulse in left 5th intercostal space in anterior axillary line, it is hyperdynamic in character. Visible pulsation seen in left 2nd intercostal space with palpable P2 with thrill present in left 2nd intercostal space. Parasternal heave and epigastric pulsation present. In mitral area loud S1 with grade II/IV mid-diastolic rumbling murmur was present along with pansystolic murmur of grade IV/IV along the left lower parasternal border. Also loud P2 with fixed split heard in pulmonary area. Respiratory system examination reveals bilateral basal crepts with rhonchi. Abdomen was soft, nontender, liver was palpable 5 cm below the right costalmargin. A provisional diagnosis of rheumatic heart disease with active carditis, congestive cardiac failure with sever mitral stenosis, tricuspid regurgitation with pulmonary arterial hypertension without infective endocarditis was made. Atria septal defect with mitral stenosis was kept as remote possibility.

Investigations revealed a haemoglobin 13.2 gm%, total leucocyte count 6,500/cumm, neutrophils 56%, lymphocyte 36%, eosinophil 1%, erythrocyte sedimentation rate of 58, random blood sugar was 107mg/dl, and where as his serum sodium is 138 meq/L and serum potassium 3.5 meq/L. LFT and KFT were normal. X-ray chest revealed plethoric lung fields and cardiomegaly with a C/T ratio 0.80 and right ventricular hypertrophy with prominent pulmonary vein and right atrial enlargement. Electrocardiogram shows rsR complex in II, III, and AVF leads suggestive of right axis deviation.

Transthorasic echocardiography (Figure 1) revealed a large ostium secundum atrial septal defect (3.9cm) with Left to right shunt, mild mitral stenosis with mitral



DOI: 10.5455/ijcbr.2017.34.16

eISSN: 2395-0471
pISSN: 2521-0394

Corresponding author: Dr. Nilesh Malgar, Department of Medicine, Shree B M Patil Medical College & Research Centre, Vijayapur, Karnataka. Email: malgarnilesh@gmail.com

valve orifices 1.6-1.7cm with AML and PML thickened, AML doming, PML fixed, right atrium and right ventricle grossly dilated, grade II tricuspid regurgitation with gradient of 41mmHg, moderate pulmonary hypertension with normal left ventricular systolic function with LVEF of 55%. The patient was treated with diuretics and advised for mitral valvulotomy and atrial septal defect closure.

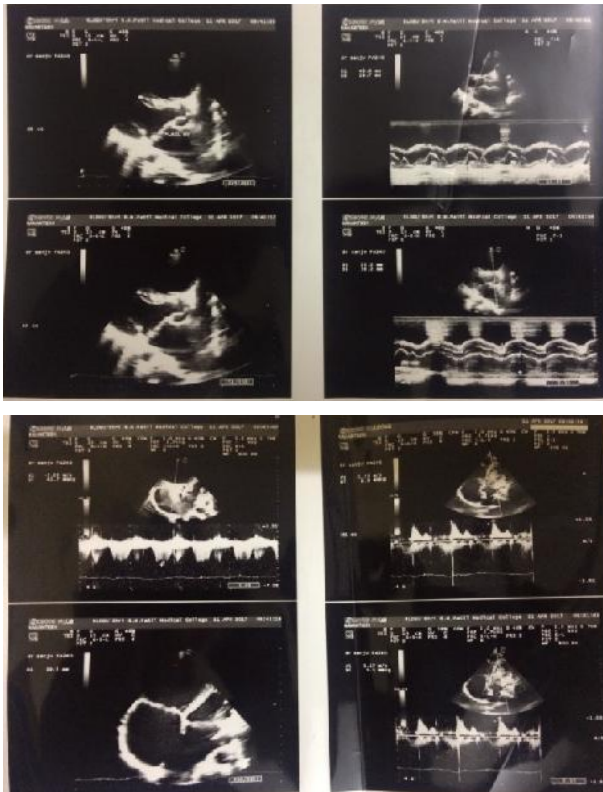


Figure 1. Transthoracic echocardiography

DISCUSSION

The incidence of Lutembacher's syndrome is very rare. In one study published in American Heart Journal in 1997, it is found that the incidence of Lutembacher's syndrome is 0.001/10,00000. The ameliorating role of the ASD in MS was evident in Lutembacher's original report of 1916 [5].

When atrial septal defect and mitral stenosis coexist, each modifies the hemodynamics and clinical expressions of the other. These modifications depend chiefly upon the degree of mitral stenosis rather than on the size of atrial septal defect because ostium secundum defects are typically non restrictive. In uncomplicated atrial septal defect, left to right shunt determined principally by the relative resistances to flow from the left atrium into the left ventricle or from the left atrium through the defect into the right ventricle. Increased right ventricular distensibility favours left to right

shunting. Mitral stenosis increases the resistance to blood flow from left atrium into left ventricle and, in so doing, augments the left to right shunt. In a non-restrictive atrial septal defect, the magnitude of augmentation varies directly with the degree of mitral obstruction [1].

Development of Eisenmenger syndrome or irreversible pulmonary vascular disease is very uncommon in the presence of large ASD and high left atrial pressure because of mitral stenosis [6].

If patient is diagnosed at late stage, pulmonary hypertension and heart failure develops and the prognosis is bad. If the patient is diagnosed earlier before the development of pulmonary hypertension and heart failure, ASD closure with mitral valve replacement bears a good prognosis and prolongs survival [6].

CONCLUSION

This case report highlights the fact that the possibility of Lutembacher's syndrome should always be kept in mind in atrial septal defect with prominent diastolic murmur and signs of pulmonary hypertension.

Conflict of interest : Nil

REFERENCES

1. Ananthkrishnan Perloff JK. The clinical recognition of congenital heart disease. 4th ed. Philadelphia: Saunders. 1994.p.323-8.
2. Budhvani N, Anis A, Nichols K, Saric M. Echocardiographical assessment of left and right heart hemodynamics in a patient with Lutembacher's syndrome. HEART AND LUNG. 2004;33(1):50-54.
3. Alexander SN, Mariano MA. Apical diastolic murmur in congenital heart disease: The rarity of Lutembacher's syndrome. American Heart Journal.1952;43(5):691-706.
4. Sadaniantz A, Luttmann C, Shulman RS, Block PC, schachne J, Thompson PD. Acquired Lutembacher's syndrome and mitral stenosis and acquired atrial septal defect after transseptal mitral valvuloplasty. CathetCardiovasc Diagn.1990 Sep; 21(1);7-9.
5. Ali SY, Rahman M, Islam M, Barman RC, Ali M Y, Islam MMSU et al. Lutembacher's syndrome a case report. Daridpur Medical college J. 2011;6:59-60.
6. Kulkarni SS, Sakaria AK, Mahajan SK, Shah KB. Lutembacher's syndrome. J Cardiovasc Dis Res. 2012;3:179-81.

How to Cite this article: Biradar SM, Mulimani MS, Nilesh Malgar. Lutembacher's syndrome - A case report . *Int. j. clin. biomed. res.* 2017;3(4):72-73