

Case Report

Rare side effect of a common drug

Anuja M. Kadagud*, Shruti Basayya Hiremath, Vijaykumar G. Warad,
Sharan Badiger, Ravi Kattimani

Department of Medicine, Shri B. M. Patil Medical College, Hospital and Research Centre, BLDE (Demand to Be), Vijayapura, Karnataka, India

Received: 11 November 2020

Accepted: 07 January 2021

***Correspondence:**

Dr. Anuja M. Kadagud,

E-mail: anuja.kadagud@gmail.com

Copyright: © the author(s), publisher and licensee Medip Academy. This is an open-access article distributed under the terms of the Creative Commons Attribution Non-Commercial License, which permits unrestricted non-commercial use, distribution, and reproduction in any medium, provided the original work is properly cited.

ABSTRACT

Metronidazole is most commonly used antimicrobial agent to treat various anaerobic bacterial and parasitic infections. Metronidazole induced side-effects are usually mild but neurotoxicity associated with it is rare. Here we report 33 year old para 1 living 1 (P1L1) post lower segment cesarean section (LSCS) discharged with metronidazole for 14 days presented to us with signs and symptoms of neurotoxicity with magnetic resonance imaging (MRI) brain findings consistent to metronidazole toxicity.

Keywords: Metronidazole induced neurotoxicity, MRI, Dentate nuclei, Corpus callosum

INTRODUCTION

Metronidazole, antimicrobial and antiparasitic agent used for treating various infections is fairly safe but can rarely cause serious neurological adverse effects like peripheral neuropathy, cerebellar dysfunction, encephalopathy and altered mental status.¹

Metronidazole induced neurotoxicity (MIN) does not seem to be dose or duration related and prognosis being excellent with Metronidazole cessation.¹⁻³

CASE REPORT

A 33 years old para 1 living 1 (P1L1) post lower segment caesarean section (LSCS) on day 14 presented to our hospital with history of slurring of speech, vertigo, ataxia. There was no history of loss of consciousness, fever, seizures, headache with her pregnancy and LSCS being uneventful.

On examination patient was hemodynamically stable with Glasgow coma scale (GCS) of 11/12. Her neurological examination revealed left horizontal nystagmus, finger

nose test being positive, rest of the systemic examination were normal.

On the day of admission magnetic resonance imaging (MRI) brain was done which showed T2W hyperintense lesions in corpus callosum with rest of the routine investigations within normal limits. Patient was empirically started on antibiotics considering meningitis and puerperal sepsis. Later her Cerebro-spinal fluid (CSF) analysis revealed cell count of 8 cells/cumm, glucose 95 mg/dl, protein 26 mg/dl, chloride 131 mg/dl.

The very third day patient worsened with GCS of 9/12, so repeat MRI Brain plus magnetic resonance angiogram (MRA) was done which revealed a new T2W hyperintense lesion in bilateral dentate nucleus with normal MRA.

Her vitamin B12, Thyroid function test, anti nuclear antibodies (ANA), compliment (C3, C4) were done which were also within normal limits. Since there was no history of poison consumption, considering drug toxicity, her discharge card were reviewed and was found that she was discharged with tablet metronidazole 400 mg once daily

for 14 days, and our patient had taken a total dose of 4800 mg.

Patient was asked to discontinue Metronidazole and as she started to improve, on day 7 repeat MRI brain was done which showed complete resolution of all previous lesions.

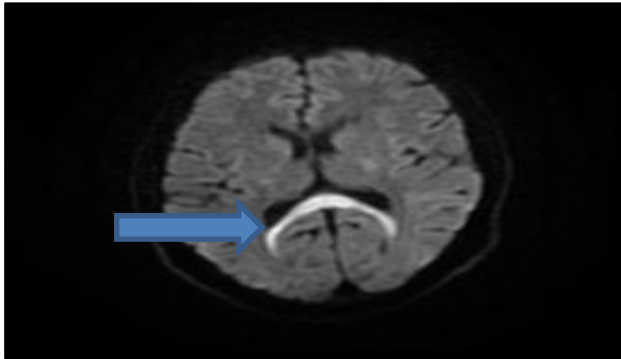


Figure 1: Axial T2W MRI of brain shows symmetrical areas of hyperintensity involving splenium of corpus callosum (arrow).

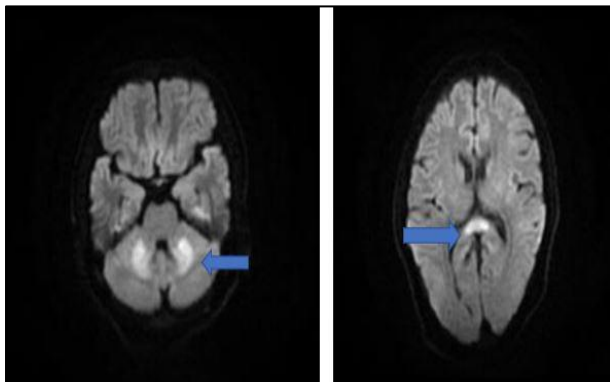


Figure 2: Axial T2W MRI of brain shows new symmetric areas of hyperintensity involving dentate nuclei (arrow) and resolving lesion of splenium of corpus callosum (arrow head).

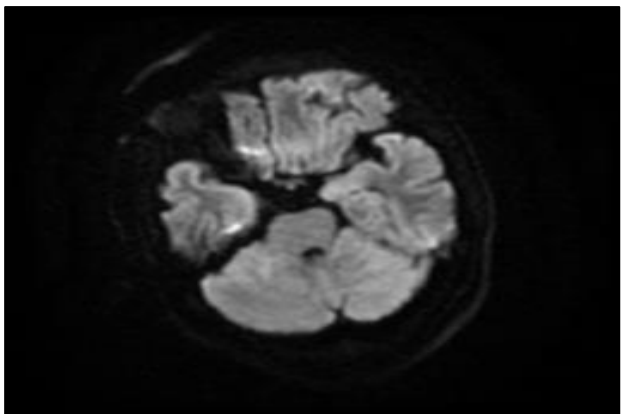


Figure 3: MRI brain showing complete resolution of all previous lesions.

DISCUSSION

The exact incidence of MIN is unknown. Very few case reports and small case series of MIN have been reported with most of the cases from United States and Korea and few cases worldwide including India.^{3,4}

Mechanism of MIN remains unclear but various theories suggest binding of metronidazole to neural RNA to inhibit protein synthesis and modulation of inhibitory neurotransmitters within the cerebellum and reversible mitochondrial dysfunction.^{1,2} It also causes vasogenic edema within the deep nuclei and white matter tracts with cytotoxic edema of corpus callosum.^{3,4}

Duration of MIN after initiation of treatment ranges from 1-90 days and dose of 0.25-109.5 g (median of 15 days and 93.4 g dose).⁵ However dosage and duration vary widely.

Imaging findings are of utmost importance for diagnosis and follow-up of these cases.^{3,4,6} The characteristic MRI brain finding of MIN are bilateral symmetrical hyperintense lesions of dentate nucleus on T2W along with splenium of corpus callosum, midbrain, dorsal pons and dorsal medulla.^{2,3} The differential diagnosis of hyperintense T2W dentate nucleus include methyl bromide intoxication, maple syrup urine disease, enteroviral encephalomyelitis, wernicke's encephalopathy.^{2,5,6,7} Differential diagnosis for involvement of splenium of corpus callosum include Marchiafava Bignani disease, encephalitis (demyelinating and infective), and anti-epileptic drugs.^{2,5}

In our case diagnosis of MIN was made clinically and supported with history of Metronidazole intake and radiological findings which were reversible once the drug was withdrawn.

CONCLUSION

MIN, though rare can present with cerebellar dysfunction, encephalopathy and seizures. There is no association between dose and duration of Metronidazole intake and toxicity. Since it is widely used our clinical suspicion should be high and history of drug intake should be sought as toxicity is completely reversible on cessation of the drug. MRI is an important tool for diagnosis of MIN.

Funding: No funding sources

Conflict of interest: None declared

Ethical approval: Not required

REFERENCES

1. Kuriyama A, Jackson JL, Doi A, Kamiya T. Metronidazole-induced central nervous system toxicity: a systematic review. *Clinical neuropharmacol.* 2011;34(6):241-7.

2. Kalia V, Vibhuti KS. Case report: MRI of the brain in metronidazole toxicity. *The Indian journal of radiology & imaging.* 2010;20(3):195.
3. Patel L, Batchala P, Almardawi R, Morales R, Raghavan P. Acute metronidazole-induced neurotoxicity: an update on MRI findings. *Clin Radiol.* 2020;75(3):202-8.
4. Li L, Tang X, Li W, Liang S, Zhu Q, Wu M. A case of methylprednisolone treatment for metronidazole-induced encephalopathy. *BMC neurol.* 2019;19(1):49.
5. Roy U, Panwar A, Pandit A, Das SK, Joshi B. Clinical and neuroradiological spectrum of metronidazole induced encephalopathy: our experience and the review of literature. *Journal of clinical and diagnostic research: JCDR.* 2016;10(6):OE01.
6. Chandak S, Agarwal A, Shukla A, Joon P. A case report of metronidazole induced neurotoxicity in liver abscess patient and the usefulness of MRI for its diagnosis. *Journal of clinical and diagnostic research: JCDR.* 2016;10(1):TD06.
7. Agarwal A, Kanekar S, Sabat S, Thamburaj K. Metronidazole-induced cerebellar toxicity. *Neurology international.* 2016;8(1).

Cite this article as: Kadagud AM, Hiremath SB, Warad VG, Badiger S, Kattimani R. Rare side effect of a common drug. *Int J Adv Med* 2021;8:303-5.