



E-ISSN: 2395-1958  
P-ISSN: 2706-6630  
IJOS 2021; 7(1): 888-891  
© 2021 IJOS  
[www.orthopaper.com](http://www.orthopaper.com)  
Received: 01-11-2020  
Accepted: 03-12-2020

**Ezhil Vikrama Vell G**  
Junior Resident, Department of  
Orthopedics, Shri B M Patil  
Medical College, Hospital &  
Research Centre Vijayapura  
Karnataka India

**Anil Bulagond**  
Assistant Professor, Post  
Salotagi Tq Indi District  
Bijapur, Karnataka India

**Dayanand BB**  
Professor & Head, Department  
of Orthopedics, Shri B M Patil  
Medical College, Hospital &  
Research Centre Vijayapura  
Karnataka India

## Functional outcome of clavicle hook plate for fractures of lateral end of clavicle & acromio-clavicular joint disruption

Ezhil Vikrama Vell G, Anil Bulagond and Dayanand BB

DOI: <https://doi.org/10.22271/ortho.2021.v7.i1n.2583>

### Abstract

**Background:** The acromioclavicular joint (AC joint) provides a 'keystone' link between the clavicle and the scapula.

**Objectives:** To evaluate the functional outcome of clavicle hook plate for fractures of lateral end of clavicle & acromioclavicular joint disruption.

**Method:** This study is a descriptive analysis, approved by the Institution Review Board and the Ethic Committee for the evaluation of the results of hook plate fixation for acromioclavicular joint disruption (Rockwood and Young III-VI) and unstable fractures of the lateral end of clavicle (Neer type II-III). Duration of study from 1<sup>st</sup> November 2018 to 31<sup>st</sup> May 2020.

**Results:** 35 patients were followed of which 28 were males and 7 were females. Left shoulder was involved in 26 patients and right shoulder was involved in 9 patients. There were 25 patients with lateral end clavicle fractures and 10 patients with AC joint injury. Two patients had Diabetes mellitus and 5 patients had hypertension. One patient had both DM and hypertension. Two patients developed shoulder stiffness and two patients developed impingement during the course of follow up. All the patients had a unified surgical approach and operative procedure. The postoperative protocol regarding medication and physiotherapy was also unified (as mentioned earlier). At the last follow up, 27 patients had an excellent outcome according to Quick DASH score. 6 had a good outcome and 2 had a poor outcome. The score ranged from 2.3 to 25 (avg was 7.26)

**Conclusion:** It was concluded Hook plate is a good option for treatment of AC joint disruption and unstable lateral end clavicle fractures, limited use of instrumentation, short duration of the procedure, stability to the AC joint attained without the need for ligament repair or reconstruction and short learning curve.

**Keywords:** clavicle hook plate, fractures, lateral end of clavicle, acromio-clavicular joint

### Introduction

Fractures of lateral end of clavicle account for 15% of all clavicle fractures<sup>[1]</sup> whereas 9% of shoulder girdle injuries involve acromioclavicular joint damage<sup>[2]</sup>. These fractures are associated with disruption of the coracoclavicular ligaments and are unstable due to four displacing forces that retard union. The nonunion rate is approximately 30%, causing pain and impaired function of shoulder girdle and upper limb and hence surgery is recommended for unstable distal clavicular fractures<sup>[3]</sup>.

A variety of surgical treatment options have been developed with varying success over the years. Currently clavicle hook plate is accepted as a surgical option for these injuries. This study is 2 pronged- analyzes the results of clavicle hook plate compared with the literature and also evaluates the need for repair of soft tissue structures around the acromio-clavicular joint. We will be analyzing the results based on clinical outcomes and radiological assessment so as to ascertain the efficacy of this procedure. Thus the present study to evaluate the functional outcome of clavicle hook plate for fractures of lateral end of clavicle & acromioclavicular joint disruption

**Corresponding Author:**  
**Anil Bulagond**  
Assistant Professor, Post  
Salotagi Tq Indi District  
Bijapur, Karnataka India

**Methods**

This study is a descriptive analysis, approved by the Institution Review Board and the Ethic Committee for the evaluation of the results of hook plate fixation for acromioclavicular joint disruption (Rockwood and Young III-VI) and unstable fractures of the lateral end of clavicle (Neer type II-III). Duration of study from 1<sup>st</sup> November 2018 to 31<sup>st</sup> May 2020.

**Inclusion criteria**

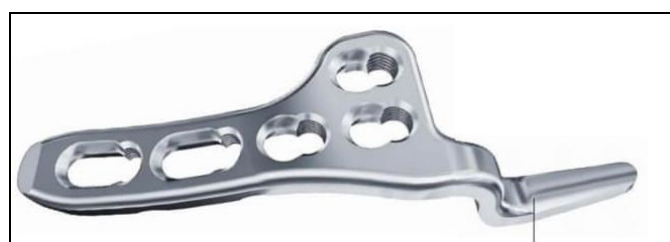1. All acromioclavicular joint disruptions of Rockwood type III-VI either acute or chronic symptomatic.
2. All fractures of the lateral end of clavicle of Neer type II and III (Craig II and VI) either acute or with painful nonunion
3. All cases were operated in our hospital.
4. Minimum of 6 months of post-operative follow up
5. All surgeries done at our centre

**Method**

We reviewed all patients who fit our criteria and had undergone surgery with our local customized hook plate and in our hospital. All operations were done by surgeons of our hospital

1. All patients were either from the Out-patient department or Emergency
2. Preoperative X-ray of shoulder in AP and Axillary view were taken.
3. The injuries were classified as per the inclusion criteria.
4. All surgeries were performed in a specified manner
5. A locally available hook plate was used
6. Specified postoperative protocol was followed for all patients.
7. Outcome was measured based on Quick DASH questionnaire at intervals of 6, 12, 24 weeks by one single examiner.
8. Radiological assessment was done at 6, 12, 24 week intervals.
9. Wound sepsis, time taken to bony union and reaching pre-fall injury status were also noted

The hook plates we used were locally available - a 4 -7 hole, 3.5mm which was available for right and left side for optimal sizing and screw positioning for each individual.



**Fig 1:** Hook Plate

The plate had a hook with posterior offset so as to avoid entry into the AC joint capsule and was hooked beneath the acromion and posterior to the AC joint capsule. The cost of the plate with the screws came to between Rs 3000 to Rs 4000.

All procedures were done with the patient in a supine position with a bolster place beneath scapula An incision along the superior margin of the lateral clavicle running posterior to the acromion joint was used in all cases Negligible soft tissue dissection and handling was practiced. The only soft tissue

dissection was the cutting of the deltotrachezial fascia while the AC joint was left UN dissected. A needle was used to identify the AC joint and also as a guide to the entry point of hook insertion. AC depth was measured with a depth gauge and the appropriate hook plate was used.

Ligament repair was not done in any of the cases and deltoid and trapezium fascia was resutured back at the time of closure. A tube drain was placed after skin suturing.

The surgical procedure described above took about 45 minutes for completion. Pendulum exercises were started on the 2<sup>nd</sup> post operative date and passive mobilization started as patient tolerated. Within 3 weeks active exercises were started and full range of movement was started after 3 weeks.

We have used the Quick DASH score as they reflect the subjective and objective perspective of the shoulder function. The quick DASH scores range from 0-100 where zero is the best score and indicates excellent results. The forms were filled at each visit and at which time they were evaluated for signs of implant failure, irritation, impingement or infection.

X-rays were taken preoperative, immediate postoperative and subsequently at 6 week and 6 months. Placement of plate, reduction of AC joint or fracture, implant loosening, osteolysis at the tip of the hook, cut out of the hook and union were assessed at serial intervals.

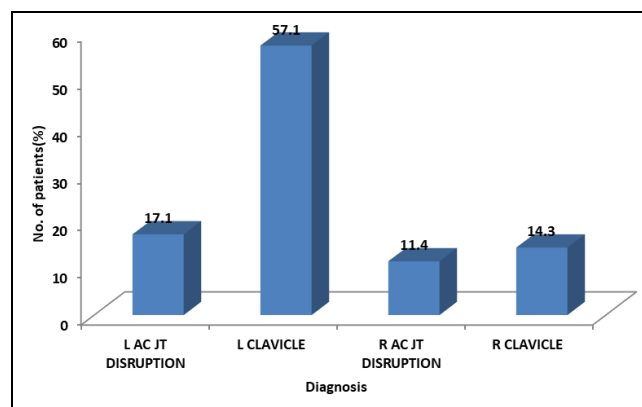
Signs to elicit subacromial impingement were done at each visit and these included the Neer impingement sign, Hawkins-Kennedy sign and Jobe supination test.

Zanca view was taken to assess the coracoclavicular reduction as compared to the opposite side.

**Result**

35 patients were followed prospectively from November 2018 to May 2020 of which 28 were males and 7 were females. Left shoulder was involved in 26 patients and right shoulder was involved in 9 patients. There were 25 patients with lateral end clavicle fractures and 10 patients with AC joint injury Mode of injury was road traffic accident in 30 patients and fall from height in 5 patients.

There were no associated injuries in patients under our study.

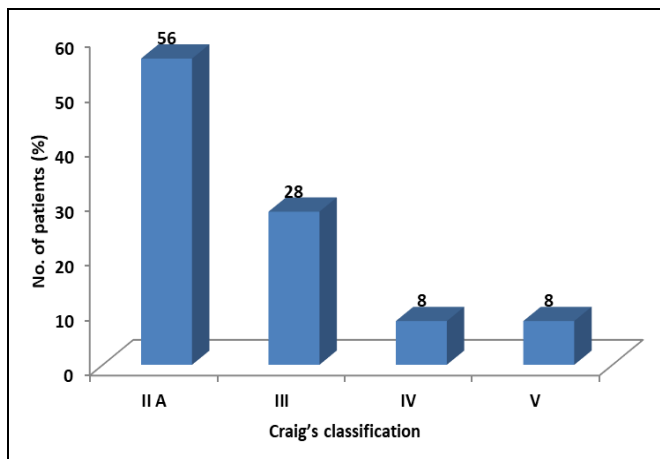


**Fig 2:** Distribution of lateral end clavicle fractures and AC joint injury

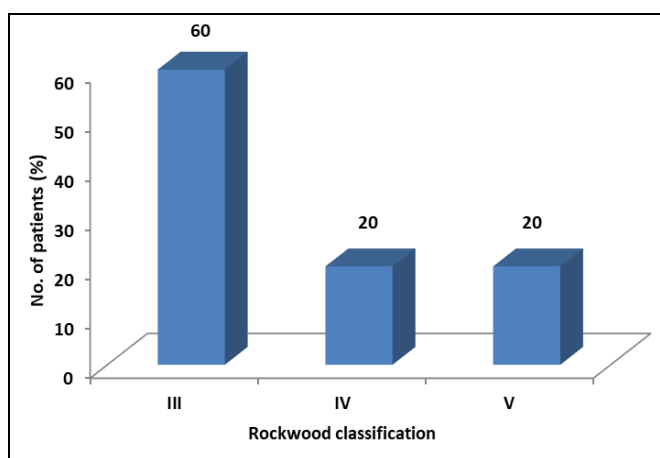
**Table 1:** Distribution of patients according to Age (Years)

Age (Years)	No. of patients	Percentage
< 20	4	11.4
20 - 29	7	20.0
30 - 39	12	34.3
40 - 49	6	17.1
50 - 59	4	11.4
60+	2	5.7
Total	35	100.0

Two patients had Diabetes mellitus and 5 patients had hypertension. One patient had both DM and hypertension.



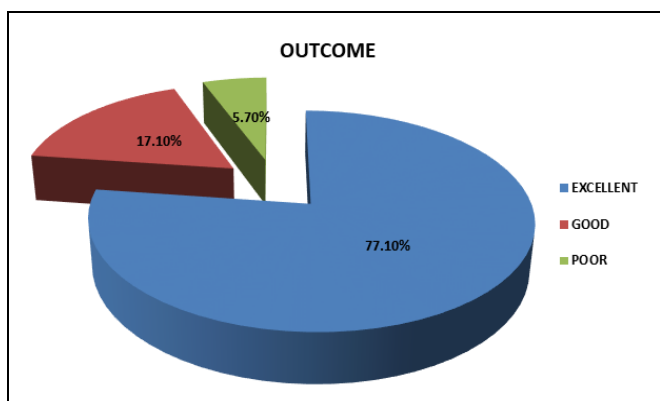
**Fig 3:** Distribution of patients according Craig's classification for Clavicle fractures



**Fig 4:** Distribution of patients according Rockwood classification for AC Joint injury

Two patients had superficial wound infection which subsided with antibiotics. Two patients developed shoulder stiffness and two patients developed impingement during the course of follow up.

All the patients had a unified surgical approach and operative procedure. The postoperative protocol regarding medication and physiotherapy was also unified (as mentioned earlier). At the last follow up, 27 patients had an excellent outcome according to QuickDASH score. 6 had a good outcome and 2 had a poor outcome. The score ranged from 2.3 to 25 (avg was 7.26)



**Fig 5:** Outcome according to Quick DASH score

**Discussion**

Treatment for unstable lateral end clavicle fractures and AC joint disruptions have been shown historically to be an area of much debate in respect to the indications, choice of treatment procedure and choice of implant. In the past a variety of implants have been used such as Kirschner wires (65; 44; 52), tension band wires around coracoid-clavicle, transfixation of clavicle to coracoid with screw [4], repair of CC ligament with augmentations (67; 47), endobuttons [5] and the hook plate(3; 19; 69; 34; 53). Some advocate the excision of the lateral end of clavicle in chronic painful dislocations (30; 70). Debate as to the use of synthetic (71) or autologous fascia slings and tendons for repair of CC ligament (23; 24; 72; 73) and its fixation techniques are yet to be resolved. Surgical approaches may be luggage strap, along the clavicle, mini stab incisions or arthroscopic reconstruction of CC ligament (36; 37) The Weaver Dunn procedure has a weak strength and can result in incomplete reduction or recurrence with a high failure rate of approximately 29%. [6]

Kirschner wire fixation has a higher rate of migration (while the Bosworth screw needed a wide surgical exposure but provided a rigid fixation leading to loss of rotation and screw cut out.

In young patients, there is a need to restore anatomical reduction because of high rates of non-unions and shoulder pain and that the ligaments will not heal without surgery.

The use of hook plate in the treatment of AC joint disruptions and lateral end of clavicle fractures is shown to be a good and acceptable treatment option.

AC joint dislocation results in an inferior sag of the scapula and stability at this joint must be achieved either by repair of the ligaments and/or stabilizing with a plate or other fixation devices. Implants like endobuttons™ (Smith & Nephew) need not be removed and this avoids an additional surgery to the patient [7]. In regards to the use of a hook plate, there are debatable statements regarding retaining the implant for a longer duration as against removal when the patient is symptomatic. Most of the patients in this study had an excellent or good outcome which is similar to the findings of various other studies [8]. There is literature questioning the need for either simultaneous reconstruction or repair of the ligaments along with hook plate method of fixation, further suggesting implant removal after radiological or clinical indication and /or reconstruction after plate removal depending on the instability [9].

In this study, 27 patients had an excellent outcome as assessed by Quick DASH scores. 6 patients had good outcome and 2 had poor outcome. These results are comparable to other studies using a hook plate [10].

We have noted the following complications: impingement occurred in 2, frozen shoulder in 2. These results are comparable with other studies [14] though the exact reason of shoulder stiffness is unknown, it appears to be a post-traumatic frozen shoulder.

The origin of impingement pain may be as a result of decrease in subacromial space or the irritation of the subacromial bursa.

The time taken to return to pre-injury status was at a mean of 51 weeks, this is partly attributed to the lack of personal initiative from the patients, lack of timely follow-up and inability to attend physiotherapy session due to distance and financial burdens.

**Conclusion**

It was concluded Hook plate is a good option for treatment of

AC joint disruption and unstable lateral end clavicle fractures, limited use of instrumentation, short duration of the procedure, and stability to the AC joint attained without the need for ligament repair or reconstruction and short learning curve.

The hook plate is a relatively less analyzed treatment option for displaced lateral endclavicle fractures and acromioclavicular joint disruptions. These injuries are rare and diagnosing and treating them proves to be a challenge as there is an array of treatment options, all of which were associated with their own set of problems. Secondly, the procedure is simple enough to be practiced by all orthopedicians with good results.

### Acknowledgements

I would like to express my profound gratitude to all my patients, for their cooperation and faith, without them it would be impossible to complete my study.

### References

1. Renger RJ, Roukema GR, Reurings JC, Raams PM, Font J, Verleisdonk EJMM. The Clavicle Hook Plate for Neer Type II Lateral Clavicle Fractures. *Journal of Orthopaedic Trauma* [Internet] 2009; 23(8).
2. MacDonald PB, Lapointe P. Acromioclavicular and sternoclavicular joint injuries. *Orthopedic Clinics of North America* 2008;39(4):535-545.
3. Meda PVK, Machani B, Sinopidis C, Braithwaite I, Brownson P, Frostick SP. Clavicular hook plate for lateral end fractures:- A prospective study. *Injury* 2006;37(3):277-283.
4. Tauber M, Gordon K, Koller H, Fox M, Resch H. Semitendinosus Tendon Graft Versus a Modified Weaver-Dunn Procedure for Acromioclavicular Joint Reconstruction in Chronic Cases: A Prospective Comparative Study. *Am. J Sports Med* 2009;37(1):181-190.
5. Gonzalez R, Damacen H, Nyland J, Caborn D. Acromioclavicular joint reconstruction using peroneus brevis tendon allograft. *Arthroscopy* 2007;23(7):788.e1-4.
6. De Baets T, Truijen J, Driesen R, Pittevels T. The treatment of acromioclavicular joint dislocation Tossy grade III with a clavicle hook plate. *Acta Orthop Belg* 2004;70(6):515-519.
7. Gummesson C, Atroshi I, Ekdahl C. The disabilities of the arm, shoulder and hand (DASH) outcome questionnaire: longitudinal construct validity and measuring self-rated health change after surgery. *BMC Musculoskeletal Disorders* 2003;4(1):11.
8. Katolik LI, Romeo AA, Cole BJ, Verma NN, Hayden JK, Bach BR. Normalization of the Constant score. *Journal of Shoulder and Elbow Surgery* 14(3), 279-285.
9. Clarke H, McCann P. Acromioclavicular joint injuries. *Orthop Clin North Am* 2000;31(2):177-87.
10. McClelland D, Krishnamurthy S, Dodenhoff R. Constant score assessment of shoulder function - is strength measurement useful? *J Bone Joint Surg Br* 2002;84-B(SUPP\_II):197-d.