

Dermoscopy in the diagnosis and assessment of treatment response in granulomatous cheilitis

Keshavmurthy A Adya , Arun Inamadar 

Dermatology Venereology and Leprosy, Shri BM Patil Medical College, Vijayapur, Karnataka, India

Correspondence to

Dr Arun Inamadar;
aruninamadar@gmail.com

Accepted 15 June 2022

DESCRIPTION

Granulomatous cheilitis is characterised by a chronic inflammatory swelling of the lips. Yellow-orange areas are typical dermoscopic features in granulomatous disorders, and their disappearance indicates a good treatment response. Here, we describe the usefulness of dermoscopy in assessment of the treatment response and determining the treatment end point at a stage earlier than that by clinical assessment alone in a case of granulomatous cheilitis.

A woman in her 30s presented with swollen upper lip for the past few months with mild discomfort (**figure 1A**). Polarised dermoscopy using handscope (FotoFinder systems GmbH, Bavaria, Germany) revealed a diffuse yellow-orange structureless background, white reticular lines and dotted vessels (**figure 1B**). Based on the clinical and dermoscopic features, granulomatous cheilitis was diagnosed and confirmed by histopathology. The patient was advised oral clofazimine (100 mg/day)

and intralesional triamcinolone injection (10 mg/mL once every 3 weeks). Serial clinical and dermoscopic follow-up (every 3 weeks) showed a progressive reduction in swelling, and change in background colour from the pretreatment yellow-orange to yellow-white at week 3 and to pink-white at week 6 (**figure 1C–F**). The latter was considered a treatment endpoint and her therapy was discontinued. Review of the patient at week 9 showed further reduction in swelling (**figure 1G**) and dermoscopy showed complete disappearance of yellow-orange and white areas (**figure 1H**). A biopsy for confirmation of diagnosis revealed non-caseating dermal granulomas comprising epithelioid cells, lymphocytes and giant cells (**figure 2**).

Granulomatous cheilitis is a component of orofacial granulomatosis—a chronic inflammatory disorder of imprecise aetiology characterised by non-caseating granulomatous inflammation of oral and maxillofacial soft tissues. It includes two conditions—Merkelsson-Rosenthal syndrome (chronic lip or facial swelling, facial palsy and fissured tongue) and granulomatous cheilitis of Miescher (swelling confined to the lips). The latter affects young adults involving one or both the lips. Various treatment modalities include systemic or intralesional steroids, clofazimine, minocycline, metronidazole, dapsone, thalidomide and surgery in recalcitrant cases or cases with severe deformation.¹

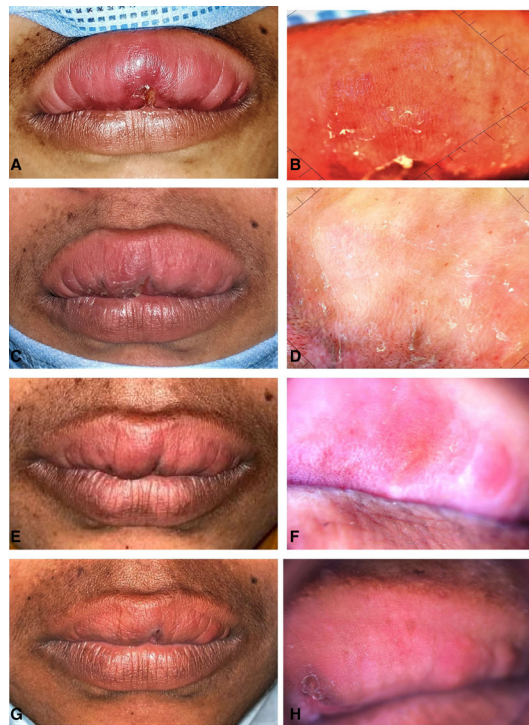

Figure 1 Pretreatment (A,B) and serial post-treatment (C–H) clinical and dermoscopic features of granulomatous cheilitis. Note the diffuse yellow-orange background on dermoscopy before treatment (B) and its progressive resolution (D,F,H) corresponding to the progressive reduction in the swelling (C,E,G). (Dermoscopy: polarised, $\times 20$).

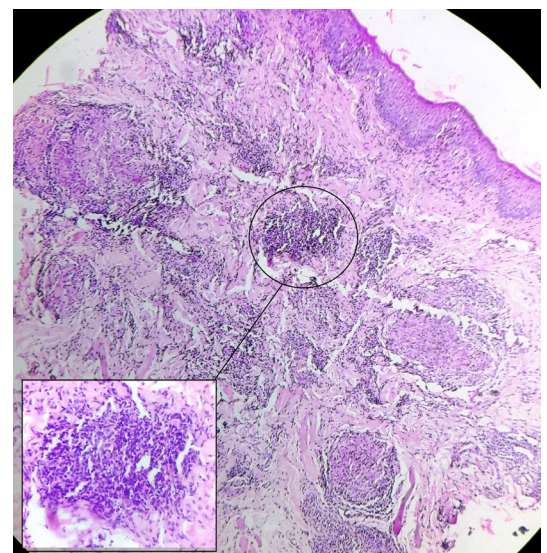
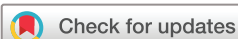

Figure 2 Photomicrograph showing multiple non-caseating granulomas in the dermis. High-power view (inset) showing epithelioid cells, lymphocytes and occasional giant cells. (H&E $\times 10$, inset $\times 40$).



© BMJ Publishing Group Limited 2022. No commercial re-use. See rights and permissions. Published by BMJ.

To cite: Adya KA, Inamadar A. *BMJ Case Rep* 2022;**15**:e251200. doi:10.1136/bcr-2022-251200

Images in...

Dermoscopy of various granulomatous diseases is characterised by a common feature of diffuse or localised yellow-orange areas (corresponding to the diffuse or focal granulomatous infiltration, respectively), commonly with telangiectatic vessels.² Similar features were observed in our case, which, in conjunction with the clinical features, prompted a diagnosis of granulomatous cheilitis that was confirmed histologically. Disappearance of the yellow-orange areas is a dermoscopic indicator of disease resolution and/or a good treatment response, which was observed on serial dermoscopic follow-up in our case.³ At week 6, although swelling was still evident clinically, dermoscopy showed complete disappearance of the yellow-orange background which prompted the treatment end point. Follow-up at week 9 showed further reduction in swelling and normal lip

architecture on dermoscopy despite treatment cessation at the previous visit (week 6).

This report illustrates that dermoscopy not only assists in the diagnosis of granulomatous cheilitis and assessing treatment response, it also appears to indicate the treatment end point earlier than that by clinical assessment alone.

Contributors KAA: Data collection, data analysis, manuscript preparation, manuscript review. ACI: Data analysis, manuscript review.

Funding The authors have not declared a specific grant for this research from any funding agency in the public, commercial or not-for-profit sectors.

Competing interests None declared.

Patient consent for publication Consent obtained directly from patient(s).

Provenance and peer review Not commissioned; externally peer reviewed.

Case reports provide a valuable learning resource for the scientific community and can indicate areas of interest for future research. They should not be used in isolation to guide treatment choices or public health policy.

Learning points

- ▶ Granulomatous cheilitis is characterised by a chronic granulomatous inflammatory swelling of lips.
- ▶ Yellow-orange areas are the essential dermoscopic features in granulomatous disorders and their disappearance indicates a good treatment response.
- ▶ Dermoscopy not only asserts the clinical diagnosis of granulomatous cheilitis, but it also helps in assessing treatment response. Furthermore, it also appears to indicate the treatment end point earlier than that by clinical assessment alone.

ORCID iDs

Keshavmurthy A Adya <http://orcid.org/0000-0003-4411-1979>
Arun Inamadar <http://orcid.org/0000-0002-8877-3723>

REFERENCES

- 1 Gupta A, Singh H. Granulomatous cheilitis: successful treatment of two recalcitrant cases with combination drug therapy. *Case Rep Dermatol Med* 2014;2014:509262.
- 2 Chauhan P, Adya KA. Dermoscopy of cutaneous granulomatous disorders. *Indian Dermatol Online J* 2021;12:34–44.
- 3 Errichetti E. Dermoscopy in monitoring and predicting therapeutic response in general dermatology (non-tumoral dermatoses): an up-to-date overview. *Dermatol Ther* 2020;10:1199–214.

Copyright 2022 BMJ Publishing Group. All rights reserved. For permission to reuse any of this content visit <https://www.bmj.com/company/products-services/rights-and-licensing/permissions/>
BMJ Case Report Fellows may re-use this article for personal use and teaching without any further permission.

Become a Fellow of BMJ Case Reports today and you can:

- ▶ Submit as many cases as you like
- ▶ Enjoy fast sympathetic peer review and rapid publication of accepted articles
- ▶ Access all the published articles
- ▶ Re-use any of the published material for personal use and teaching without further permission

Customer Service

If you have any further queries about your subscription, please contact our customer services team on +44 (0) 207111 1105 or via email at support@bmj.com.

Visit casereports.bmj.com for more articles like this and to become a Fellow