

Difficult Airway Management- A Challenge to Anaesthesiologists

LK SHIVANAND¹, SD PRATIBHA², SAI PRASAD³, DIVYA SHANKAR⁴, VIDYA PATIL⁵

ABSTRACT

Anticipated and unanticipated difficult airway remains an everlasting challenge for anesthesiologist. Most airway problems can be solved with enough resources available but clinical judgment borne of experience, and expertise is crucial in implementing the skills in any difficult airway scenario. Detailed patient history, best utilisation patient protocols, with good clinical assessment may reduce the difficult airway complications. The present series reports six patients with anticipated difficult airway-burn contracture, fractured mandible with restricted mouth opening; meningo myelocoele (in a neonate, and there was difficulty in positioning for intubation), anterior mediastinal mass (with difficulty in maintenance of anesthesia), cervical spine injury and one patient with left mandible fracture with history of road traffic accident. Different methods were successfully adopted for managing all of these difficult airway cases. Hence planning, preparation, and execution is very important in successful management of difficult airway.

Keywords: Burn contracture, Cervical spine injury, Meningo myelocoele neonate

INTRODUCTION

Management of a difficult airway is one of the most important task for anaesthesiologists which remains most relevant and challenging clinical situation encountered by anaesthesia practitioners as major adverse event can occur if the airway is not secured in a timely situation. Inability to visualise the vocal cords during direct laryngoscopy prevents successful tracheal intubation. Many newer techniques and devices are now available that overcome the problems encountered in intubation of a difficult airway using conventional direct laryngoscopy [1].

For an effective management of anticipated difficult airway one should always have airway plan and airway management strategy which are two key factors in management of difficult airway. Unanticipated difficult airway in contrast to the anticipated difficult airway is more challenging to the anesthesiologist after induction of the general anaesthesia. Encountering an unanticipated difficult airway can be very stressful so it is necessary to be familiar with management algorithm for the unanticipated difficult airway and follow the strategy in such a situation [2].

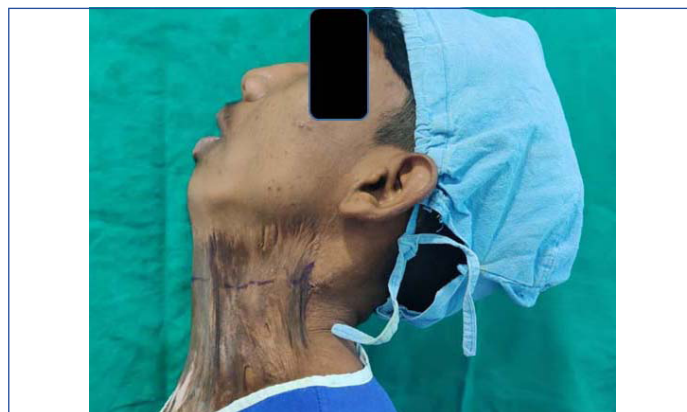Series of cases of difficult airway scenarios managed successfully with different techniques and equipment are presented in this case series.

CASE SERIES

Case 1

A 19-year-old male patient, with history of electrical burns eight years back, was posted for contracture release surgery. His mouth opening was restricted and the Mallampatti grade was II. He had a gross restricted neck extension because of burn contracture, reduced temporomandibular joint movement, and decreased mentohyoid distance [Table/Fig-1].

A thorough preanaesthetic examination was done and airway visualized. Airway management was planned with BPL C-Mactintosh of size 3 video laryngoscope. Video laryngoscope was checked before induction. The patient was premeditated with midazolam 0.08 mg/kg, ondansetron 0.15 mg/kg, glycopyrrolate 0.008 mg/kg. Analgesia fentanyl 2 mcg/kg was given. Anesthesia was induced with propofol 2 mg/kg after confirming adequate ventilation by proper positioning, neuromuscular blockade was achieved with rocuronium 0.6 mg/kg which is intermediate acting



[Table/Fig-1]: Shows extensive burns contracture of patient lateral view.

non depolarizing muscle relaxant usually used to facilitate tracheal intubation. Scoline was avoided due to history of burns and instead rocuronium was used which can be safely administered for tracheal intubation. A 7 mm Endotracheal Tube (ETT), accompanying the video laryngoscope, was inserted and advanced into the trachea. The video laryngoscope was removed once the position of the ETT was clinically confirmed by the presence of bilateral air entry and capnography. Maintenance of anesthesia was done with oxygen, nitrous oxide, isoflurane and vecuronium as a muscle relaxant. Blood loss was minimal. The surgeon had performed plastering with a cast, hence extubation of the trachea was challenging with intact airway reflexes after adequate reversal. Fiber optic bronchoscopy-assisted tracheal intubation would have been the best alternative modality to rescue the airway if intubation was not achieved with video laryngoscopy.

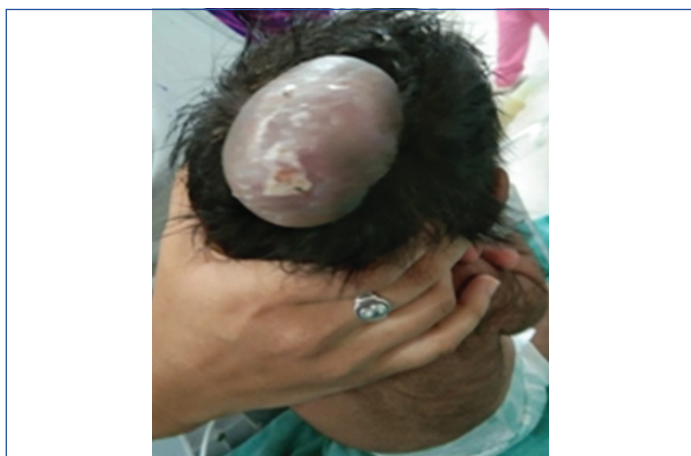Case 2

A 50-year-old male, with history of assault, followed by head injury and loss of consciousness presented with undisplaced fracture of parasymphysis of right side of mandible. He was posted for open reduction and mini plate fixation. The patient had no co-morbidities. On thorough examination of the airway, it was found that cervical spine movement was restricted and was painful. Mouth opening was 1.5 fingers and the Mallampatti grade was IV, overcrowding of teeth was present. After thorough physical examination of the patient and following normal routine investigations, the patient was posted for surgery.

Patient was kept nil orally for six hours before surgery and shifted to the operating room. patient was put in a semi-propped up position and all standard monitors were connected. Nasal decongestant drops were instituted to reduce nasal bleeding, along with a nasal packing of xylocaine 2%. Bilateral superior laryngeal nerve block was given with 2 mL of 2% lignocaine at the greater cornu of the hyoid bone. Transtracheal injection of 2% lignocaine was instilled. Two puffs of 10% lignocaine was sprayed onto the posterior pharyngeal wall before Fiberoptic Bronchoscope (FOB) was inserted. The FOB was checked and a 7.0 mm Internal Diameter (ID) cuffed ETT was passed over it. The fiberscope was inserted into the right nostril and after passing through the upper airway and the vocal cords, slowly entered through the trachea, and the carina was envisioned. The ETT was then passed over the bronchoscope into the trachea. The passage was confirmed with fiberscope by viewing the tube tip inside the trachea. Anesthesia was then induced with propofol 2 mg/kg and atracurium 0.5 mg/kg and maintained with fentanyl and sevoflurane. The patient vitals were monitored throughout the procedure. The procedure was uneventful. The patient was extubated after adequate reversal.

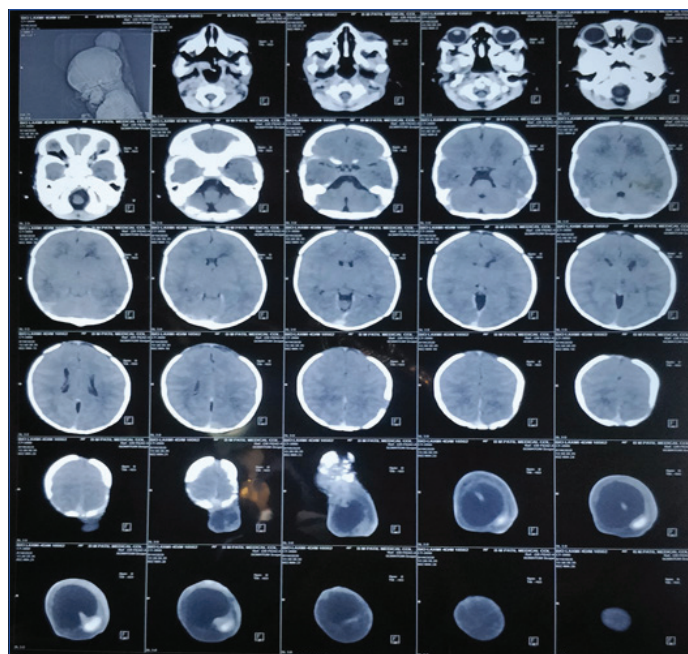
Case 3

A 10-day-old male neonate visited with a giant occipital meningoencephalocele, and then was scheduled for surgical excision. The neonate was delivered via a normal vaginal delivery in a government hospital. It was a complete term delivery, and the birth weight was 2.7 kg. The baby cried immediately after birth. Cardiovascular and respiratory system examination was normal. The swelling was present since birth and had gradually increased to the size of 6×4cm, with head circumference of 39 cm. It was diagnosed as a meningomyelocele. The Magnetic Resonance Imaging (MRI) brain showed a defect of 3.2 cm size in the occipital region through which parenchymal tissue was herniating [Table/Fig-2a,b].



[Table/Fig-2a]: Shows a giant meningomyelocele.

The neonate was kept nil orally for four hours on the day of surgery and ringer's lactate was started at the rate of 14 mL/hour. Intubation was planned in supine position. As the meningoencephalocele was bulky, the head was positioned so that the meningoencephalocele does not rupture. A blanket was placed over the body to avoid hypothermia. Baseline parameters were recorded. Electrocardiography (ECG), Non Invasive Blood Pressure (NIBP), pulse oximeter, and End tidal carbon dioxide (EtCO₂) were monitored. Premedication was administered with Inj. glycopyrrolate 0.01 mg i.v., Inj. fentanyl 7 µg. Induction was done with Inj. propofol 6 mg and sevoflurane, and Inj. succinylcholine 7 mg was given for tracheal intubation after confirmation of mask ventilation. The two-hand technique was adopted and the neonate was lifted from the table by two anesthesiologists. One anesthesiologist stabilized the head and shoulders, and the other supported the pelvis, and lower limbs. Laryngoscopy in this position improved visualization (Cormack-Lehane Grade 2) and intubation was done using 3.0 mm (inner diameter)



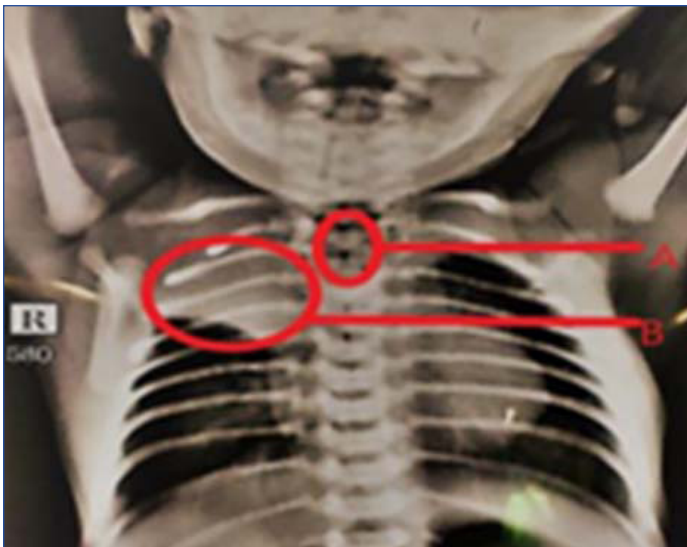
[Table/Fig-2b]: MRI showing a giant meningomyelocele.

uncuffed ETT. The intubation was successful at first attempt and fixed at 9 cm after confirming bilateral equal air entry. The baby received Inj. atracurium 1.75 mg as a loading dose. The neonate was put in prone position with extreme caution to avoid accidental extubation. Anaesthesia was maintained using Oxygen (O₂) and Nitrous Oxide (N₂O) (50:50) + sevoflurane (1-2%), Inj. atracurium 0.5 mg was used as top ups dose. The duration of the surgery was about two and half hours. The intraoperative period was uneventful. Due to excision of large amount of brain tissue and increased duration of surgery decision for elective ventilation was taken. After the procedure, the neonate was shifted to Neonatal Intensive Care Unit (NICU) for further monitoring and ventilation. On the second postoperative day, the baby was extubated. He started accepting regular feeds, and was discharged on 10th postoperative day.

Case 4

A 2-day-old male neonate, weighing 2.4 kgs, was diagnosed with oesophageal atresia and with Tracheo-oesophageal Fistula (TEF). He was posted for right thoracotomy for TEF repair. The baby was delivered via elective lower segment caesarean section and had weak cry immediately after birth. During preoperative assessment neonate was on oxygen supplementation at the rate of 5 litres/min, and on examination patient had stridor and bilateral subcostal retractions. On auscultation, reduced air entry in the right upper lobe was noted with bilateral fine crepitations in all lung fields. An ETT was left in situ in the oesophagus for continuous suctioning. Chest radiography revealed right upper lobe collapse and a mediastinal mass [Table/Fig-3], and on further investigation using Ultrasound scan (USG) it was reported to be anterior mediastinal mass (thymoma). On cardiovascular examination, there were no significant findings. Signs of compression of great vessel were looked for such as oedema of the upper body but second echocardiography revealed anacyanotic heart disease with atrial septal defect having a left to right shunt with dilated right atrium, moderate pulmonary artery hypertension, and a good bi-ventricular function. Airway assessment was done and no significant abnormalities were noted. The only concern was the anterior mediastinal mass which was discovered in the USG chest.

On the day of surgery, the baby was kept nil orally for 4 hours, and was shifted to the operation theater and NIBP, pulse oximeter, Electrocardiograph (ECG) were attached. Fluid administration was started with 0.45% dextrose using a pediatric micro drip set. The neonate was pre-medicated with Inj. atropine and ondansetron. A rigid bronchoscopy was kept standby anticipating difficult airway due to the mediastinal mass. Thorough oral and ETT tube

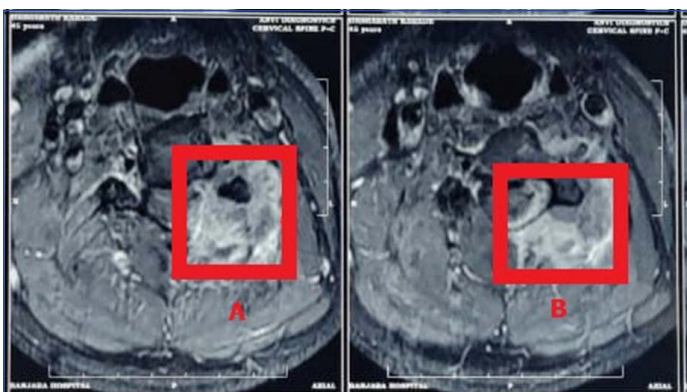


[Table/Fig-3]: Chest radiograph (anteroposterior view) showing anterior mediastinal mass (A) and right upper lung collapse (B).

suctioning was done. A soft foam was placed under the shoulder to facilitate laryngoscopy. Inhalational induction with sevoflurane was administered at 3% Monitored Anaesthesia Care (MAC) with Fraction of inspired Oxygen (FiO_2) of 60%. After attaining adequate depth of anesthesia, laryngoscopy was done with Miller blade 0, cords were visualized, and ETT no. 3 was used to attempt intubation. There was difficulty in negotiating the ETT beyond the initial glottic opening as the tube needed to be placed distal to TEF and then pulled back to assure bilateral air entry. On encountering difficulty in passing the ETT, bronchoscope of size 3 was used. Intubation was done and bilateral air entry confirmed. Anesthesia was maintained with sevoflurane 1%, O_2 at 40%, N_2O at 40%, and muscle relaxation was achieved using Inj. atracurium 0.3 mg/kg. The intraoperative period was uneventful and the neonate was transferred to NICU with ETT in-situ.

Case 5

A 45-year-old male, weighing 74 kgs, complained of neck pain and bilateral upper limb paraesthesia, difficulty in swallowing, and change in voice. The patient had pain in the neck since a year, which was progressive in nature, and associated with restricted neck movements. Investigations revealed a chondroma at the level of C2-C3 [Table/Fig-4]. He was thus planned for a surgery. During pre anaesthetic evaluation, it was found that he was tobacco chewer since 20 years and had submucosal fibrosis. On examination, patient had both restricted mouth opening and cervical spine. Mallampatti grading could not be assessed as the mouth opening was restricted while all other airway parameters were within normal limits.



[Table/Fig-4]: MRI showing mass located at cervical spine- axial plane spine.

The patient was planned for awake fiberoptic oral intubation. On the day of surgery he was given nebulization with lignocaine 4%. Once the patient was shifted to operation theatre, monitoring using NIBP, pulse oximeter and ECG leads were started and intravenous fluid was

administered with Ringer lactate at 5 mL/kg. Inj. Dexmedetomidine 1 mcg/kg was started after 10 mins bilateral airway blocks had been administered. After placing a bite block, awake FOB was attempted. Once the fiberoptic scope was advanced beyond the epiglottis evidence of erosion of the posterior pharyngeal wall was seen. After visualizing the cords, lignocaine 2% was injected via the side port of fibre optic scope and the ETT no.8 was passed beyond the glottic opening, then anaesthesia was induced with inj. propofol 2 mg/kg and Inj. vecuronium 4 mg was administered. Anesthesia was maintained with oxygen, nitrous oxide and isoflurane. The intraoperative period was uneventful.

Case 6

A 25-year-old male, with alleged history of road traffic accident, was diagnosed to have left mandible fracture. He was posted for surgery. On examination, the patient was moderately built and nourished. Respiratory and cardiovascular examinations were normal. Airway examination revealed Mallampatti grade IV with no loose tooth. Mouth opening was one and half fingers. Neck flexion and extension were normal. All other routine investigations were normal. Preoperatively, the patient was nebulized with 4% lignocaine. Nasal packing with lignocaine 2% and adrenaline was done. Mouth gargling was done with lignocaine 2%. He was explained about the procedure in advance and shifted to operation theater. On the operating table, standard monitors including pulse oximetry, ECG and NIBP were connected and baseline vitals were noted. The patient was given airway nerve blocks (translaryngeal and superior laryngeal). Pre medication was done with Inj. ondansetron 4 mg I.V (intravenous), Inj. glycopyrrolate 0.2 mg i.v and Inj. midazolam 1 mg i.v. As an analgesic Inj. fentanyl 50 microgram i.v was given. The patient was awake and cooperative while fiberscope was introduced nasally and advanced into trachea. On visualising vocal cords the flexometallic tube of 7.5 mm size was inserted and after confirmation of tube position using bilaterally equal air entry, the patient was induced with both intravenous and inhalational agent. Surgery lasted for 3 hours with minimal blood loss and no intraoperative complications. At the end of surgery, patient was extubated. In the postoperative period, the patient was stable.

DISCUSSION

A difficult airway can be defined as a "the clinical situation in which a conventionally trained anesthesiologist experiences difficulty with mask ventilation, difficulty with tracheal intubation or both" [3]. A difficult endotracheal intubation is defined as "proper insertion of the tracheal tube with conventional laryngoscopy that requires more than 3 attempts or more than 10 minutes" [4].

Sometimes difficult intubation can occur because of anatomical abnormalities or other factors. Anatomical factors indicative of difficult airway include high body mass index, older age, Mallampatti grade III or IV, severely limited jaw protrusion, and thyromental distance of less than 6 cm. Sometimes even these predictors could fail in predicting difficult laryngoscope intubation [2].

A good airway assessment should be undertaken to diagnose the potential for difficult airway for proper patient preparation, proper selection of equipment and proper technique and participation of person experienced in the difficult airway management. On the other hand, determining that the airway is normal avoids time consuming, invasive and potentially more traumatic methods of securing the airway from being adopted. Essential component of good airway assessments are to correctly predict the four pillars of safe airway management which include mask ventilation, laryngoscopy and tracheal intubation, placement of supraglottic device, performing a surgical access to the airway. History of surgery, burns, trauma, or tumour in and around the oral cavity, neck, cervical spine pose a potential problem for difficult intubation.

Common causes for anticipated difficult airway may include syndromes such as Pierre-Robin, Treacher Collins, Downs, Klippel-

Feil, tumors, trauma and burns with contractures, large goiter, cleft lip and palate, congenital hydrocephalus, meningomyelocele, cystic hygroma, downs syndrome, acromegaly. While unanticipated difficult airway may include infections, abscess, Ludwig's angina, rheumatoid arthritis, obesity, and acromegaly, TEF. Endotracheal tube guides, different types and sizes of laryngoscope blades, supraglottic airway devices, lighted stylets, rigid video laryngoscopes, and indirect fiber optic laryngoscopes are some options available to circumvent the difficult airway challenges [5]. In the present case series, the recent American Society of Anaesthesiologists (ASA) difficult airway guidelines were followed [6].

The use of FOB dates back to 1967, where choledoscope was first used to intubate patients with Stills disease. First case series of the use of fiberoptics for intubations was published in 1972 [7]. Any decision to perform the procedure in an awake versus anesthetized patient depends on the risk of losing the airway control. If there is any concern that patient airway cannot be secured, it is safe to have the patient maintain his or her own oxygenation and ventilation. One should not give up on the wakefulness easily. Hence knowledge of FOB functionality and care is paramount to prevent damage and loss of clinical availability. Fiber optic intubation under spontaneous ventilation remains the choice, in anticipated difficult airway. Awake fiber optic intubation has recently gained popularity with good intubating conditions are found in awake patients because they can assist in clearing their own secretions, phonating, or panting [5]. A successful FOB is reported in this series, where an awake intubation was performed in a patient with undisplaced fracture of parasymphysis of mandible, repaired with miniplating. Shaik SI et al., in a case report on anaesthetic management of Ludwig's angina concluded that awake fiberoptic intubation under topical anesthesia is sophisticated and a less invasive method of securing airway in patients with deep neck infection [8].

Successful videolaryngoscope was performed in a post burn contracture, where the patient had restricted neck movement and reduced mentohyoid distance [9,10]. The authors had performed intubation with video laryngoscope successfully in which patients with post-burn contractures. Pahuja HD et al., reported a patient with a giant oblong occipital meningoencephalocele, in a 1-month-old male neonate. The arrangement for positioning of the neonate for intubation was done by stack of towel blocks. For head support movable blocks were used. So, once the baby was placed on the pillow with the head beyond its edge, each part can be moved as and when required so that the head is supported from all sides with the huge swelling in the depression between the blocks. Each stack could be adjusted as and when required to support the uneven contour of the swelling. This was an innovative approach of positioning such patients with giant meningoencephalocele for intubation in supine position, made according to the availability of resources [11]. Such cases need to be well planned before induction, to avoid injury and rupture. Overall, 35-55% of the mediastinal masses in neonates arise from the anterior mediastinum and these masses might originate from the thymus, thyroid, lymphoma or thyroid [12]. Symptoms depend on the size of the mass and involvement of the surrounding structures. The anesthesia associated complication in children with anterior mediastinal mass is found to be 9.7-15% [13]. Preoperative assessment must involve assessment of the airways and cardiovascular and respiratory compromise due to the mediastinal mass. A detailed anesthesia plan including induction, maintenance, and post-operative management should be done, and this should include the position in which the patient is most comfortable. Symptoms due to respiratory compromise are seen when the lumen of the trachea is narrowed and the presence of stridor in the preoperative period is a good indicator of possible complications during anesthesia. Cardiovascular symptoms are generally not seen in anterior mediastinal mass, but one dreaded complication involving the Cardiovascular System (CVS) is the

superior vena cava syndrome [14]. Tütüncü AC et al., published a similar report about a 6-month-old baby with massive mediastinal mass, measuring 93x78 mm (cystic lesion) with compression symptoms, who was posted for excision of mass. Induction was done using 4% sevoflurane and remifentanyl infusion was started at 0.05 mc/kg. There were no adverse events during mask ventilation and intubation was done without using neuromuscular blockers. Intubation was successful and anesthesia was maintained using sevoflurane at 2% with air and oxygen mixture [14]. Dhiwan S et al., published a case report of a 8-month-old male baby with huge mediastinal mass, who was posted for thoracotomy. The baby was premedicated glycopyrrolate and fentanyl 2 mcg/kg. Anaesthesia was induced with air, nitrous oxide and isoflurane and intubation was done by direct laryngoscopy with ETT 3.0 mm and after confirming bilateral air entry and the thoracotomy was started, neuromuscular blocker atracurium was only administered after the mass was moved away from the tracheobronchial tree [15].

In the above-mentioned 2-day-old neonate (with TEF and esophageal atresia) the plan of anesthesia was to induce him using sevoflurane and intubate without using neuromuscular blockers. The preservation of spontaneous respiration reduced the chances of compression on vascular structure post neuromuscular blockade. The use of sevoflurane and ketamine during induction helped in preserving this spontaneous respiration. Hence, the plan should be based on preserving spontaneous respiration and rigid bronchoscopy and other emergency airway equipment should be kept ready, and postoperatively intensive care support should be given to avoid complications [16-19].

Spine surgeries of the cervical region present a unique difficulty for patients having limited cervical extension. Cervical spine manipulation should be avoided to ensure no injury to the cord. Limited cervical extension leads to poor alignment of the oropharyngeal axis and poor glottic visualization. The plan of anesthesia management should be drafted keeping in mind the above problems and their possible complications. Owing to the restricted mouth opening and cervical mobility, the plan of anesthesia for the above-mentioned patient with cervical mass was awake fiber optic oral intubation. Bhatnagar V et al., published a similar case report (of cervical chondroma at C2 level) having extension into the posterior pharyngeal wall. Their plan of anesthesia was awake fiberoptic oral intubation because of the limited neck extension. Nasal intubation was avoided owing to the posterior pharyngeal wall extension and the previous radiotherapy for the patient which would have made the area of interest friable [20]. A study conducted by Khedr HSM et al., showed that use of intubating Laryngeal Mask Airway (LMA) for patients with restricted cervical spine mobility is a suitable alternative to conventional laryngoscopy and limits the cervical spine manipulation [21]. Retrospectively, the use of awake fiber optic orotracheal intubation proved to be a boon in the patient owing to the retropharyngeal erosion and extension which was missed on imaging.

CONCLUSION(S)

A difficult intubation situation must be anticipated by an anesthesiologist. Alternative strategies need to be used if unanticipated difficulties are encountered. One should opt for the technique with which one is comfortable and confident. Henceforth, fiberoptic intubation remains the gold standard for anticipated difficult airway and video laryngoscope remains the gold standard for unanticipated difficult airway.

REFERENCES

- [1] Hagberg CA. Current concepts in the management of the difficult airway. *Anaesthesiology News*. 2014;11:45-72.
- [2] Cattano D, Killoran PV, Iannucci D, Maddukuri V, Altamirano AV, Sridhar S, et al. Anticipation of the difficult airway: Preoperative airway assessment, an educational and quality improvement tool. *Br J Anaesth*. 2013;111:276-85.
- [3] SM Crawley, MBChB FRCA, AJ Dalton, MBChB FRCA, Predicting the difficult airway, *BJA Education*. 2015;15(5):253-57.

- [4] Andranik Ovassapian, David O. Warner; Principles of Airway Management, Third Edition. *Anesthesiology*. 2004;101:1255.
- [5] Bhat R, Mane RS, Patil MC, Suresh SN. Fiberoptic intubation through laryngeal mask airway for management of difficult airway in a child with Klippel-Feil syndrome. *Saudi J Anaesth*. 2014;8:412-14.
- [6] Apfelbaum JL, Hagberg CA, Connis RT. American Society of Anesthesiologists Practice Guidelines for Management of the Difficult Airway. *Anesthesiology*. 2022;136:31.
- [7] Chen PD, Yu SL, Chen S, Weng XH. Retrospective study of 61 patients with adult-onset Still's disease admitted with fever of unknown origin in China. *Clin Rheumatol*. 2012;31(1):175-81.
- [8] Shaikh SI, Sarala BM, Bhosale R. Anaesthetic management of case of Ludwig's angina: Forewarned is forearmed. *Int J Biomed Adv Res*. 2014;5:123-25.
- [9] Sung JK, Kim HG, Kim JE, Jang MS, Kang JM. Endotracheal tube intubation with the aid of a laryngeal mask airway, a fiberoptic bronchoscope, and a tube exchanger in a difficult airway patient: A case report. *Korean J Anesthesiol*. 2014;66:237-39.
- [10] Langeron O, Semjen F, Bourgain JL, Marsac A, Cros AM. Comparison of the intubating laryngeal mask airway with the fiberoptic intubation in anticipated difficult airway management. *Anesthesiology*. 2001;94:968-72.
- [11] Pahuja HD, Deshmukh SR, Lande SA, Palsodkar SR. Anaesthetic management of neonate with giant occipital meningoencephalocele: Case report. *Egyptian Journal of Anaesthesia*. 2015;31(4):331-34.
- [12] Manhas Y Chinnan, NK Singh AK. Neonatal airway management in occipital encephalocele. *AnesthAnalg*. 2006;103(6):1632.
- [13] Hack HA, Wright NB, Wynn RF. The anaesthetic management of children with anterior mediastinal masses. *Anaesthesia*. 2008;63:837-46.
- [14] Tütüncü AÇ, Kendigelen P, Kaya G. Anaesthetic Management of a Child with a Massive Mediastinal Mass. *Turk J Anaesthesiol Reanim*. 2017;45(6):374-76.
- [15] Diwan S, Patil S, Jadhav S, Nair AS. Comprehensive perioperative management of an infant with huge mediastinal mass. *Saudi J Anaesth*. 2019;13(3):246-48.
- [16] Scrace B, McGregor K. Anterior mediastinal masses in paediatric anaesthesia. *Anesthesia tutorial of the week*. 2015;320:01-07.
- [17] Pearson JK. Pediatric anterior mediastinal mass: A review article. *Semin Cardiothorac Vasc Anesth*. 2015;3:248-54.
- [18] Stricker PA, Gurnaney HG, Litman RS. Anesthetic management of children with an anterior mediastinal mass. *J ClinAnesth*. 2010;3:159-63.
- [19] Lerman J. Anterior mediastinal masses in children. *Semin Anesth Periop Med Pain*. 2007;26:133-40.
- [20] Bhatnagar V, Karmarkar AA, Dwivedi D, Ray A. Anesthetic management of excision of recurrent C2 chordoma with extension into posterior pharyngeal wall. *J Mar Med Soc*. 2017;19:128-30.
- [21] Hisham SM, Gomaa ZH, Nesrine EE, et al. Degree of cervical mobility differs or not when using alternative way of intubation: Intubating laryngeal mask or classic laryngoscope. *Egyptian Journal of Anaesthesia*. 2016;32(3):309-14.

PARTICULARS OF CONTRIBUTORS:

1. Associate Professor, Department of Anaesthesia, BLDE (Deemed to be University) Shri B M Patil Medical College, Hospital and Research Centre, Bijapur, Karnataka, India.
2. Associate Professor, Department of Anaesthesia, BLDE (Deemed to be University) Shri B M Patil Medical College, Hospital and Research Centre, Bijapur, Karnataka, India.
3. Junior Resident, Department of Anaesthesia, BLDE (Deemed to be University) Shri B M Patil Medical College, Hospital and Research Centre, Bijapur, Karnataka, India.
4. Junior Resident, Department of Anaesthesia, BLDE (Deemed to be University) Shri B M Patil Medical College, Hospital and Research Centre, Bijapur, Karnataka, India.
5. Professor and Head, Department of Anaesthesia, BLDE (Deemed to be University) Shri B M Patil Medical College, Hospital and Research Centre, Bijapur, Karnataka, India.

NAME, ADDRESS, E-MAIL ID OF THE CORRESPONDING AUTHOR:

Dr. SD Pratibha,
H No-13, Behind KHB Colony, Sadashiv Nagar,
Solapur Road, Bijapur, Karnataka, India.
E-mail: pratibhakaradi@gmail.com

PLAGIARISM CHECKING METHODS: [\[Lain H et al.\]](#)

- Plagiarism X-checker: Apr 16, 2022
- Manual Googling: May 11, 2022
- iThenticate Software: Jun 07, 2022 (18%)

ETYMOLOGY: Author Origin**AUTHOR DECLARATION:**

- Financial or Other Competing Interests: None
- Was informed consent obtained from the subjects involved in the study? Yes
- For any images presented appropriate consent has been obtained from the subjects. Yes

Date of Submission: **Apr 14, 2022**Date of Peer Review: **May 17, 2022**Date of Acceptance: **June 08, 2022**Date of Publishing: **Jul 01, 2022**