

# Pulmonary Cavity: An Additional Entity to the Spectrum of COVID-19 Complications

KEERTIVARDHAN D KULKARNI<sup>1</sup>, V PRANAVI<sup>2</sup>, APOORVA RAVI<sup>3</sup>, HT LATHADEVI<sup>4</sup>, SM BIRADAR<sup>5</sup>

## ABSTRACT

The latest pandemic caused by Severe Acute Respiratory Syndrome Coronavirus 2 (SARS-CoV-2) is known to manifest in various forms, ranging from a mild illness to a life-threatening condition. Though lung cavitation has not been commonly reported as a post Coronavirus Disease 2019 (COVID-19) infection complication, there has been a rise in the number of patients presenting with lung cavitation post the viral infection. In this case series, authors have reported four cases of lung cavitation developed post COVID-19 infection. Three out of four patients were newly diagnosed cases of diabetes, all received steroids as a part of treatment for COVID-19 infection. Three patients showed a temporary improvement in their condition after COVID-19 treatment, in the form of decreasing trends of inflammatory markers and decreased total count, but subsequently developed signs of super added infection during the course of their illness. Two patients had associated sino-orbital mucormycosis. Two patients required the support of non invasive ventilation and did not show clinical improvement, while one amongst the two succumbed to the infection. The cause for the development of lung cavities post COVID-19 infection is difficult to speculate it appears to be multifactorial with factors including isolated bacterial, fungal infections or bacterial and fungal co-infection, SARS-CoV-2 specific inflammatory pathways, and the immunosuppressive effects of glucocorticoids.

**Keywords:** Coronavirus Disease 2019, Co-infection, Fungal infections, Mucormycosis, Steroids

## INTRODUCTION

The pandemic of coronavirus remains to be a continuing problem worldwide, with the disease manifesting in various forms, leading to difficulties in devising a standard protocol for management. Although the mechanisms causing acute clinical presentation are mostly clear now, surviving the disease is the first battle among many along the long road to recovery, as there are post COVID-19 complications reported that are equally life threatening [1]. The typical abnormalities that have been described commonly in Computed Tomography (CT) of the chest among COVID-19 infected patients are peripheral ground glass opacities, consolidation, linear opacities, crazy-paving pattern and interlobular septal thickening [2]. Few studies reported on the development of traction bronchiectasis and pleural effusions at late stages of severe disease but very few case reports have been published that reported the presence of lung cavitation as a COVID-19 infection sequel [3,4]. Cavitation in COVID-19 pneumonia may be due to the diffuse alveolar damage, intra-alveolar haemorrhage, and necrosis of parenchymal cells [5]. This case series include four cases of cavitary lesions in the lung that developed post COVID-19 infection.

## CASE SERIES

### Case 1

A 55-year-old female was tested positive for COVID-19 infection, by nasopharyngeal swab for Reverse Transcription-Polymerase Chain Reaction (RT-PCR). The patient had no history of diabetes or any other debilitating conditions and no relevant family history. On admission, complete blood count, liver and renal function tests were within normal limits, CRP was >90 mg/L, D-dimer was 314 ng/mL and Interleukin-6- 4.2 pg/mL. Her High Resolution Computed Tomography (HRCT) scan of the thorax revealed multifocal well-defined patchy ground glass opacities in bilateral lung fields in subpleural distribution with a CT severity index of 8/25 [Table/Fig-1a,b]. Her Glycated hemoglobin (HbA1c) at the time of admission was 8.5%, with Fasting Blood Sugar (FBS) being 132 mg/dL, and Post Prandial Blood Sugar (PPBS) being 213 mg/dL.

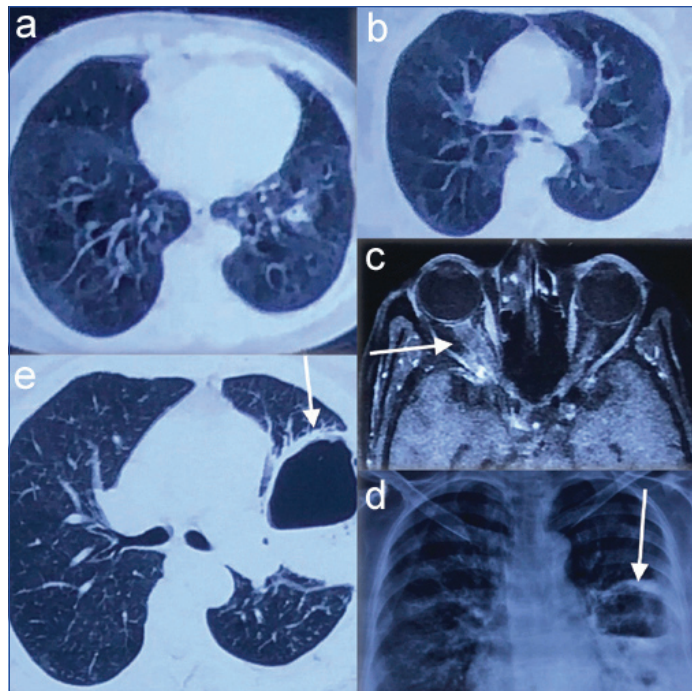
She was started on intravenous (i.v.) inj. remdesivir with a loading dose of 200 mg, followed by 100 mg daily for 5 days, inj. piperacillin Tazobactam 4.5 gm i.v. TID, inj. methylprednisolone i.v. 80 mg/day, inj. low molecular weight heparin 0.6 mL subcutaneously BD, and inj. human actrapid titrated according to blood sugar values as a part of COVID-19 management for 7 days, and then discharged. The patient required no oxygen support during her stay in the hospital.

After three days of discharge, the patient complained of headache and watery discharge from the right eye followed by redness and swelling of face on the right side, associated with pain. On examination, her oxygen saturation was 89% at room air, there was complete ptosis of right eye with chemosis and absent perception to light, with no nasal discharge. She was re-admitted and provided oxygen support.

Magnetic Resonance Imaging (MRI) of brain, orbit and paranasal sinuses revealed peripherally enhancing mucosal collection in the right ethmoidal, right half of frontal and right maxillary sinus with an early orbital invasion seen at the base of right orbit, suggestive of fungal sinusitis [Table/Fig-1c]. She was started on inj. amphotericin B 50 mg/day i.v. infusion in 5% dextrose along with anticoagulants and Tab. posaconazole 100 mg TID, with careful monitoring of renal function tests and blood sugar levels and inj. human actrapid titrated according to it. On 7<sup>th</sup> day of her treatment, her C-Reactive Protein (CRP) showed a decreasing trend (20.2 mg/L), but D-dimer was persistently elevated (4766.75 ng/mL), with perception of light present in right eye, but her ocular movements were restricted.

During the treatment period, after five days of starting antifungals, the patient complained of increased cough with sputum production, which was blackish in colour. Chest X-ray showed cavity with air fluid level on left side suggestive of lung abscess [Table/Fig-1d]. The patient was started on antibiotic inj. meropenem 1 gm IV BD and was advised chest physiotherapy and postural drainage. Plain CT thorax showed subsegmental and segmental patches of consolidation with internal large cavitary changes with air fluid levels within, in left upper and left lower lobe; suggestive of active infective lung parenchymal disease with possibility of pulmonary mucormycosis, though the typical reverse halo sign

or bird's nest sign were not seen [Table/Fig-1e]. The patient's sputum samples were sent for aerobic culture and fungal culture, which revealed the presence of *Klebsiella pneumoniae* that was resistant to all antibiotics except fosfomycin, while fungal culture did not yield any results. The patient was later advised Functional Endoscopic Sinus Surgery (FESS), which was done at a higher centre where the scrapings showed no yield in fungal culture. Unfortunately, the patient succumbed to the infection.



**[Table/Fig-1]:** a,b) HRCT of the thorax showing multifocal well defined patchy ground glass opacities in bilateral lung fields in subpleural distribution; c) MRI of brain, orbit and paranasal sinuses revealing peripherally enhancing mucosal collection in right ethmoidal, right half of frontal and right maxillary sinus with an early orbital invasion at the base of right orbit, suggestive of fungal sinusitis; d) Chest X-ray during the course of treatment showing cavity with air fluid level on left side suggestive of lung abscess; e) Plain CT Thorax showing internal large cavitary changes with air fluid levels within, noted in left upper and left lower lobe-suggestive of active infective lung parenchymal disease with likely possibility of pulmonary mucormycosis.

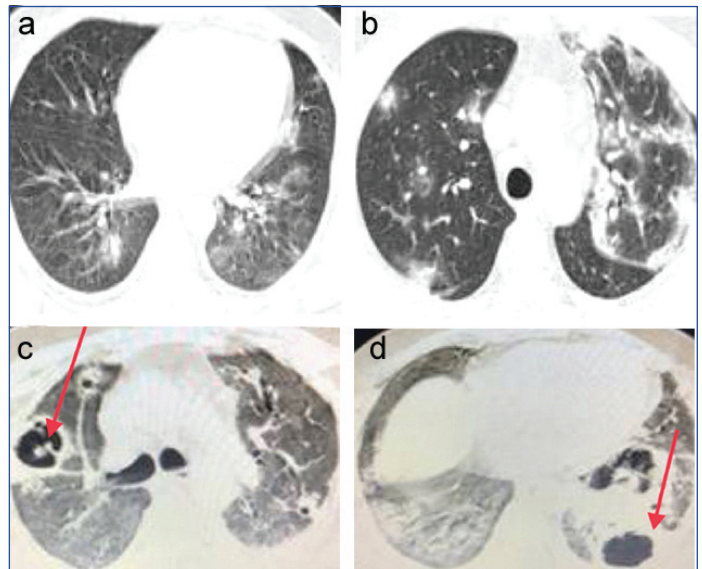
**Case 2**

A 42-year-old male, RT-PCR for COVID-19 positive, presented with breathlessness with oxygen saturation of 82%. His medical history revealed no co-morbidities. On admission, his haemoglobin was 14 g/dL, with a total count of 18,320/ $\mu$ L, while his liver and renal function tests were within normal limits. His CRP was >90 mg/L and D-dimer was 4280.20 ng/mL, with HbA1c 7.7%. His FBS and PPBS values were 265 mg/dL and 309 mg/dL respectively. The HRCT of thorax revealed multiple bilateral patchy ground glass opacities with CT severity score of 16/25 as shown in [Table/Fig-2a,b].

He was supplemented with oxygen and was started on inj. remdesivir 200 mg i.v. once a day on first day followed by 100 mg once a day for another four days, Inj. piperacillin tazobactam 4.5 gm i.v. TID, Inj. methylprednisolone i.v. 120 mg/day, Inj. low molecular weight heparin 0.6 mL subcutaneously BD and Inj. human actrapid titrated according to blood sugar values. The patient required non invasive ventilation after two days of admission due to fall in oxygen saturation levels, when the total count raised to 26,090/ $\mu$ L, while CRP and D-dimer showed a decreasing trend (10.3 mg/L and 2636.49 ng/mL, respectively). The antibiotic was changed to inj. meropenem 1 gm i.v. BD. The patient was maintained on non invasive ventilation for 13 days when the total count dropped down to 15,670/ $\mu$ L, with CRP and D-dimer showing persistently decreasing trends (<10 mg/L, and 1545 ng/mL, respectively), with gradual improvement in patient's condition.

The patient was weaned off to oxygen support, when his cough worsened with expectoration after five days of weaning off. He

also complained of an episode of hemoptysis, following which anticoagulants were stopped and a repeat HRCT thorax was ordered, which revealed diffuse randomly distributed areas of ground glass attenuation with interlobular septal thickening and alveolar exudates in bilateral lungs with an ill-defined thick walled cavitary lesion with surrounding consolidation causing architectural distortion, volume loss in bilateral upper lobe and left lower lobe, along with left sided mild pleural effusion suggestive of organising lobar pneumonia with breakdown cavitation and septal emboli. This radiological findings were suggestive of pulmonary mucormycosis [Table/Fig-2c,d]. But the patient had no symptoms and signs of sino-orbital mucormycosis.



**[Table/Fig-2]:** a,b) HRCT of thorax showing multiple bilateral patchy ground glass opacities, diffusely scattered in both the lungs; c,d) A defined thick walled cavitary lesion in left lower lobe with surrounding consolidation, with randomly distributed areas of ground glass attenuation in bilateral lung fields in HRCT thorax.

On further evaluation, his CRP raised to 224 mg/L, while his D- dimer showed a continuing decreasing trend (822 ng/mL) and total count raised to 20,998/ $\mu$ L, but the patient's oxygen requirement remained to be 8 litres/minute. The patient was subsequently started on Inj. amphotericin B 50 mg/day iv infusion in 5% dextrose, with careful monitoring of renal function tests and blood sugar levels, owing to the rise in mucormycosis cases among COVID-19 infected patients. For further management of cavitary lesion in the lung, he was advised to consult a thoracic surgeon for surgical management, and hence referred after 5 days of treatment with antifungals. The trends of inflammatory markers and total count during the course of illness has been summarised in [Table/Fig-3].

Variables	Day 1	Day 3	Day 15	Day 20
CRP (mg/L)	>90	10.3	<10	224
D-dimer (ng/mL)	4820.20	2636.49	1545	822
Total count ( $\mu$ L)	18320	26090	15670	20998

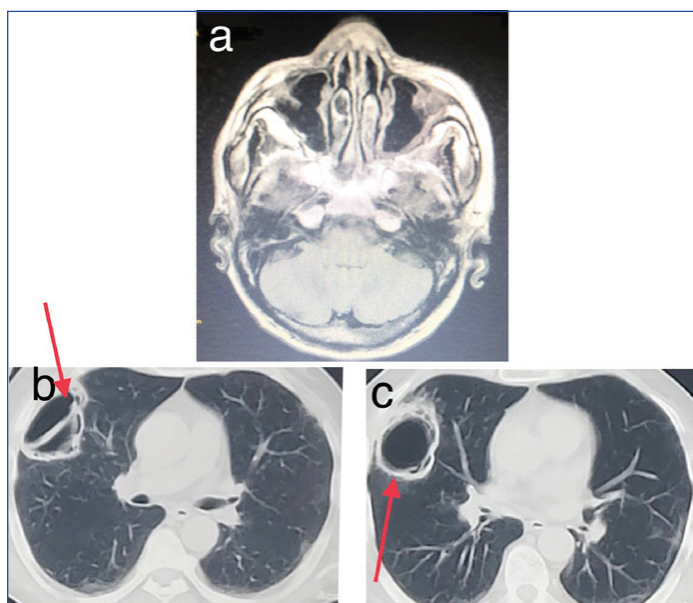
**[Table/Fig-3]:** Trends of inflammatory markers and total count in case 2.

**Case 3**

A 55-year-old male presented with complaints of right sided facial pain with swelling on the right side of the face of 3 days duration. He gave a history of abscess on the right cheek, that burst out with pus discharge. The patient had no history or contact with COVID-19 infection and suffered from no known co-morbidities. On evaluation, his complete blood count, liver and renal function tests were within normal limits. His FBS and PPBS values were 197 mg/dL and 226 mg/dL respectively, with HbA1c of 14.1%. CT of paranasal sinuses revealed minimal mucosal thickening of right maxillary sinus [Table/Fig-4a]. On suspicion of a sequelae of COVID-19 infection, patient was tested for COVID-19 antibodies,



IgM was positive, while nasopharyngeal swab for RTPCR turned out to be negative. Due to IgM antibody positivity, the patient was further evaluated with HRCT thorax to rule out active COVID-19 infection, which revealed a cavitary lesion in right upper lobe of the lung while the rest of the lung parenchyma was normal [Table/Fig-4b,c], though the patient had no respiratory complaints. The patient had no previous history of tuberculosis either. The CT score was 2/25. The CRP levels were 421 mg/L, D-dimer was 796.03 ng/mL, IL-6 49.6 pg/mL and serum ferritin 861.3 ng/mL with total count of 18,628/ $\mu$ L. His sputum analysis was negative for AFB and later was advised to undergo FESS, and the scrapings were subjected to histopathological examination, which were suggestive of mucormycosis and aspergillosis in bilateral maxillary sinus. The patient was started on Inj. Amphotericin B 50mg/day iv infusion in 5% dextrose, keeping a check on the blood sugar levels and titrating them accordingly. After one week of Inj. amphotericin, the patient was discharged with oral posaconazole 200 mg TID, while CRP levels reduced to 29.4 mg/L and D-dimer was 202 ng/mL and total count of 10,101/ $\mu$ L. The patient was reviewed after 2 weeks when renal function tests were within normal limits, as the patient's blood sugar levels were kept in control with Inj. human actrapid and Inj. lantus. The patient was also advised to consult a thoracic surgeon for the resection of affected segment of the lung. The trends of inflammatory markers and total count during the course of illness has been summarised in [Table/Fig-5].



**[Table/Fig-4]:** a,b) CT of Para nasal sinuses showing minimal mucosal thickening of right maxillary sinus; c) A well-defined cavitary lesion in right upper lobe of the lung in HRCT thorax of a 55 year old male patient.

Variables	Day 1	Day 9	2 weeks postdischarge
CRP (mg/L)	421	29.4	5.6
D-dimer (ng/mL)	79603	202	224
Total count ( $\mu$ L)	18628	10101	7868

**[Table/Fig-5]:** Trends of inflammatory markers and total count in case 3.

#### Case 4

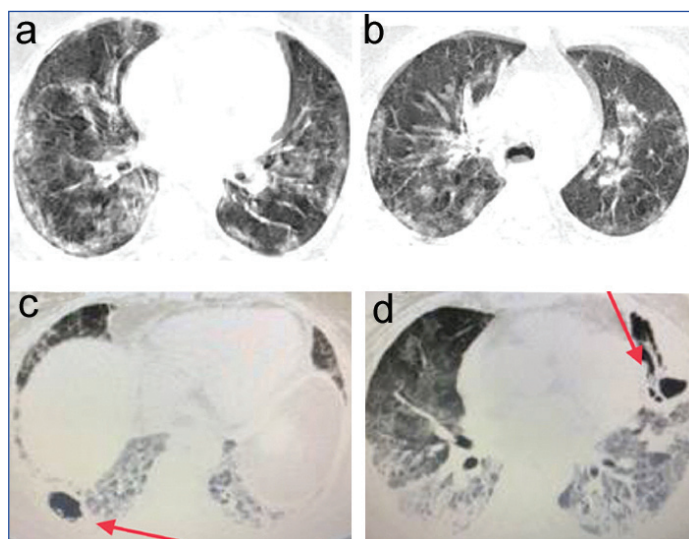
A 46-year-old female presented with complaints of low grade, intermittent fever with dry cough and breathlessness. She turned RT-PCR positive for COVID-19 infection. Her room air saturation was 88%, hence given oxygen support at 6 l/min that improved her saturation to 94%. Her blood panel revealed anemia (Hb- 9.6 g/dL), with normal white blood cell count and platelets. Her liver and renal function tests were within normal limits, while CRP was elevated with a value of 67.3 mg/L, with a normal D-dimer level (370 ng/mL). She was a known diabetic for 6 years and was on regular

medication. Her HbA1c was 7.2% with FBS being 178 mg/dL and PPBS being 209 mg/dL and total count was 11,232/ $\mu$ L.

The HRCT thorax at the time of admission showed multiple patchy areas of consolidation with adjacent ground glass opacities and pleural thickening involving bilateral lung fields, with a CT severity score of 22/25 [Table/Fig-6a,b]. She was started on Inj. remdesivir 200 mg in 100 mL normal saline on day 1 followed by 100 mg OD for the next 4 days, Inj. methylprednisolone 40mg BD, Inj. lenox 0.4 mL subcutaneous BD, antibiotics and Inj.human actrapid according to sliding scale.

The patient had a fall in saturation on the third day of admission and did not improve even with 15 L/min of oxygen. Hence, she required non invasive ventilation, and with an FiO<sub>2</sub> of 80%, she maintained saturation of 96%. Her repeated values of CRP and D- dimer on the third day showed an increasing trend with levels being, >90 mg/L and 1400.70 ng/mL respectively, while white blood cell count raised to 11,500/ $\mu$ L, with further fall in hemoglobin levels (8.6 g/dL). After three days, CRP (125 mg/L) and D-dimer (2376 ng/mL) showed an increasing trend, with total blood count being 14,375/ $\mu$ L, and no improvement in the condition of the patient for 12 days. The dosage of Inj. methylprednisolone was increased to 80 mg BD, and Inj. lupenox to 0.6 mL subcutaneous BD, with Inj. remdesivir extended to a total of 10 days. After 12 days, the levels of inflammatory markers showed a decreasing trend, with CRP was 14.8 mg/L and D-dimer was 494 ng/mL. Her IL-6 levels were 4.9 pg/mL, and the patient's FiO<sub>2</sub> requirement on non invasive ventilation reduced to 60%. The patient was on non invasive ventilation for another 10 days, where her CRP, D-dimer and complete blood count were continuously monitored. Her hemoglobin levels improved to 12.7 g/dL, while total count raised to 15000/ $\mu$ L, with CRP and D-dimer reaching normal limits. The patient was gradually weaned off to oxygen on 23<sup>rd</sup> day, while she maintained saturation of 95% with 12 L/min. On the 32<sup>nd</sup> day, the patient developed increased breathlessness, with productive cough, sputum being greenish in colour, mucoid in consistency, quantity of less than one teaspoon/day, with no blood staining.

A repeat HRCT thorax was advised, owing to progressive breathlessness, which revealed moderate to large sized subpleural areas of ground glass attenuation in bilateral lungs, with a thick-walled cavity lesion in the posterior segment of the right lower lobe and in the left upper lobe with adjacent consolidation that was suggestive of necrotising pneumonitis, likely fungal aetiology like mucormycosis [Table/Fig-6c,d]. Her CRP levels were 164 mg/L, D-dimer was 4000



**[Table/Fig-6]:** a,b) HRCT thorax of a 46 year old female showing multiple patchy areas of consolidation with adjacent ground glass opacities and pleural thickening involving bilateral lung fields; c) A repeat HRCT thorax of the same patient revealed moderate to large sized sub pleural areas of ground glass attenuation in bilateral lungs, with a thick walled cavity lesion in the posterior segment of the right lower lobe; d) Another thick walled cavity lesion in the left upper lobe with adjacent consolidation that was suggestive of necrotising pneumonitis in the same patient.

Parameters	Day 1	Day 3	Day 7	Day 20	Day 32
C-Reactive protein (mg/L)	67.3	>90	125	14.8	164
D-dimer (ng/mL)	370	1400.70	2376	494	4000
Total count ( $\mu$ L)	11232	11500	14375	15000	20175

[Table/Fig-7]: Trends of inflammatory markers and total count in case 4.

ng/mL, total count 20,175/ $\mu$ L. She was empirically started on Inj. amphotericin B 50 mg/day i.v. infusion in 5% dextrose, while her sputum analysis was insignificant. The patient did not improve with continuous oxygen support and later succumbed to the infection after 6 days. The trends of inflammatory markers and total count during the course of illness has been summarised in [Table/Fig-7].

Among the four COVID-19 infected patients, the age group involved was between 42-55 years, with a male to female ratio of 1:1. All the patients suffered from diabetes mellitus, and received steroids as a part of COVID-19 treatment. Patients with moderate and severe COVID-19 infection required non invasive Ventilation support and their clinical condition deteriorated. It was also observed that two patients with mild COVID-19 infection had associated probable sino-orbital mucormycosis. The details of the patients along with outcomes have been summarised in [Table/Fig-8].

Variables	Case 1	Case 2	Case 3	Case 4
Age (in years)	55	42	55	46
Diagnosis of COVID-19 by	Nasopharyngeal swab for RT-PCR	Nasopharyngeal swab for RT-PCR	Nasopharyngeal swab for RT-PCR	Nasopharyngeal swab for RT-PCR
History of Diabetes Mellitus (DM)	Newly diagnosed DM	Newly diagnosed DM	Newly diagnosed DM	Known case of DM for 6 years
CT Severity Score	8/25	16/25	2/25	22/25
Severity of infection	Mild	Moderate	Mild	Severe
Requirement of Oxygen/ non invasive ventilation Support	Nil	NIV support	Nil	NIV support
Treatment	Antibiotics, Insulin, Steroids, Anticoagulants, Antivirals	Antibiotics, Insulin, Steroids, Anticoagulants, Antivirals	Antibiotics, Insulin, Steroids, Anticoagulants, Antivirals	Antibiotics, Insulin, Steroids, Anticoagulants, Antivirals
Associated probable sino-orbital mucormycosis	Yes	No	Yes	No
Clinical improvement	Present	No improvement	Present	No improvement

[Table/Fig-8]: Summary of the cases including severity of infection and outcome.

## DISCUSSION

The survivors of the pandemic are in constant dread, along their road to recovery, regarding the complications that arise, which range from persistent fatigue, dyspnea to thromboembolic events and pulmonary fibrosis, whilst lung cavitation has been an uncommon finding on CT thorax among COVID-19 infected patients [2,6].

On reviewing the literature, Chen Y et al., Anguish B et al., and few others reported the occurrence of lung cavities after COVID-19 infection [6,7]. The incidence of cavitary lung lesions as a complication of COVID-19 infection has been reported to vary from 1.7% to 11% in several studies [3,4] In a retrospective study by Zoumot Z et al., 11% incidence rate of lung cavitation amongst the patients with severe COVID-19 infection, admitted in Intensive Care Unit (ICU), was reported, while 3.3% of the patients with mild COVID-19 infection developed pulmonary cavity [8].

A cavity is an air-filled space forming within an area of pulmonary consolidation, mass or nodule, as a result of liquefaction of the necrotic portion of the lesion and the discharge of this necrotic material via the bronchial tree [8]. This exact process seems to have occurred in our patients as cavities formed in areas of the lung where ground glass opacities were seen in early stages. Cavitary lung lesions are usually related to fungal, mycobacterial, autoimmune, parasitic or neoplastic aetiologies, uncommonly caused by viral pneumonias even in severe infection, but have been observed in COVID-19 patients. The velocity of development of cavitary lesions can be atypical to mycobacterial infections,

with supportive evidence of negative acid-fast bacilli on smear of respiratory specimens, and hence regarded as a complication of COVID-19 pneumonia.

Cavities in the lung have been reported as a post COVID-19 squeal, usually during the recovery phase of illness, i.e, during the third week of acquiring the infection. Chen Y et al., reported about a 34-year-old male who developed a large cavity in 3<sup>rd</sup> week of illness and improved without the use of antibiotics [6]. Another case report by Selvaraj V et al., stated cavity formation during the third week in a 52-year-old male [9]. Similarly, in the present case series, three patients developed lung cavitation during their third week of illness.

In a study by Amalnath D et al., 22 patients were included and 14 of them were on non invasive ventilation. Ten among the 14 patients on NIV succumbed to death, indicating the correlation of severity of illness with clinical outcome. Similarly, the present series showed that there was requirement of NIV among patients with moderate and severe COVID-19 infection and there was no clinical improvement observed among them [10].

Three patients in the present case series received intravenous steroids as a treatment for COVID-19, which suppress the immune system impairing innate immunity, providing an environment for the

opportunistic pathogens, especially in diabetic population. One patient had infection with bacterial organism known to cause lung cavitation. Hence, it is difficult to speculate whether bacterial infection and/or invasive fungal co-infection may have contributed to the development of the cavities, or if the infections were opportunistic. Another cause might be attributed to pulmonary infarction that leads to cavity formation, but it is less likely since all the patients received prophylactic doses of injection of low molecular weight heparin. Thus, the causes of cavity in a post COVID-19 patient appears to be multifactorial with factors including isolated bacterial, fungal infections or bacterial and fungal co-infection, SARS-CoV-2 specific inflammatory pathways, and the immunosuppressive effects of glucocorticoids.

With the rising incidence of Cavitary lung lesions as a sequelae to COVID-19 infection, there is a need for the follow-up of recovered and convalescent patients, despite a successful treatment for COVID-19. Since the cause still remains unknown, there is a need for further studies to delineate the pathology and etiology, so as to provide further evidences to the existing literature regarding the lung cavities following COVID-19 infection.

## CONCLUSION(S)

The clinical spectrum of post COVID-19 infection still remains unclear, with the advent of new lung lesions. The subsequent development of lung cavitation in COVID-19 infected individuals warrants vigilant monitoring of patients through regular follow ups, especially the immunocompromised, for early recognition and definitive treatment

of the disease. The rapid course of development of lung cavities following the viral illness implies the need for further studies to determine the causative factors. Further, there is also a need for the clinicians to be aware of the evolving CT findings in COVID-19 and appropriate follow-up of convalescent patients with COVID-19 to ensure complete recovery.

## REFERENCES

- [1] Jiang DH, McCoy RG. Planning for the post-COVID syndrome: How payers can mitigate long-term complications of the pandemic. *J Gen Intern Med.* 2020;35(10):3036-39.
- [2] Kon W, Agarwal PP. Chest imaging appearance of COVID-19 infection. *Radiol. Cardiothoracic. Imaging.* 2020;2(1):e200028.
- [3] Zheng Y, Wang L, Ben S. Met analysis of chest CT features of patients with COVID-19 pneumonia. *J Med Virol.* 2021;93(1):241-49.
- [4] Sun Z, Zhang N, Li Y, Xu X. A systematic review of chest imaging findings in COVID-19. *Quant Imaging Med Surg.* 2020;10(5):1058-79.
- [5] Menter T, Haslbauer JD, Nienhold R, Savic S, Hopfer H, Deigendes N, et al. Postmortem examination of COVID-19 patients reveals diffuse alveolar damage with severe capillary congestion and variegated findings in lungs and other organs suggesting vascular dysfunction. *Histopathology.* 2020;77(2):198-09.
- [6] Chen Y, Chen W, Zhou J, Sun C, Lei Y. Large pulmonary cavity in COVID-19 cured patient case report. *Ann Palliat Med.* 2020;9:5-52.
- [7] Angirish B, Parmar K. Lung cavitation-a rare complication in COVID-19 patients: A case report. *Arch Pulmonol Respir Care.* 2020;6(1):78-80. Doi: 10.17352/aprc.000061.
- [8] Zoumot Z, Bonilla MF, Wahla AS, Shafiq I, Uzbeck M, El-Lababidi RM, et al. Pulmonary cavitation: An under-recognized late complication of severe COVID-19 lung disease. *BMC Pulmonary Medicine.* 2021;21(1):01-08.
- [9] Selvaraj V, Dapaah-Afriyie K. Lung cavitation due to COVID-19 pneumonia. *BMJ Case Rep.* 2020;13:e237245.
- [10] Amalnath D, Barathi D, Pari H. Uncommon manifestation of COVID-19-delayed onset cavitating lung lesions, a retrospective study of 22 patients from a tertiary care centre in Southern India. *The Journal of the Association of Physicians of India.* 2022;70(1):11-12.

### PARTICULARS OF CONTRIBUTORS:

1. Associate Professor, Department of Respiratory Medicine, Shri. B. M. Patil Medical College, Hospital and Research Centre, Vijayapura, Karnataka, India.
2. Postgraduate Student, Department of Respiratory Medicine, Shri. B. M. Patil Medical College, Hospital and Research Centre, Vijayapura, Karnataka, India.
3. Postgraduate Student, Department of Respiratory Medicine, Shri. B. M. Patil Medical College, Hospital and Research Centre, Vijayapura, Karnataka, India.
4. Professor, Department of Ear, Nose and Throat, Shri. B. M. Patil Medical College, Hospital and Research Centre, Vijayapura, Karnataka, India.
5. Professor, Department of General Medicine, Shri. B. M. Patil Medical College, Hospital and Research Centre, Vijayapura, Karnataka, India.

### NAME, ADDRESS, E-MAIL ID OF THE CORRESPONDING AUTHOR:

Dr. V Pranavi,  
House No. A105, NRI and PG Hostel, Shri. B.M Patil Medical College, Hospital and Research Centre, B.M. Patil Road, Vijayapura-586103, Karnataka, India.  
E-mail: pranavireddy94@gmail.com

### PLAGIARISM CHECKING METHODS: [Jain H et al.]

- Plagiarism X-checker: Feb 01, 2022
- Manual Googling: May 05, 2022
- iThenticate Software: Jun 30, 2022 (11%)

### ETYMOLOGY: Author Origin

Date of Submission: **Jan 28, 2022**

Date of Peer Review: **Mar 15, 2022**

Date of Acceptance: **May 14, 2022**

Date of Publishing: **Jul 01, 2022**

### AUTHOR DECLARATION:

- Financial or Other Competing Interests: None