

**“FUNCTIONAL OUTCOME OF PRIMARY TOTAL HIP  
ARTHROPLASTY IN ELDERLY PATIENTS WITH  
FRACTURE NECK OF FEMUR – A PROSPECTIVE STUDY”**

**By**

**Dr. Adityaa E**



Dissertation submitted to BLDE (Deemed to be University), Vijayapura.

In partial fulfilment of the requirements for the award of the degree of

**DOCTOR OF MEDICINE**

**IN**

**ORTHOPAEDICS**

Under the guidance of

**Dr. Ashok Nayak**

Professor and HOD Department of Orthopaedics  
**BLDE (DEEMED TO BE UNIVERSITY)**

**SHRI B.M. PATIL MEDICAL COLLEGE, HOSPITAL & RESEARCH  
CENTRE, VIJAYAPURA, KARNATAKA.**

**2019**

**“FUNCTIONAL OUTCOME OF PRIMARY TOTAL HIP  
ARTHROPLASTY IN ELDERLY PATIENTS WITH FRACTURE  
NECK OF FEMUR – A PROSPECTIVE STUDY”**

BLDE (DEEMED TO BE UNIVERSITY),  
VIJAYAPURA, KARNATAKA



**DOCTOR OF SURGERY  
IN  
ORTHOPAEDICS**

## **LIST OF ABBEVIATIONS USED**

FNF-	Fracture neck of femur
HA-	Hemiarthroplasty
THA-	Total Hip Arthroplasty
THR-	Total hip replacement
ECG-	Electrocardiogram
DER-	Distal end radius fracture
DVT-	Deep vein thrombosis
HTN-	Hypertension
DM-	Diabetes mellitus
BA-	Bronchial asthma
IHD-	Ischemic heart disease
UTI-	Urinary tract infection
HHS-	Harris Hip Score
LMWH-	Low molecular weight heparin
PMMA-	Polymethyl methacrylate
PE-	Polyethylene
M-O-M	Metal on metal
C-O-C	Ceramic on ceramic

## **TABLE OF CONTENTS**

<b>Sl. No.</b>	<b>TOPIC</b>	<b>Page No.</b>
1	INTRODUCTION	17
2	AIMS AND OBJECTIVES	19
3	REVIEW OF LITERATURE	20
4	SURGICAL ANATOMY	27
5	METHODOLOGY	54
6	RESULTS	77
7	PHOTOGRAPHS	90
8	DISCUSSION	93
9	CONCLUSION	97
10	BIBLIOGRAPHY	98
11	ANNEXURES	
12	I: ETHICAL COMMITTEE CLEARANCE CERTIFICATE	104
13	II: VOLUNTEER CONSENT FORM	105
14	III: STUDY PROFORMA	107
15	IV: MODIFIED HARRIS HIP SCORE SYSTEM	111
16	V: STUDY MASTER CHART	115

## LIST OF TABLES

<b>S. No.</b>	<b>TOPIC</b>	<b>Page.No.</b>
1	MUSCLES AROUND THE HIP JOINT	28
2	LIGAMENTS AROUND THE HIP JOINT	35
3	KINESIOLOGY OF HIP JOINT	39
4	AGE DISTRIBUTION	77
5	SEX DISTRIBUTION	78
6	MODE OF INJURY	79
7	LATERALITY	80
8	ASSOCIATED INJURIES	81
9	ASSOCIATED COMORBID CONDITIONS	82
10	COMPLICATIONS	83
11	SHORTENING	84
12	LENGTHENING	85
13	POST OPERATIVE WEIGHT BEARING	86
14	DAY OF DISCHARGE	87
15	MODIFIED HARRIS HIP SCORE	88
16	FUNCTIONAL OUTCOME	89

## LIST OF FIGURES

<b>S.No.</b>	<b>TOPIC</b>	<b>Page.No.</b>
1	LIGAMENTS AROUND THE HIP JOINT	35
2	BLOOD SUPPLY OF PROXIMAL FEMUR	37
3	TRABECULAE OF PROXIMAL FEMUR	41
4	SINGH & MAINI INDEX	41
5	NECK LENGTH & OFFSET MEASUREMENTS	44
6	VERSION	44
7	PAUWEL'S CLASSIFICATION	49
8	GARDEN'S CLASSIFICATION	50
9	ACETABULAR COMPONENT	58
10	FEMORAL COMPONENT	59
11	FEMORAL STEM SIZES	59
12	FEMORAL HEAD SIZES	60
13	GENERAL AND SPECIAL INSTRUMENTS	61
14	MERIL THA SET & TRIAL COMPONENTS	62
15	ZIMMER THA SET & TRIAL COMPONENTS	63
16	OPERATIVE POSITION	64

## LIST OF CHARTS/ GRAPHS

<b>S.No.</b>	<b>TOPIC</b>	<b>Page No.</b>
1	AGE DISTRIBUTION	77
2	SEX DISTRIBUTION	78
3	MODE OF INJURY	79
4	LATERALITY	80
5	ASSOCIATED INJURIES	81
6	ASSOCIATED COMORBID CONDITIONS	82
7	COMPLICATIONS	83
8	SHORTENING	84
9	LENGTHENING	85
10	POST OPERATIVE WEIGHT BEARING	86
11	DAY OF DISCHARGE	87
12	MODIFIED HARRIS HIP SCORE	88
13	FUNCTIONAL OUTCOME	89

## LIST OF PHOTOGRAPHS

<b>S.No.</b>	<b>TOPIC</b>	<b>Page. No.</b>
1	PREPARATION AND DRAPING	65
2	INCISION	65
3	SUPERFICIAL DISSECTION	66
4	REMOVAL OF FEMORAL HEAD	67
5	ACETABULAR PREPARATION	68
6	ACETABULAR REAMING	69
7	ACETABULAR COMPONENT FIXATION	70
8	FEMORAL NECK OSTEOTOMY	70
9	FEMORAL CANAL PREPARATION	71
10	FEMORAL COMPONENT FIXATION	73
11	CLOSURE	73
12	CLINICAL AND RADIOLOGICAL PHOTOGRAPHS	90



# **ABSTRACT**

## **INTRODUCTION:**

Hip fractures caused by osteoporosis have become a leading source of morbidity and mortality in the adult and elderly populations worldwide. Normal locomotion necessitates a stable, pain-free, and mobile hip. Unsuitable for reduction and primary fixation, displaced subcapital and intracapsular femoral neck fractures are usually treated with an arthroplasty procedure. Total hip replacement has several advantages, including an extended implant life and a lower risk of revision surgery, making it ideal for patients with a longer life expectancy.

## **AIMS AND OBJECTIVES:**

The aim of the study is to assess the functional outcome of primary total hip arthroplasty in elderly patients with fracture neck of the femur.

## **MATERIALS AND METHODS:**

In this prospective study, 25 elderly patients who met the inclusion criteria were admitted in Department of Orthopaedics in BLDEU (Deemed to be University), Shri B. M. Patil Medical College Hospital and Research Centre, Vijayapura. Procedure was explained and informed consent taken. The period of study was from Nov 2019 to May 2021. The patients were followed up for a period of 6 months.

## **RESULTS:**

In our study, there were 11 male and 14 female patients. Most common mode of injury was trivial trauma. The primary total hip arthroplasty in fracture neck of femur in elderly population provided a mean HHS of 81.1 at the end of 1 month, 83.9 at the end of 3 months and 85.7 at the end 6 months. The functional outcomes obtained were excellent results in 32%, good results in 52%, fair results in 12% and poor result in 4% of the study population, with a 'p value' of 0.045.

**CONCLUSION:**

The key to success lies in selecting patients who are active, independent, mobile pre-injury, motivated and in a sound mental state. We recommend the total hip arthroplasty as a primary procedure in elderly patients with fracture neck of femur for better function of the hip and to avoid further revisions in patients with long life expectancy.

**KEYWORDS:** Total hip arthroplasty, Total hip replacement, Neck of femur fracture,

Modified Harris hip score

## INTRODUCTION

Hip fractures caused by osteoporosis have become a leading source of morbidity and mortality in the adult and elderly populations worldwide. Hip fractures are becoming a major concern in Asia, owing to a 2–3 fold increase in their occurrence in nearly every country on the continent.(1) Hip fractures are expected to increase from 1.66 million in 1990 to 6.26 million in 2050. Apart from increased urbanisation in Asia, there has also been an increase in the share of the elderly population as the average life span has increased.(1)

By the year 2050, it is expected that more than half of these fractures will be centred in Asia due to changing global population dynamics. Widespread Vitamin D and calcium deficiency, disregard for osteoporosis, alcohol intake, smoking, reduced physical activity levels, obesity, and migration status are all risk factors for hip fracture.

According to the 2001 census, there are around 163 million Indians over the age of 50, with that figure anticipated to rise to 230 million by 2015. Even the most conservative estimates show that 20 percent of women and 10-15 percent of males are osteoporotic. As a result, the total population affected would be roughly 25 million people. If reduced bone density is found to be associated with a higher risk of fracture, as projected, the number might rise to 50 million.(2)

Hip fractures can be intracapsular (involving the femur neck) or intertrochanteric. Both have a similar incidence. Intracapsular fractures, on the other hand, are three times more prevalent in women than in men.(3) Normal locomotion necessitates a stable, pain-free, and mobile hip. Unsuitable for reduction and primary fixation, displaced subcapital and intracapsular femoral neck fractures are usually treated with an arthroplasty procedure.

Hip hemiarthroplasty, either cemented or uncemented, or total hip replacement may be performed. In competent, medically fitter (ASA [American Society of Anaesthesiologists]

grades 1-2), 'high demand', active individuals, the results of hip hemiarthroplasty have been proven to be inferior to total hip replacement.(4)

Total hip replacement has several advantages, including an extended implant life and a lower risk of revision surgery, making it ideal for patients with a longer life expectancy. Primary total hip replacement (THR) has greatly improved the quality of life by significantly improving both immediate and long-term pain and function. Many studies have shown that functional improvements in gait and range of motion can be achieved. Total hip arthroplasty (THA) is now the most routinely performed joint replacement procedure, and the demand for THA is predicted to grow significantly in the future.

We have hereby conducted the study to evaluate the functional outcome of primary Total Hip Arthroplasty in elderly patients with fracture neck of femur.

## **AIM OF THE STUDY**

The aim of the study is to assess the functional outcome of primary total hip arthroplasty in elderly patients with fracture neck of the femur.

## **OBJECTIVES OF THE STUDY**

- To analyze the functional outcome of primary total hip arthroplasty in elderly patients with fracture neck of the femur by using modified Harris Hip Score.
- To facilitate early weight bearing, mobilization, and rapid rehabilitation after surgery.
- To avoid complications and multiple surgeries.

## REVIEW OF LITERATURE

The total hip arthroplasty (THA) procedure is regarded as one of the most successful orthopaedic procedures of its time.(5)

More than 400 years ago, Ambrose Pare, a great French surgeon, recognised the existence of hip fractures. Sir Astley Cooper was the first to distinguish between femoral neck fractures, also known as intracapsular fractures, and other hip fractures and dislocations.(6) In FEMUR NECK FRACTURE, Philips presented a technique for longitudinal and lateral traction to minimize shortening and deformity in 1867.

The first attempts at hip replacement were documented in Germany in 1891, and the results were reported at the 10th International Medical Conference. Professor Themistocles Glück demonstrated how ivory could be used to replace femoral heads in patient's affected with tuberculosis of the hip joint.(5)

Later, in the late 19th and early 20th centuries, surgeons experimented with interpositional arthroplasty, which required inserting various tissues (fascia lata, skin, pig bladder submucosa) between the articulating hip surfaces of the arthritic hip.(7)

There are five key milestones in the history of hip arthroplasty:

1. Osteotomy,
2. Inter Positioning Arthroplasty,
3. Reconstructive Arthroplasty,
4. Hemi Arthroplasty and
5. Total Replacement Arthroplasty.

In 1925, Marius Smith-Petersen, an American surgeon, developed the first glass mould arthroplasty. This was made up of a hollow hemisphere that fit over the femoral head and provided a new smooth movement surface. Despite the fact that glass is a biocompatible material, it shattered when subjected to the tremendous stresses that pass through the hip joint.(8) Marius Smith-Petersen and Philip Wiles went on to test the current material of choice, stainless steel, to develop the first total hip replacement with bolts and screws fixed to the bone.(9)

English surgeon George McKee was the first to adopt a metal-on-metal prosthesis on a regular basis. In 1953, he started with a modified Thompson stem (a cemented hemiarthroplasty used to treat femur neck fractures) and a new one-piece cobalt-chrome socket as the new acetabulum. This prosthesis had a decent survival rate, with one research reporting a 74 percent 28-year survival rate.(10) However, by the mid-1970s, this procedure had become unpopular due to the local impact of metal particles seen during revision surgery for prosthetic failure.(11)

The contemporary THA is credited to the orthopaedic physician Sir John Charnley, who worked at the Manchester Royal Infirmary. In concept, his low friction arthroplasty from the early 1960s is identical to the prostheses used today. A metal femoral stem, a polyethylene acetabular component, and acrylic bone cement - which was taken from dentists - were the three components. Because Charnley advocated for the use of a small femoral head with a lower surface area, it was dubbed the low friction arthroplasty.(12)

As the number of successful procedures has grown, techniques have become more standardised, and the average age of people undergoing hip replacements has decreased. As a result, the concerns of implant failure owing to bearing wear were magnified. As a result, a range of bearings and procedures are currently being explored in an attempt to discover the greatest balance of problems and long-term survival.

## METAL ON POLYETHYLENE

Metal-on-polyethylene (M-on-PE) bearings are the most often used and heavily scrutinized of all prostheses, accounting for the vast majority of THA procedures.(13) Polyethylene-based implants pretty much totally displaced all other bearing surfaces, thanks to the early success of the Charnley prosthesis in the 1970s. So much so that much of the study was dedicated entirely to refining design and implantation techniques for the M-on-PE prosthesis.(14)

PE debris, which causes periprosthetic osteolysis by releasing cytokines and proteolytic enzymes, is the chief concern for M-on-PE prostheses, which can lead to implant failure.(15) PE wear debris is now being attributed for the majority of total joint arthroplasty failures, resulting in a higher rate of hip revisions due to aseptic loosening. Although implant failure has rekindled interest in metal-on-metal bearings, debris can be reduced by irradiating PE with gamma particles, considerably enhancing the material's wear resistance.

## METAL ON METAL

After falling out of favour in the 1970s, metal-on-metal (M-on-M) prostheses are making a comeback. Concerns had previously been raised about the bearings' ability to create metal ions (metallosis), which could be carcinogenic, as well as related hypersensitivity reactions and prosthetic loosening. Poor design and inappropriate implantation method, rather than the M-on-M bearings themselves, are now regarded to be the cause of aseptic loosening in first generation versions. M-on-M prosthesis have been shown to have 60 times less wear than traditional M-on-PE prostheses.(16)

However, because metal femoral heads are less brittle than other materials, they can have a bigger diameter, which improves joint stability and reduces the risk of dislocation in these



arthroplasties.(17) In comparison to polyethylene implants, M-on-M implants minimise osteolysis and peri-prosthetic inflammatory tissue.(18)

Long-term implications of metal ions liberated in M-on-M bearings are unknown, with cobalt and chromium ion blood levels 3-5 times greater than in patients with M-on-PE prostheses. Furthermore, because of the wear characteristics of M on M implants, many patients who receive them are younger, potentially lengthening the total length of the exposure to these metal ions over their lifetime.(19)

## CERAMIC ON CERAMIC

Ceramic heads were first used in hip arthroplasties in Central Europe in 1970 by French surgeon Pierre Boutin, but they are used far less frequently in the United Kingdom and the United States.(13)(18) The ceramics used in orthopaedics are either alumina or zirconia, and were developed to solve the problems of friction and wear noted in other materials. In comparison to metal or PE variants, ceramic-on-ceramic (C-on C) bearings have a higher level of hardness, scratch resistance, and debris inert nature.(20)

Additionally, these hydrophilic prostheses promote lubrication, resulting in a decreased coefficient of friction and superior wear resistance.(21) As a result of the reduced wear, C-on-C bearings are a good choice of implant in young, active patients. Fracture risk in first-generation alumina ceramic bearings has been widely documented. Chipping of the contact surfaces during prosthesis insertion or dislocation owing to the small femoral heads utilised in ceramic implants can result in devastating third body wear, hence surgical insertion technique is critical.

## HYBRID PROSTHESES

A hybrid hip prosthesis is made up of a cemented femoral stem and an acetabular cup that is cemented in place. This is an excellent alternative for young, active patients since it minimizes pelvic bone loss, which aids with revision, while still offering good fixation and

function. In younger patients, a large research in Norway found that hybrid devices outperform cemented socket in terms of survival.(22)

## CEMENTLESS TECHNIQUES

Glück described cementing hip arthroplasties in 1891, using methacrylate bone cement to improve prosthetic fixation, but it was Charnley in the late 1950s who popularised the technique using a cement obtained from dentists. Cementing often failed between these dates, so attention was focused on developing cementless techniques. The purpose of cement is to act as a grout rather than a glue to improve the fit and, theoretically, the longevity of the prosthesis. Cementless prostheses have a special coating, hydroxyapatite, that allows bone ingrowth and thus prosthesis fixation.

Cementless techniques make hip revision surgery easier to plan, especially for younger patients, because they preserve more bone structure. However, cemented procedures had superior short- to medium-term clinical outcomes than uncemented approaches, with no radiological differences.(23) Due to a dearth of large randomised controlled studies, long-term comparisons are difficult to make.

- In 2010, April, Colin Hopley, et al., in their meta- analysis concluded that single stage total hip arthroplasty may lead to lower revision rates and better functional outcomes when compared with hemiarthroplasty in elderly patients with displaced fracture of the femoral neck.(24)
- In 2011, Carl Johan Hedbeck, et al., in their randomized trial, results confirm the superior results in terms of functional outcome and health-related quality of life after total hip arthroplasty as compared with bipolar hemiarthroplasty in elderly, mentally sound patients with a displaced fracture of the femoral neck. The results of this study and

previous studies imply that a total hip arthroplasty should be the preferred method of treatment for this fracture in an active elderly patient with a long life expectancy.(25)

- In 2012, March, Liang Liao, et al., in their meta-analysis, concluded that Total hip arthroplasty is associated with better functional outcome and lower reoperation rate than hemiarthroplasty in treatment of displaced femoral neck fractures in the elderly patients. (26)
- In 2014, Iftikhar H. Wani et al., in their study of 100 patients affected by displaced fracture of the femoral neck, concluded that Primary total hip arthroplasty when compared with other modalities of fixation, appears to be a reasonably safe method of treating displaced fracture of femoral neck in elderly patients. They also concluded that functional outcome is generally better after total hip arthroplasty compared with other modalities of fixation.(27)
- In 2015, Sriram T. et al., in their study of 23 patients, excellent results were obtained in 31%, good results in 65% and fair results in 4%. None of the patients had a poor result. 91% of the patients were pain free and independently mobile at the last follow up. Therefore they concluded that primary THA is a viable option for treatment in a selected group of previously independently mobile patients.
- In 2015, Mani, et al., Total hip arthroplasty for displaced femoral neck fractures in elderly patients. *Orthop Muscular Syst.* 2015 Dec;4:204. concluded that Total hip arthroplasty is a suitable alternative for senior patients over 65 who are independently mobile, cognitively sound, and have a displaced femoral neck fracture. It has greater rehabilitation potential, hip function, and a low revision rate.(28)
- In 2017, Jayaram and Shivananda, *Indian Journal of Orthopaedics Surgery* 2017;3(3):245-251. 245. concluded that primary total hip arthroplasty improves the functional ability in terms of gait and range of movements.(29)

- In 2018, Sudesh Sharma, et al., JMSCR Vol||06||Issue||12||Page 640-645||December concluded that THA is better than hemiarthroplasty for fracture neck of femur in patients with active pre-injury ambulatory status and long-life expectancy.(30)
- In 2018, May, Zhong Wang and Timothy Bhattacharyya, in their cohort study concluded that patients treated with hemiarthroplasty following femoral neck fractures had significantly lower proportional hazard of reoperation than those treated with total hip arthroplasty. Total hip arthroplasty may be associated with lower mortality.(31)
- In 2019, August, Daniel P. Lewis, Daniel Waever, et al., in their systematic review and meta – analysis, concluded on overall, THA appeared to be more beneficial than HA. THA should be the first-line treatment for DFNF in patients with a life expectancy of more than four years and who are under the age of 80. In patients beyond the age of 80 and with a decreased life expectancy, both HA and THA are appropriate procedures.(32)
- In 2019, September, Fahad S et al., in a retrospective cohort study, concluded that in relatively young and active elderly patients with displaced neck of femur fracture, a THA with dual mobility cuff provides better hip functional outcome, does not increase mortality or morbidity as compared to BHA and can be considered as primary treatment modality.(33)
- In 2020, Rohit Amar et al., in a study of 120 patients concluded that the total hip arthroplasty gave better results in displaced Intracapsular neck of femur fractures radiologically.

## **SURGICAL ANATOMY(34–36)**

The femoral head and the acetabulum comprise the hip joint, which is a multiaxial synovial ball and socket joint.

### **DEVELOPMENT**

The femur begins to develop between the 5th to 6th gestational week by way of endochondral ossification. While several ossification centres appear throughout intrauterine life, the bone continues to develop through childhood and early adolescence. Between the ages of 14 and 18, the ossification of the femur is completed.

### **OSSEOUS ANATOMY**

The head, neck, and greater and lesser trochanters make up the proximal femur. The femur's head is smooth and constitutes two-thirds of a spherical. It is directed medially, superiorly, and slightly anteriorly to fit into the acetabulum. Except for the fovea, the surface is covered in articular cartilage. The fovea is located slightly inferior and posterior to the centre of the femoral head.

The diameter of the femoral head varies depending on the individual's build and ranges from 40 to 60 mm. The femoral neck is a flattened pyramidal piece of bone that connects the head and shaft. It extends obliquely infero-laterally from the femoral head to meet the femoral shaft. The posterior surface is broader and more concave than the anterior surface.

The anterior surface of the neck is separated from the femoral shaft by the intertrochanteric line, a roughened, broad band of bone. The intertrochanteric crest, a prominent ridge, connects the two trochanters posteriorly.

The greater trochanter is a large, irregular, quadrilateral eminence, projecting from the junction of the neck and body. It serves as an attachment for several muscles of the gluteal region. The lesser trochanter is a conical eminence that projects from posteromedial surface of the femur at the inferior end of the intertrochanteric crest.

The calcar femorale is a vertically oriented plate of compact bone that is situated amid cancellous bone. It originates in the posteromedial portion of the femoral shaft, radiates superiorly towards the greater trochanter, and fuses with the cortex of the posterior femoral neck. This structure provides mechanical strength to resist deforming forces.

## **MUSCLES AROUND THE HIP(35)**

### **MUSCLES IN FRONT OF THE THIGH**

<b>Muscle</b>	<b>Origin</b>	<b>Insertion</b>	<b>Nerve supply</b>	<b>Action</b>
Psoas Major	Lateral surfaces of T12-L5 vertebrae and discs between them transverse process of all lumbar vertebrae	Lesser trochanter of femur	Ventral rami of lumbar nerves (L1, L2 and L3)	Flexion of hip
Iliacus	Iliac crest, iliac fossa, ala of sacrum, and anterior surface of sacroiliac joint	Tendon of psoas major, lesser trochanter	Femoral nerve(L2 and L3)	Flexion of hipjoint

Tensor fascia latae	Anterior superior iliac spine and anterior part of iliac crest	Ilio-tibial tract that attaches to lateral condyle of tibia	Superior gluteal (L4 and L5)	Abducts, medially rotate and flexes the hip; helps to keep knee extended
Sartorius	Anterior superior iliac spine	Superior part of medial surface of tibia	Femoral nerve (L2 and L3)	Flexes, abducts, and laterally rotates hip joint; flexes knee joint
<b>QUADRICEPS FEMORIS</b>				
Rectus Femoris	Anterior inferior iliac spine and ilium superior to acetabulum	Base of patella and by patellar ligament to tibial tuberosity	Femoral nerve (L2, L3, and L4)	Extension of knee joint, rectus femoris also steadies hip joint and helps iliopsoas to flex the hip
Vastus lateralis	Greater trochanter and lateral lip of linea aspera of			

	femur			
Vastus intermedius	Anterior and lateral surfaces of shaft of femur			
Vastus medialis	Intertrochanteric line and medial lip of linea aspera of femur			

#### MUSCLES OF THE GLUTEAL REGION

Muscle	Origin	Insertion	Nerve supply	Action
Gluteus maximus	Surface of ilium, posterior to posterior gluteal line, dorsal surface of sacrum and coccyx and sacrotuberous ligament	Most fibres end in iliotibial tract that inserts lateral condyle of tibia, some fibres insert on gluteal tuberosity of femur	Inferior gluteal nerve (L5, S1 and S2)	Extension and lateral rotation of hip, steadies hip and assists in raising trunk from flexed position



Gluteus medius	External surface of ilium between anterior and posterior gluteal line	Lateral surface of greater trochanter of femur	Superior gluteal nerve (L5 and S1)	Abduction and medial rotation of hip, steadies pelvis on lower limb when opposite leg is raised
Gluteus minimus	External surface of ilium between anterior and inferior gluteal line			
Obturator internus	Anterior surface of sacrum and sacrotuberous ligament	Superior border of greater trochanter of femur	Nerve to obturator internus (L5 and S1)	External rotators of hip
Superior and inferior gemelli	Pelvic surface of obturator membrane and surrounding bones	Medial surface of greater trochanter of femur	Superior gemelli-nerve to obturator internus	

			Inferior gemelli– nerve to quadratus femoris	
Quadratus femoris	Lateral border of ischial tuberosity	Quadratus tubercle on intertrochanteric crest of femur and inferior to it	Nerve to quadratus femoris (L5 and S1)	

### MUSCLES POSTERIOR TO THE HIP

Muscle	Origin	Insertion	Nerve supply	Action
Semitendinosus	Ischial tuberosity	Medial surface of superior part of tibia	Tibial division of sciatic nerve (L5, S1 and S2)	Extension of hip, flexion of knee and medial rotation of knee
Semimembranosus	Ischial tuberosity	Posterior part of medial condyle of tibia		

Biceps femoris	Ischial tuberosity: linea aspera and lateral supracondylar line of femur	Lateral side of fibular head	Sciatic nerve (L5, S1 and S2)	Extension of hip, flexion and lateral rotation of knee
----------------	--	------------------------------	-------------------------------	--

### MUSCLES MEDIAL TO THE HIP

Muscle	Origin	Insertion	Nerve supply	Action
Pectineus	Superior ramus of pubis	Pectineal line of femur, just inferior to lesser trochanter	Femoral nerve (L2 and L3); may receive a branch from obturator nerve	Adducts, flexes and medially rotates the hip
Adductor longus	Body of pubis, inferior to pubic crest	Middle third of linea aspera of femur	Anterior branch of obturator nerve (L2, L3 and L4)	Adducts the hip
Adductor brevis	Body and inferior ramus of pubis	Pectineal line and proximal part of linea	Obturator nerve (L2, L3 and L4)	Adducts the hip, and some extent flexes the hip

		aspera of femur		
Adductor magnus	Inferior ramus of pubis, ramus of ischium, adductor part from ischial tuberosity	Adductor part – gluteal tuberosity, linea aspera, medial supracondylar line Hamstring part – adductor tubercle of femur	Adductor part – obturator nerve (L2, L3 and L4) Hamstring part – tibial part of sciatic nerve (L4)	Adducts the hip Adductor part also flexes hip and hamstring part extend the hip
Gracilis	Body and inferior ramus of pubis	Superior part of medial surface of tibia	obturator nerve (L2, L3)	Adducts the hip, flexes the hip and its hamstring part extend the hip
Obturator externus	Margins of obturator and obturator membrane	Trochanteric fossa of femur	obturator nerve (L3 and L4)	Laterally rotates hip, steadies head of femur in acetabulum

## LIGAMENTS

Transverse acetabular ligament	Attached to the free edges of the acetabular labrum.
Ligament of head of femur	Attached to the fovea of the femoral head and the center of the acetabulum.
Pubofemoral ligament	Attached to the obturator crest and membrane, the iliopubic eminence, and the superior pubic ramus; blends with the iliofemoral ligament distally.
Iliofemoral ligament	Proximally inserted between the anterior superior iliac spine and the acetabular rim; distally attached at the intertrochanteric line. Also known as the Y ligament of Bigelow and the ligament of Bertin.
Ischiofemoral ligament	Arising from the greater trochanter to the ischium. Supports the joint posteriorly. Comprised of medial, lateral, and central bands.

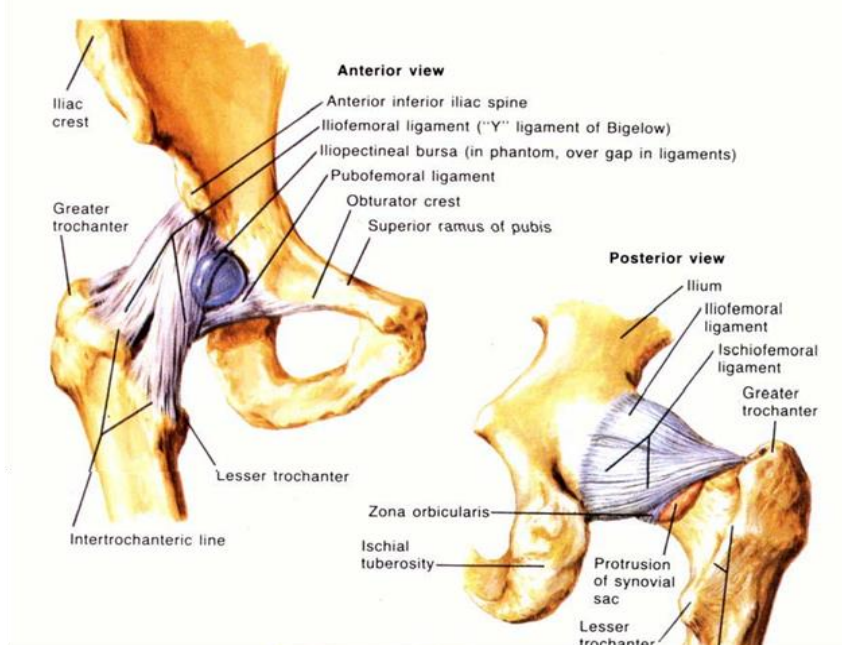


Fig.1: Ligaments around the hip joint

# **BLOOD SUPPLY OF THE PROXIMAL FEMUR**

## **ARTERIAL SUPPLY:**

Extra capsular arteries to upper end of femur (entering the trochanters and base of neck) arise from,

1. Medial circumflex femoral artery. (Which branch into)
  - a. Lateral epiphyseal artery
  - b. Superior metaphyseal artery
  - c. Inferior metaphyseal artery (supply head derived from metaphysic)
2. Lateral circumflex femoral artery
3. Superior gluteal artery
4. Obturator artery, Medial epiphyseal artery (artery of ligamentum teres branch from acetabular artery).
5. First perforating branch of profunda femoris artery.

Most of the vascular supply to the femoral head comes from the posterior medial and lateral femoral circumflex arteries, which form an extracapsular ring about the femoral neck. The lateral epiphyseal artery has been shown to provide the majority of the blood supply. Trueta and Harrison showed this in their high-quality injection study of 15 femoral heads using barium suspensions examined in 15-um sections studied with light microscopy.

Their study found the lateral epiphyseal artery to supply 80% of the femoral head, 67 % in seven cases, and greater than 50 % in one case. The inferior metaphyseal artery is the terminal branch of ascending portion of the lateral femoral circumflex artery, which pierces the mid portion of the anterior hip capsule. This vessel supplies the distal most portion of metaphyseal bone anteriorly.

The third important blood supply to the femoral head comes from the medial epiphyseal artery of the ligamentum teres, however it usually perfuses only the perifoveolar area and rarely supplies a significant area of the head.

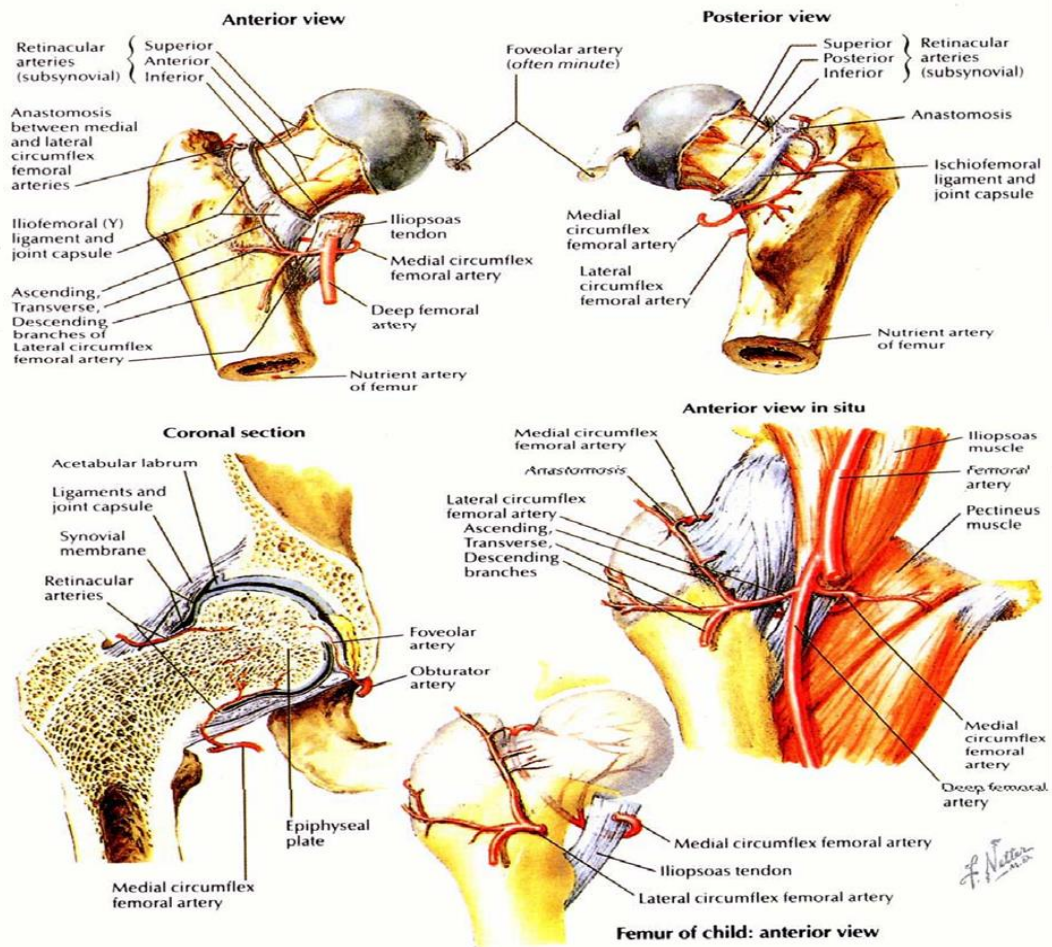


Fig.2: Blood supply of proximal femur

## **VENOUS SUPPLY:**

Capsular veins run inferomedially along the trochanteric line before draining into the obturator vein through the obturator foramen. Circumflex veins form a diffuse plexus in the base of the neck and greater trochanter, exiting at the lesser trochanter to enter the femoral vein. Smaller veins on the back of the neck and in the greater trochanter lead to plexuses in the ischial tuberosity and greater sciatic notch. Linea aspera veins provide for minimal venous drainage.

## **NERVE SUPPLY TO HIP JOINT**

According to Hilton's rule: The nerve that supplies a muscle acting across a joint supply the joint itself and the skin over the joint.

**Primary:** Direct branches from adjacent nerve trunks.

- Posterior articular nerve, branch of nerve to quadrates femoris, enters posterior capsule of the joint, and is the most important branch.
- Medial articular nerve, a branch from anterior division of obturator nerve through its lateral branch to pectineus and adductor muscles and supply the anteromedial and inferior aspect of joint capsule.
- Nerve to ligamentum teres, a branch from posterior division of obturator nerve which supplies to obturator externus muscle.

**Accessory:** From nerves within muscles related to joint, supply a small portion of hip joint and arise mainly from femoral nerve through nerve to pectineus.



## KINESIOLOGY OF HIP JOINT

<b>MOVEMENT</b>	<b>MUSCLES (Prime Movers and Assisted by)</b>	<b>AXIS</b>
Flexion	Psoas major, Iliacus, Pectineus, Rectus femoris, Sartorius, Adductor Longus (in early flexion from full extension)	Along the centre of femoral neck (pure spin)
Extension	Gluteus maximus, Posterior hamstrings	Along the centre of femoral neck (pure spin)
Abduction	Gluteus medius and minimus Tensor fasciae latae sartorius	Antero-posterior through femoral head
Adduction	Adductors longus, brevis and magnus, Gracilis, Pectineus	Antero-posterior through femoral head
Medial Rotation	Tensor fasciae latae and Anterior fibres of Gluteus, medius and minimus	Vertical axis through centre of femoral head and lateral condyle with foot stationary on the ground
Lateral Rotation	Oburator Externus and Internus, Gemelli, Quadratus femorus, Assisted by Piriformis, gluteus	Vertical axis through centre of femoral head and lateral condyle with foot stationary

	maximus and Sartorius.	on the ground.
--	------------------------	----------------

## TRABECULAR ANATOMY

The orientation of trabeculae can be observed by sectioning the femur in the frontal plane.

There are 2 principle trabecular systems.

1. **Principle compressive trabeculae:** These arise from the femoral shaft's medial cortex and ascend into the femoral head's weight-bearing dome. These trabecular systems are the most dense and powerful of all the trabecular systems. They make a 160 degree angle with the shaft's medial cortex (trabecular angle).
  
2. **Principle tensile trabeculae:** These run from the interior of the foveal area to the trochanter and therefore to the lateral femoral cortex, passing via the head and superior section of the femoral neck. These are caused by the shearing stresses that the upper end of the femur is subjected to. These trabeculae only transfer a little amount of the body's weight.

In addition, there are secondary trabecular systems in the trochanteric region, they are:

3. **Secondary compressive group:** These extend from the medial femoral cortex to the greater trochanter.

**4. Secondary tensile group:** These extend from the lateral femoral cortex into the middle of the neck.

**5. Trochanteric group:** These are arranged vertically within the greater trochanter.

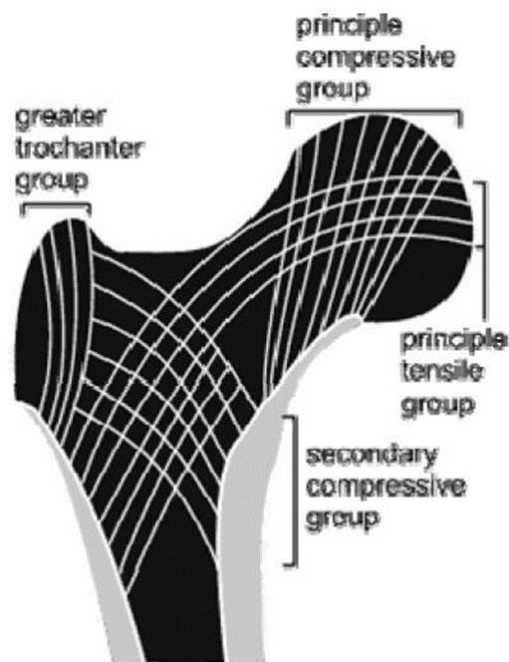


Fig.3: Trabeculae of proximal femur

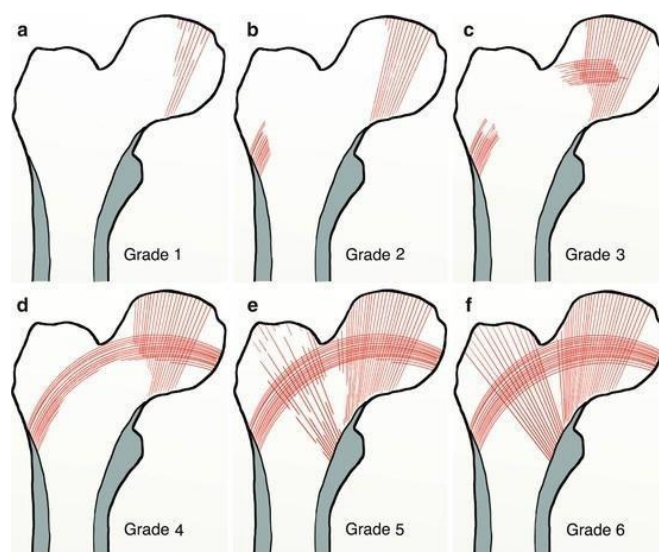


Fig.4: Singh & Maini index with Gr.1 Representing severe osteoporosis & Gr.6 normal bone.

## **BIOMECHANICS OF THE HIP JOINT(37,38)**

The hip joint is a ball and socket joint. Regardless of the location of the pelvis, forces are delivered to the head and neck of the femur at an angle of 165 to 170 degrees during weight bearing. Because of the strong muscles that extend across the hip, it can withstand high loads. The shaft bends due to the leverage of the femoral head and neck under loading.

Compressive stress is generated medially, while tensile stress is generated laterally, as a result of the bending forces. Compressive forces are more powerful than tensile forces. This is known as the "Bending Movement." The bending movement is larger when the lever arm is longer. Bending movement is a significant contributor to varus deformity, implant stress fractures, and non-union.

In the Sagittal plane, flexion spans from 0-140 degrees and extension ranges from 0-15 degrees. Adduction is 0-30 degrees in the frontal plane, and abduction is 0-45 degrees. Internal rotation in transverse plane motion varies from 0 to 30 degrees, while external rotation spans from 0 to 40 degrees. The abductors (Gluteus medius and minimus) abduct the proximal segment, which is flexed by the iliopsoas and externally rotated by the short external rotators.

Even at rest, these muscle forces act on the fixation device following the operation. The fulcrum of the hip joint is the centre of the hip, and the forces acting on it are body weight and abductor muscle tension. Because the distance between the trochanter and the femoral head's centre is shorter than the distance between the body's midline, the abductors must apply more force than the body's weight to maintain the pelvis balanced.

The variation in neck shaft angle will influence the relative ratio of the lever arm distance between the midline and the femoral head and the trochanter and will

there by influence the efficiency of the abductor muscles, even the hip is in valgus, the short abductor lever arm requires tremendous pull of the hip to balance the pelvis. The abductors will not have to work as hard to keep the pelvis balanced in the varus position.

An average hip joint reaction force of 4 times body weight occurs shortly after heel strike in males, with another peak of 7 times body weight during toe off, according to research. The magnitudes of joint reaction forces are smaller in females, with the first peak being around 2.5 times body weight and the second peak being at 4 times body weight.

Standing on one leg generated a force 2.5 times one's own weight in the hip, according to Rydell. At rest, each hip joint was subjected to half the body weight, however standing with the hip and knee flexed 90 degrees raised the force to rear body weight across the flexed hip. Running boosts the force to five times that of the body's weight. A force of 1.5 times body weight is applied to the hip joint when lifting a leg from a supine posture with the knee straight.

### **Neck lengths and offsets**

- a) Vertical offset - the distance between a fixed bony point, such as the lesser trochanter, and the femoral head's centre. To avoid limb length discrepancy, this distance must be restored. It is calculated using the modular head length plus the base length of the prosthetic neck.
- b) Horizontal offset - The distance between the line along the axis of the stem and the centre of the femoral head is known as horizontal offset. Inadequate horizontal offset restoration shortens the abductor lever arm, which leads to eventual limp, bone impingement, and dislocation. Excessive offset causes stem loosening and breaking in the future. By lowering the neck stem angle or moving the neck to a more medial location, offset can be increased without limb lengthening.

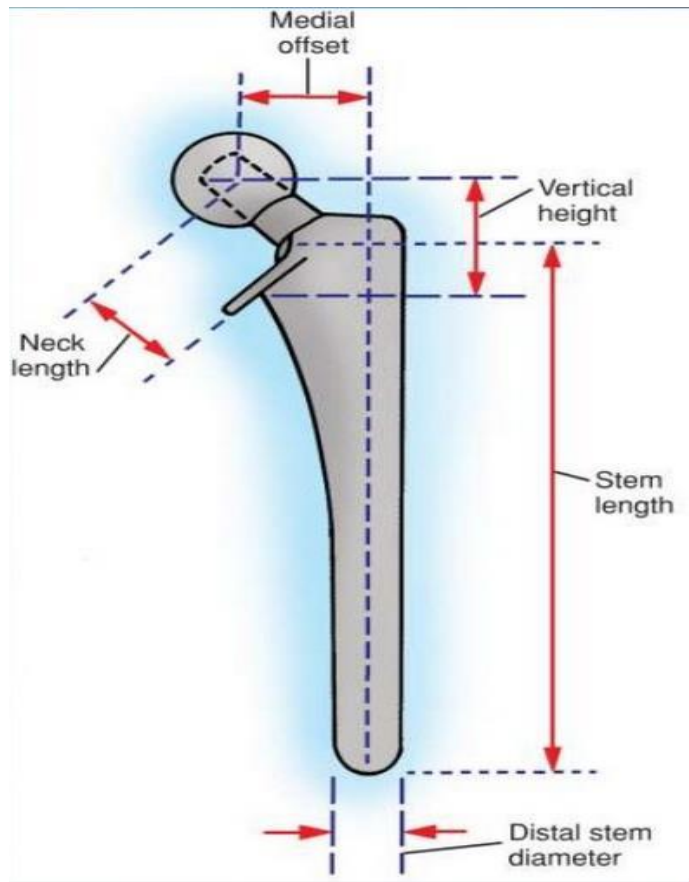


Fig.5: Neck length and offset measurements

c) Version - refers to the neck's orientation in relation to the coronal plane. It's classified as either anteversion or retroversion. It's crucial for the implant's long term stability.

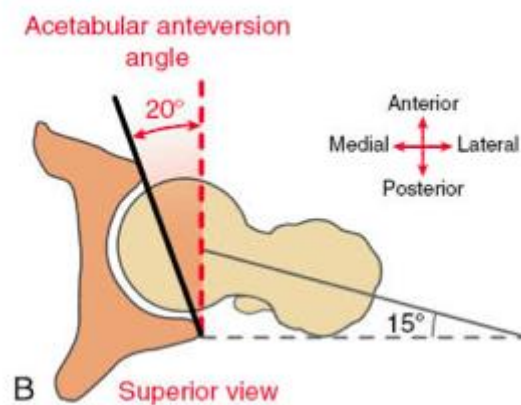


Fig.6: Version angle

- d) The "jump distance" is the distance the head must travel to exit the socket rim, which can be increased by using a large diameter head. Higher jump distance leads to increased hip movement.

## **PATHOMECHANICS OF INJURY**

Femur Neck Fractures are unusual in young persons with good bone structure and in races wherein osteoporosis is uncommon, such as African Americans and South African Bantu.(39) Femur Neck Fractures are more prevalent in elderly women than in men.(40) By the age of 65, 50% of women develop osteoporosis, and by the age of 85, the fracture threshold has decreased to the point where 100% of women's fracture threshold is below the needed bone mineral content.(41)

The suggested mechanism of injury are:

- Direct blow or trauma to the greater trochanter during a fall
- Increased tension in the anterior capsule and iliofemoral ligaments caused by sudden external rotation of the leg.
- Micro- and macro-fractures being caused by cyclical loading.(42)

Even within physiological limits, forces produce fractures in osteoporotic bone. A stress fracture of this type becomes complete after a minor torsional injury preceding the fall, which the patient often identifies with the fracture. Muscle forces produce an axial load along the longitudinal axis of the femoral neck, and coupled with external pressure, help to determine the fracture pattern.(43)

### **MECHANISM OF BONE FAILURE:**

If a structure is overloaded, it will fail. If the system is unable to absorb the energy provided to it, a situation like this could arise. Overloading of the hip joint can be caused by a variety of separate but often interrelated events. The following factors are important:



- A. Impact of falls
- B. Impairment of energy absorbing mechanisms
- C. Strength of bone

### **IMPACT OF FALLS:**

In the standing position, the body has a significant quantity of potential energy. Falling converts potential energy to kinetic energy, which must be absorbed by the body's structures upon collision with the floor to avoid a fracture. There is enough potential energy in the standing body to break any bone in the body if it is not absorbed when falling. The amount of potential energy to be observed in a fall in an average-sized woman is around 4000kg/cm, while the energy absorbing capability of the upper end of the femur is only 60kg/cm. Thus, the energy-absorbing mechanisms must function if a bone injury is to be avoided.

### **Impairment of energy absorbing mechanisms:**

Active muscular contraction is the primary source of energy dissipation. This dissipation takes time, and in the case of high-speed trauma, there isn't enough time for muscle contraction to absorb energy before the bone is overloaded, resulting in failure. The neuromuscular response may be delayed in the elderly, and hence energy absorption may be insufficient to prevent a fracture.

In the elderly, the typical protective muscular contraction in the event of a slip rather

than a fall may result in an uninhibited muscle contraction around the hip, resulting in a force of up to 600kg/cm, which can fracture the neck of the femur without involving any other factors.

### **Strength of bone:**

Bone decreases to roughly a quarter of its usual strength and has a decreased energy absorbing capability in osteoporosis or osteomalacia, leading to failure.(42)

## **CLASSIFICATION OF FEMUR NECK FRACTURES(36)**

### **ANATOMICAL CLASSIFICATION**

The first anatomical classification of fracture neck of femur was done by Sir Astely Cooper in 1823. He classified them into.

- a. Intracapsular and
- b. Extracapsular fractures

Intracapsular fracture are again classified as

1. Subcapital fracture
2. Transcervical fractures

### **PAUWELL CLASSIFICATION**

Pauwels divided Femur Neck Fracture based on the plane of the neck fracture.

- Type I fracture subtends an angle of 30 degrees or less.

- Type II fractures are between 30 and 50 degrees, and
- Type III fractures are greater than 50 degrees

The prognosis is linked to the angle of the fracture plane; as the angle increases, the fracture becomes more unstable, and difficulties with fracture healing and fixation become more common.

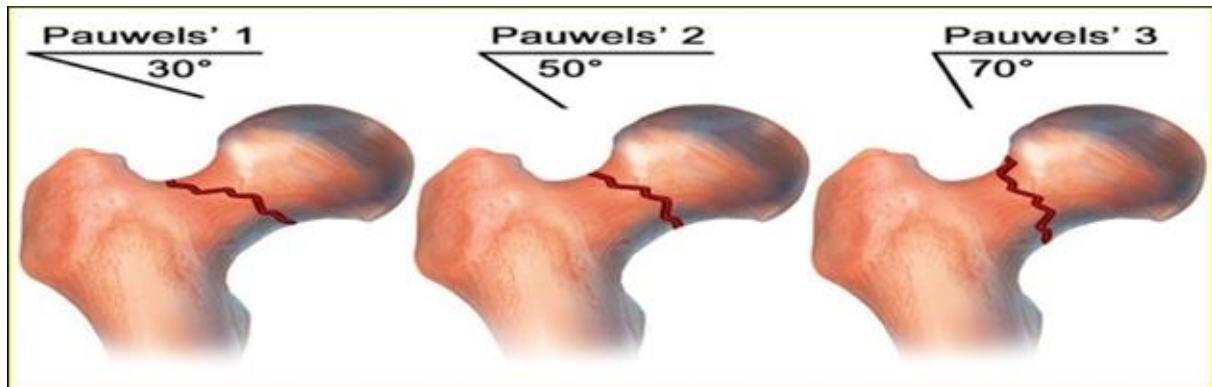


Fig.7: Pauwells' classification of femur neck fracture

## GARDEN CLASSIFICATION

Garden proposed a classification system based on the degree of displacement, which is judged on the AP radiograph by determining the relationship of the trabecular lines in the femoral head to those in the acetabulum.

- **Type I - Valgus-impacted subcapital fracture.**

The fracture is incomplete with a lateral fracture line that does not breach the medial cortex. The trabecular lines in the femoral head therefore form an angle with those in the acetabulum.

- **Type II - The fracture is complete but undisplaced**

The trabecular lines in the head are colinear with those in the acetabulum and the femoral neck distal to the fracture.

- **Type III - Incompletely displaced fractures.**

The femoral head has not lost contact with the femoral neck, but the head is varus and extended, resulting in angulation of the trabecular lines. The angulation is in the opposite direction to that described for Garden I fractures.

- **Type IV - Completely displaced**

The trabecular lines line up as the femoral head returns to a neutral position within the acetabulum. The femoral neck loses contact with the head and externally rotates, so the trabecular lines in the neck are not colinear with those in the head.

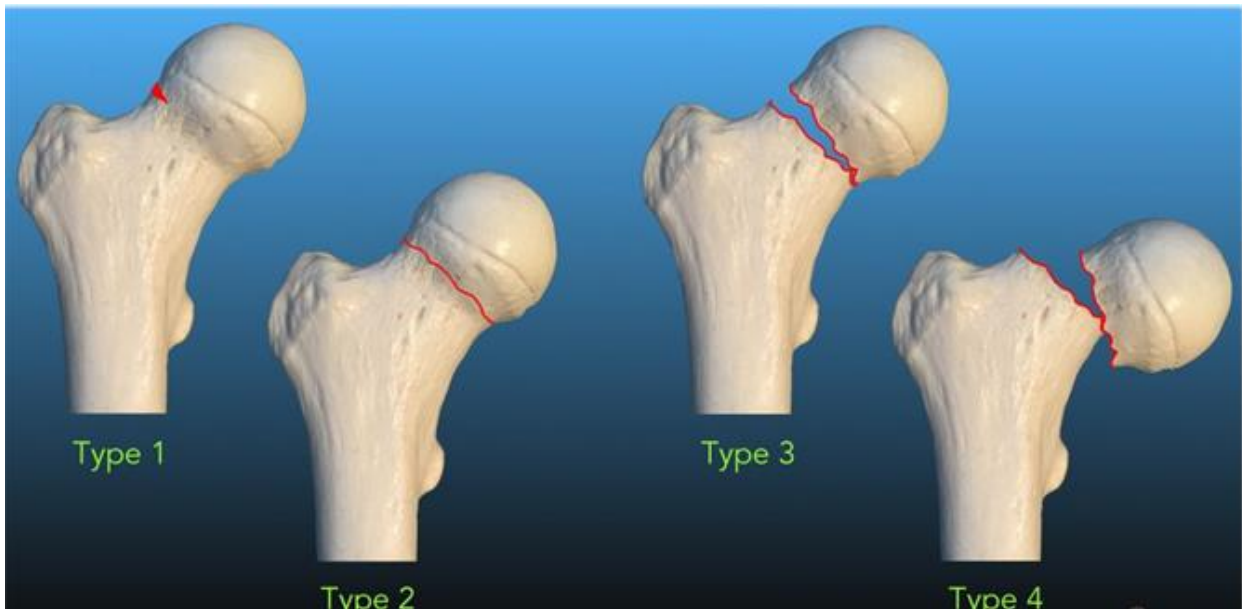


Fig.8: Garden's classification of neck of femur fracture

## A.O. CLASSIFICATION

A.O. classification of fracture neck of femur is based on modification of Pauwel's grading with further subdivision into subcapital, transcervical, basicervical and midcervical.

In this system the fractures of the femoral neck are classified as

<b>Type B1</b>	<b>Type B2</b>	<b>Type B3</b>
Subcapital with no or minimal displacement	Transcervical	Displaced sub capital fracture. Each of these types is further identified.
Type B3 have the worst prognosis		

The femoral neck is designated 31B.

The B1 group describes undisplaced femoral neck fractures,

The B2 transcervical fractures, and

The B3 category describes displaced subcapital fractures

31-B1 - Subcapital fracture

31-B1.1 – Valgus impacted

31-B1.2 – Undisplaced

31-B1.3 – Displaced

31-B2 – Transcervical fracture

31-B2.1 - Simple

31-B2.2 – Multifragmentary

31-B2.3 - Midcervical shear

31-B3 – Basicervical fracture

31-B3.1 - Mild displacement in varus and external rotation

31-B3.2 - Moderate displacement with vertical translation and external rotation

31-B3.3 - Marked displacement in varus with translation

## **CLINICAL FEATURES**

The typical presentation in an elderly person is a history of minor trauma, such as a slip in the restroom or while walking, inability to stand after the fall, and pain around the hip joint.

## **SYMPTOMS & SIGNS:**

- Pain in the groin, inner aspect of the thigh.
- Shortening and external rotation of the affected limb.
- External rotation of limb is not as extreme as seen in Intertrochanteric fractures or hip dislocation.
- Tenderness present over the anterior joint line of the hip joint.
- Range of movements are painful and restricted.

## **INVESTIGATIONS:**

1. Plain radiograph of the pelvis with both hips – AP view
2. Plain radiograph of the affected proximal femur – Cross table lateral view

Antero posterior views are important for determining the fracture pattern and extent, as well as the quality of the bone, and for identifying undisplaced and impacted fractures when compared to the contralateral side. The actual neck shaft angle is seen in an AP view with 10-15 degrees of internal rotation.

## **METHODOLOGY**

The present prospective study includes 25 cases with fracture neck of femur with finite population correction (N=200) in elderly patients above the age of 60 years irrespective of sex treated by total hip arthroplasty in the Department of Orthopaedics at Shri B. M. Patil Medical College Hospital and Research Centre, Vijayapura, between November 2019 to March 2021. The clearance has been obtained from ethical committee.

The study was carried out to evaluate the immediate and early results of total hip arthroplasty for fracture of neck of femur in elderly patients using modified Harris Hip Score.

### **INCLUSION CRITERIA**

1. Fracture neck of femur in patients above 60 years of age.
2. Patients who are medically fit.
3. Patients giving consent for proposed surgery.

### **EXCLUSION CRITERIA**

1. Active infection of hip joint.
2. Bone tumors involving proximal femur and acetabulum
3. Neuropathic hip joint.
4. Patients below 60 years of age.
5. Patients medically unfit for surgery.



Twenty five cases treated by total hip arthroplasty were followed up for 6 months. Once the patient was admitted to the hospital, all the essential information was recorded in the proforma prepared for this study. They were observed regularly during their hospital stay till they got discharged. They were asked to come for follow up regularly to the outpatient department. Those who could not come were contacted via phone. The follow up summary was recorded in the follow up chart of the proforma.

## Statistical methods used

All characteristics were summarized descriptively. For continuous variables, the summary statistics of mean±standard deviation (SD) were used. For categorical data, the number and percentage were used in the data summaries and diagrammatic presentation.

The difference of the means of analysis variables between more than two independent groups was tested by ANOVA and F test of testing of equality of Variance.

ANOVA				
Source	d.f.	SS	MS	F
Treatment	$a - 1$	$SS_{\text{treat}}$	$\frac{SS_{\text{treat}}}{a-1}$	$\frac{MS_{\text{treat}}}{MS_{\text{error(a)}}$
Error (a)	$N - a$	$SS_{\text{error(a)}}$	$\frac{SS_{\text{error(a)}}}{N-a}$	
Time	$t - 1$	$SS_{\text{time}}$	$\frac{SS_{\text{time}}}{t-1}$	$\frac{MS_{\text{time}}}{MS_{\text{error(b)}}$
Treat x Time	$(a - 1)(t - 1)$	$SS_{\text{treat x time}}$	$\frac{SS_{\text{treat x time}}}{(a-1)(t-1)}$	$\frac{MS_{\text{treat x time}}}{MS_{\text{error(b)}}$
Error (b)	$(N - a)(t - 1)$	$SS_{\text{error(b)}}$	$\frac{SS_{\text{error(b)}}}{(N-a)(t-1)}$	
Total	$Nt - 1$	$SS_{\text{total}}$		

The sources of the variation include treatment; Error (a); the effect of Time; the interaction between time and treatment; and Error (b). Error (a) is the effect of subjects within treatments and Error (b) is the individual error in the model. All these add up to the total.

If the p-value was  $< 0.05$ , then the results were considered to be statistically significant otherwise it was considered as not statistically significant. Data were analyzed using SPSS software v.23(IBM Statistics, Chicago, USA)and Microsoft office 2007.

## INVESTIGATIONS

- X-ray of pelvis with both hips AP view
- X-ray of hip AP view in 15 degrees of internal rotation
- X-ray of hip lateral view (if necessary)
- CT scan / MRI scan (if necessary)
- Complete haemogram.
- Bleeding time, Clotting time.
- Urine complete
- Random blood sugar, Blood urea and Serum creatinine.
- HIV, HCV and HbsAg.
- Blood grouping and Rh- typing.
- ECG.
- Chest X-ray
- Other specific investigations whichever needed.

### **Pre - Operative preparation:**

- Thorough medical history and general physical examination were done.
- Cardiopulmonary evaluation was done by physician and pre anesthetic evaluation was done by anesthetist.

- Patients received clearance from the ENT and Dental departments as well, to rule out potential foci of infection.
- Radiographs of the pelvis should be reviewed to estimate the size of the implant required.
- The patients were taken up for surgery after obtaining written and informed risk content of the nature and complications of surgery.
- Xylocaine test dose and tetanus toxoid injections were given pre operatively.
- The operative site was shaved and prepared with betadine scrub, few hours prior to the surgery.
- IV antibiotics [II/III generation cephalosporin] given prophylactically, a day before surgery and before induction of anesthesia.

## **IMPLANT DESIGN:**

The prosthesis used in our study are VerSys Heritage primary hip prosthesis system manufactured by Zimmer Biomet India Pvt Ltd., and Latitud hip replacement system manufactured by Meril life sciences Pvt Ltd. The implants were chosen based on availability and affordability. Most of the patients were treated with VerSys Heritage systems. The technical specifications are as follow:

### **ACETABULAR CUP**

ZCA All-poly acetabular cup were used for cemented fixation. Cup sizes were available in increments of 2mm. The cups are available in four ID sizes (22mm, 26mm, 28m, 32mm). The last reamer used should match the cup diameter.




Fig.9: Acetabular cup

### **FEMORAL STEM**

The VerSys heritage stem has been engineered to fit within the rasp's envelope, allowing for a cement mantle of at least 1mm in all directions. The VerSys heritage components are manufactured from a forged, cobalt-chrome alloy with adequate strength to allow for a smaller A/P dimension in the neck, which increases the range of motion.

The VerSys heritage system has a rectangular geometry, comparable to Sir John Charnley's original polished, flat-back stem with parallel anterior and posterior surfaces. The

distal tip of the VerSys heritage stem has a modified taper design, which minimises strain on the distal cement mantle. They come in two offsets: standard and extended. Standard femoral stem sizes are from 11 to 17.

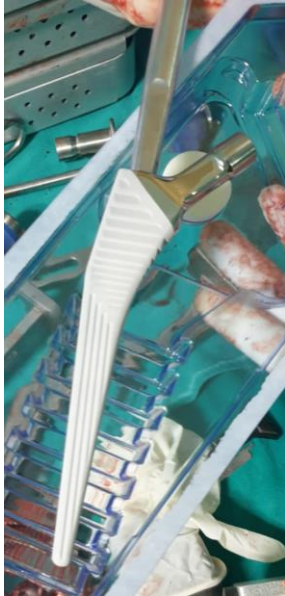

Fig.10: Femoral stem

Chart A

Stem Size	Stem Length*	Depth to which Cement Plug should be Inserted*
11	120mm	140mm
12	125mm	145mm
13	130mm	150mm
14	135mm	155mm
15	140mm	160mm
16	145mm	165mm
17	150mm	170mm

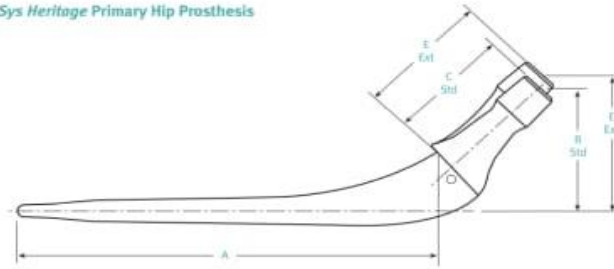
\* All measurements are from the medial calcar.

Fig.11: Stem sizes

## FEMORAL HEAD

The femoral head prosthesis determines the offset of the construct. It comes in standard and extended offset and in variations of  $\pm 3.5$ mm. It comes in -7, -3.5, 0, +3.5, +7, +10.5.

VerSys Heritage Primary Hip Prosthesis



Standard Offset

VerSys Heritage Primary Prod. No.	Stem Size	A Stem Length (mm)	B Offset (mm) When Head/Neck Component Selected is:					C Neck Length (mm) When Head/Neck Component Selected is:					Average Cement Mantle Thickness (mm)
			-3.5	0	+3.5	+7	+10.5	-3.5	0	+3.5	+7	+10.5	
7857-11	11	120	33	36	38	41	43	26	30	33	37	40	1.0
7857-12	12	125	36	39	41	44	46	28	32	35	39	42	1.5
7857-13	13	130	36	39	41	44	46	28	32	35	39	42	1.75
7857-14	14	135	39	42	44	47	49	33	36	40	43	47	2.0
7857-15	15	140	39	42	44	47	49	33	36	40	43	47	2.0
7857-16	16	145	42	45	47	50	52	37	40	44	47	51	2.0
7857-17	17	150	42	45	47	50	52	37	40	44	47	51	2.0

Extended Offset

VerSys Heritage Primary Prod. No.	Stem Size	A Stem Length (mm)	D Offset (mm) When Head/Neck Component Selected is:					E Neck Length (mm) When Head/Neck Component Selected is:					Average Cement Mantle Thickness (mm)
			-3.5	0	+3.5	+7	+10.5	-3.5	0	+3.5	+7	+10.5	
7857-13-20	13	130	41	44	46	49	51	31	35	38	42	45	1.75
7857-14-20	14	135	44	47	49	52	54	35	39	42	46	49	2.0
7857-15-20	15	140	44	47	49	52	54	35	39	42	46	49	2.0
7857-16-20	16	145	47	50	52	55	57	39	43	46	50	53	2.0

Fig.12: Femoral head sizes

# INSTRUMENTS

## GENERAL SET

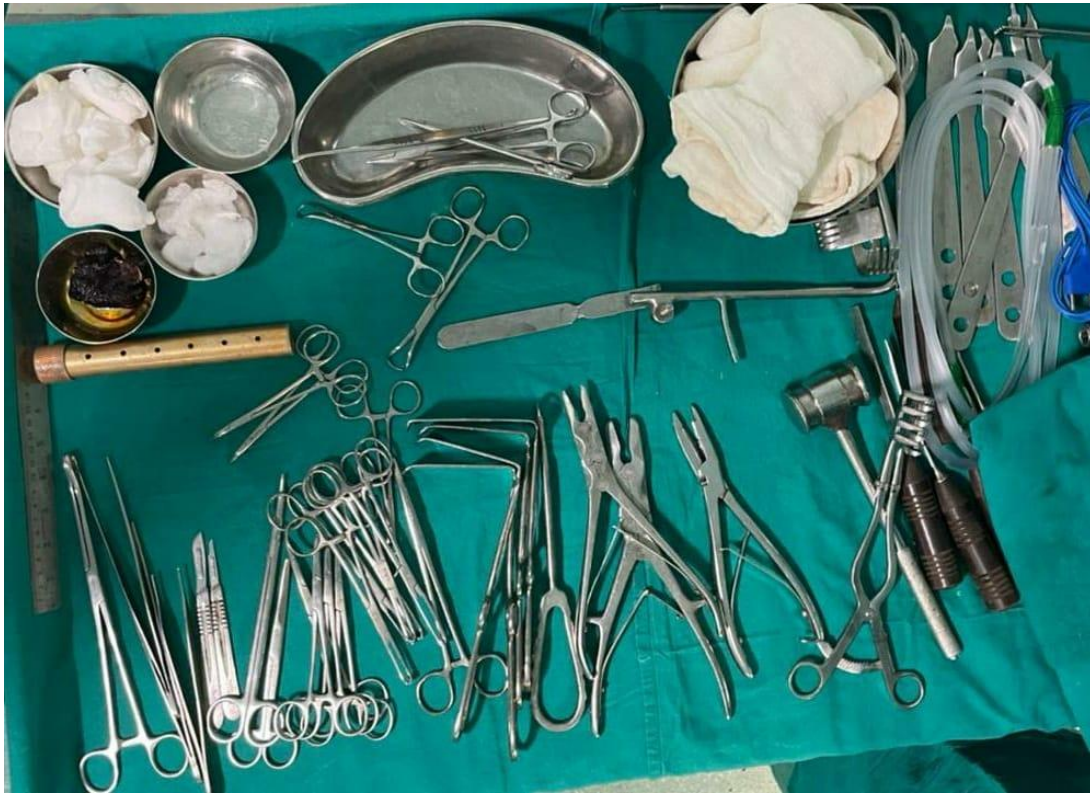

Fig.13: General instruments

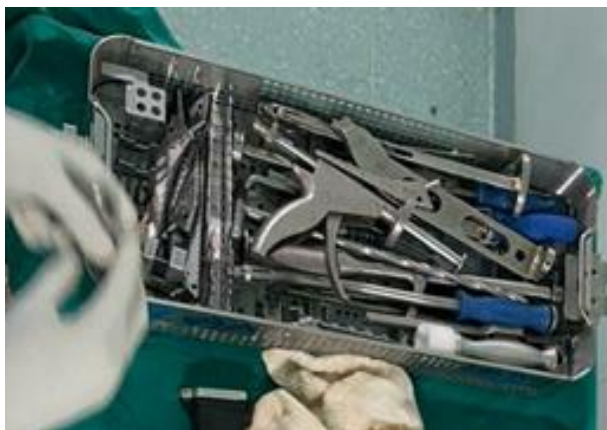

Fig.14: Special instruments

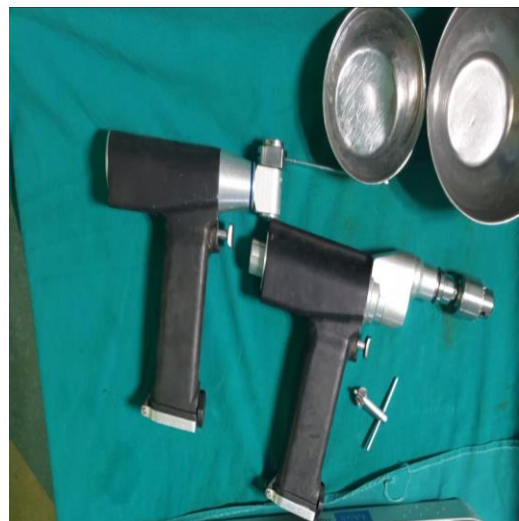



Fig.15: Power tools

# TOTAL HIP ARTHROPLASTY SET



Fig.16-19: Meril Total hip arthroplasty set and trial components








Fig.20: Zimmer trial components and rasps

Fig.21: Zimmer acetabular reamers



## SURGICAL TECHNIQUE

### Peri – Operative planning and Draping:

- An operating table that tilts easily was chosen.
- Patients were given spinal or epidural anesthesia and then put in lateral position [operative limb on top]
- Positioning devices were placed against the pubic symphysis or the anterior superior iliac spine, so as not to impede the motion of hip intra operatively.
- Bony prominences were adequately padded.
- Under all aseptic precautions the operative limb was scrubbed, painted and draped.
- The adhesive edges of a U-shaped plastic drape were applied to the skin to seal off the perineal and gluteal areas.
- The foot preferably was covered with a stockinette or cling drape to allow abundant irrigation without fear of contaminating the field.

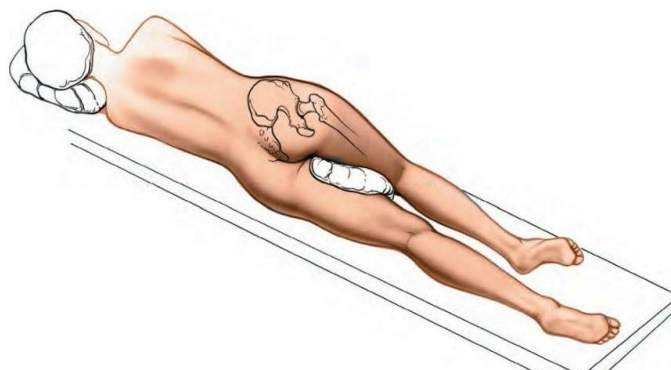
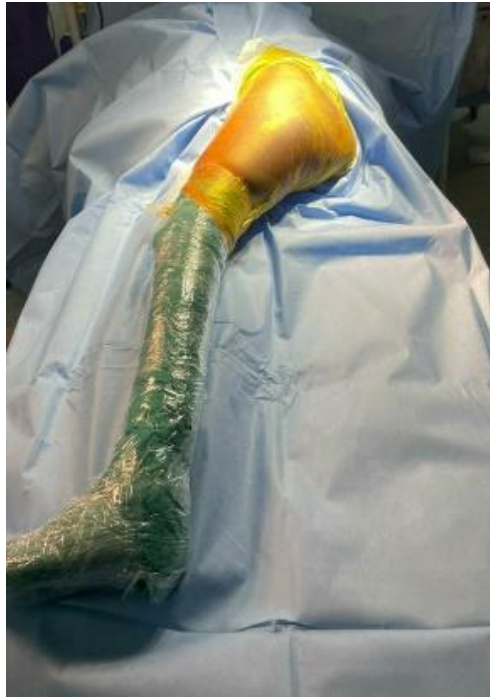

Fig.22: Position of the patient for the posterior approach to the hip joint.

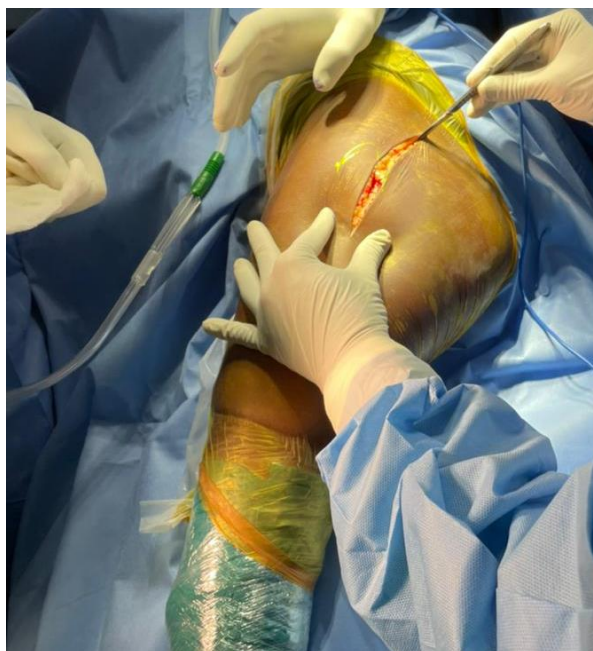


Photograph 1: Preparation and draping

## 1. Incision

A 10 to 15 cm incision centered on the posterior aspect of the greater trochanter was made.

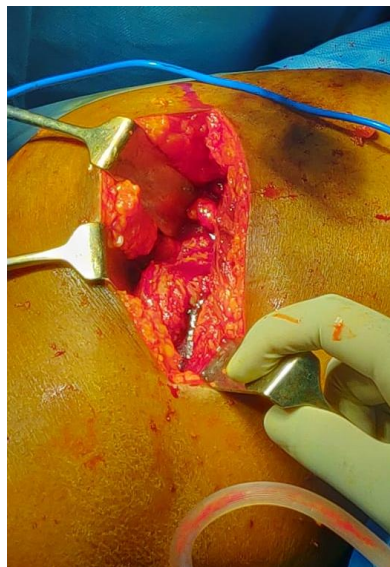
Photograph 2: Incision



## **2. Superficial dissection**

Fascia lata was incised on the lateral aspect of femur. Fascial incision was extended superiorly along the skin incision and the fibres of the gluteus maximus were split by blunt dissection. Any bleeders found were coagulated.

Photograph 3: Superficial dissection



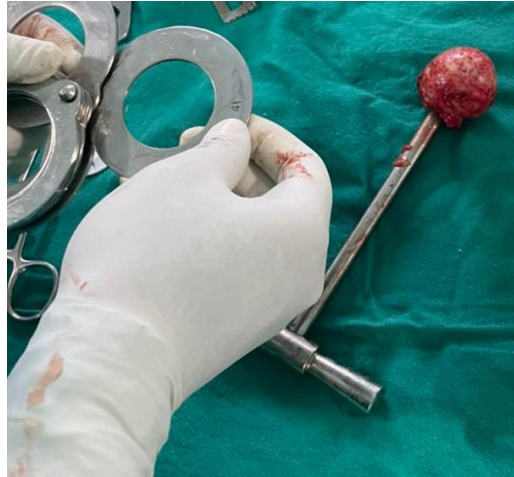## **3. Deep Surgical dissection**

The gluteus maximus and the deep fascia of the thigh are retracted. The hip was internally rotated to put the short external rotator muscles on stretch and to pull the operative field away from the sciatic nerve. Stay sutures were placed on the piriformis and obturator internus tendons. The muscles were then detached close to their femoral insertion and reflected.

The posterior aspect of the hip joint capsule was fully exposed. A T shaped incision was taken over the hip joint capsule. Femoral head and neck were visualized.

#### **4. Removal of Femoral Head:**

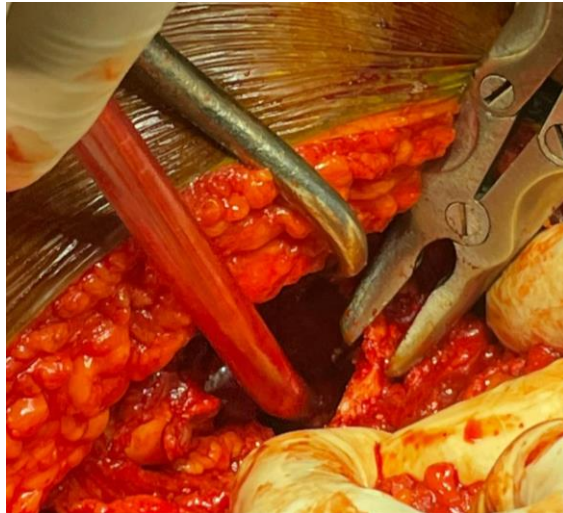Using a threaded handle corkscrew or a Hohmann's retractor, the head of femur was removed. The ligamentum teres was divided as necessary.



Photograph 4: Femoral head removal using corkscrew

#### **5. Acetabular preparation:**

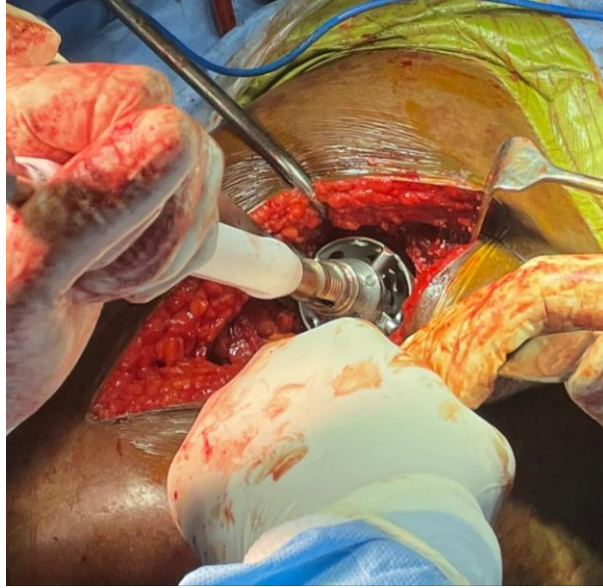Femur was retracted anteriorly with a bone hook and anterior capsule was isolated and divided. Placed a curve cobra or blunt Hohmann retractor in the space between the anterior rim of the acetabulum and the psoas tendon to avoid injury to the femoral nerve and adjacent vessels. Placed an additional retractor beneath the transverse acetabular ligament to provide inferior exposure. Retracted the posterior soft tissues with a spike retractor placed in the posterior column. Excision of the labrum was done.



Photograph 5: Acetabular preparation

Bony margins of the rim of the acetabulum were exposed around its entire circumference to facilitate proper placement of the acetabular component. Using an osteotome, any osteophytes that were protruding beyond the bony limits of the true acetabulum were removed. The procedure of cartilage removal and reaming of the acetabulum was the same, irrespective of cementless and cemented acetabular components.

Excised the ligamentum teres, curetted any remaining soft tissue from the region of the pulvinar. The floor of the acetabulum was palpated within the cotyloid notch. Removed the osteophytes with osteotome and rongeur to locate the medial wall. The acetabulum was prepared with motorized reamers. Began with a reamer smaller than the anticipated final size and directed it medially down to, but not through, the medial wall.



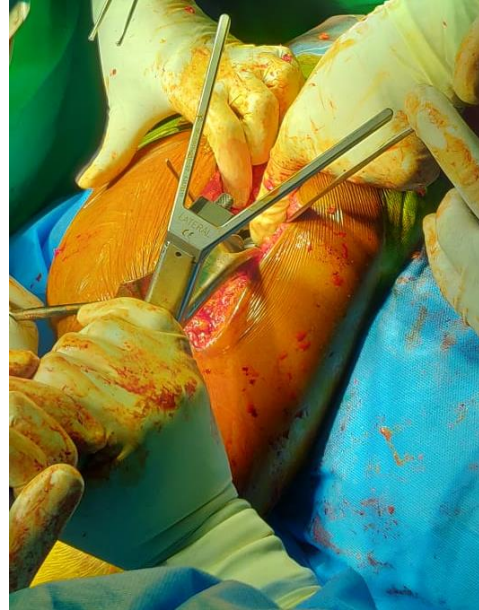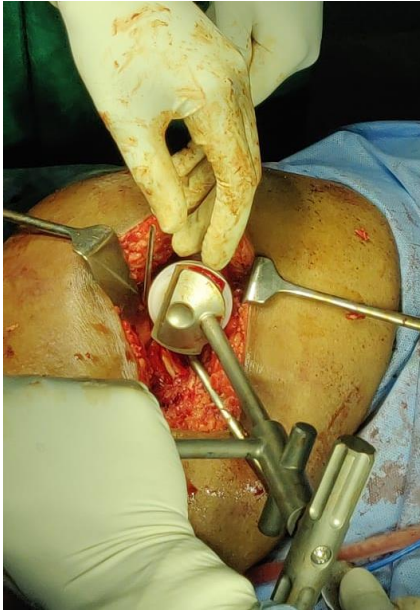
Photograph 6: Acetabular reaming

The acetabulum was frequently irrigated to assess the adequacy of reaming and to adjust the direction of the reaming to ensure that circumferential reaming occurs. Reaming was complete when all cartilage had been removed, the reamers had cut bone out to the periphery of the acetabulum, and a hemispherical shape had been produced. Maintained as much of the subchondral bone plate as possible.

## **6. Acetabular component fixation:**

The size of the implant can be denoted by either the outer diameter of the polyethylene or the outer diameter of the polyethylene plus the additional size provided by the PMMA spacers. The size of the reamed acetabulum should be equal to the outer diameter of the component including spacers.

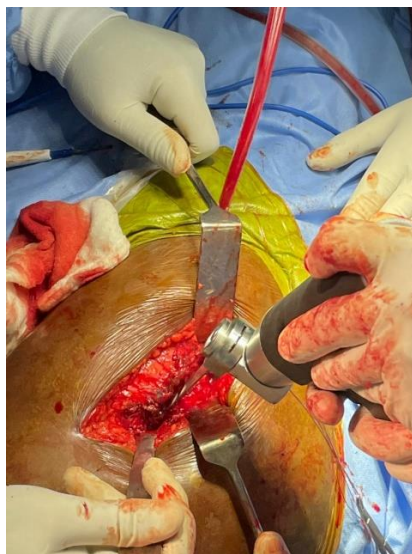
Cement is finger packed and spread with a cement pressurizer. The acetabular component is placed using a positioning device and held immobile until the cement hardens, maintaining appropriate pressure. All the residual cement was removed. The acetabular component's stability was evaluated.



Photograph 6&7: Acetabular cup fixation in proper position

## **7. Osteotomy of femoral neck:**

The level and angle of the proposed osteotomy of the femoral neck was marked with electrocautery. Usually, a finger breadth or 1-2 cms of neck was left proximal to the lesser trochanter. Using an oscillating power saw, osteotomy was done perpendicular to the axis of femoral neck.

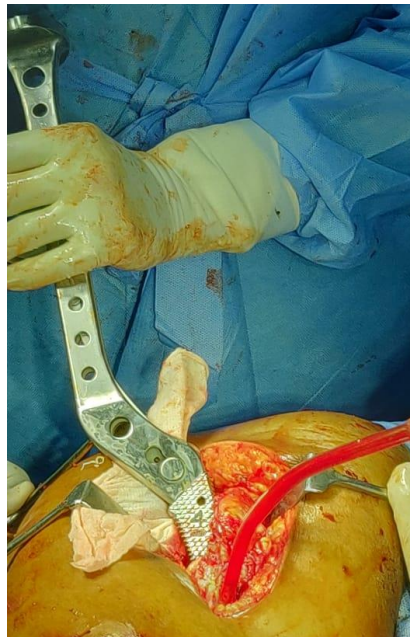


Photograph 8: Neck osteotomy



## **8. Femoral preparation:**

The proximal femur was delivered from the wound by internal rotation of femur and keeping tibia perpendicular to the floor and pushed proximally. Soft tissue from the posterior and lateral aspect of the neck were excised. Box cut osteotomy was done. A small reamer is used to locate medullary canal. Starting with the smallest broach, it was inserted in 10 – 15° of anteversion. Used progressively larger broaches in 2-mm increments.



Photograph 9: Femoral canal preapration

## **9. Trial and Assembly of Prosthesis:**

When the stability of the final broach has been checked, trial head and neck components, determined by preoperative templating were inserted. Once the neck length was satisfactory, debris in the acetabulum was irrigated. By giving gentle traction to the limb with the hip in slight flexion and by using a pusher over the femoral component, head is pushed into the socket.

Stability, limb length and offset are reassessed. Range of movements are assessed. If all the parameters are acceptable, the hip is redislocated by flexion and internal rotation. Trial components are removed.

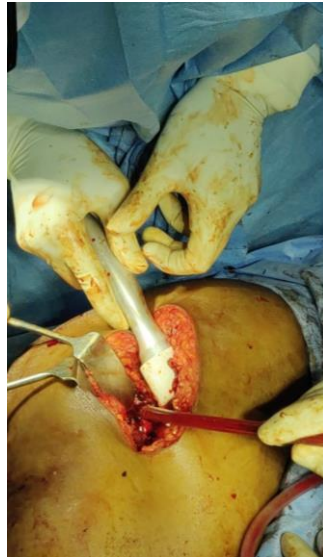### **10.Cementing:**

The usage of cemented components varied from patient to patient, depending on the quality of their bone stock. Ensured that the patient remains in the true lateral position before insertion of the acetabular component. If the pelvis has been rotated anteriorly by forceful anterior retraction of the femur, the acetabular component can easily be placed in a retroverted position, which may predispose to postoperative dislocation. In case of cemented procedure, cemented prosthesis in place using standard cementing techniques - lavage, cleaning, drying and plugging of the canal. Absolute haemostasis was obtained.

The femoral canal was plugged with a plastic plug of 2 cm below the tip of prosthesis. Good pressurization was allowed to femoral cement. The canal was irrigated thoroughly with saline to remove blood and bone debris. The cement was injected in the femoral canal by cement gun with syringe.

### **11.Femoral component fixation:**

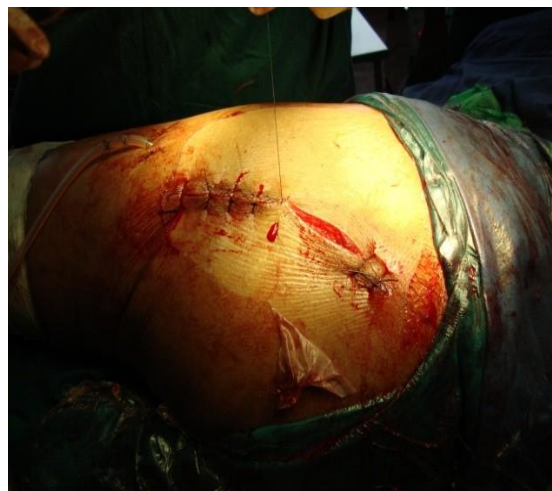Proximal femur is again exposed and all loose debris are irrigated and removed. The appropriate sized femoral component is inserted and impacted down the canal. The appropriate sized prosthetic head and neck components are assembled on the trunnion and affixed with a single blow over an impactor. Debris removed from acetabulum and hip is relocated. Stability and functional ROM checked.



Photograph 10: Femoral component fixation & reduction

### **12.Closure:**

Removed all cement debris and gauze from the operative wound. After several saline plus betadine wash given, posterior capsule was reattached, and drill holes were made over the post intertrochanteric line for the attachment of short external rotators through pull sutures. The muscles and the fascia were sutured back with 1-0 vicryl sutures after achieving proper haemostasis. The wound was closed in usual manner over 2 suction drains. [1- subcutaneous, 2 – deep intramuscular]. A watertight closure was achieved.



Photograph 11: Skin closure

Patient was given IV broad spectrum cephalosporin one dose post-operatively and followed twice a day dose till 48 hours depending on the condition of the wound and patient.

Intraoperatively, the following parameters were recorded:

1. The surgery's total duration
2. Incision length
3. Specifics of the implant
4. Stability of the prostheses

## **Postoperative Management**

In case of spinal anaesthesia, foot end elevation was given depending on the patients postoperative blood pressure. Every half an hour blood pressure, pulse rate, temperature, and respiratory rate were monitored for the first 24 hours.

Whenever necessary, postoperative blood transfusion was given. Intramuscular analgesics were given as per patient's compliance. Intravenous antibiotics were continued for 5 days, followed by oral antibiotics. Patient's lower limbs were kept in abduction by using a pillow in between both the legs. Drain removal was done after 48 hours. Check radiograph was taken after 48 hours.

Patients were made to sit up on the second day, stand up with support (walker), on the third day, and were allowed to full weight bear and walk with the help of a walker on the fourth postoperative day depending on his/her pain tolerance and were encouraged to walk thereafter. Sitting cross-legged and squatting were not allowed.

Suture removal was done on the twelfth postoperative day. The patients were assessed for any shortening or deformities if any and discharged from the hospital. Patients who had infection and bedsores were treated accordingly before discharging them from the hospital.

### **PHYSIOTHERAPY:**

- Active toe and ankle movements
- Static Quadriceps exercise
- Mobilization of knee and hip
- Non weight bearing crutch walking/walker
- Time of full weight bearing was given progressively after 2 to 3 weeks

## **Follow Up**

Patients were followed up at an interval of 1 month, 3 months, and 6 months and functional outcome was analyzed by modified Harris hip scoring system. At each follow up radiograph of the hip was taken.

At the time of discharge the patients were asked to come for follow up after 1 month and for further follow up at 3 months and 6 months. The patients who could not come for follow up due to Covid 19 restrictions and lockdown were contacted through phone and details were collected for the assessment of functional results. Such results were then re confirmed on subsequent follow ups after the patient came to the hospital following relaxation of lockdown.

At follow up, detailed clinical examination was done systematically. Patients were evaluated according to Harris hip scoring system for pain, limp, the use of support, walking distance, ability to climb stairs, ability to put on shoes and socks (in our study for some patients' ability to cut toenail, wash their own foot was enquired) sitting on chair, ability to enter public transportation, deformities, leg length discrepancy and movements. All the details were recorded in the follow up chart.

## RESULTS

The study included 25 patients with the diagnosis of Fracture of the neck of femur from November 2019 to March 2021. All the patients were subjected to a primary total hip arthroplasty.

The following results were collected from the study.

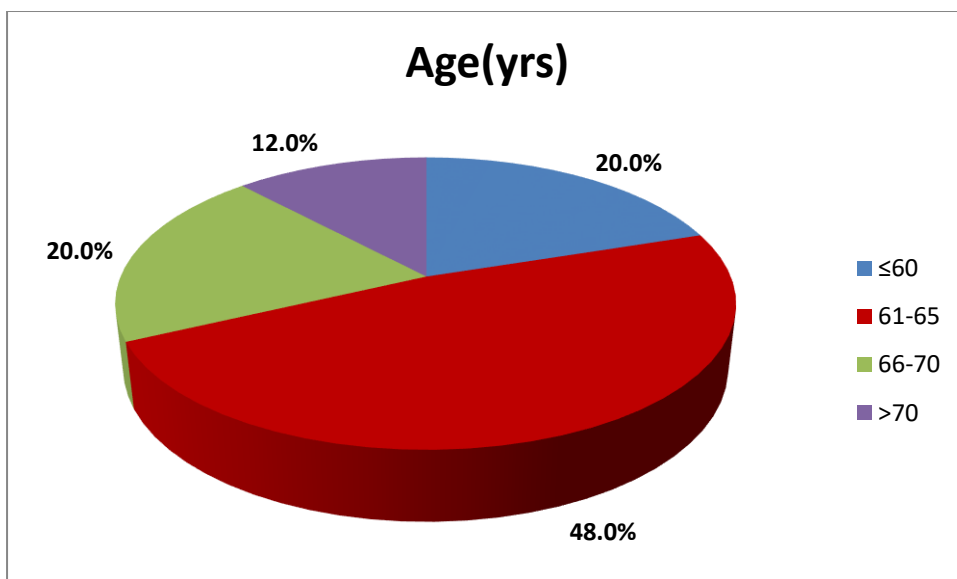
### AGE

The study was conducted on elderly population of patients above 60 years of age.

**Chart.1: Distribution of Cases according to Age**

Age(Yrs)	No. of cases	Percent
≤60	5	20
61-65	12	48
66-70	5	20
>70	3	12
Total	25	100

**Graph.1: Distribution of Cases according to Age**



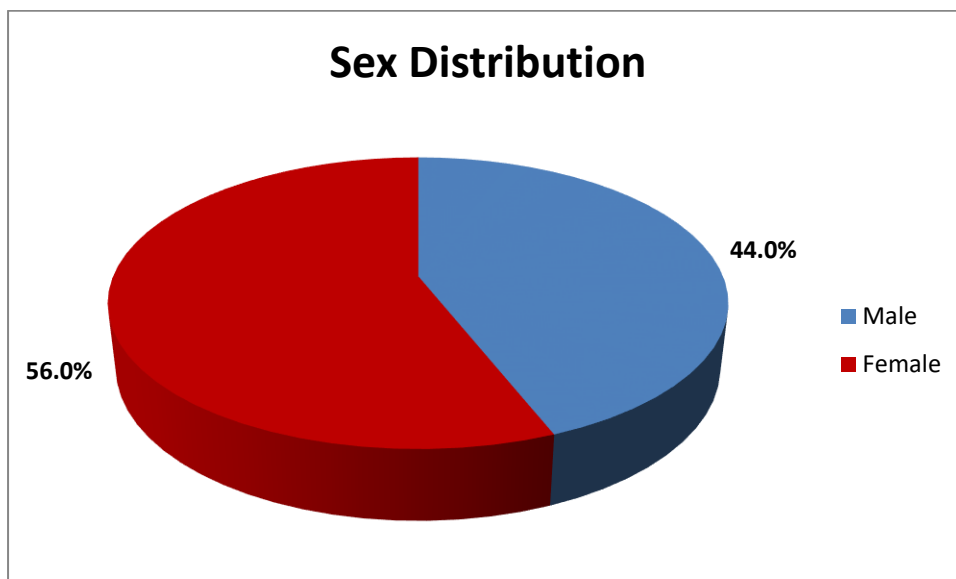
## SEX

The study had 11 male and 14 female patients.

**Chart.2: Distribution of Cases according to Sex**

Sex	No. of cases	Percent
Male	11	44
Female	14	56
Total	25	100

**Graph.2: Distribution of Cases according to Sex**





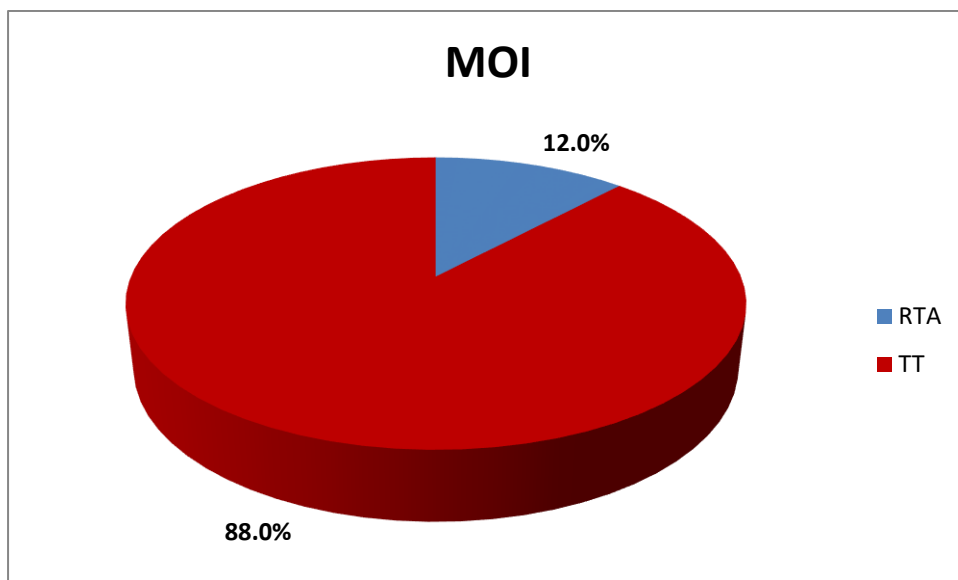
## MODE OF INJURY

The most common mode of injury was Trivial trauma (mostly domestic falls); there were 22 patients of this mode. 3 patients were involved in road traffic accidents.

**Chart.3: Distribution of Cases according to MOI**

MOI	No. of cases	Percent
RTA	3	12
TT	22	88
Total	25	100

**Graph.3: Distribution of Cases according to MOI**



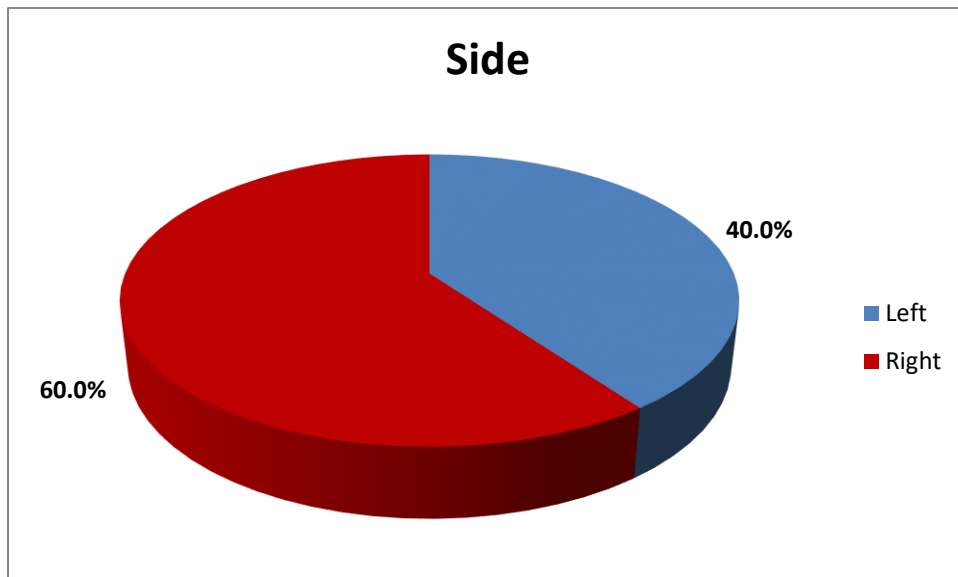
### LATERALITY/ SIDE:

There were 10 patients with left sided involvement and 15 patients with right hip involvement.

**Chart.4: Distribution of Cases according to Side**

Side	No. of cases	Percent
Left	10	40
Right	15	60
Total	25	100

**Graph.4: Distribution of Cases according to Side**



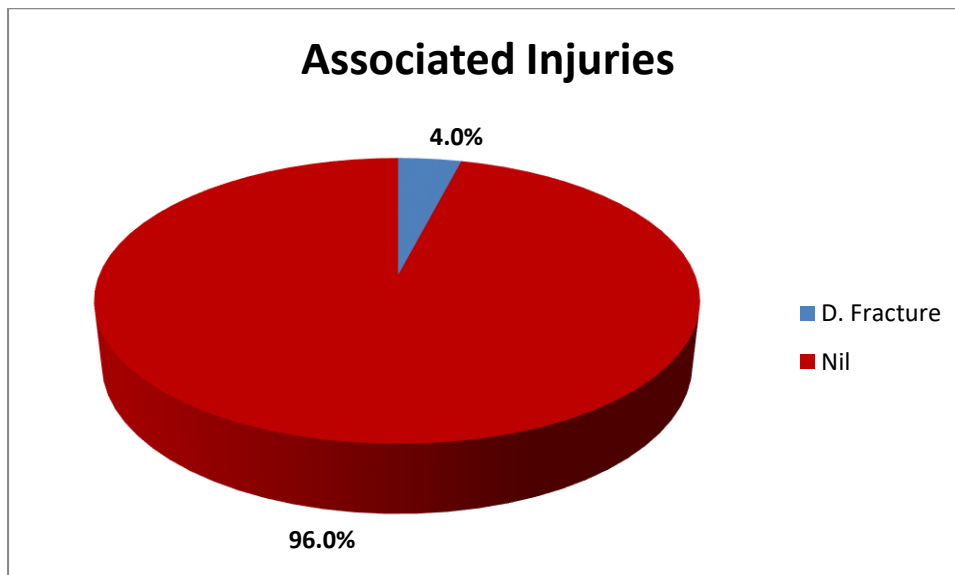
## ASSOCIATED INJURIES

Only one patient sustained a distal end radius fracture apart from the fracture of the neck of femur. The patient was treated conservatively with closed reduction and cast.

**Chart.5: Distribution of Cases according to Associated Injuries**

Associated Injuries	No. of cases	Percent
D. Fracture	1	4
Nil	24	96
Total	25	100

**Graph.5: Distribution of Cases according to Associated Injuries**



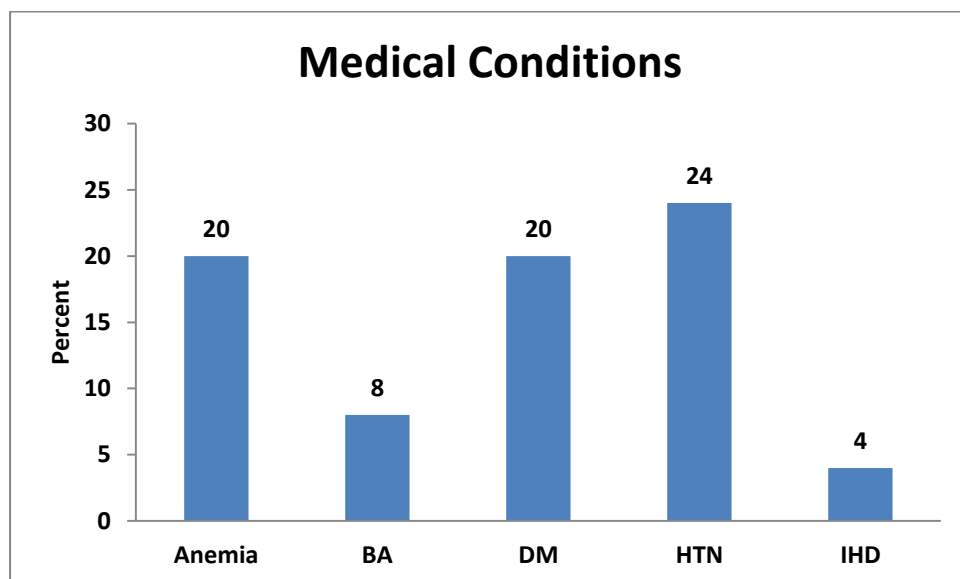
## ASSOCIATED COMORBID CONDITIONS

5 patients were diagnosed with iron deficiency anemia, 2 patients had Bronchial Asthma, 5 patients were diabetic, 6 patients were hypertensive and 1 patient had Ischemic heart disease.

**Chart.6: Distribution of Cases according to Comorbid Conditions**

Medical Conditions	No. of cases	Percent
Nil	9	36
Anemia	5	20
BA	2	8
DM	5	20
HTN	6	24
IHD	1	4

**Graph.6: Distribution of Cases according to Medical Conditions**



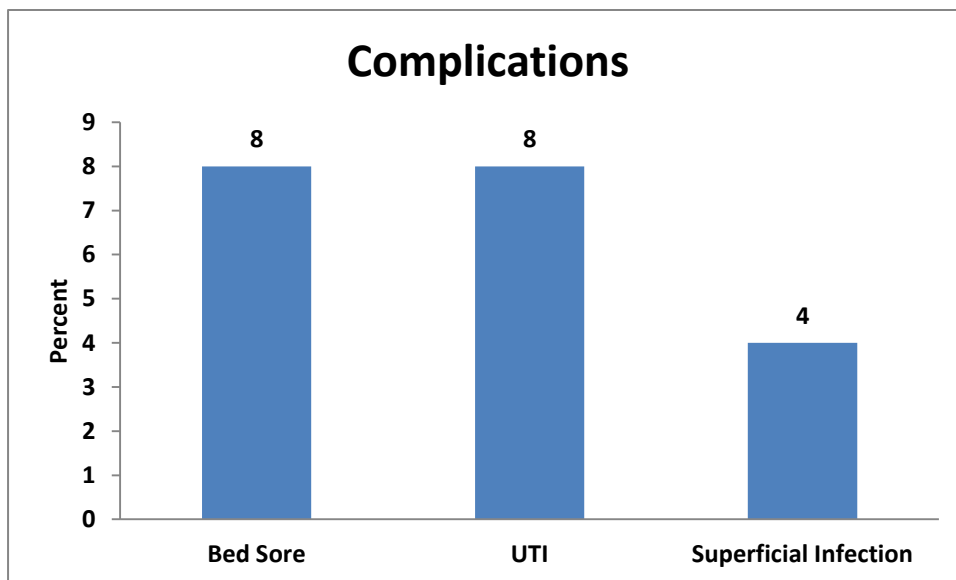
## COMPLICATIONS

In the study, 2 patients developed bed sores of grade 1. 2 patients had urinary tract infection and 1 patient had superficial infection around the surgical site.

**Chart.7: Distribution of Cases according to Complications**

Complications	No. of cases	Percent
Nil	21	84
Bed Sore	2	8
UTI	2	8
Superficial Infection	1	4

**Graph.7: Distribution of Cases according to Complications**

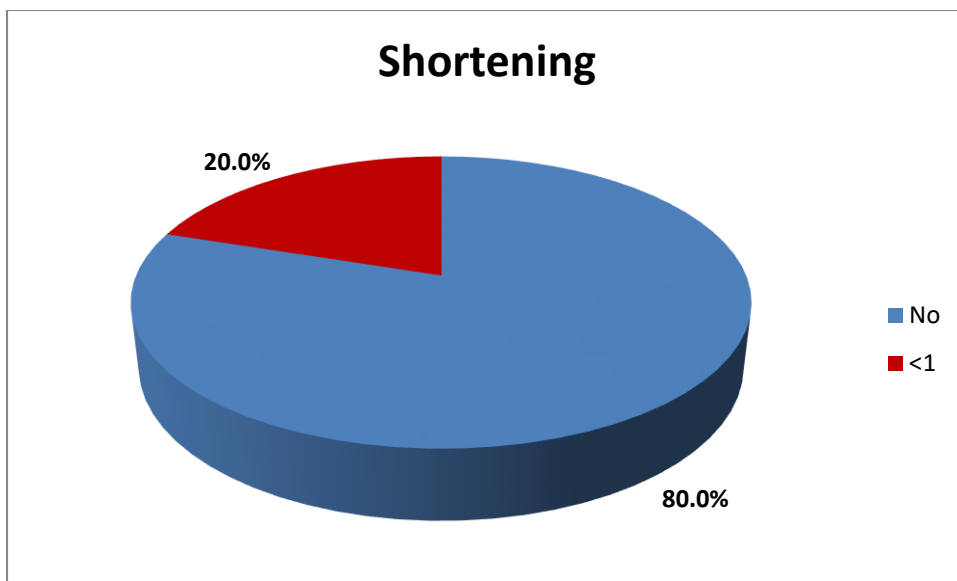


**SHORTENING:**

**Chart.8: Distribution of Cases according to Shortening**

<b>Shortening</b>	<b>No. of cases</b>	<b>Percent</b>
No	20	80
<1	5	20
Total	25	100

**Graph.8: Distribution of Cases according to Shortening**

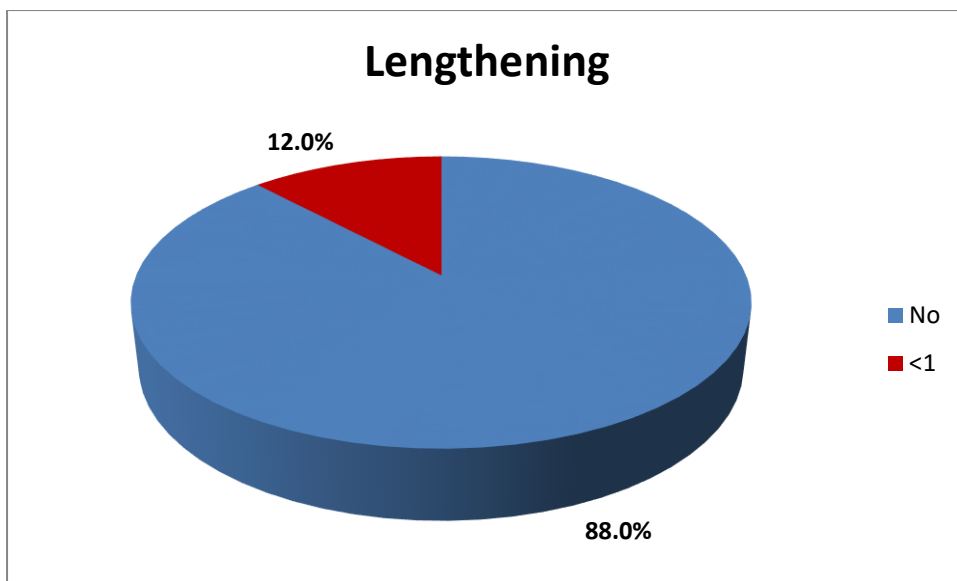


**LENGTHENING:**

**Chart.9: Distribution of Cases according to Lengthening**

<b>Lengthening</b>	<b>No. of cases</b>	<b>Percent</b>
No	22	88
<1	3	12
Total	25	100

**Graph.9: Distribution of Cases according to Lengthening**



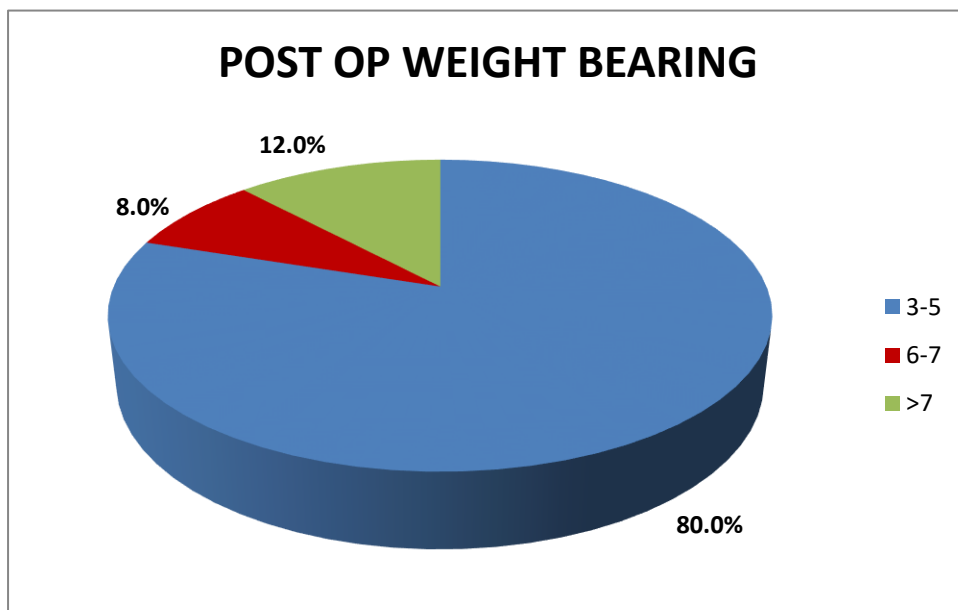
**POST-OP WEIGHT BEARING:**

**Chart.10: Distribution of Cases according to Post Op Weight Bearing**

<b>Post Op Weight Bearing</b>	<b>No. of cases</b>	<b>Percent</b>
3-5	20	80
6-7	2	8
>7	3	12
Total	25	100

<b>Descriptive Statistics</b>	<b>Min</b>	<b>Max</b>	<b>Mean</b>	<b>SD</b>
POST OP WEIGHT BEARING	3	21	5.5	4.0

**Graph.10: Distribution of Cases according to Post Op Weight Bearing**





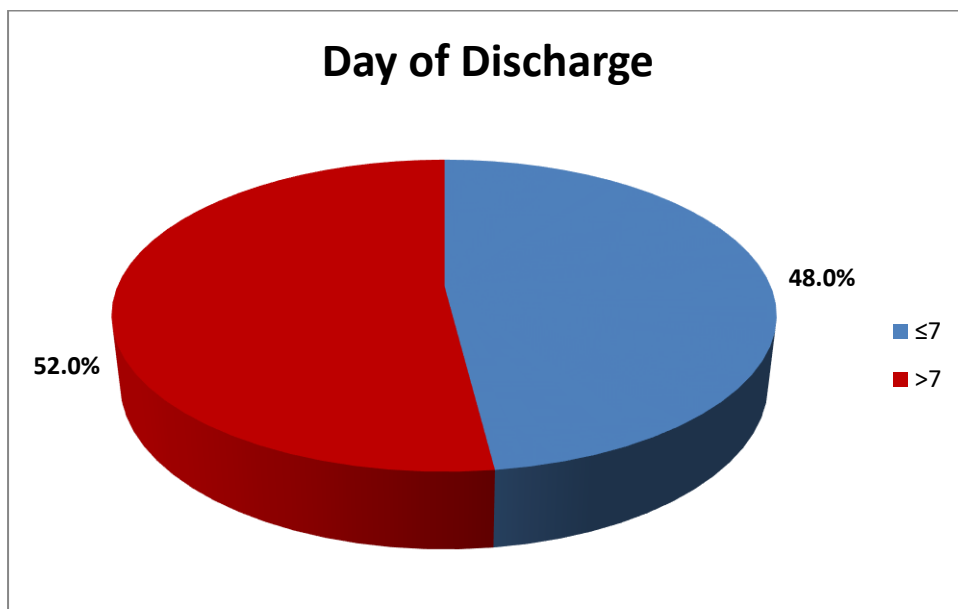
**DAY OF DISCHARGE:**

**Chart.11: Distribution of Cases according to Day of Discharge**

Day of Discharge	No. of cases	Percent
$\leq 7$	12	48
$> 7$	13	52
Total	25	100

Descriptive Statistics	Min	Max	Mean	SD
DAY OF DISCHARGE	5	17	9.0	3.8

**Graph.11: Distribution of Cases according to Day of Discharge**



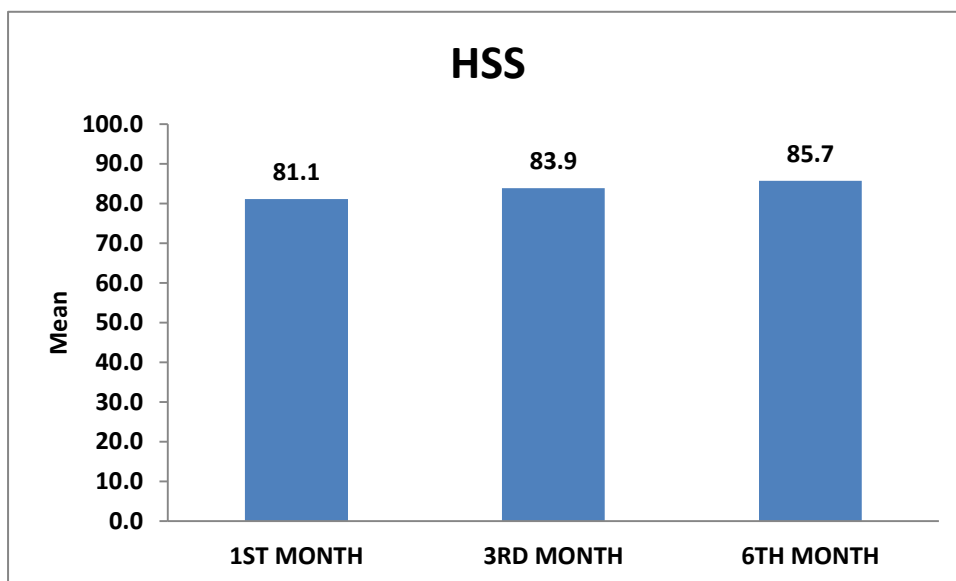
## MODIFIED HARRIS HIP SCORE:

Chart.12: Distribution of HHS according to time

HHS	Min	Max	Mean	SD	p value
1ST MONTH	62	89	81.1	6.2	0.045*
3RD MONTH	65	91	83.9	6.5	
6TH MONTH	65	93	85.7	6.6	

Note: p value\* significant at 5% level of significance ( $p < 0.05$ )

Graph.12: Distribution of HHS according to time

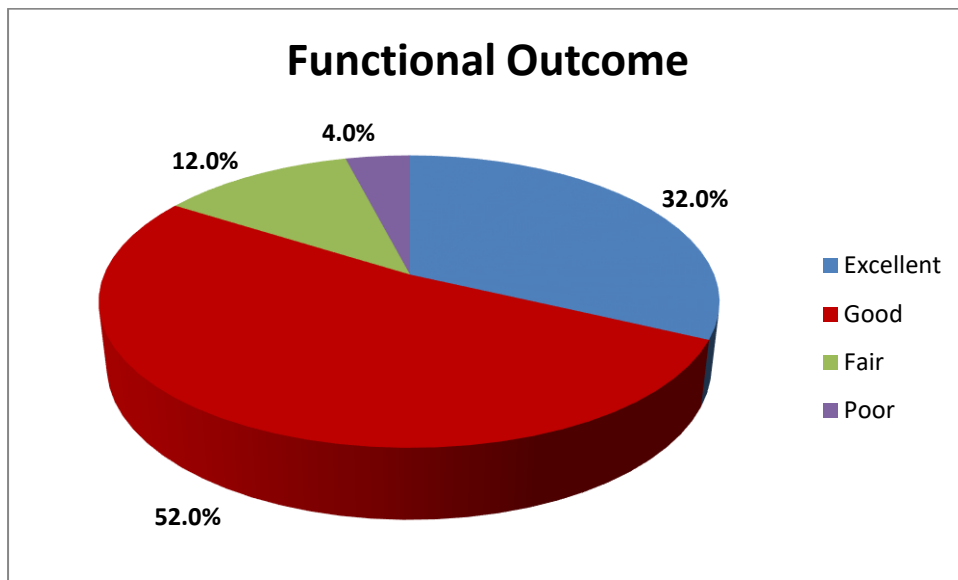


## FUNCTIONAL OUTCOME:

**Chart.13: Distribution of Cases according to Functional Outcome**

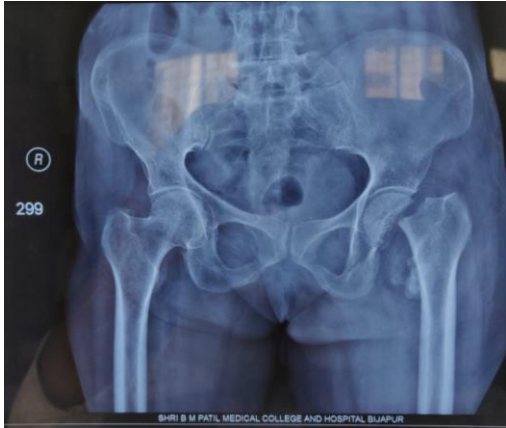Functional Outcome	No. of cases	Percent
Excellent	8	32
Good	13	52
Fair	3	12
Poor	1	4
Total	25	100

**Graph.13: Distribution of Cases according to Functional Outcome**

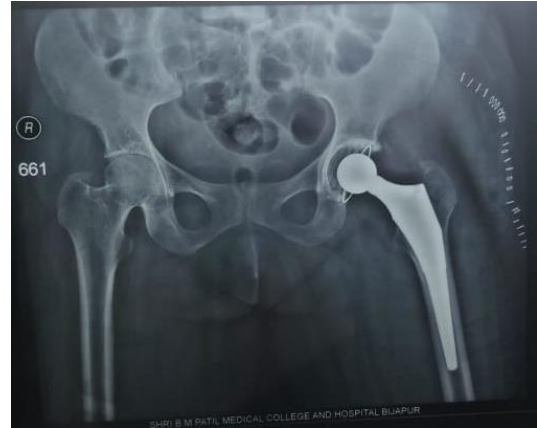

# CLINICAL AND RADIOGRAPHICAL PHOTOS

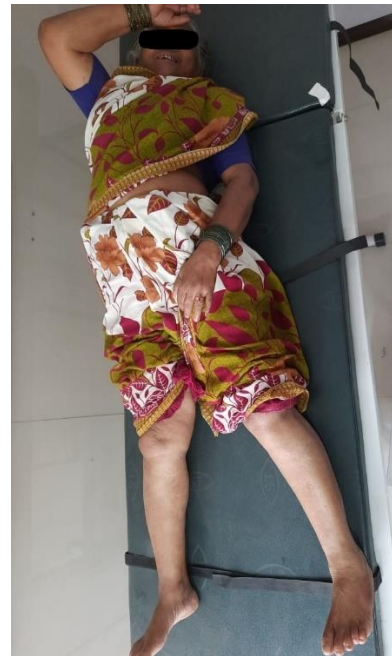## CASE NO:1



Pre operative radiograph



Post operative radiograph

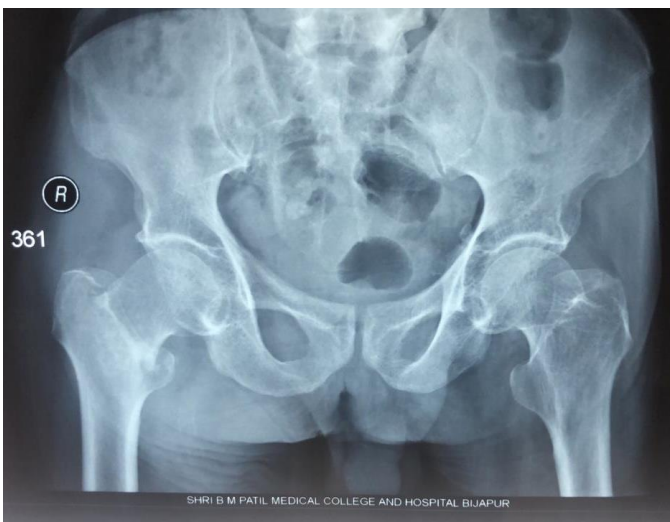

Clinical images at 6 month follow up: Standing, Sitting, Abduction of limb

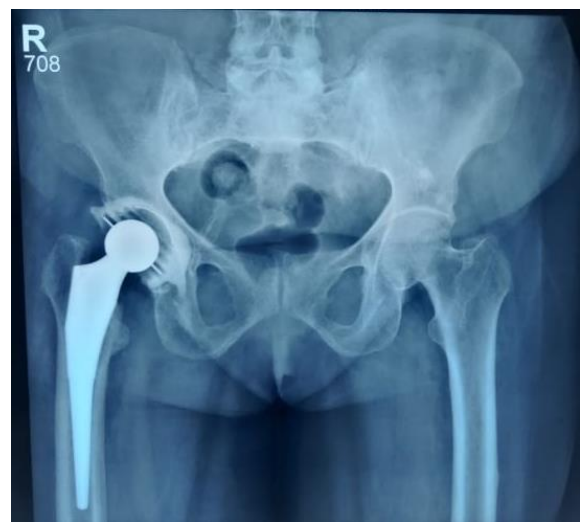

Clinical images at 6 month follow up: Flexion

**CASE NO:2**



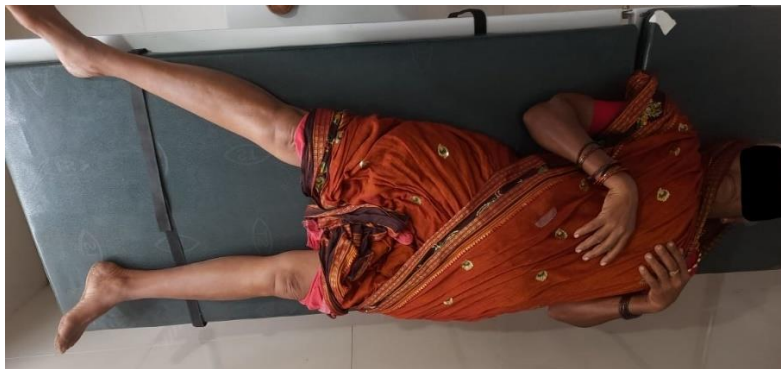Pre operative radiograph



Post operative radiograph



Clinical images at 6 month follow up: Standing, Sitting, Abduction of limb and Flexion



## DISCUSSION

Internal fixation, unipolar hemi-arthroplasty, bipolar arthroplasty, and total hip arthroplasty are the current treatment options for femoral neck fractures, each with its own set of indications, outcomes, and risks. Arthroplasty improves stability and reduces pain following surgery, allowing patients to walk immediately after implantation and lead to more effective mobilisation and rehabilitation.(44) However, hemiarthroplasty presents the potential for development of acetabular cartilage erosion, resulting in pain and may lead to conversion from hemiarthroplasty to total hip arthroplasty.(26)

Although there is no statistically significant difference in functional outcomes between bipolar hemiarthroplasty and total hip arthroplasty, THR appeared to be more cost effective and functional because it seldom requires revision surgery, which is often required with bipolar hemiarthroplasty.(44)

In our study, a primary Total hip arthroplasty was performed on 25 patients with fracture neck of femur. The study group consisted of only elderly population with age above 60 years. The mean age at the time of surgery was found to be 65.36 years. There were 11 male and 14 female patients. The most common mode of injury was found to be trivial trauma such as domestic falls which was 88%.

Gregory et al.(45) reported a significant rate of postoperative hip dislocation in femur fracture necks treated with total hip arthroplasty. The risk of dislocation is determined by the

surgical approach, reconstruction of the hip biomechanics, head size and offset, capsular closure quality, and surgeon expertise. Ricci et al.(46) found a very low dislocation rate when performing THA in acute displaced femoral neck fractures using the posterior approach as long as the protocol for patient selection criteria and surgical techniques assuring posterior hip stability were followed.

The patients were put in lateral decubitus position and a posterior Southern Moore approach was used in all the patients. All the surgeries were done by experienced surgeons. The rate of dislocation in our study was nil due to ideal selection of patients, proper placement of the acetabular cup, good closure of capsule, good attachment of the short external rotators by drilling holes in the bone and reinforcing with strong suture materials.

Complications such as bed sores were seen in 2 patients, urinary tract infections were seen in 2 patients and superficial infection at surgical site was seen in 1 patient. Bed sores were of grade 1 and healed on mobilisation. Superficial infection developed due to lack of hygiene and treated promptly with antibiotics. No patient had any DVT, pneumonia or cement related complications.

In our study, early mobilisation and weight bearing with walker was encouraged. Average mean for post operative weight bearing was around 5.5 days. Mean average day of discharge was about 9 days from the day of surgery. 5 patients had limb length shortening of 1 cm and 3 patients had lengthening of 1 cm, which was not significant, and patients were comfortable and did not require any shoe modifications.



All patients were followed up from the time of discharge to 6 months from the date of surgery. They were evaluated clinically and radiographically, and functional outcomes were recorded using Modified Harris Hip Score. Harris Hip Score (HHS) was dominated by THR group compared to HA group up to 9 years following surgery, according to Avery et al.(47).

In our study, we found that the mean Harris hip score was 81.1 at the end of 1<sup>st</sup> month follow up. At the 3<sup>rd</sup> month follow up, mean Harris hip score was 83.9. At the end of 6 months, mean Harris hip score was 85.7. Out of the 25 patients, 8 patients had excellent outcome, 13 patients had good outcome, 3 patients had fair outcome and 1 patient had poor outcome. The poor outcome was recorded in 1 patient due to lack of mobilisation secondary to recovery from covid pneumonia.

Iorio et al.(48) found that total hip arthroplasty for displaced femur fracture necks is the best cost-effective procedure when considering complications, re-operation rate, mortality, and functional results of the hip during a two-year period. Even while the cost of surgery with a prosthesis appears to be high at first, it will become more cost effective over time because revision surgery is rarely required, and the hip's performance is excellent. THA has been shown in a number of studies to have a place in the treatment of patients with acute femoral neck fractures.(49)(50)

In our study, most patients had none to occasional pain with no compromise in daily activities and did not require analgesics. Patients were able to walk a distance of more than

six blocks comfortably. The patients with fair and poor outcomes were found to walk with a slight limp. All the patients were found to use a cane while walking; some attributed its use as a precautionary measure to avoid another fall despite good stability.

Twenty one patients were able to use public transportation. 8 patients were able to sit comfortably on an ordinary chair, while the rest required a high chair. 21 patients were able to climb stairs normally by using the railing. None of the patients in our study developed any deformity. At the end of the study, the sum of the range of movements of the hip joint was on an average about 186°.

## CONCLUSION

Total hip arthroplasty when performed as a primary procedure in elderly patients with fracture neck of femur, provided excellent results in 32%, good results in 52%, fair results in 12% and poor result in 4% of the study population. Though this study included only a small number of patients and a shorter follow up period, the results suggest that primary Total hip arthroplasty is an excellent option for treatment of fracture neck of femur in elderly population.

The key to success lies in selecting patients who are active, independent, mobile pre-injury, motivated and in a sound mental state. There were no cases of dislocation in our study, as is commonly dreaded. We recommend the total hip arthroplasty as a primary procedure in patients with fracture neck of femur to avoid further reoperations in patients with long life expectancy.

## BIBLIOGRAPHY

1. Lau EM. The epidemiology of osteoporosis in Asia. *IBMS Bonekey*. 2009;6(5):190–3.
2. Malhotra N, Mithal A. Osteoporosis in Indians. *Indian J Med Res*. 2008;127(3):263–8.
3. Aljizani A, Baawad F, Almaghrabi A, Alshehri A, Alhawash A, Alzahrani J, et al. Total hip replacement versus hemiarthroplasty in intracapsular fracture of the elderly. *Int J Community Med Public Heal*. 2018;5(7):2606.
4. Stafford GH, Charman SC, Borroff MJ, Newell C, Tucker JK. Total hip replacement for the treatment of acute femoral neck fractures: Results from the National Joint Registry of England and Wales at 3-5 years after surgery. *Ann R Coll Surg Engl*. 2012;94(3):193–8.
5. Knight SR, Aujla R, Biswas SP. 100 Years of Operative History of the Hip. *Orthop Rev*. 2011;3:2–4.
6. Sir Cooper A. A treatise on dislocations and on fractures of the joints: fractures of the neck of the thigh-bone. 1823. *Clin Orthop Relat Res*. 2007;458:6–7.
7. Learmonth ID, Young C, Rorabeck C. The operation of the century: total hip replacement. *Lancet*. 2007;370(9597):1508–19.
8. Smith-Petersen MN. Evolution of mould arthroplasty of the hip joint. 1948. *Clin Orthop Relat Res*. 2006;453(August):17–21.
9. Wiles P. The surgery of the osteo-arthritic hip. *Clin Orthop Relat Res*. 2003;(417):3–16.

10. Brown SR, Davies WA, DeHeer DH, Swanson AB. Long-term survival of McKee-Farrar total hip prostheses. *Clin Orthop Relat Res.* 2002;(402):157–63.
11. McKellop H, Park SH, Chiesa R, Doorn P, Lu B, Normand P, et al. In vivo wear of 3 types of metal on metal hip prostheses during 2 decades of use. *Clin Orthop Relat Res.* 1996;(329 SUPPL.).
12. Bezwada HP, Cho RH, Nazarian DG. Hemiarthroplasty of the hip. *Oper Tech Adult Reconstr Surg.* 2012;(1944):39–54.
13. McMinn DJW, Daniel J, Ziaee H. The best bearing couple for hip arthroplasty. *Ann R Coll Surg Engl.* 2005;87(6):411–8.
14. Beaulé PE, Mussett SA, Medley JB. Metal-on-Metal Bearings in Total Hip Arthroplasty. *Instr Course Lect.* 2010;59(3298):17–25.
15. Bizot P, Nizard R, Hamadouche M, Hannouche D, Sedel L. Prevention of wear and osteolysis: Alumina-on-alumina bearing. *Clin Orthop Relat Res.* 2001;(393):85–93.
16. Cuckler JM. The rationale for metal-on-metal total hip arthroplasty. *Clin Orthop Relat Res.* 2005;(441):132–6.
17. Jacobs JJ, Roebuck KA, Archibeck M, Hallab NJ, Glant TT. Osteolysis: Basic science. *Clin Orthop Relat Res.* 2001;(393):71–7.
18. Boutin P. Total arthroplasty of the hip by fritted alumina prosthesis. Experimental study and 1st clinical applications. *Orthop Traumatol Surg Res* [Internet]. 2014;100(1):15–21. Available from: <http://dx.doi.org/10.1016/j.otsr.2013.12.004>
19. Tharani R, Dorey FJ, Schmalzried TP. The risk of cancer following total hip or knee arthroplasty. *J Bone Jt Surg - Ser A.* 2001;83(5):774–80.

20. Morrison JC, Ward D. Ceramic-on-Ceramic Bearings in Total. 2002;(405):158–63.
21. Christel PS. Biocompatibility of surgical-grade dense polycrystalline alumina. *Clinical Orthopaedics and Related Research*. 1992. p. 10–8.
22. NAR. The Norwegian Arthroplasty Register. 2010;71(4):1–99. Available from: [http://nrlweb.ihelse.net/eng/Report\\_2010.pdf](http://nrlweb.ihelse.net/eng/Report_2010.pdf)
23. Ni GX, Lu WW, Chiu KY, Fong DY. Cemented or uncemented femoral component in primary total hip replacement? A review from a clinical and radiological perspective. *J Orthop Surg (Hong Kong)*. 2005;13(1):96–105.
24. Hopley C, Stengel D, Ekkernkamp A, Wich M. Primary total hip arthroplasty versus hemiarthroplasty for displaced intracapsular hip fractures in older patients: Systematic review. *BMJ*. 2010;340(7761):1397.
25. Hedbeck CJ, Enocson A, Lapidus G, Blomfeldt R, Törnkvist H, Ponzer S, et al. Comparison of bipolar hemiarthroplasty with total hip arthroplasty for displaced femoral neck fractures: A concise four-year follow-up of a randomized trial. *J Bone Jt Surg - Ser A*. 2011;93(5):445–50.
26. Liao L, Zhao JM, Su W, Ding XF, Chen LJ, Luo SX. A meta-analysis of total hip arthroplasty and hemiarthroplasty outcomes for displaced femoral neck fractures. *Arch Orthop Trauma Surg*. 2012;132(7):1021–9.
27. Wani IH, Sharma S, Latoo I, Salaria AQ, Farooq M, Jan M. Primary total hip arthroplasty versus internal fixation in displaced fracture of femoral neck in sexa- and septuagenarians. *J Orthop Traumatol*. 2014;15(3):209–14.
28. Mani KC K, Raj RC D. Total Hip Arthroplasty for Displaced Femoral Neck Fractures

- in Elderly Patients. *Orthop Muscular Syst.* 2016;05(01):5–8.
29. Bs J, Shivananda S, Patel G. A study of clinical and functional outcome of primary total hip replacement in osteoarthritis of hip. 2017;(June 2014):245–51.
  30. Sharma DS. Functional Outcome of Total Hip Replacement vs Hemiarthroplasty in Fracture Neck of Femur: A Prospective Study. *J Med Sci Clin Res.* 2018;6(12):640–5.
  31. Wang Z, Bhattacharyya T. Outcomes of Hemiarthroplasty and Total Hip Arthroplasty for Femoral Neck Fracture: A Medicare Cohort Study. *J Orthop Trauma.* 2017;31(5):260–3.
  32. Lewis DP, Wæver D, Thorninger R, Donnelly WJ. Hemiarthroplasty vs Total Hip Arthroplasty for the Management of Displaced Neck of Femur Fractures: A Systematic Review and Meta-Analysis. *J Arthroplasty [Internet].* 2019;34(8):1837-1843.e2. Available from: <https://doi.org/10.1016/j.arth.2019.03.070>
  33. Fahad S, Nawaz Khan MZ, Aqueel T, Hashmi P. Comparison of bipolar hemiarthroplasty and total hip arthroplasty with dual mobility cup in the treatment of old active patients with displaced neck of femur fracture: A retrospective cohort study. *Ann Med Surg [Internet].* 2019;45(March):62–5. Available from: <https://doi.org/10.1016/j.amsu.2019.07.025>
  34. Azar M. F, Beaty H. J, Canale S. T. *Campbell's operative orthopaedics.* Thirteenth. Philadelphia: Elsevier; 2017.
  35. Thompson C. J. *Netter's Concise Orthopaedic Anatomy.* 2nd editio. Philadelphia: Elsevier; 2016.
  36. Court-Brown CM, Heckman JD, McQueen MM, Ricci WM, Tornetta III P. *Rockwood*

- and Green's Fractures in Adults. 8th editio. Wolters Kluwer; 2015.
37. Rydell N. Biomechanics of the hip joint. Vol. 92, Clin.Orthop. 1973. p. 6–15.
  38. Mow VC, Huiskes R. Basic orthopaedic biomechanics & mechano-biology. 3rd editio. Philadelphia: Lippincott Williams & Wilkins; 2005.
  39. Solomon L. AND FRACTURE OF THE FEMORAL THE SOUTH AFRICAN BANTU NECK studied uncommon The present investigation is part of a large scale epidemiological The epidemiological method depends on the demonstration clear cut. J bone Jt Surg. 1968;50B(1):2–13.
  40. Hinton RY, Smith GS. The association of age, race, and sex with the location of proximal femoral fractures in the elderly. J Bone Jt Surg - Ser A. 1993;75(5):752–9.
  41. Elffors L, Gullberg B, Allander E, Johnell O, Kanis JA. Methodology of MEDOS multicentre study of hip fracture incidence: Validity and relevance considerations. Bone. 1993;14(SUPPL. 1):45–9.
  42. Hirsch C, Frankel V. Analysis of Forces Producing End Fractures the Femur of the. J Bone Jt Surg. 1960;42B(3):633–40.
  43. GARDEN RS. Stability and Union in Subcapital Fractures of the Femur. J Bone Joint Surg Br. 1964;46:630–47.
  44. Mani KC K, Raj RC D. Total Hip Arthroplasty for Displaced Femoral Neck Fractures in Elderly Patients. Orthop Muscular Syst. 2016;05(01).
  45. Gregory RJH, Wood DJ, Stevens J. JJ. (3):168–70.
  46. Ricci WM, Langer JS, Leduc S, Streubel PN, Borrelli J. Total hip arthroplasty for acute displaced femoral neck fractures via the posterior approach: A protocol to



- minimise hip dislocation risk. *HIP Int.* 2011;21(3):344–50.
47. Avery PP, Baker RP, Walton MJ, Rooker JC, Squires B, Gargan MF, et al. Total hip replacement and hemiarthroplasty in mobile, independent patients with a displaced intracapsular fracture of the femoral neck: A seven- to ten-year follow-up report of a prospective randomised controlled trial. *J Bone Jt Surg - Ser B.* 2011;93 B(8):1045–8.
  48. Iorio R, Healy WL, Lemos DW, Appleby D, Lucchesi C a, Saleh KJ. Outcomes and Cost Effectiveness. *Clin Orthopaedics Relat Res.* 2001;(383):229–42.
  49. Davison JNS, Calder SJ, Anderson GH, Ward G, Jagger C, Harper WM, et al. Treatment for displaced intracapsular fracture of the proximal femur. *J Bone Jt Surg - Ser B.* 2001;83(2):206–12.
  50. Ossendorf C, Scheyerer MJ, Wanner GA, Simmen H, Werner CML. Treatment of femoral neck fractures in elderly patients over 60 years of age - which is the ideal modality of primary joint replacement ? 2010;1–8.

**ANNEXURE**  
**ETHICAL COMMITTEE CLEARANCE**

IEC / 131 / 19  
22 / 11 / 20



**B.L.D.E. (DEEMED TO BE UNIVERSITY)**

(Declared vide notification No. F.9-37/2007-U.3 (A) Dated. 29-2-2008 of the MHRD, Government of India under Section 3 of the UGC Act, 1956)  
The Constituent College

**SHRI. B. M. PATIL MEDICAL COLLEGE, HOSPITAL AND RESEARCH CENTRE**


**INSTITUTIONAL ETHICAL CLEARANCE CERTIFICATE**

The ethical committee of this college met on 13-11-2019 at 3-15 pm to scrutinize the synopsis of Postgraduate students of this college from Ethical Clearance point of view. After scrutiny the following original/corrected and revised version synopsis of the Thesis has been accorded Ethical Clearance

**Title:** Functional outcome of primary total hip arthroplasty in elderly patients with fracture neck of femur - a prospective study

**Name of PG student:** Dr. Adhitiyaa. E. Department of Orthopaedics

**Name of Guide/Co-investigator :** Dr Ashok Nayak, Professor & HOD,  
Department of Orthopaedics

  
**DR RAGHVENDRA KULKARNI**  
**CHAIRMAN**

Institutional Ethical Committee  
B.L.D.E. (Deemed to be University)  
Medical College, B.L.D.E. (Deemed to be University)

Following documents were placed before Ethical Committee for Scrutinization:

1. Copy of Synopsis / Research project
2. Copy of informed consent form
3. Any other relevant documents.

## **ANNEXURE**

### **INFORMED CONSENT FORM**

**B.L.D.E (DEEMED TO BE UNIVERSITY) SHRI B.M. PATIL MEDICAL COLLEGE  
HOSPITAL AND RESEARCH CENTRE, VIJAYAPUR-586103**

#### **INFORMED CONSENT FOR PARTICIPATION IN DISSERTATION/RESEARCH**

I, the undersigned, \_\_\_\_\_, S/O D/O W/O \_\_\_\_\_, aged \_\_\_\_ years, ordinarily resident of \_\_\_\_\_ do hereby state/declare that Dr. ADHITIYAA. E of Shri. B. M. Patil Medical College Hospital and Research Centre has examined me thoroughly on \_\_\_\_\_ at \_\_\_\_\_ (place) and it has been explained to me in my own language that I am suffering from \_\_\_\_\_ disease (condition) and this disease/condition mimic following diseases. Further Dr. ADHITIYAA. E informed me that he/she is conducting dissertation/research titled “FUNCTIONAL OUTCOME OF PRIMARY TOTAL HIP ARTHROPLASTY IN ELDERLY PATIENTS WITH FRACTURE NECK OF FEMUR – A PROSPECTIVE STUDY” under the guidance of DR. ASHOK R. NAYAK requesting my participation in the study. Apart from routine treatment procedure, the pre-operative, operative, post-operative and follow-up observations will be utilized for the study as reference data.

Doctor has also informed me that during conduct of this procedure like adverse results may be encountered. Among the above complications most of them are treatable but are not anticipated hence there is chance of aggravation of my condition and in rare circumstances it may prove fatal in spite of anticipated diagnosis and best treatment made available. Further Doctor has informed me that my participation in this study help in evaluation of the results of

the study which is useful reference to treatment of other similar cases in near future, and also I may be benefited in getting relieved of suffering or cure of the disease I am suffering.

The Doctor has also informed me that information given by me, observations made/ photographs/ video graphs taken upon me by the investigator will be kept secret and not assessed by the person other than me or my legal hirer except for academic purposes.

The Doctor did inform me that though my participation is purely voluntary, based on information given by me, I can ask any clarification during the course of treatment / study related to diagnosis, procedure of treatment, result of treatment or prognosis. At the same time I have been informed that I can withdraw from my participation in this study at any time if I want or the investigator can terminate me from the study at any time from the study but not the procedure of treatment and follow-up unless I request to be discharged.

After understanding the nature of dissertation or research, diagnosis made, mode of treatment, I the undersigned Shri/Smt \_\_\_\_\_ under my full conscious state of mind agree to participate in the said research/dissertation.

Signature of patient:

Signature of doctor:

Witness: 1.

2.

Date

Place

# **ANNEXURE**

## **PROFORMA**

**SHRI B.M. PATIL MEDICAL COLLEGE, HOSPITAL AND RESEARCH CENTRE,**

**VIJAYAPURA- 586103**

### **PROFORMA**

CASE NO. : I.P NO :  
NAME : AGE/SEX :  
OCCUPATION : RESIDENCE :  
DATE OF ADMISSION :  
DATE OF SURGERY :  
DATE OF DISCHARGE :

Presenting complaints with duration :

History of presenting complaints :

Past History :

Family History :

Personal History :

## General Physical Examination

Pallor:	present/absent
Icterus:	present/absent
Clubbing:	present/absent
Generalized lymphadenopathy:	present/absent
Built:	poor/moderate/well
Nourishment:	poor/moderate/well

## Vitals

PR:	RR:
BP:	TEMP:

## Other Systemic Examination:

### Local examination:

- i. Gait
- ii. Inspection:
  - a) Attitude of limb
  - b) Scar/ sinus/ swelling around the hip

c) Shortening/ lengthening of limb

d) Skin changes

e) Deformity of spine/ knee

f) Wasting

iii. Palpation:

a) Inflammatory signs

b) Tenderness over greater trochanter/ joint line

c) Level of ASIS/ patella/ medial malleolus

d) Palpatory Bryant's triangle

e) Vascular sign of Narath

iv. Movements:

Right

Left

Hip Joint: Flexion

Extension

Adduction

Abduction

Internal rotation

External rotation

v. Measurements:

Right

Left

a. Limb length- Apparent and true

b. Bryant's triangle

- c. Nelaton's line
- d. Shoemaker's line
- e. Wasting
- vi.** Stability tests:
  - a. Telescopy test
  - b. Trendelenburg test
  - c. Thomas test
- vii.** Examination of spine and knee



# ANNEXURE

## SCORING SYSTEM

### MODIFIED HARRIS HIP SCORE

<b>Total I</b>	<b>PAIN</b>	<b>44</b>
<b>1</b>	Totally disabled, crippled, pain in bed, bedridden	<b>00</b>
<b>2</b>	Marked pain, serious limitation of activities	<b>10</b>
<b>3</b>	Moderate pain, tolerable but makes concession to pain	<b>20</b>
<b>4</b>	Mild pain, no effect on average activities	<b>30</b>
<b>5</b>	Slight, occasional, no compromise in activity	<b>40</b>
<b>6</b>	None, or ignores it	<b>44</b>
<b>Total II</b>		
	<b>Function</b>	<b>47</b>
<b>A.</b>	<b>Distance walked</b>	
<b>1</b>	Bed and chair only	<b>00</b>
<b>2</b>	Two or three blocks	<b>05</b>
<b>3</b>	Six blocks	<b>08</b>
<b>4</b>	Unlimited	<b>11</b>
<b>B.</b>	<b>Activities</b>	
<b>Shoes &amp; Socks</b>		
<b>1</b>	Unable to fit or tie	<b>00</b>

2	With difficulty	02
3	With ease	04
<b>Public transportation</b>		
1	Unable to use public transportation (bus)	00
2	Able to use transportation (bus)	01
<b>Limp</b>		
1	Severe or unable to walk	00
2	Moderate	05
3	Slight	08
4	None	11
<b>Support</b>		
1	Two crutches or not able to walk	00
2	Two canes	02
3	One crutch	03
4	Cane most of the time	05
5	Cane for long walks	07
6	None	11
<b>Stairs</b>		
1	Unable to do stairs	00
2	In any manner	01
3	Normally using a railing	02
4	Normally without using a railing	04
<b>Sitting</b>		
1	Unable to sit in any chair comfortably	00

<b>2</b>	On a high chair for 30 min	<b>03</b>
<b>3</b>	Comfortably on a ordinary chair for one hour	<b>05</b>
<b>Total III</b>		
	<b>Motions</b>	<b>05</b>
	<b>Flexion+ Abduction + Adduction+ External rotation + internal rotation=</b>	
<b>1</b>	00 to 29°	<b>00</b>
<b>2</b>	30 to 59°	<b>01</b>
<b>3</b>	60 to 99°	<b>02</b>
<b>4</b>	100 to 159°	<b>03</b>
<b>5</b>	160 to 209°	<b>04</b>
<b>6</b>	210 to 300°	<b>05</b>
<b>Total IV</b>		
	<b>Deformity</b>	<b>04</b>
<b>1</b>	Flexion deformity 30° of more	<b>00</b>
<b>2</b>	Flexion deformity less than 30°	<b>01</b>
<b>3</b>	Fixed adduction 10° more	<b>00</b>
<b>4</b>	Fixed adduction less than 10°	<b>01</b>
<b>5</b>	Fixed internal rotation(in extension) 10°or	<b>00</b>
<b>6</b>	Fixed internal rotation(inextension) less than 10°	<b>0</b>
<b>7</b>	Limb length discrepancy more than or equal	<b>00</b>

	to 3.2 cms	
<b>8</b>	Limb length discrepancy less than 3.2cms	01
	<b>Total</b>	
	<b>Total of I+II+III+IV</b>	<b>100</b>

## Harris hip scoring system

Total functional outcome was graded as following depending on the total Harris hip score.

<b>Harris Hip score [Range]</b>	<b>Comments</b>
<b>Less than 70.</b>	Poor
<b>Between 71 - 80</b>	Fair
<b>Between 81 - 90</b>	Good
<b>Between 91 - 100</b>	Excellent

# ANNEXURE

## MASTER CHART

S.NO.	NAME	IP.NO.	AGE	SEX	DATE OF SURGERY	MOI	SIDE	ASSOCIATED INJURIES	MEDICAL CONDITIONS	BLOOD TRANSFUSION		COMPLICATIONS	SHORTENING	LENGTHENING	POST OP WEIGHT BEARING	DAY OF DISCHARGE	HHS 1ST MONTH	HHS 3RD MONTH	HHS 6TH MONTH	FUNCTIONAL OUTCOME
										PRE-OP	POST-OP									
1	NAGAMMA	37711	65	F	16-11-2019	TT	L	NIL	DM	-	1	-	-	-	5	12	77	82	85	Good
2	MAHADEVAPPA	37694	62	M	20-11-2019	RTA	L	NIL	-	-	-	-	-	<1	5	12	85	89	91	Excellent
3	RAMADEVI	39927	66	F	04-12-2019	TT	R	NIL	HTN	-	-	-	-	-	3	7	86	89	91	Excellent
4	DANAMMA	39114	60	F	11-12-2019	TT	R	NIL	HTN, ANE	1	-	-	-	-	5	12	82	82	85	Good
5	KALAVATI	43752	67	F	30-12-2019	TT	L	NIL	-	-	1	-	-	-	5	12	77	82	85	Good
6	CHANAMMA	41200	78	F	01-01-2020	TT	R	NIL	ANE	2	-	BED SORE, UTI	<1	-	11	12	62	65	65	Poor
7	DANDAPPA	1359	70	M	22-01-2020	TT	R	NIL	BA	-	-	-	<1	-	3	5	82	85	87	Good
8	NAGAMMA	3251	60	F	05-02-2020	TT	L	NIL	IHD, HTN	1	-	-	-	-	5	5	85	87	87	Good
9	PADMAVATI	5431	65	F	20-02-2020	TT	L	NIL	-	-	-	-	-	-	3	5	89	91	93	Excellent
10	NINGAMMA	6946	62	F	05-03-2020	TT	R	NIL	DM	-	1	BED SORE	-	-	12	17	74	75	76	Fair
11	SHANTAPPA	12769	65	M	16-05-2020	TT	L	NIL	BA	-	-	-	<1	-	3	5	85	89	89	Good
12	VALIBAI	13924	70	F	05-06-2020	TT	R	DER	HTN	-	-	-	-	<1	21	12	75	77	82	Good
13	ISMAIL	15571	80	M	25-06-2020	TT	R	NIL	HTN, DM	1	1	SUPERFICIAL INFECTION	-	-	7	12	75	75	76	Fair
14	KALAPPA	2363	62	M	08-09-2020	TT	L	NIL	-	-	-	-	-	-	3	5	89	91	93	Excellent
15	SARASWATI	17131	75	F	10-11-2020	TT	L	NIL	DM	-	-	-	-	-	5	12	77	82	85	Good
16	PARSHWANATH	21285	65	M	02-12-2020	TT	R	NIL	-	-	-	-	-	<1	5	12	85	89	91	Excellent
17	MAHADEVI	23677	70	F	10-12-2020	TT	L	NIL	DM	-	1	UTI	-	-	7	12	75	75	76	Fair
18	MALLIKARJUN	52664	60	M	18-01-2021	TT	R	NIL	-	-	-	-	-	-	3	5	89	91	93	Excellent
19	FATIMA	56621	62	F	28-01-2021	TT	R	NIL	HTN	-	1	-	<1	-	3	5	85	89	89	Good
20	DANDAPPA	87397	60	M	09-02-2021	RTA	R	NIL	-	-	-	-	-	-	5	7	82	85	85	Good
21	LAXMAN	10384	63	M	23-02-2021	TT	R	NIL	ANE	1	-	-	-	-	5	12	82	82	85	Good
22	ASHOK	134134	62	M	12-03-2021	RTA	R	NIL	ANE	1	-	-	-	-	3	5	85	89	91	Excellent
23	SOWBHAGYA	134029	63	F	15-03-2021	TT	R	NIL	ANE	1	1	-	-	-	5	12	77	82	85	Good
24	REKHA	134091	62	F	15-03-2021	TT	L	NIL	-	-	-	-	-	-	3	5	86	89	91	Excellent
25	SABU BAJANTRI	123451	60	M	19-03-2021	TT	R	NIL	-	-	-	-	<1	-	3	5	82	85	87	Good