

Non-Hodgkin's Lymphoma Presenting as a Soft Tissue Mass on Right Thigh

SANJEEVKUMAR NEELAKANTAPPA BENTOOR¹, SAVITRI MALLIKARJUN NERUNE², R NIKITHA³

ABSTRACT

Non-Hodgkin's Lymphomas (NHL) are a heterogeneous group of lymphoproliferative malignancies with a greater preference for disseminating to extranodal locations. Prevalence of extranodal involvement in NHL has increased in the past decade, and the sites involved are the stomach, spleen, waldeyer's ring, Central Nervous System (CNS), lungs and skin. This is a rare case of NHL in a 48-year-old female who presented with solitary exophytic mass with ulceration over the right thigh and erythematous plaque over postaxillary region and enlarged right inguinal and left axillary lymph nodes. Magnetic Resonance Imaging (MRI) of the right thigh showed lobulated mass involving skin and subcutaneous soft tissues without any intramuscular extension suggestive of neoplastic mass. Fine needle aspiration cytology of the inguinal node and biopsy of the right thigh lesion showed features suggestive of NHL. She was treated with three cycles of Cyclophosphamide, Hydroxydaunorubicin, Oncovin and Prednisone (CHOP) regimen, but the patient succumbed to death after six months of chemotherapy.

Keywords: Cutaneous lymphoma, Extranodal involvement, Lymph node

CASE REPORT

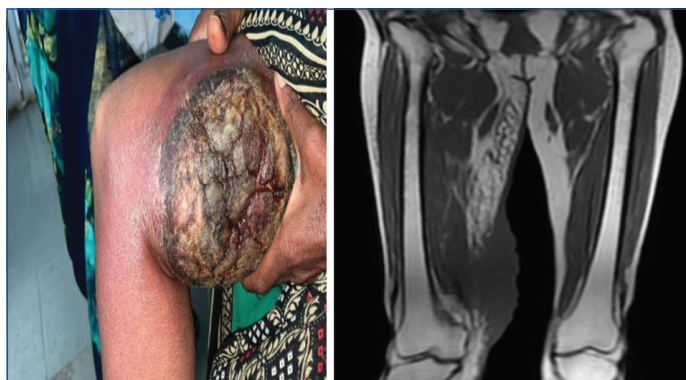
A 48-year-old female presented with an ulcerated lesion over the medial aspect of the right thigh and a lesion over the left posterior axillary fold. Right thigh soft tissue mass was initially noted as small localised swelling gradually progressed to an ulcerated lesion over one year, associated with loss of appetite for 15 days, not associated with pain or fever or discharge. There was no significant personal and family history.

On general physical examination, a solitary exophytic mass was noted, measuring 20x15 cm on the posterolateral aspect of the right thigh with crusting over the surface and erythema around. The lesion was seen extending superiorly about 10 cm from the anterior superior iliac spine and inferiorly 3-4 cm from the knee joint. The swelling was hard in consistency, tender, bleeds on touch, with the local rise of temperature, non mobile on quadriceps muscle contraction with a plane of swelling being intramuscular. Right inguinal node was palpable, measured 3x3 cm and was firm to hard in consistency. Peripheral pulsations over the right lower limb were felt [Table/Fig-1]. Solitary erythematous indurated plaque over postaxillary fold with axillary lymphadenopathy was also noted.

On routine investigations, haemoglobin was normal, total leukocyte count was 14640 cells/cumm. Liver function test showed an increase in total bilirubin (5.10 mg/dL), alkaline phosphatase (475 U/L), whereas urine routine and renal function tests were within normal range with serology being negative.

Ultrasonography (USG) abdomen and pelvis showed no significant abnormality, Magnetic Resonance Imaging (MRI) of right thigh showed 16x10x8 cm sized lobulated mass involving skin and subcutaneous soft tissues in the medial aspect of the distal thigh, encasing subcutaneous vein, and compressing underlying muscles without any intramuscular extension suggestive of neoplastic mass [Table/Fig-2]. A large 3x3 cm enlarged right inguinal node was noted. Fine needle aspiration cytology of the inguinal node showed features suggestive of NHL. A biopsy of the thigh mass was done and sent for histopathological examination.

On microscopic examination, partially encapsulated tumour tissue was noted to be comprised of a monomorphic population of tumour cells arranged in diffuse sheets. Individual tumour cells were small to medium sized with hyperchromatic nuclei and a scanty amount of cytoplasm. Hyalinised vessels surrounded by whorls of cells

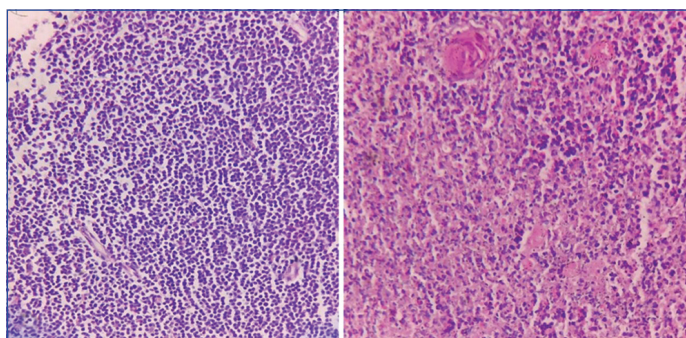


[Table/Fig-1]: Ulcerated thigh swelling.

[Table/Fig-2]: A 16x10x8 cm lobulated mass with skin and subcutaneous soft tissues involved but no intramuscular extension was visible on magnetic resonance imaging of the right thigh, suggestive of a neoplastic mass. (Images from left to right).

arranged in onion peel pattern noted. Abnormal mitotic figures 2-3/ High Power Field (HPF) were also noted as focal areas of necrosis, nuclear debris, many apoptotic bodies, a few bizarre cells and neutrophils [Table/Fig-3,4]. Based on these features, a diagnosis of Non-Hodgkin's Lymphoma (NHL)/Castleman disease was suspected and immunohistochemistry was suggested.

On immunohistochemistry, neoplastic cells were positive for Cluster Differentiation 3 (CD3), CD5, D43, B-cell lymphoma 2 (Bcl2) focal positivity for CD4 and CD7 noted, cells were negative for CD10,

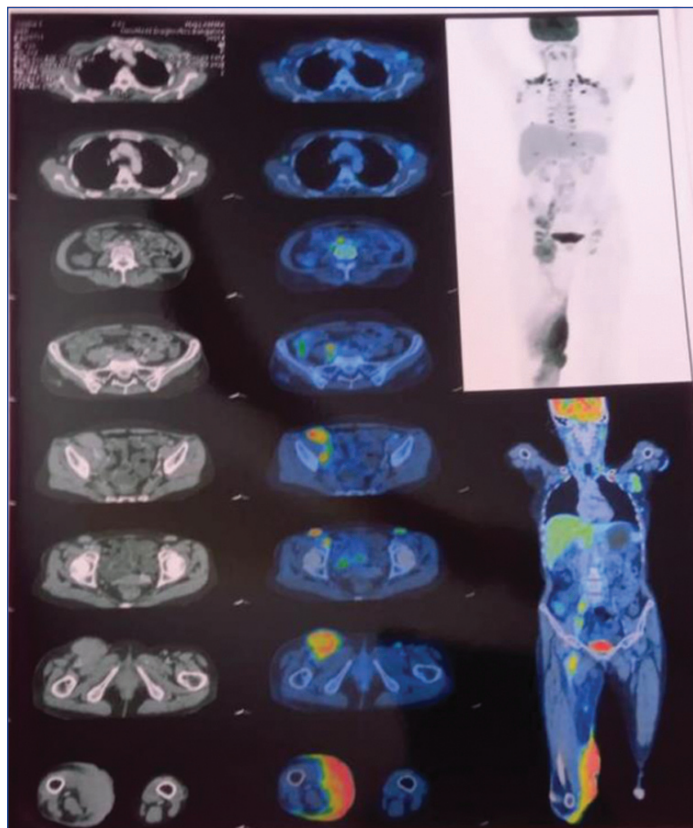


[Table/Fig-3]: Tumour tissue comprised of monomorphic population of tumour cells arranged in diffuse sheets (H&E stain, 400X).

[Table/Fig-4]: Areas of necrosis and apoptotic bodies (H&E, 400X). (Images from left to right).

CD56, cyclin D1, Bcl6, CD23, CD8, Terminal deoxynucleotidyl Transferase (TdT), granzyme and perforin. Immunomorphology favoured diagnostic of peripheral T cell lymphoma.

Fluorodeoxyglucose-positron emission tomography showed disease involvement in metabolically active supra and infra diaphragmatic lymph nodes, skin and subcutaneous lesions around the right thigh, knee and around the left upper arm [Table/Fig-5].



[Table/Fig-5]: F18 Fluorodeoxyglucose-Positron Emission Tomography (FDGPET) Computed Tomography (CT) scan showing disease involvement in metabolically active supra and infra diaphragmatic lymph nodes, skin and subcutaneous lesions.

The therapy involving doxorubicin-based combination chemotherapy {Cyclophosphamide, Hydroxydaunorubicin, Oncovin and Prednisone (CHOP)} was initiated and three cycles were given. Unfortunately, the patient succumbed to death after six months of chemotherapy.

DISCUSSION

Non-hodgkin's lymphoma is a heterogeneous group of lymphoproliferative disorders originating in B, T and natural killer lymphocytes [1]. The extranodal disease is lymphomatous infiltration of anatomic sites other than lymph nodes. Prevalence of extranodal involvement in NHL has increased in the past decade, and the most common areas involved are the stomach, spleen, waldeyer's ring, Central Nervous System (CNS), lungs and skin [2]. Cutaneous lymphoma manifests either as a primary tumour or as a secondary manifestation as a disseminated disease. Primary cutaneous lymphoma has been the second most prominent group of NHL [3].

Non-hodgkin's lymphoma is a lymphoid tissue neoplasm originating from B cell precursors, mature B cells and mature T cells. NHL is divided into indolent and aggressive courses based on disease prognosis [4]. Indolent lymphomas are follicular lymphoma, chronic lymphocytic leukaemia/small lymphocytic lymphoma, and splenic marginal zone lymphoma with waxing and waning lymphadenopathy [4]. Aggressive lymphomas present with weight loss, fever, night sweats called as B symptoms. These include large B cell lymphoma, Burkitt lymphoma, precursor B and T cell lymphoblastic leukaemia/lymphoma, adult T cell leukaemia/lymphoma, and certain other peripheral T cell lymphomas [4].

Immunosuppression, ultraviolet radiation, viruses and other infections such as Epstein-Barr virus, Human T-lymphotropic Virus (HTLV), Human Herpes Virus-8 (HHV8), Hepatitis C, Simian Virus 40 (SV40), *Helicobacter pylori* would be potential risk factors to develop NHL. Occupational exposure to pesticides including phenoxy acids, organophosphates, and organochlorines, as well as chronic inflammatory and autoimmune disorders such as rheumatoid arthritis, sjogren's syndrome, and Systemic Lupus Erythematosus (SLE) add to risk factors for NHL [5]. A potential risk factor, in this case, would be immunosuppression or viral aetiology.

Chromosomal translocation, mutation, or deletion is another factor that leads to NHL. Chromosomal translocation activates proto-oncogenes, whereas chromosomal deletion or mutation inactivates tumour suppressor genes. The most prevalent chromosomal aberration in NHL is the t (14;18) translocation [6].

The most typical sites for extranodal lymphomas are lower limb, especially in the thigh (25%), followed by the retro-peritoneum (16%), then the upper limb (11%), unusual sites of extranodal lymphoma are gastrointestinal tract, thyroid, bone, brain, testis, soft tissue, kidney, liver, breast and skin [7,8]. The differential diagnosis include benign masses and malignant tumours such as soft tissue sarcomas, metastatic melanoma, metastatic carcinoma (small cell carcinoma of the lung), malignant bone tumours involving soft tissue (Ewing sarcoma) and lymphomas [7].

Nodular or diffuse are the histologic pattern described. In the nodular pattern the neoplastic cells aggregate in cluster form. In diffuse pattern, there is monotonous distribution of cells, within the lymph node, without any indication of nodularity or the establishment of germinal centers [9]. In the indexed case diffuse pattern was noted.

Cytology helps in differentiating lymphomas from other soft tissue related cancers. A further biopsy is required for doing immunohistochemistry, subtyping and a definitive diagnosis of lymphoma. Avoiding ineffective radical surgery prevents morbidity and also provides a reliable clinical parameter to assess therapy success and response [7].

Non-hodgkin's lymphoma is commonly treated by chemotherapy, radiotherapy, immunotherapy, stem cell transplant, and in rare cases surgery. Radiation is the primary treatment for early stage of tumour [10]. Common adverse effects of chemotherapy are myelosuppression immunosuppression, and neutropenic fever. Myelosuppression can be treated by transfusions (red cells and platelets) or by administration of colony-stimulating factors (e.g., granulocyte colony-stimulating factor) [4].

Peripheral T cell lymphoma being the most probable diagnosis in this indexed case by immunohistochemistry represents a heterogeneous group of rare haematologic malignancies accounting for less than 10% of NHL [11]. These lymphomas are clinically distinguished by superficial, hyperkeratotic patches and plaques or localised or disseminated eruptive papules, nodules, and tumours revealing core ulceration and necrosis. BetaF1+, CD3+, CD8+, granzyme B+, perforin+, TIA-1+, CD45RA+, CD45RO-, CD2-, CD4-, CD5-, and CD7-/+ phenotypes are present in the tumour cells [12]. CHOP or CHOP-like regimen is considered the standard treatment with newly diagnosed Peripheral T cell lymphoma. Autologous stem cell transplantation's role has been investigated to prevent the high relapse rate in chemosensitive patients [13].

Extranodal NHL is uncommon, accounting for 0.1% of soft tissues lymphoma cases [14]. When they initially manifest, soft tissue lymphomas are termed primary, if other disease sites in staging process are not involved. An early excision biopsy is required to confirm the diagnosis of malignant neoplasms and ascertain the histological subtype. The best treatment option for NHL of the soft tissues is chemotherapy or radiotherapy [15].

To be distinguished between soft tissue sarcoma and lymphoma; clinical history, physical examination, and MRI would be non concluding, therefore pathological diagnosis should be made prior to surgery [16].

CONCLUSION(S)

Soft tissue lymphomas represent an infrequent entity. It is essential to differentiate soft tissue lymphomas from soft tissue sarcomas. Prior histopathological diagnosis from biopsy tissue plays an important diagnostic role in avoiding amputation of a limb. A soft tissue lymphoma should always be considered in the differential diagnosis of a suspected soft tissue sarcoma.

REFERENCES

- [1] Singaraju S, Patel S, Sharma A, Singaraju M. Non Hodgkins lymphoma--A case report and review of literature. *Journal of Oral and Maxillofacial Pathology: JOMFP*. 2020;24(2):322.
- [2] Puranik AD, Agrawal A, Purandare N, Shah S, Rangarajan V. Four rare extranodal sites seen on FDG PET/CT in a single patient of disseminated lymphoma. *Indian Journal of Medical and Paediatric Oncology*. 2013;34(02):101-03.
- [3] Paes FM, Kalkanis DG, Sideras PA, Serafini AN. FDG PET/CT of extranodal involvement in non Hodgkin lymphoma and Hodgkin disease. *Radiographics*. 2010;30(1):269-91.
- [4] Sapkota S, Shaikh H. Non Hodgkin Lymphoma. [Updated 2022 May 1]. In: StatPearls [Internet]. Treasure Island (FL): StatPearls Publishing; 2022 Jan-. Available from: <https://www.ncbi.nlm.nih.gov/books/NBK559328/>.
- [5] Fisher SG, Fisher RI. The epidemiology of non Hodgkin's lymphoma. *Oncogene*. 2004 Aug;23(38):6524-34. Fisher SG, Fisher RI. The epidemiology of non Hodgkin's lymphoma. *Oncogene*. 2004;23(38):6524-34.
- [6] Nogai H, Dörken B, Lenz G. Pathogenesis of non Hodgkin's lymphoma. *Journal of Clinical Oncology*. 2011;29(14):1803-11.
- [7] Knowles B, Serpell JW. Extra-nodal lymphoma presenting as a mimic of soft-tissue sarcoma. *ANZ Journal of Surgery*. 2003;73(1-2):26-30.
- [8] Thomas AG, Vaidhyanath R, Kirke R, Rajesh A. Extranodal lymphoma from head to toe: part 1, the head and spine. *American Journal of Roentgenology*. 2011;197(2):350-56.
- [9] Singh R, Shaik S, Negi BS, Rajguru JP, Patil PB, Parihar AS, et al. Non Hodgkin's lymphoma: A review. *Journal of Family Medicine and Primary Care*. 2020;9(4):1834.
- [10] Shanbhag S, Ambinder RF. Hodgkin lymphoma: A review and update on recent progress. *CA: A Cancer Journal for Clinicians*. 2018;68(2):116-32.
- [11] Rangoonwala HI, Cascella M. Peripheral T-Cell Lymphoma. [Updated 2022 Aug 8]. In: StatPearls [Internet]. Treasure Island (FL): StatPearls Publishing; 2022 Jan-. Available from: <https://www.ncbi.nlm.nih.gov/books/NBK562301/>
- [12] Willemze R, Cerroni L, Kempf W, Berti E, Facchetti F, Swerdlow SH, et al. The 2018 update of the WHO-EORTC classification for primary cutaneous lymphomas. *Blood, The Journal of the American Society of Hematology*. 2019;133(16):1703-14.
- [13] Rogers AM, Brammer JE. Hematopoietic cell transplantation and adoptive cell therapy in peripheral T cell lymphoma. *Current Hematologic Malignancy Reports*. 2020;15(4):316-32.
- [14] Jena M. Primary lymphoma of the soft tissue: a pathologist's perspective. *Journal of Clinical and Diagnostic Research*. 2018;12(12):ED19-ED20.
- [15] Corti M, Villafañe MF, Bismans A, Campitelli A, Narbaitz M. Soft-tissue masses as presentation of non Hodgkin's lymphoma in AIDS patients. *Anais Brasileiros de Dermatologia*. 2013;88:631-34.
- [16] Rochwerger A, Mattei JC. Management of soft tissue tumors of the musculoskeletal system. *Orthopaedics & Traumatology: Surgery & Research*. 2018;104(1):S9-17.

PARTICULARS OF CONTRIBUTORS:

1. Professor, Department of General Medicine, B.M. Patil Medical Sciences and Research Centre, Vijayapura, Karnataka, India.
2. Associate Professor, Department of Pathology, B.M. Patil Medical Sciences and Research Centre, Vijayapura, Karnataka, India.
3. Junior Resident, Department of General Medicine, B.M. Patil Medical Sciences and Research Centre, Vijayapura, Karnataka, India.

NAME, ADDRESS, E-MAIL ID OF THE CORRESPONDING AUTHOR:

Dr. Savitri Mallikarjun Nerune,
Associate Professor, Department of Pathology, B.M. Patil Medical Sciences and Research Centre, Vijayapura-586013, Karnataka, India.
E-mail: saviraj31@gmail.com

AUTHOR DECLARATION:

- Financial or Other Competing Interests: None
- Was informed consent obtained from the subjects involved in the study? Yes
- For any images presented appropriate consent has been obtained from the subjects. Yes

PLAGIARISM CHECKING METHODS: [Jan H et al.]

- Plagiarism X-checker: Jul 04, 2022
- Manual Googling: Nov 09, 2022
- iThenticate Software: Nov 19, 2022 (9%)

ETYMOLOGY: Author Origin

Date of Submission: **Jul 02, 2022**
Date of Peer Review: **Aug 12, 2022**
Date of Acceptance: **Nov 22, 2022**
Date of Publishing: **Mar 01, 2023**