



# Occupational hand injury by snap button machine

Sandeep Naik , Sharanagoud Honnagol , Santosh Nandi

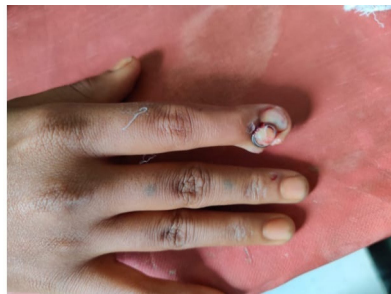Orthopaedics, BLDE Deemed to be University, Vijayapura, Karnataka, India

**Correspondence to**  
Dr Sandeep Naik;  
sandeep.naik@bldedu.ac.in

Accepted 31 July 2023

## DESCRIPTION

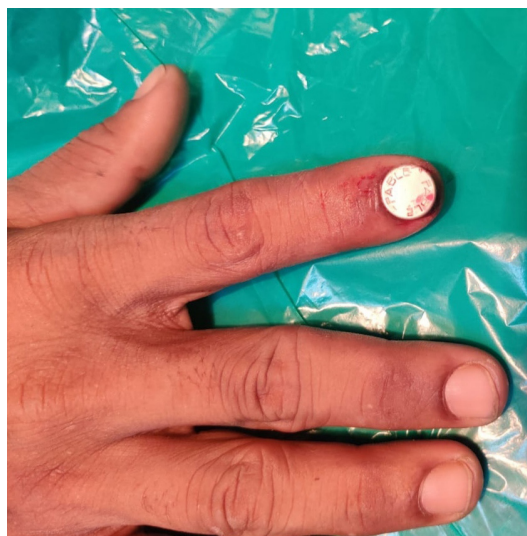The revolution in industry and agriculture has led to a rise in the occurrence of hand injuries, which make up almost 10% of visits to hospital emergency departments.<sup>1-3</sup> More than half of these injuries result from hands becoming trapped in active machinery.<sup>4</sup> Accidents involving snap button machines can result in severe injuries, which may involve bone, tendon, muscle, nerve and vessel.<sup>5</sup>



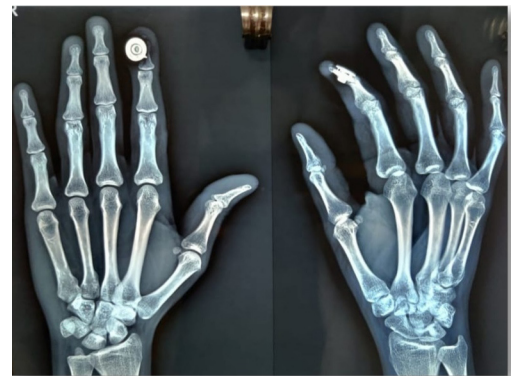
**Figure 1** Preoperative clinical image of case 1.



**Figure 2** Preoperative clinical image of case 1.

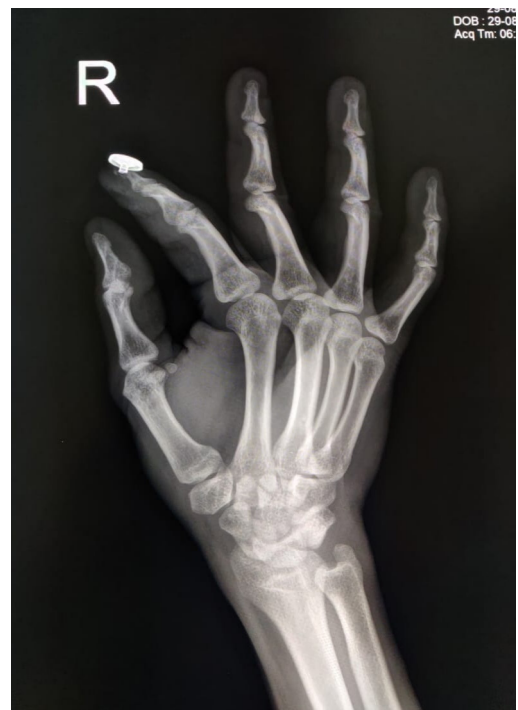

**Figure 3** Preoperative clinical image of case 2.



**Figure 4** Preoperative X-ray images of case 1.

We present two cases of work-related snap button injury to the index finger. Cases 1 and 2 (figures 1 and 2, figure 3), both of which presented with wound and crush injury to the right index finger with the button fixed to the pulp, involving soft tissue and the distal phalanx. Both patients arrived at the emergency department within an hour of their injuries, complaining of pain and compromised vascularity of the soft tissue distal and surrounding to the button. However, contamination was minimal. A plain radiograph (figures 4 and 5) of the affected hand and basic blood tests for surgery were performed. Both cases were given a course of injections of ceftriaxone with sulbactam as preoperative prophylaxis. After appropriate counselling, both



**Figure 5** Preoperative X-ray image of case 2.

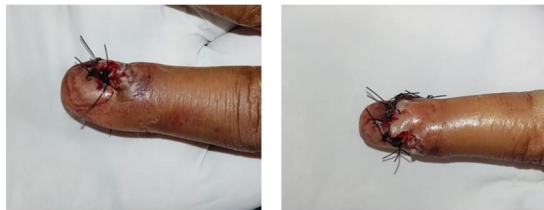 Check for updates

© BMJ Publishing Group Limited 2023. No commercial re-use. See rights and permissions. Published by BMJ.

**To cite:** Naik S, Honnagol S, Nandi S. *BMJ Case Rep* 2023;**16**:e255337. doi:10.1136/bcr-2023-255337

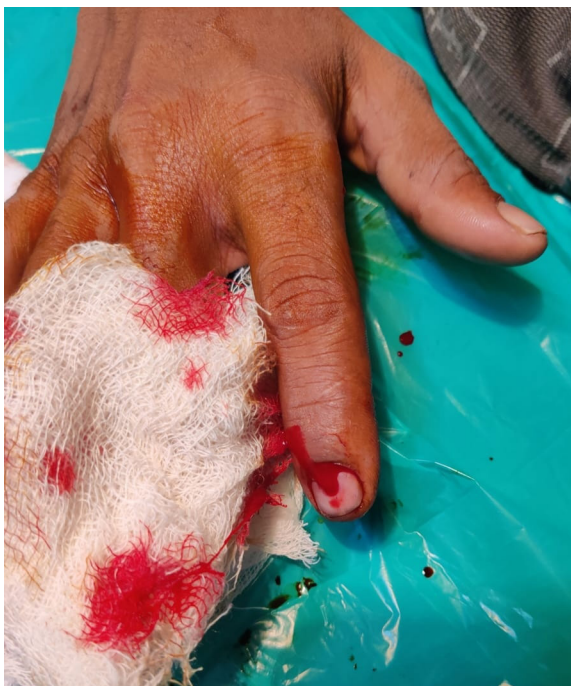

**Figure 6** Components of snap button.

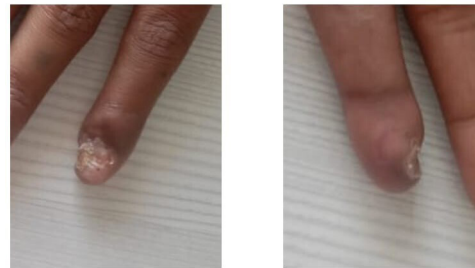

**Figure 7** Postoperative clinical image of case 1.

cases underwent emergency surgery under regional anaesthesia for disengagement of the button. The snap button is composed of two rings as shown (figure 6), one with sharp prongs and one with slots for these prongs, which interlock when manually or machine applied to a cloth. Until the ring with prongs is cut, the system will not disengage, and if removal is attempted by pulling, it can sever the soft tissue that is caught in between the rings, resulting in the amputation of the affected part. The ring with prongs was cut with a K-wire cutter, and each prong was straightened individually. Both rings were then dismantled. The wound was debrided, and primary closure was performed in both cases (figures 7 and 8). After wound inspection,



**Figure 8** Postoperative clinical image of case 2.



**Figure 9** Follow-up clinical image at 1 month.

the patients were discharged on the third day after continuing antibiotics for 3 days. Both cases had uneventful recoveries and were able to return to work without any disability. Both patients had pain-free movement at the end of 1 month, with no further complications related to the wound or sensation (figure 9). However, the scar from the injury remained, but apart from the cosmetic issue, full functional recovery was achieved at the end of the month. Both cases were counselled and educated on the prevention of future accidents of this type and the necessary precautions to take.

### Learning points

- ▶ In cases of snap button injuries, it is crucial to seek emergency medical attention immediately to prevent further damage.
- ▶ Emergency surgery under regional anaesthesia can be performed to disengage the button and prevent amputation of the affected part.
- ▶ Patients with snap button injuries can achieve full functional recovery after proper treatment, although the scar from the injury may remain as a cosmetic issue.

**Contributors** The following authors were responsible for drafting of the text, sourcing and editing of clinical images, investigation results, drawing original diagrams and algorithms, and critical revision for important intellectual content: SNaik, SH and SNandi. The following authors gave final approval of the manuscript: SNaik, SH and SNandi.

**Funding** The authors have not declared a specific grant for this research from any funding agency in the public, commercial or not-for-profit sectors.

**Competing interests** None declared.

**Patient consent for publication** Consent obtained directly from patient(s).

**Provenance and peer review** Not commissioned; externally peer reviewed.

Case reports provide a valuable learning resource for the scientific community and can indicate areas of interest for future research. They should not be used in isolation to guide treatment choices or public health policy.

### ORCID iDs

Sandeep Naik <http://orcid.org/0000-0002-1545-8722>

Sharanagoud Honnagol <http://orcid.org/0009-0000-8479-6074>

### REFERENCES

- 1 Lese AB, Waggy CA. Hand and finger injuries: tendon and soft tissue injuries of the hand. *FP Essent* 2021;500:28–32.
- 2 Campbell DA, Kay SPJ. The hand injury severity scoring system. *J Hand Surg* 1996;21:295–8.
- 3 Saaiq M. Occupational hand trauma: can we do something to reduce the sufferings of our poor workers? *Ann Pak Inst Med* 2007;3. Available: [https://www.researchgate.net/publication/236018777\\_OCCUPATIONAL\\_HAND\\_TRAUMA\\_CAN\\_WE\\_DO\\_SOMETHING\\_TO\\_REDUCE\\_THE\\_SUFFERINGS\\_OF\\_OUR\\_POOR\\_WORKERS](https://www.researchgate.net/publication/236018777_OCCUPATIONAL_HAND_TRAUMA_CAN_WE_DO_SOMETHING_TO_REDUCE_THE_SUFFERINGS_OF_OUR_POOR_WORKERS)
- 4 Vollman D, Khosla K, Shields BJ, et al. Lawn mower-related injuries to children. *J Trauma* 2005;59:724–8.
- 5 Bindra RR. Management of nail-bed fracture-lacerations using a tension-band suture. *J Hand Surg Am* 1996;21:1111–3.

Copyright 2023 BMJ Publishing Group. All rights reserved. For permission to reuse any of this content visit <https://www.bmj.com/company/products-services/rights-and-licensing/permissions/>  
BMJ Case Report Fellows may re-use this article for personal use and teaching without any further permission.

Become a Fellow of BMJ Case Reports today and you can:

- ▶ Submit as many cases as you like
- ▶ Enjoy fast sympathetic peer review and rapid publication of accepted articles
- ▶ Access all the published articles
- ▶ Re-use any of the published material for personal use and teaching without further permission

#### **Customer Service**

If you have any further queries about your subscription, please contact our customer services team on +44 (0) 207111 1105 or via email at [support@bmj.com](mailto:support@bmj.com).

Visit [casereports.bmj.com](http://casereports.bmj.com) for more articles like this and to become a Fellow