

Multiple Firm Swellings in a Middle-Aged Woman

A woman in her 50s presented with asymptomatic slow growing swellings over the neck and bilateral feet since

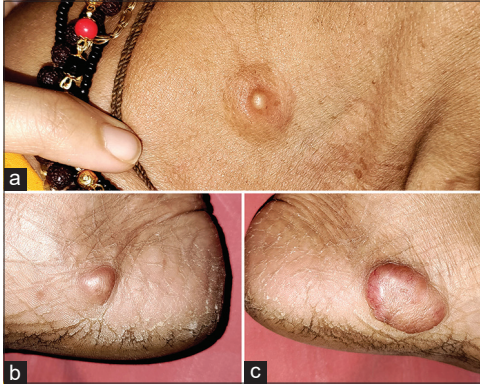

Figure 1: Well-defined firm skin-colored nodules over the right side of the neck (a) and medial aspects of the right (b), and left (c) feet near the heels

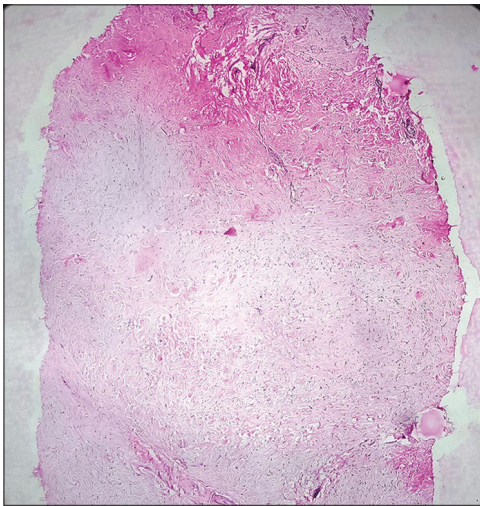


Figure 2: Dermal tumor comprised of widely spaced spindle-to-stellate shaped cells embedded in extensive collagenous stroma. [H and E, $\times 4$]

the past 2 years. Examination revealed three well-defined, firm, non-tender skin-colored nodules over the right side of the neck (about 2×2 cm), and medial aspects of the right (about 1×2 cm) and left (about 4×3 cm) feet near the heels [Figure 1a-c]. The nodule on the neck showed a central white umbilication [Figure 1a]. A 4 mm punch biopsy obtained from the lesion on the neck revealed a hypocellular dermal tumor comprised of widely spaced bland spindle-to-stellate shaped cells embedded in extensive collagenous stroma. Sparse inflammatory cell infiltrate comprised of lymphocytes and mast cells along with occasional entrapped adnexal structures were also noted [Figures 2 and 3].

What is the Diagnosis?

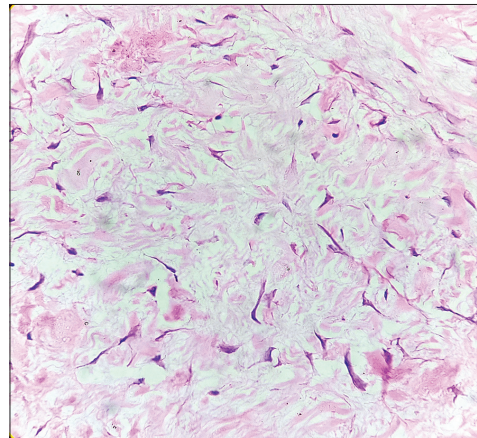


Figure 3: High power view showing widely spaced spindle-to-stellate shaped cells within thick collagen bundles exhibiting normal cellular architecture and absence of mitotic activity. [H and E, $\times 40$]

**Keshavmurthy A. Adya,
Arun C. Inamadar**

Department of Dermatology,
Venereology and Leprosy, Shri
B M Patil Medical College,
Hospital and Research
Center, BLDE (Deemed to
be University), Vijayapur,
Karnataka, India

Address for correspondence:
Dr. Arun C. Inamadar,
Department of Dermatology,
Venereology and Leprosy, Shri
B M Patil Medical College,
Hospital and Research
Center, BLDE (Deemed to be
University), Vijayapur -586 103,
Karnataka, India.
E-mail: aruninamadar@gmail.com

This is an open access journal, and articles are distributed under the terms of the Creative Commons Attribution-NonCommercial-ShareAlike 4.0 License, which allows others to remix, tweak, and build upon the work non-commercially, as long as appropriate credit is given and the new creations are licensed under the identical terms.

For reprints contact: WKHLRPMedknow_reprints@wolterskluwer.com

How to cite this article: Adya KA, Inamadar AC. Multiple firm swellings in a middle-aged woman. Indian Dermatol Online J 2023;14:746-7.

Received: 03-Jan-2023. **Revised:** 16-Feb-2023.

Accepted: 18-Feb-2023. **Published:** 25-May-2023.

Access this article online

Website: <https://journals.lww.com/idoj>

DOI: 10.4103/idoj.idoj_7_23

Quick Response Code:



Answer

Collagenous fibroma (desmoplastic fibroblastoma).

Discussion

Collagenous fibroma (CF) is a rare benign fibroblastic tumor, first described by Evans in 1995 as a series of 7 cases.^[1] Thereafter, Miettinen *et al.* described the largest series of 63 cases in 1998.^[2] It arises commonly from the subcutis or skeletal muscle and may rarely arise from the dermis and bone. Collagenous fibroma is considered a tumor than a reactive process, based on its slow growth, persistence, and ability to attain large size. Chromosomal translocations t (2;11) and t (11;17), affecting 11q12 along with over-expression of FOSL1 protein has been noted in this tumor.^[3]

Collagenous fibroma commonly affects the extremities of middle-aged to elderly males. Involvement of unusual sites (oral and genital) has also been described. Clinically, it is a well-defined painless, non-tender, and slow-growing mass ranging in size from 1 cm to as large as 20 cm. Histologically, it is characterized by a paucicellular tumor comprised of widely spaced fibroblasts within thick abundant collagen bundles in a fibromyxoid background. The fibroblasts are stellate or spindle-shaped and appear reactive, being uniform in shape, size, and without/negligible mitotic activity. The tumor is generally well-defined, although occasional infiltration into muscle and adipose tissue, and entrapment of adnexae may be seen. Immunohistochemically, CF shows diffuse positivity with vimentin and focal positivity with actin, desmin, cytokeratin, and S-100. Staining for β -catenin, EMA, and CD34 is negative. Simple excision is curative without any recurrences.^[2,3]

Although CF is slow growing and asymptomatic, instances of rapidly growing, symptomatic, as well as tumors resolving spontaneously have been described.^[2-4] Intraosseous and synovial tumors eroding bone have been described as well.^[4,5] Other soft tissue masses exhibiting

fairly uniform stellate or spindle shaped cells in a fibromyxoid stroma include a wide variety of benign tumors (e.g., nodular fasciitis, tendon sheath fibroma, nuchal fibroma), locally infiltrating tumors (e.g., fibromatosis), and malignant tumors (e.g., low grade fibromyxoid sarcoma).^[2,3] None of the available literature on CF describes multiple lesions in the same patient (including the largest series) as in this case.

Declaration of patient consent

The authors certify that they have obtained all appropriate patient consent forms. In the form, the patient has given her consent for her images and other clinical information to be reported in the journal. The patient understands that her names and initials will not be published and due efforts will be made to conceal her identity, but anonymity cannot be guaranteed.

Financial support and sponsorship

Nil.

Conflicts of interest

There are no conflicts of interest.

References

1. Evans HL. Desmoplastic fibroblastoma. A report of seven cases. *Am J Surg Pathol* 1995;19:1077-81.
2. Miettinen M, Fetsch JF. Collagenous fibroma (desmoplastic fibroblastoma): A clinicopathologic analysis of 63 cases of a distinctive soft tissue lesion with stellate-shaped fibroblasts. *Hum Pathol* 1998;29:676-82.
3. Alcántara-González J, Pérez González YC, Rodríguez-Lopez T. Rapidly growing tumor on the left big toe. *Actas Dermosifiliogr (Engl Ed)* 2021;112:167-8.
4. Osipov V, Carrera GF. Collagenous fibroma (desmoplastic fibroblastoma) with vertebral body erosion. *Sarcoma* 2009;2009:682687.
5. Beggs I, Salter DS, Dorfman HD. Synovial desmoplastic fibroblastoma of hip joint with bone erosion. *Skeletal Radiol* 1999;28:402-6.