

# Spontaneous occurrence and expulsion of a massive Steinstrasse.

Vinay Kundargi, Santosh Patil, Vikas Shukla, Siddanagouda B Patil

Urology, Shri BM Patil Medical College, Bijapur, Karnataka, India

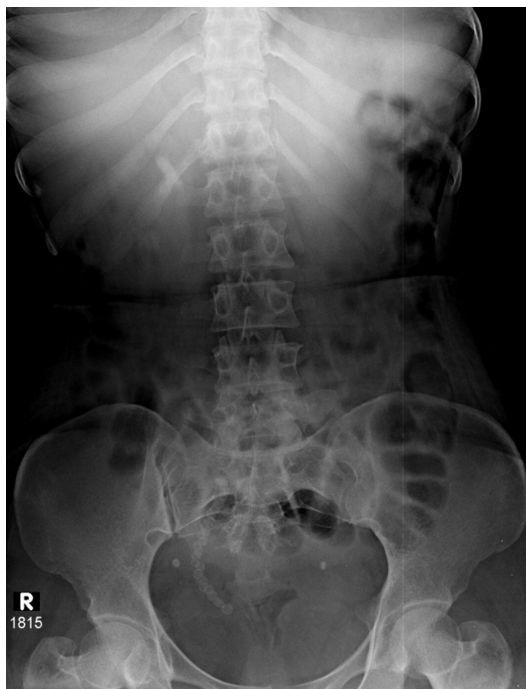**Correspondence to**  
Dr Vikas Shukla;  
vikasshukla060690@gmail.com

Accepted 13 February 2024

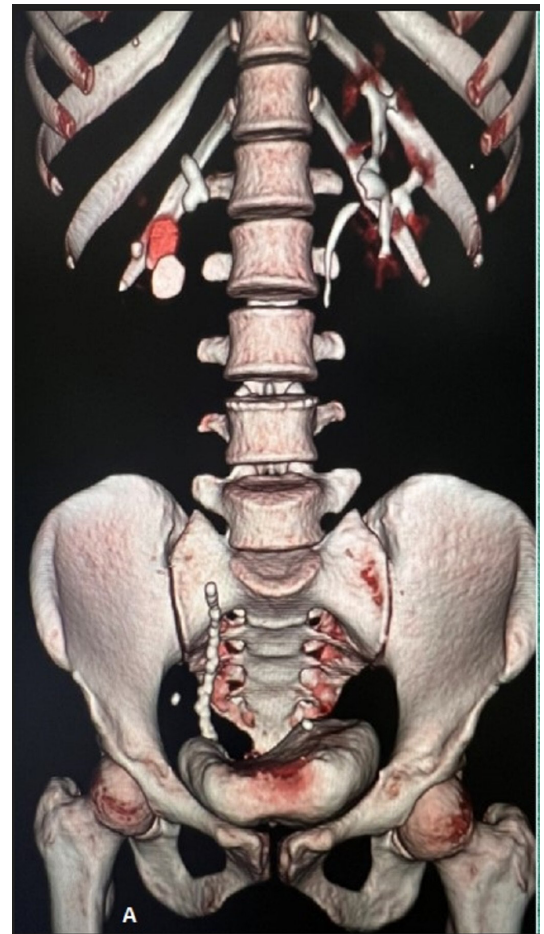
## DESCRIPTION

Steinstrasse is the accumulation of ureteric stone fragments causing a ureteric blockage, mainly occurring after renal stones treatment. Steinstrasse clears spontaneously; however, about 6% require intervention.<sup>1</sup> Spontaneous steinstrasse without a history of extracorporeal shockwave lithotripsy (ESWL) is a rare occurrence, and only a few cases are reported in the literature.<sup>2</sup> Management options of steinstrasse discussed in the literature include a conservative approach, ESWL, ureteroscopy and rarely open surgery.<sup>3</sup> Conservative management of steinstrasse included a meticulous follow-up for 3–4 weeks, antibiotics and analgesics.<sup>4</sup>

A female patient in her 30s presented with pain in the right side of the abdomen for 1 month. She also reported burning micturition and fever 10 days ago. The complete blood count and urine routine examination were normal, and the serum creatinine was 0.9 mg/dL. X-ray KUB (X-Ray of Kidney ureter and bladder) (see [figure 1](#)) and USG KUB (Ultrasound of Kidney ureter and bladder) showed radio-opaque shadows in the right distal ureter region and the right renal shadow region. CT urogram (see [figure 2](#)) was suggestive of a large linear hyperdense calculus of about



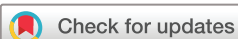**Figure 1** X-ray KUB with radio-opaque shadows in the right distal ureter region.



**Figure 2** CT urogram with three-dimensional reconstruction with right steinstrasse and renal calculus.

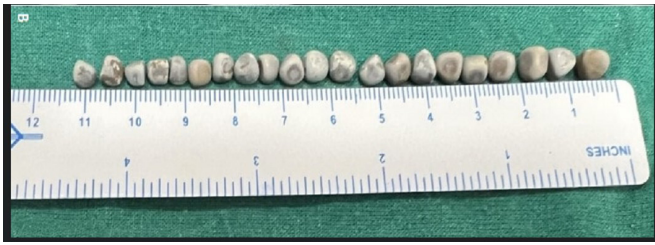10–12 cm in length and 8 mm in width from the iliac crossing to the distal ureter. We have done a complete metabolic evaluation of the patient which was normal and renal tubular acidosis was ruled out.

Ureteroscopic lithotripsy with percutaneous nephrolithotomy (PCNL) was planned. However, the patient spontaneously passed around 24–25 calculi (out of which 21 could be retrieved) (see [figure 3](#)) of sizes 3–8 mm. X-ray KUB after the spontaneous passage of ureteric calculi confirmed no evidence of radio-opaque shadow (see [figure 4](#)) in the right ureteric region. For the renal calculi, PCNL was performed (see [figure 5](#)). Kidney and ureteric stones were analysed via the FTIR (Fourier Transform Infrared Spectroscopy) method. The main composition of the stone was calcium oxalate monohydrate (online supplemental figure 1).



© BMJ Publishing Group Limited 2024. No commercial re-use. See rights and permissions. Published by BMJ.

**To cite:** Kundargi V, Patil S, Shukla V, et al. *BMJ Case Rep* 2024;**17**:e259065. doi:10.1136/bcr-2023-259065



**Figure 3** Spontaneously expelled calculus.

**Types of steinstrasse:** (Radiological grading) Coptcoat *et al*<sup>5</sup>

Type 1: Multiple small fragments most commonly seen (after renal calculus treatment);

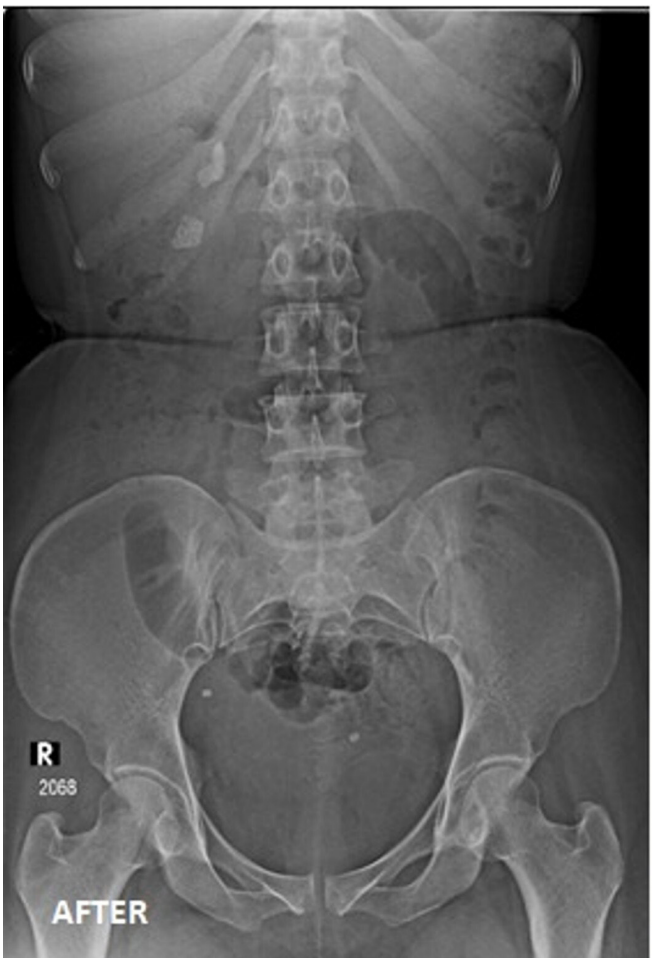Type 2: Distal large fragment of >5 mm obstructing proximal small fragments;

Type 3: Multiple large fragments.

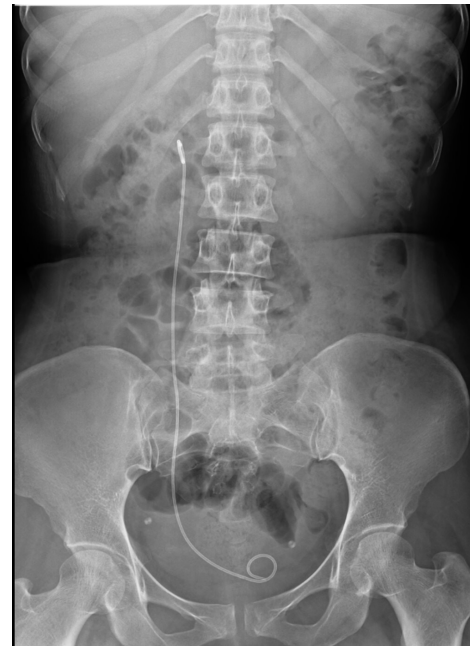Our case is categorised under type 3 steinstrasse.

A similar study by Tezcan *et al* reported the spontaneous passage of stones.<sup>6</sup>

Deirdre *et al* concluded in their study that the spontaneous passage rate for stones 1 mm in diameter was 87%; for stones 2–4 mm, 76%; for stones 5–7 mm, 60%; for stones 7–9 mm, 48% and for stones larger than 9 mm, 25%. Spontaneous passage rate as a function of stone location was 48% for stones in the proximal ureter, 60% for mid-ureter, 75% for distal ureter stones and 79% for ureterovesical junction



**Figure 4** X-ray KUB after the spontaneous passage.



**Figure 5** Post-percutaneous nephrolithotomy X-ray KUB with double J stent in situ.

stones.<sup>7</sup> Spontaneous passage of steinstrasse formed after renal interventions occur in 50%–60% of cases, but these are mainly small fragments belonging to type 1 or 2. Only in rare cases are type 3 fragments formed after treatment of renal stones, and their expulsion requires intervention. This report mentions large fragments belonging to grade 3. The literature does not mention the spontaneously formed steinstrasse's expulsion rate, and the formation or expulsion behaviour is difficult to predict.

#### Learning points

- ▶ Steinstrasse occurs most commonly in renal stone treatment but can occur spontaneously.
- ▶ Symptoms range from no to severe acute pain and can be managed with a conservative, medical, endoscopic or surgical approach.
- ▶ Retrograde pyelogram with double J stenting should be an intervention in an emergency setting.

**Contributors** The following authors were responsible for the drafting of the text, sourcing and editing of clinical images, investigation results, drawing original diagrams and algorithms, and critical revision of important intellectual content: VS, VK, SP and SBP. The following authors gave final approval of the manuscript: VK and SP.

**Funding** The authors have not declared a specific grant for this research from any funding agency in the public, commercial or not-for-profit sectors.

**Competing interests** None declared.

**Patient consent for publication** Consent obtained directly from patient(s).

**Provenance and peer review** Not commissioned; externally peer reviewed.

**Supplemental material** This content has been supplied by the author(s). It has not been vetted by BMJ Publishing Group Limited (BMJ) and may not have been peer-reviewed. Any opinions or recommendations discussed are solely those of the author(s) and are not endorsed by BMJ. BMJ disclaims all liability and responsibility arising from any reliance placed on the content. Where the content includes any translated material, BMJ does not warrant the accuracy and reliability of the translations (including but not limited to local regulations, clinical guidelines,

terminology, drug names and drug dosages), and is not responsible for any error and/or omissions arising from translation and adaptation or otherwise.

Case reports provide a valuable learning resource for the scientific community and can indicate areas of interest for future research. They should not be used in isolation to guide treatment choices or public health policy.

## REFERENCES

- 1 Parmar K, Manoharan V, Kumar S, *et al.* Large spontaneous steinstrasse: our experience and management issues in the tertiary care center. *Urologia* 2022;89:226–30.
- 2 Rabbani SMR. Treatment of steinstrasse by transureteral lithotripsy. *Urol J* 2008;5:89–93.
- 3 Goyal R, Dubey D, Khurana N, *et al.* Does the type of steinstrasse predict the outcome of expectant therapy *Indian J Urol* 2006;22:135.
- 4 Abdulmajed MI, Anandaram PS, Wyn Jones V, *et al.* Massive steinstrasse without lithotripsy: a rare case report. *Turk J Urol* 2013;39:61–3.
- 5 Coptcoat MJ, Webb DR, Kellet MJ, *et al.* The steinstrasse: a legacy of ESWL. *Eur Urol* 1988;14:93–5.
- 6 Tezcan E, Burrell R, Bell DJ, *et al.* Spontaneous resolution of a spontaneous steinstrasse: a case report. *J Surg Case Rep* 2018;2018:rjy252.
- 7 Coll DM, Varanelli MJ, Smith RC. Relationship of spontaneous passage of ureteral calculi to stone size and location. *AJR Am J Roentgenol* 2002;178:101–3.

Copyright 2023 BMJ Publishing Group. All rights reserved. For permission to reuse any of this content visit <https://www.bmj.com/company/products-services/rights-and-licensing/permissions/>  
BMJ Case Report Fellows may re-use this article for personal use and teaching without any further permission.

Become a Fellow of BMJ Case Reports today and you can:

- ▶ Submit as many cases as you like
- ▶ Enjoy fast sympathetic peer review and rapid publication of accepted articles
- ▶ Access all the published articles
- ▶ Re-use any of the published material for personal use and teaching without further permission

### Customer Service

If you have any further queries about your subscription, please contact our customer services team on +44 (0) 207111 1105 or via email at [support@bmj.com](mailto:support@bmj.com).

Visit [casereports.bmj.com](http://casereports.bmj.com) for more articles like this and to become a Fellow