

**“DIAGNOSTIC ACCURACY OF RADIOLOGICAL
INVESTIGATIONS IN ACUTE ABDOMEN”**

By

Dr. SIDDALINGAPPA.D.SHIGIHALLI

Dissertation submitted to

BLDE UNIVERSITY, BIJAPUR.

KARNATAKA



In Partial fulfillment of the requirements for the degree of

M.S

in

GENERAL SURGERY

Under the Guidance of

Dr. M.B.PATIL M.S.

PROFESSOR,

DEPARTMENT OF GENERAL SURGERY

B. L. D. E. U'S

**SHRI B. M. PATIL MEDICAL COLLEGE HOSPITAL & RESEARCH
CENTRE, BIJAPUR.**

2011

DECLARATION BY THE CANDIDATE

I hereby declare that this dissertation/thesis entitled “**DIAGNOSTIC ACCURACY OF RADIOLOGICAL INVESTIGATIONS IN ACUTE ABDOMEN**” is a bonafide and genuine research work carried out by me under guidance of **Dr. M.B.PATIL. M.S.**

Date:

Dr. S.D.SHIGIHALLI.

Place: Bijapur

B.L.D.E.U's

SHRI B. M. PATIL MEDICAL COLLEGE HOSPITAL & RESEARCH

CENTRE, BIJAPUR, KARNATAKA

CERTIFICATE BY THE GUIDE

This is to certify that the dissertation entitled “**DIAGNOSTIC ACCURACY OF RADIOLOGICAL INVESTIGATIONS IN ACUTE ABDOMEN**” is a bonafide research work done by **Dr. S.D.SHIGIHALLI**, in partial fulfillment of the requirement for the degree of **M.S in GENERAL SURGERY**.

Date:
Place: Bijapur

DR. M.B.PATIL M.S
PROFESSOR
DEPARTMENT OF GENERAL SURGERY,
B.L.D.E.U's Shri. B. M. PATIL
MEDICAL COLLEGE HOSPITAL &
RESEARCH CENTRE,
BIJAPUR.

B.L.D.E.U's

**SHRI B. M. PATIL MEDICAL COLLEGE HOSPITAL & RESEARCH
CENTRE, BIJAPUR, KARNATAKA**

**ENDORSEMENT BY THE HOD, PRINCIPAL/HEAD OF THE
INSTITUTION**

This is to certify that the dissertation entitled “**DIAGNOSTIC ACCURACY OF RADIOLOGICAL INVESTIGATIONS IN ACUTE ABDOMEN**” is a bonafide research work done by **Dr. S.D.SHIGIHALLI**, under the guidance of **Dr.M.B.PATIL. M.S**, Professor, Department of General Surgery.

Dr.TEJASWINI.U .M.S.
PROFESSOR & HEAD
DEPARTMENT OF GENERAL
SURERY,
B. L. D. E. U's Shri. B. M. PATIL
MEDICAL COLLEGE HOSPITAL
& RESEARCH CENTRE
BIJAPUR.

Date:

Place: Bijapur

Dr. R.C.BIDRI M.D
PRINCIPAL
B. L. D. E. U's Shri. B. M.
PATIL MEDICAL COLLEGE
HOSPITAL & RESEARCH
CENTRE,
BIJAPUR.

Date:

Place: Bijapur

COPYRIGHT

DECLARATION BY THE CANDIDATE

I hereby declare that the Bijapur Liberal District Education University, Karnataka shall have the rights to preserve, use and disseminate this dissertation / thesis in print or electronic format for academic / research purpose.

Date:

Dr. S.D.SHIGIHALLI.

Place: Bijapur

© Bijapur Liberal District Education University, Karnataka

ACKNOWLEDGEMENT

*With proud privilege and deep sense of respect, I express my gratitude and indebtedness to my teacher and guide **Dr.M.B.PATIL**, Professor Department of General Surgery, BLDEU's SHRI B. M. PATIL MEDICAL COLLEGE, BIJAPUR, for his constant inspiration, patience, encouragement and support, which he rendered in preparing this dissertation and in pursuit of my post graduate studies.*

*I am grateful to **Dr. R.C.Bidri**, Principal of BLDEU'S Shri.B.M.Patil Medical College Hospital and Research Centre, Bijapur, for permitting me to conduct this study.*

*I am forever grateful to my Professor and HOD of Surgery **Dr. Tejaswini.U**, and I am forever grateful to my teachers and Professors. **Dr.P.L.Kariholu**, **Dr.A.V.Patil**, **Dr.B.B.Metan**, Associate Professors of Surgery **Dr.S.B.Anantapur**, **Dr.Manjunath.S.Kottenavar**, **Dr.Vijaya.Patil**, **Dr.Prasad.Sasanur**, **Dr B.P.Kattimani**, and also Assistant Professors of Surgery , **Dr.Vikram.S**, **Dr.Nandeesh**, **Dr.S.Agarwal**, **Dr.Sunil Bhairagond**, **Dr. Ashok Biradar** , **Dr. Deepak C**, **Dr. Ramakant B**, **Dr. Hemanth Kumar** , **Dr Ravi G**, for their valuable help, support and guidance when required during my study.*

I am extremely thankful to Mrs.Vijaya Soraganvi, Statistician for her guidance in statistical analysis.

*I am thankful to my seniors **Dr. Nagaraj.H**, **Dr. Pavan Patil**, **Dr Nataraj.B** , **Dr. Praveen chandra** , **Dr. Sapna**, **Dr. Digvijay** , and also to my colleagues **Dr.Sharvani**, **Dr Mandar** , **Dr Manjunath**, **Dr Rishabh** and my juniors **Dr.Jayakrthik,Y** , **Dr. Rashmi Patil**, **Dr. Uday Karjol**, **Dr. Amith M**, **Dr.Deepika.P**, **Dr. Ashish**, **Dr. Dayanand**, **Dr.Ravi**, **Dr.Rohan K** and my friend **Dr.Ashwani** for his cooperation.*

I express my thanks to one and all in Surgery department, medical records section, library staff and all hospital staff for their kind co-operation in my study.

*From the bottom of my heart I convey my heartfelt gratitude to **all my patients** without whose co-operation this study would have been incomplete.*

*No amount of words can measure up to deep sense of gratitude and fullness that I feel towards my parents **Shri D.S.Shigihalli and Smt N.D.Shigihalli** whose cherished blessings and love, are behind whatever success I have achieved in my life.*

I also thank Mr.Kalyankumar.Awati, Preeti computer and internet browsing centre, Ashram road, Bijapur for their help during printing of this dissertation.

Date:

Dr. S.D.Shigihalli.

Place: Bijapur.

LIST OF ABBRAVATIONS USED

BP	-	Blood Pressure
CT Scan	-	Computerized Tomography Scan
Chi Sq	-	Chi square test
F	-	Frequency
GIT	-	Gastro Intestinal Tract
h/o	-	History of
i.e	-	that is
No	-	Number
PR	-	Pulse Rate
t	-	Student's t test

ABSTRACT

Background:

The term ‘acute abdomen’ refers to signs and symptoms of abdominal pain and tenderness- a clinical presentation that often requires emergency surgical therapy.

Acute surgical emergencies constitute 50% of all general surgical admissions and 50% of them are for ‘acute abdomen’, 50% of which requires surgical intervention. Pre-operative diagnosis of acute abdomen with limited facilities is very crucial to minimize the morbidity and mortality in the developing countries like ours, where the facilities of diagnosis are limited, and clinical acumen play a pivotal role in the diagnosis of acute abdomen.

Pre-operative knowledge of cause of acute abdomen has the advantage of enabling formation of detailed operative plan including- incision, operative procedures, instrument preparation, and pre-operative instructions to patients and their family members.

Since acute abdomen is the most common surgical emergency, present study intended to find out the accuracy of clinical methods and radiological investigations in diagnosing the cause for it.

Objectives:

1. To find out the diagnostic accuracy of clinical methods and radiological investigations to achieve definitive diagnosis in patients with acute abdomen.

Method:

This study “DIAGNOSTIC ACCURACY OF RADIOLOGICAL INVESTIGATIONS IN ACUTE ABDOMEN” was carried out at BLDE

UNIVERSITY SHRI B.M.PATIL MEDICAL COLLEGE HOSPITAL, BIJAPUR.

from October 2008 to May 2010.

The 100 patients who form the basis of this study were randomly selected, fulfilling the inclusion and exclusion criteria. These comprised of patients who presented with acute abdominal pain (of non-traumatic origin) at the emergency department, surgical out patient department, surgical wards and patients referred from other departments.

Only those cases that underwent surgery have been included in this study, as the correct diagnosis could be established only then.

Each case was assessed with the help of a specially designed proforma. All cases were subjected to a detailed history and a thorough physical examination to arrive at a clinical diagnosis. The details recorded in the proforma and analysed.

The radiological investigations comprised of plain abdominal x-ray, ultrasonography and CT scan for which no ordering protocol was followed. It was left to the discretion of the treating unit to order the investigation which they felt most appropriate for each case. Radiologic diagnosis was made after the official report by the radiologist. The radiologic investigations were divided into two categories, ones with positive findings were considered diagnostic and the others considered inconsistent.

All the final diagnoses were operative. In all cases the operative findings and post-operative diagnosis were recorded.

As soon as possible after admission routine investigations namely: - Hb%, TC, DC, ESR, Urine routine were carried out. A relevant procedure like four quadrant

aspiration was carried out in some cases. A Widal test was done in suspected cases of enteric fever.

The pre-operative preparation essentially consisted of treating shock, correction of dehydration, gastric aspiration and antibiotic administration.

Treatment was instituted according to the cause of acute abdomen. Complications if any were noted and managed accordingly.

Results:

We found 80% of the x-rays to have positive findings and thus helpful in confirming the suspected diagnosis. In other words, positive x-rays outnumbered the inconsistent ones.

In the present study the overall diagnostic accuracy for ultrasonography was 68.6%, compared to a clinical diagnostic accuracy of 81.18%. However, if only cases of acute appendicitis and acute cholecystitis were considered, the ultrasonographic accuracy rises to 75%. Failure to visualize an inflamed appendix was probably due to dilated bowel loops obstructing the field of study, in these cases.

Thus from our study we can conclude that ultrasonography to be the initial radiologic investigation for acute appendicitis, especially in clinically doubtful cases and also in acute cholecystitis.

In our study, CT scan was called for only in three cases. In two cases it helped to diagnose the cause of acute abdomen. In one case it confirmed the clinical diagnosis of acute cholecystitis, where ultrasonography was normal. In the other case, it picked up a growth in the descending colon. However, CT scan was helpful to diagnose infected pancreatic necrosis in the third case.

Conclusion:

In majority of the cases, it was possible to make an accurate clinical diagnosis after a proper history and physical examination and analyzing the clinical pattern.

The clinical diagnostic accuracy was superior to the diagnostic accuracy obtained by radiological investigations. The diagnosis of acute abdominal pain depends on optimal clinical assessment. There is no substitute for skill in interviewing patients and eliciting physical signs. While further imaging is usually not necessary for patients presenting with classic signs and symptoms of various acute abdominal pathologies, it is the atypical patients that require careful, appropriately tailored diagnostic imaging.

Keywords:

Acute abdomen, clinical, radiological, operative diagnosis.

LIST OF CONTENTS

SL.NO.	CONTENTS	PAGE NO
1	INTRODUCTION	1-2
2	AIMS OF THE STUDY	3
3	REVIEW OF LITERATURE	4-52
4	MATERIALS AND METHODS	53-55
5	RESULTS	56-74
6	DISCUSSION	75-101
7	SUMMARY	102-104
8	CONCLUSION	105
9	BIBLIOGRAPHY	106-115
10	ANNEXURE A)PROFORMA B)CONSENT C)KEY TO MASTER CHART D)MASTER CHART	116-120 121-122 123-124 125-126

LIST OF TABLES

Sl.No.	TABLES	Page No.
1	Causes of acute abdomen as noted at operation	56
2	Age and sex distribution of 100 cases of acute abdomen	58
3	Comparative age distribution of acute appendicitis and peptic ulcer perforation	59
4	The mean age and SD of causes of acute abdomen	60
5	Sex ratio by causes of acute abdomen	61
6	The presenting symptoms in 100 cases of acute abdomen	62
7	Duration of pain in acute abdomen by cause	64
8	Signs in 100 cases of acute abdomen	65
9	Four leading signs in different kinds of acute abdomen	66
10	Correlation between clinical and x-ray diagnosis in 60 cases	71
11	Correlation between clinical and ultrasonographic diagnosis in 44 cases	73
12	Radiologic signs in cases of perforated 'duodenal ulcer' (Plain x-ray abdomen)	92

LIST OF FIGURES

Sl. No.	FIGURES	Page No.
1	Regions and Planes of abdomen	8
2	Abdominal Viscera	10
3	Muscles of the abdominal wall and nerve supply	13
4	Sites of visceral pain	15
5	Sites of referred pain	19
6	Location and character of pain	26
7	Causes of acute abdomen as noted at operation	57
8	Age and sex distribution of 100 cases of acute abdomen	58
9	Comparative age distribution of acute appendicitis and peptic ulcer perforation	59
10	Comparative age distribution of acute appendicitis and peptic ulcer perforation	60
11	The presenting symptoms in 100 cases of acute abdomen	63
12	Signs in 100 cases of acute abdomen	65
13	Picture showing multiple air fluid levels	70
14	Picture showing gas under both domes of diaphragm	70
15	Correlation between clinical diagnosis and no of patients x-rayed	71
16	Correlation between x-ray diagnosis and no of patients x-rayed	72

17	Picture showing normal appendix on ultrasonography	74
18	Picture showing inflammed appendix on ultrasonography	74
19	Picture showing duodenal ulcer perforation	77
20	Picture showing closure of the perforation	77
21	Pictures showing gastric ulcer perforation	79
22	Pictures showing ileal perforation	82
23	Pictures showing acute cholecystitis	86
24	Pictures showing acute necrotizing pancreatitis	90

INTRODUCTION

“Acute abdominal disease is sometimes diagnosed with ease but oft the best attempts will meet with sad and sorrowful defeat”.

- The acute abdomen in rhyme, Zeta 1962⁴⁷

The accurate diagnosis and management of a patient with acute abdominal pain remains one of the most challenging tasks for the surgeon. The wide range of causes and the varied spectrum of patient presentations pose a formidable diagnostic and therapeutic challenge⁷².

The term acute abdomen is loosely defined as a clinical course of abdominal symptoms that can range from minutes to hours to weeks, and is often used synonymously for a condition that requires immediate operation⁷². However those patients who require immediate surgery represent only a subset of patient with an acute abdomen.

History taking and physical examination form the corner stones of diagnosis⁹⁶. Equally important is the investigational confirmation of the suspected diagnosis by laboratory tests and radiologic investigations. In the past 10 years, the ability to accurately determine intra-abdominal pathology by radiologic imaging has allowed earlier and more accurate diagnosis⁹⁶. And in no other speciality has such dramatic transformation taken place⁵.

Imaging of the abdomen traditionally began with plain film radiography⁶⁵. However with the recent advent of new and sophisticated imaging modalities the usefulness of the plain film has been questioned^{19, 86}.

Ultrasonography, of late, has become a routine procedure in many centers to diagnose acute abdominal pain. The advantages being a quick and non-invasive procedure ⁸⁶.

All the more, there has been a recent consensus that new multisectional imaging modalities like CT scan, can provide better information, and some regard as ‘the imaging work horse’ in acute abdominal conditions ^{5,72}. But the question is - Are such new and costly investigations always required to diagnose an acute abdomen, and are they superior to the surgeon’s hard earned clinical acumen, skill and judgment?

In this dissertation, we therefore endeavour to study atraumatic acute abdomen, the various clinical patterns that help to make a clinical diagnosis and the effectiveness of radiological investigations in diagnosing the acute abdomen and its influence on clinical decision making. The emphasis laid here is whether a proper history and clinical examination, coupled with cost effective investigations like plain x-ray or ultrasound can help to prove the diagnosis as later confirmed by operative findings.

The statistical analysis may not be a complete one because of the limitation imposed by selective study of operated cases only, the conservatively managed cases not being taken into account.

AIMS OF THE STUDY

- 1) To assess the association between clinical, radiological and operative findings and thus evaluate clinical diagnostic accuracy and radiological diagnostic accuracy.
- 2) To assess the effectiveness of radiological investigations in diagnosing acute abdominal condition.

REVIEW OF LITERATURE

Historical Aspects ^{56,77,83,96,100,114}

The knowledge of acute abdomen dates back to antiquity. Herodotus described an Egyptian cure by purgative and emetics and clearing of the gut for fecal impaction and intestinal obstruction.

Hippocrates (460 to 377 BC) advocated inflation of the intestine and use of enema in intestinal obstruction. Susrutha recommended that obstruction be treated by incision of the intestine, replacement of the organs after moistening them with honey and butter and sewing up the intestine.

Asphyrius in 300 BC introduced puncture of a bowel as a method of decompression and used it only in cases which failed to respond to any treatment.

The second half of the 19th century saw surgery develop from what the young “Joseph Lister” called it in 1853:- “This bloody and butchery department of healing art”, into a speciality that had a respectable scientific basis and was conducted in a recognizably modern manner.

Exploration of the peritoneal cavity first became feasible in 1846 following the discovery of anesthetic agents by Morton in USA (ether) and Simpson in U.K. (chloroform). However it was not until Lister introduced the principles of antiseptic 20 years later than there became a real possibility of survival after abdominal section.

Even the condition of acute appendicitis, then known by names such as ‘iliac passion’ and ‘perityphilitis’ was not fully understood until the later years of the 19th century. Hancock in 1848, in London successfully drained an appendicular abscess

and removed a fecolith. Williard Parker of New York, in 1867 reported that the appendix ceaci could become gangrenous and perforate to form an abscess.

The term 'acute appendicitis' was coined by Reginald Fitz, Professor of Pathology at Harvard in June 1886. In 1887, T.G.Morton in Philadelphia was the first to make a pre-operative diagnosis of acute-appendicitis, followed by a successful urgent appendectomy. Two years later Mc-Burney of New York pioneered early operative intervention and also devised the muscle splitting incision named after him. In 1902, Treves drained the appendicular abscess of King Edward VII, two days before he was due to be crowned, and made appendicitis a fashionable disease !

Little was written about perforated ulcers of the stomach and duodenum until the 19th Century. It initially was considered as a disease of young women. A perforated gastric ulcer and a perforated duodenal ulcer were first reported in 1727 and 1746 respectively. It is believed that Kriege in 1892 was the first medical practitioner to describe the successful management of a case. He summoned, Heissner, a surgeon (by telegram) to a man of 41 whom Kriege believed had suffered a perforation, and was operated on, at home, under candle light and after a long search a gastric perforation was sutured.

Morse of Norwich and MacLaren of Carlisle described successful surgical management of gastric ulcer perforation in 1894. In the same year Dean from London was the first describe successful suture of a perforated duodenal ulcer. Graham in 1938 recommended the use of omentum to close large perforations.

Ambrose pare (1510-1590) was the first to recognize bowel obstruction as a pathological entity. According to Wangenstein, Praxagoras in the third or fourth century B.C was one of the first to report a surgical operation for strangulated hernia.

In 1885, Greves reported a patient who suffered for 5 days from complete bowel obstruction. Earlier methods of conservative treatment gave way to surgical procedures for bowel obstruction, which was emphasized in Frederick Treves' quote: "It is less dangerous to leap from the Clifton Suspension Bridge than to Suffer from acute intestinal obstruction and decline operation".

In 1896 John B. Murray in Chicago described distinctive features of adynamic ileus and contrasted it with mechanical obstruction.

Robert Lawson Tait in 1879 performed cholecystectomy and his courageous insistence on operative intervention for ruptured ectopic gestation in 1884 qualified him for the title "British Pioneer in surgery of acute abdomen".

In 1893, Roentgen described x-rays. There was a major advance in the field of diagnosis when Schwartz (1911) described the patterns of fluid and gas distribution to be seen in plain x-rays of the obstructed abdomen.

Popper in 1915, demonstrated the usefulness of horizontal beam technique in demonstration of pneumoperitoneum. Kloiber Frankfurt gave a more detailed description in 1919, paying particular attention to the characteristic pattern of gas in distended small intestine and the value of films taken in lateral decubitus position. The earliest article dealing with question of how small a volume of gas could be demonstrated by erect and left lateral decubitus filming was that by Paine and Rigler in 1938.

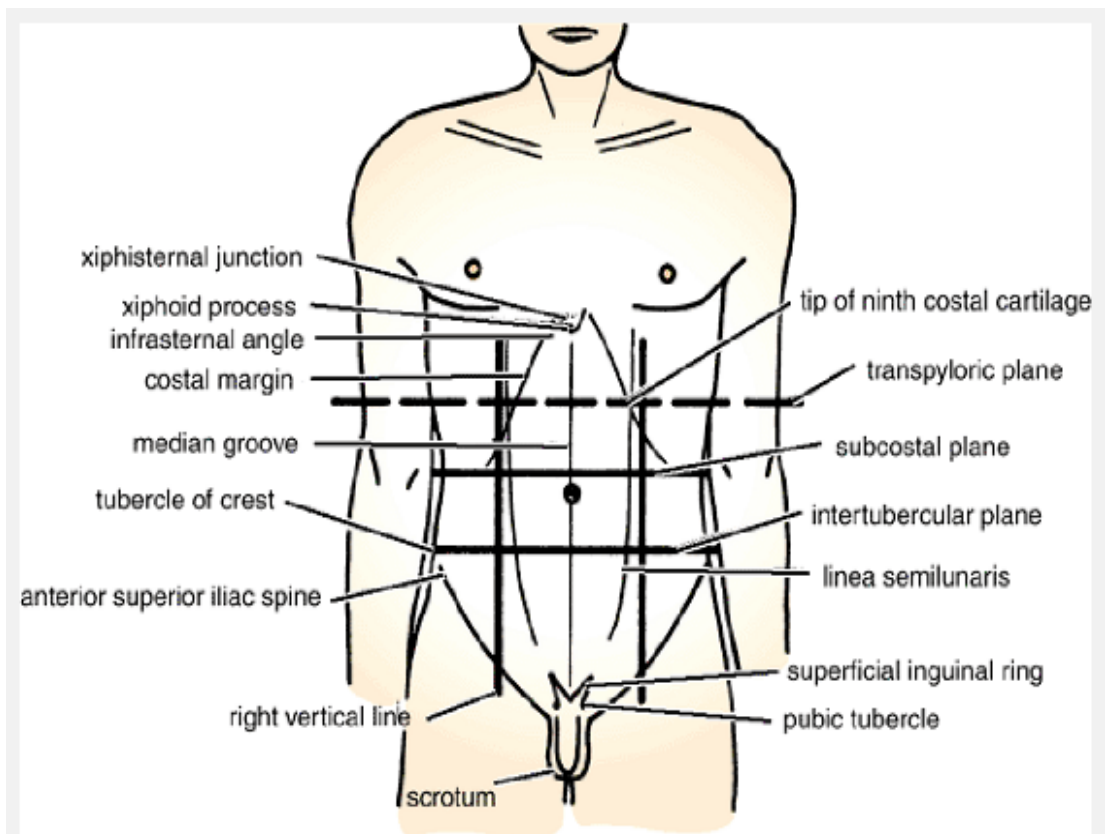
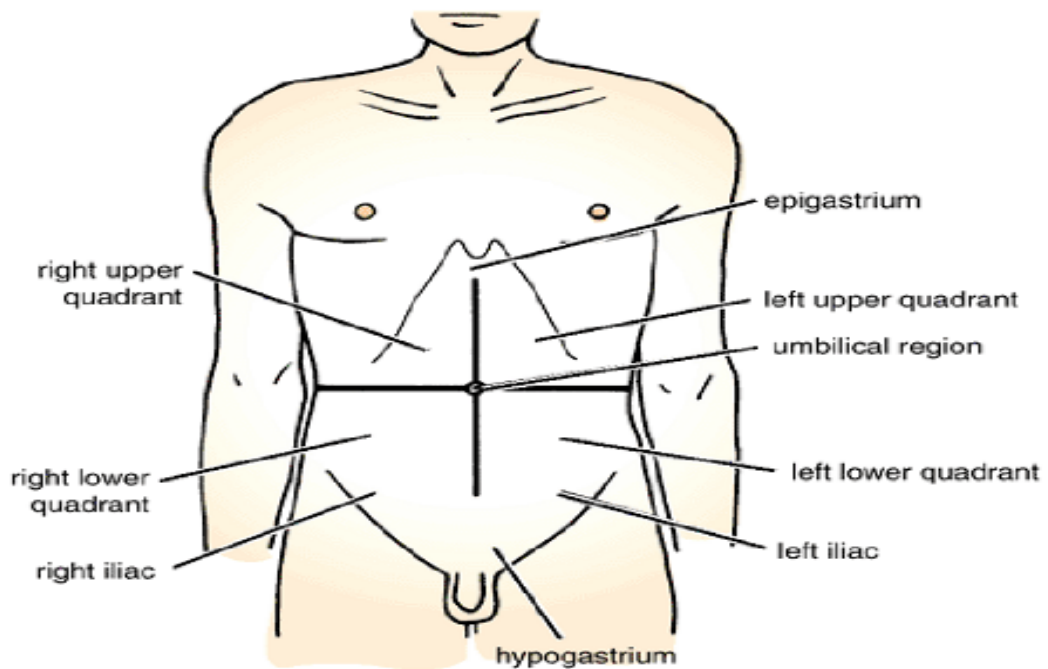
The ultrasonography as an important tool in medical diagnostic imaging was recognised in 1930's and 40's when Theodore Dussik, a psychiatrist and his brother Friedrich attempted to use ultrasound to diagnose brain tumors.

John Julian Wild, used ultrasound to distinguish between mechanical bowel obstruction and ileus, on World War-II victims. He was able to identify 3 distinct layers of intestine by using ultrasound.

Douglas Howry is considered as the pioneer of the modern ultrasound machine. He built the 'somascope' the first compound circumferential scanner.

In June 1958, Ian Donald published the landmark article- "Investigation of abdominal masses by pulsed ultrasound". He popularized the use of ultrasound for localizing intraabdominal abscess. Gold Berg in 1970 suggested its use for early detection of ascites. Tiling, from the University of Cologne, used ultrasonography for evaluation of thorax, retroperitoneum and intraabdominal organs in mid 1980's.

Regions and Planes of abdomen



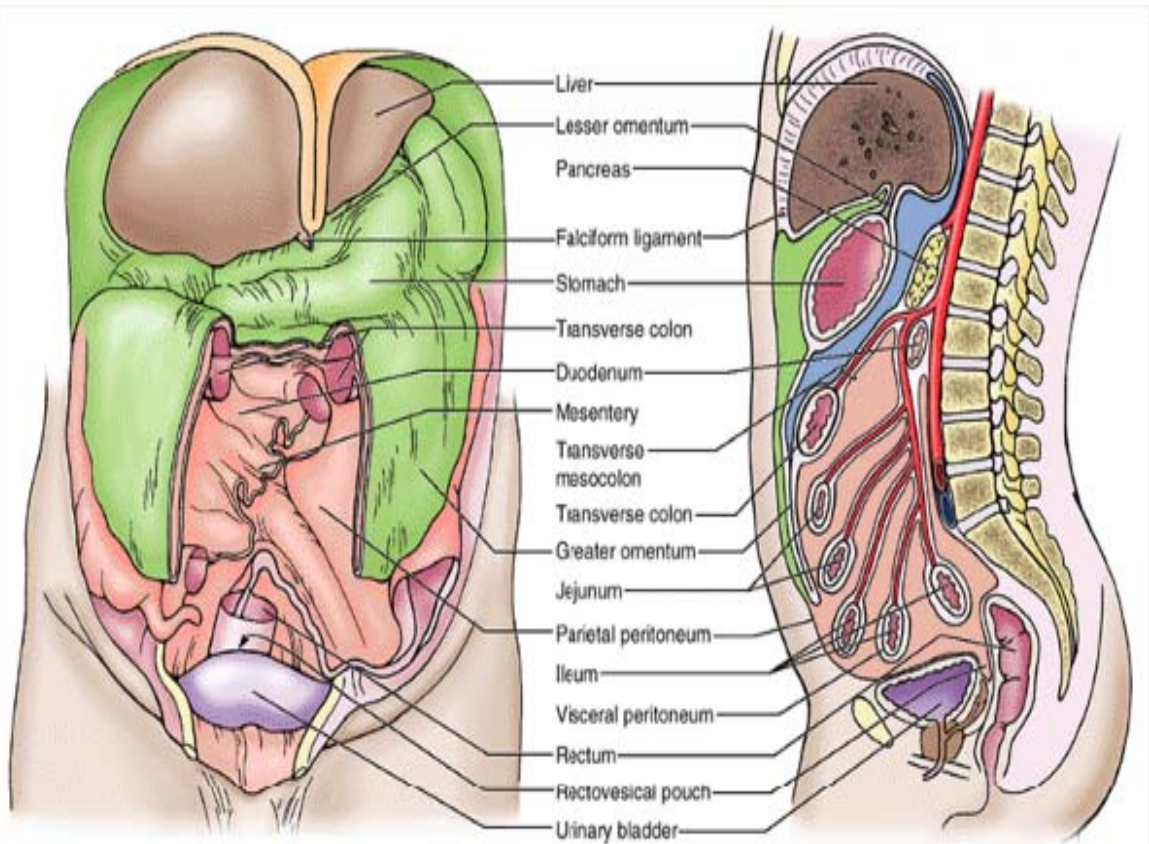
ANATOMIC CONSIDERATIONS^{95,103,105,111,114}

A thorough knowledge of the normal size, position and relationships of the abdominal viscera, including visceral attachments has a significant influence upon localization of signs and symptoms of acute abdominal disease.

The abdominal cavity is much more extensive than the impression gained from examination of the anterior abdominal wall. Much of it lies under cover of the lower ribs, the domes of the diaphragm arch high above the costal margin, hiding beneath it the liver, spleen, much of the stomach and upper poles of the kidneys and both suprarenal's. Below the abdominal cavity extends up to the bases of the pelvis, which accommodates the pelvic organs (rectum, uterus, bladder etc.) and also a good volume of intestine (sigmoid colon and ileum). The abdominal cavity is thus divided into an abdomen proper and lesser pelvis.

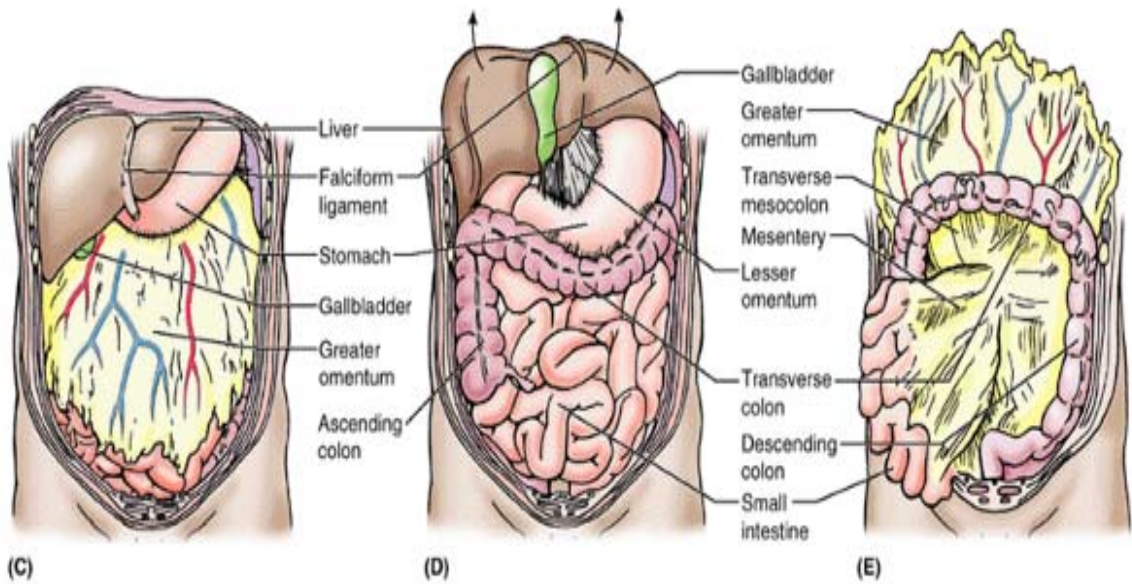
The peritoneal cavity is a potential space lined by a single layer of mesothelial cells, with an average surface area of 1.18 m² (in an adult male) and has the ability to heal by metamorphosis. The two major divisions of the peritoneal cavity, the greater sac and the lesser sac, communicate through the foramen of Winslow. The alimentary canal is invested unevenly. The visceral layer of peritoneum i.e., the layer surrounding intra- abdominal organs (liver, spleen, stomach etc) is tightly adherent to the fibrous visceral stroma by its connective tissue and is supplied by the autonomic (sympathetic/ parasympathetic) nervous system. The loosely attached parietal peritoneum on the other hand is supplied by somatic nerves (spinal nerves). Organs like the kidney. Ureters and vessels like Aorta, Inferior vena cava and part of the gastrointestinal tract like duodenum, ascending colon, and descending colon lie behind the peritoneum and are termed retroperitoneal.

Abdominal Viscera



(A) Anterior view

(B) Left lateral view



(C)

(D)

(E)

For location of the viscera in clinical practice, the abdomen is divided into nine regions (quadrants) by two horizontal and two vertical or parasagittal planes.

1) **Transpyloric plane of Addison:** Runs midway between xiphisternum and the umbilicus.

1. **Transtubercular plane:** Runs at the level of the tubercles of the iliac crest about two inches behind anterior superior iliac spines.

2. The two vertical lines are drawn on either side, midway between the anterior superior iliac spines and pubic symphysis. Also known as “**midclavicular or mammary lines**”.

The use of these quadrants for topographic location of pain, tenderness or masses is a helpful aid to the clinician in arriving at a diagnosis.

One can best illustrate the value of applied anatomy in abdominal diagnosis by considering those structures that are least variable in their position - the voluntary muscles and cerebrospinal nerves. Different muscles like the psoas, the quadratus lumborum, obturator internus, rectus and lateral abdominal muscles which when irritated directly or reflexly by inflammatory changes, become tender and rigid and pain is caused when the muscle fibers are moved (E.g. Copes- psoas test, obturator test).

The rigidity of the diaphragm may be indirectly assessed from impairment of movement of the upper part of the abdominal wall and lower thorax.

The visceral attachments, the peritoneal compartments and spaces (Morrison's pouch, paracolic gutters etc.) influence location and spread of blood, abscess and intra-abdominal fluid within the peritoneal cavity.

ANATOMY AND PHYSIOLOGY OF ABDOMINAL PAIN

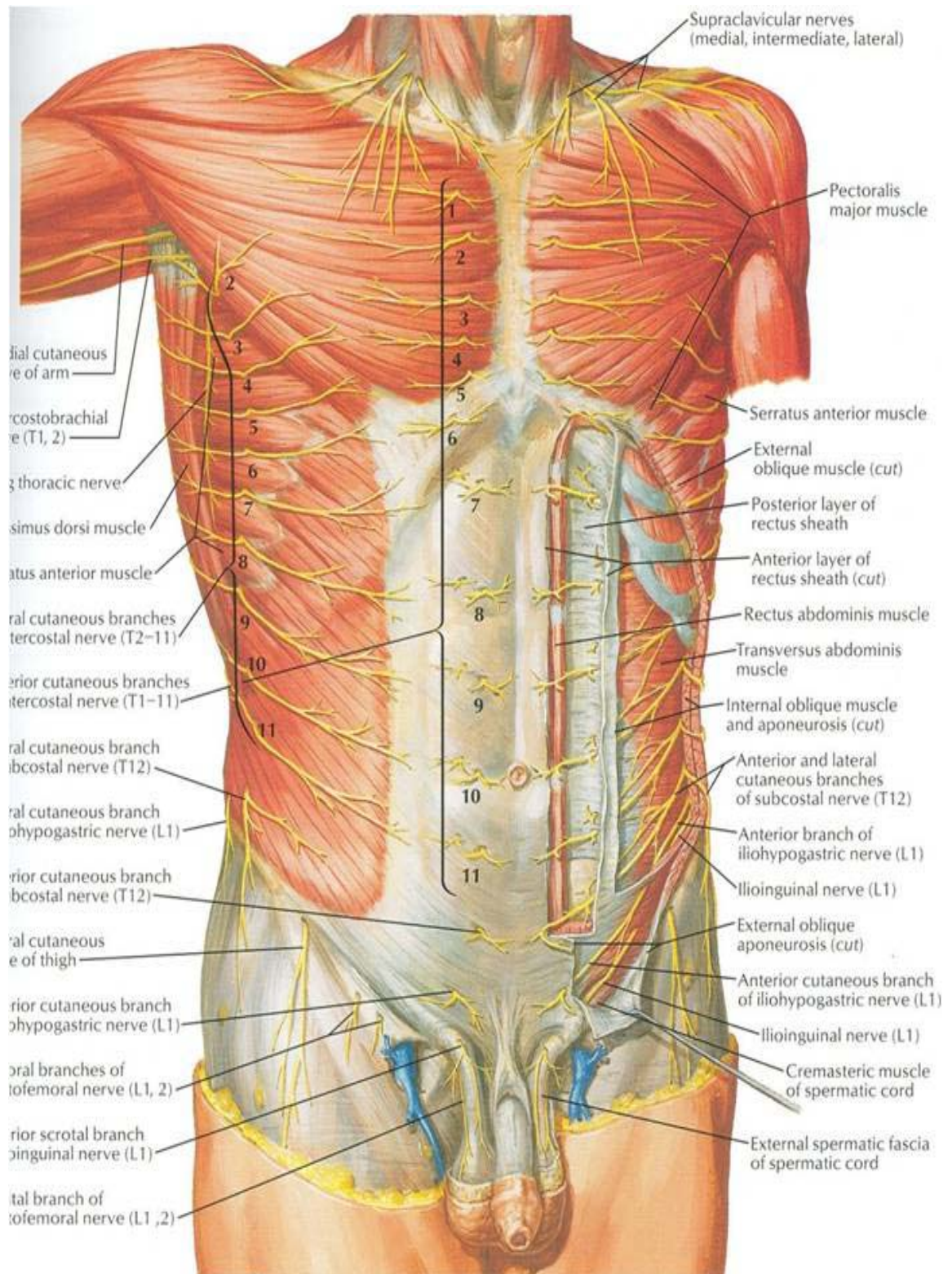
The causes of acute abdominal pain are many, hence a thorough knowledge of the anatomy and physiology of abdominal pain is mandatory, which in turn may point a finger towards the possible cause. Until the twentieth century, the viscera were thought to be completely insensitive. In 1901, Lennander showed that viscera was insensitive to cutting, crushing and burning and that only traction or irritation of parietal peritoneum produced abdominal pain¹⁰⁰. In 1911, Hurst demonstrated that distension of hollow viscus produced pain¹⁰⁰.

Under this context, it would therefore be appropriate to have an insight into the following regarding abdominal pain.

1. Pain receptors and their distribution.
2. Pain producing stimuli and its mechanism.
3. Type of abdominal pain (Visceral, parietal, referred)
4. Pain pathways

1) Pain receptors and their distribution: Primary pain receptors or primary afferent nociceptors comprises mainly of two types of nerve fibres; myelinated A-delta and unmyelinated C type (Gasser's class IV and III according to Lloyd)¹⁰⁵. These fibres are present in the skin, deep somatic and visceral structures. But the difference is that, these fibres in the viscera are relatively insensitive to known mechanical and thermal stimuli under normal circumstances. However in the presence of inflammatory mediators they become highly sensitized and are hence known as silent nociceptors³⁹. The result is that they produce intense, often debilitating pain in a normally insensitive viscus under pathologic conditions.

Muscles of the abdominal wall and nerve supply



Pain producing stimuli and its mechanism : The viscera has somatic pain fibres, and is sparsely innervated by autonomic, slow transmitting 'C' fibres, which are normally insensitive to stimuli that produce pain to skin. There are '4' general classes of visceral stimulation that result in abdominal pain ¹¹⁴.

- a) Change in diameter of hollow viscus – rhythmic stretching and contraction.
- b) Traction, compression and torsion.
- c) Stretch of capsule of solid organs.
- d) Ischemia, chemicals, inflammation.

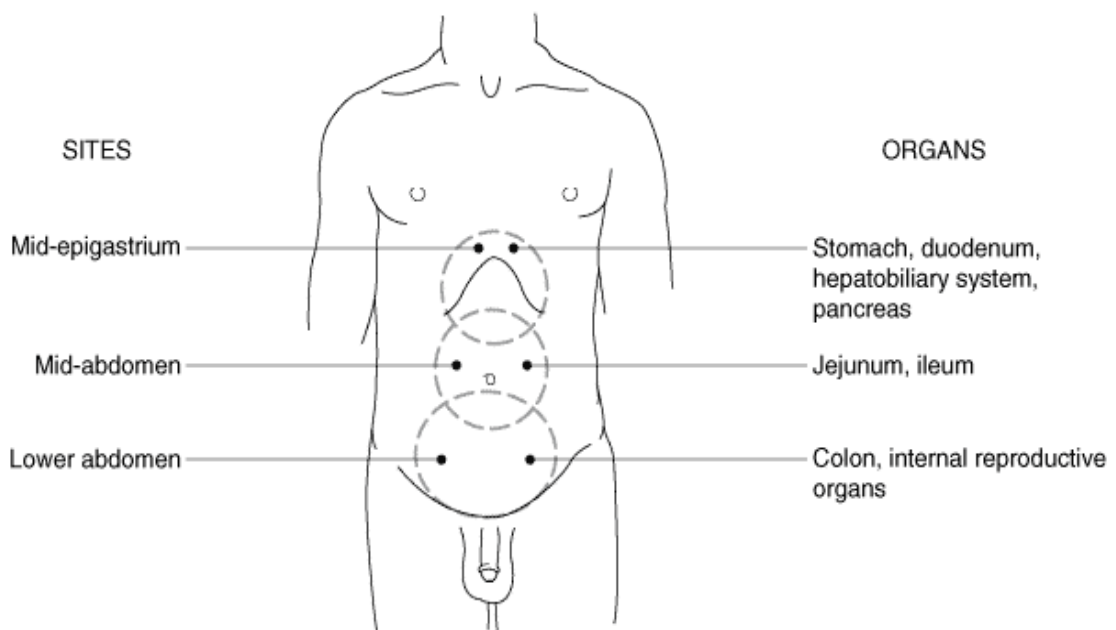
(a), (b) and (c) are brought about by the primary nociceptors which are located intramurally in hollow organs, on serosal structures like visceral peritoneum, capsules of solid organs and intramesenteric. (d) is mainly brought by mucosal receptors.

Pain due to ischemia, inflammation and chemicals is brought about by K^+ ions released during cell damage, prostaglandin(PG) and bradykinin (Inflammatory mediators) causing primary activation and secondary activation brought about by Lewis substance 'P'¹⁴⁵ which causes release of histamine and serotonin (from platelets). Increasing concentrations of H^+ ions, are also hypothesized to cause pain in ischaemia.^{39, 45}

2) Type of abdominal pain ^{39,100,103,114} : Three kinds of pain are commonly described a) visceral b) parietal c) referred.

a) Visceral Pain : This refers to pain arising in the visceral peritoneum and its visceral organs. It has the following features.

- 1) It is perceived as originating in the midline, due to embryonic bilateral midline autonomic innervations.
- 2) Position of the pain in the midline is determined by embryonic origin of the involved viscus. (I.e from foregut, midgut, hind-gut).
- 3) Visceral pain is transmitted by slow velocity 'C' fibres and hence is poorly localized (due to sparse distribution) dull aching in character, gradual in onset and of longer duration.
- 4) Severe visceral pain may be associated with autonomic reflexes like sweating, nausea, vomiting, change in pulse rate, fall in blood pressure and involuntary spastic contractions of abdominal wall musculature (rigidity).



Sites of visceral pain.

b) Parietal Pain : Refers to pain arising from the parietal peritoneum and abdominal wall. Also known as somatic pain.

- 1) It is mediated by A-delta fibres (high velocity) and is therefore perceived as sudden, sharp, well localised (dense distribution) and constant.
- 2) Pain is perceived as arising from a given site, since it is relayed by spinal nerves which enter the spinal cord ipsilaterally. (Anterior and lateral abdominal wall T₇-L₁, posterior abdominal wall (L₂-L₅).
- 3) The stimuli for parietal pain are inflammation, change in pH, pressure changes, chemical and thermal stimuli, movement and change in tension.
- 4) Pelvic parietal peritoneum has no significant pain fibres, hence significant disease can occur in the in the true pelvis without pain detection¹⁰⁰.
- 5) Direct contact with underlying inflamed viscera can produce irritation of the parietal peritoneum to cause pain localized at that site. Eg. McBurney's point in acute appendicitis.

c) Referred Pain: In 1893 Head first used the term 'referred pain' and is defined as the "somatic localization of sensory experiences evoked from the viscera"⁴³. It occurs secondary to shared common central pathways (due to same embryonic origin) for afferent neurons arising from different sites. Mechanisms of "convergence theory" and "facilitation theory" have been postulated⁴⁵, according to which visceral pain afferents entering the spinal cord converge with cutaneous pain afferents to end on a common neuron. The brain then interprets impulses reaching the common pathway as having come from the skin, since previous experience (learned inputs) will have

conditioned it to believe that the common tract was initially stimulated by cutaneous afferents.

Doran FSA (1967)^{31,32} reported that pain from the common bile duct is most commonly referred to epigastrium and the area around the xiphoid. In only '6' out of '56' patients was pain referred to the scapula.

Pain may be referred to the shoulder in cases of subdiaphragmatic abscess acute pancreatitis, ruptured spleen etc, when the terminations of the phrenic nerve on the under surface of the central portion of diaphragm is irritated¹⁰³.

Pain Pathways^{39,100} :

The current and preferable terminology is “visceral afferents”, to denote all afferent fibres from the viscera including those that give rise to visceral reflexes as well as those subserve pain.

Pain impulses from the abdominal cavity reach the central nervous system by 3 routes.

- | | | |
|----------------------------|---|---|
| 1) Sympathetic | } | from viscera via visceral afferents |
| 2) Parasympathetic | | |
| 3) Segmental spinal nerves | | from parietal peritoneum, body wall, diaphragm, mesentery |

Primary Neurons:

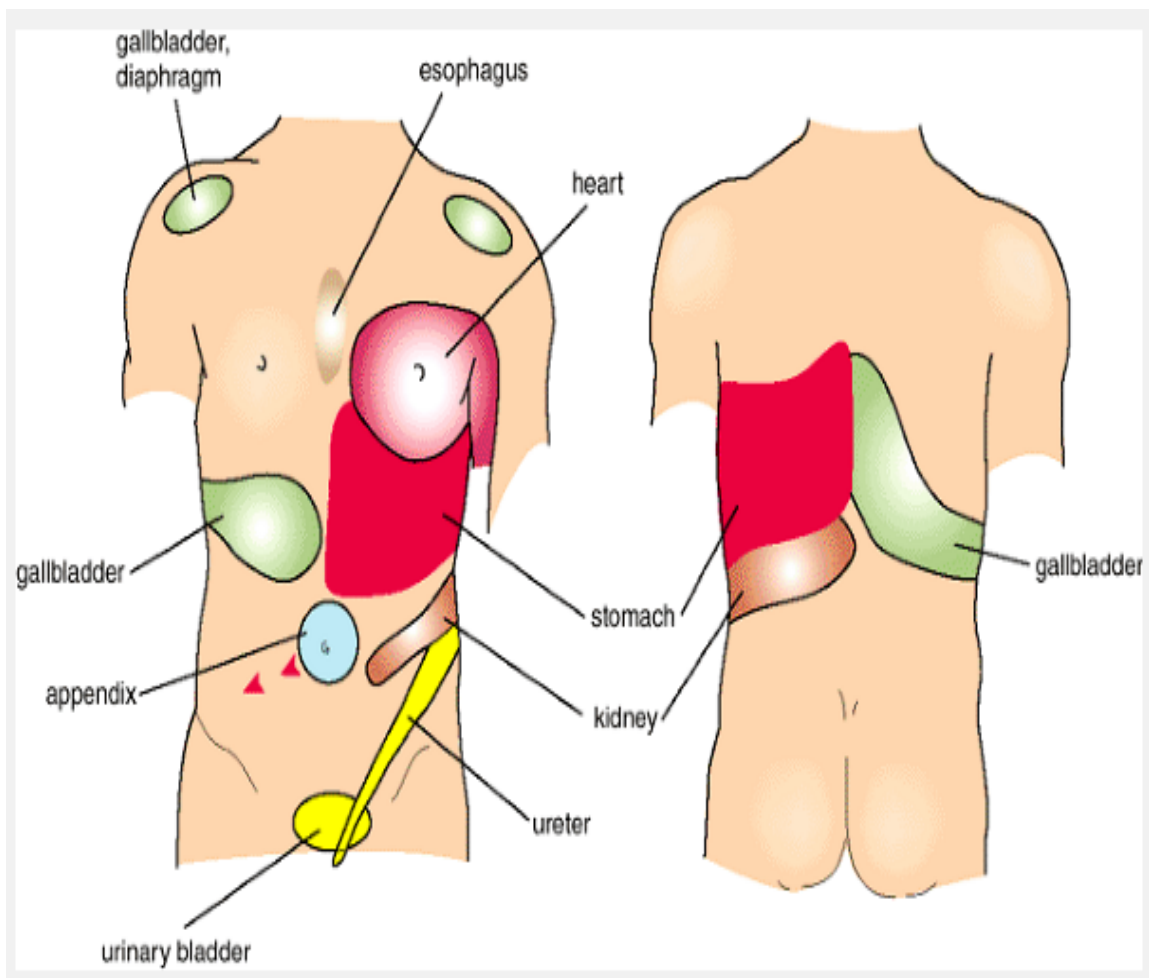
Formed by primary nociceptors in the walls of the viscera have their cell bodies in the dorsal root ganglia and their central processes synapse with cell bodies in the dorsal horn of the spinal cord.

Secondary Order Neurons:

Pass to contralateral side and ascend in contralateral spinothalamic and spinoreticulothalamic tracts, via lateral medulla, lateral pons and midbrain, and finally end in the thalamus.

Tertiary Neurons:

Project from the thalamus to the somatosensory cortex and cingulate gyrus (responsible for the emotional component of pain).



Sites of referred pain

CAUSES OF ACUTE ABDOMEN

(Excluding traumatic causes)

The cases of acute abdomen can be broadly classified into ⁸⁷

- 1) Surgical 2) Non-surgical

1) SURGICAL CAUSES	
<p>I) INFLAMMATION</p> <p style="padding-left: 40px;">Acute Appendicitis</p> <p style="padding-left: 40px;">Acute Cholecystitis</p> <p style="padding-left: 40px;">Acute Diverticulitis</p> <p style="padding-left: 40px;">Acute Pancreatitis</p> <p style="padding-left: 40px;">Salpingitis</p> <p style="padding-left: 40px;">Septic abortion</p> <p style="padding-left: 40px;">Mesentric adenitis</p> <p style="padding-left: 40px;">Primary peritonitis</p> <p style="padding-left: 40px;">Chron's disease</p> <p style="padding-left: 40px;">Meckel's diverticulitis</p> <p style="padding-left: 40px;">Pyelonephritis and cystitis</p> <p style="padding-left: 40px;">Yesinia infection</p> <p>II) PERFORATION</p> <p style="padding-left: 40px;">Gastric Ulcer</p>	<p>III) Obstruction</p> <p style="padding-left: 40px;">Renal Colic</p> <p style="padding-left: 40px;">Biliary Colic</p> <p style="padding-left: 40px;">Small Bowel</p> <ul style="list-style-type: none"> - Congenital bands/ atresia - Meconium ileus <p style="padding-left: 40px;">- Malrotation of the gut</p> <p style="padding-left: 40px;">- Adhesions from previous surgery</p> <p style="padding-left: 40px;">- Hernia</p> <p style="padding-left: 40px;">- Intussusception</p> <p style="padding-left: 40px;">- Gall Stone</p> <p style="padding-left: 40px;">- Tumour's</p> <p style="padding-left: 40px;">- Chron's</p> <p style="padding-left: 40px;">Large Bowel</p> <ul style="list-style-type: none"> - Tumour

Duodenal Ulcer	- Volvulus
Acute appendicitis with perforation	- Inflammatory Stricture
Acute cholecystitis with perforation	Iv) Infarction
Diverticular disease	Torsion Of Viscus
Carcinoma of the colon	Arterial Embolism Or Thrombosis
Chron's disease	Venous thrombosis
Ulcerative colitis	Dissecting aneurysm
Lymphoma	V) HEAMORRHAGE
Foreign body perforation	Ruptured abdominal aortic aneurysm
Boerhaeve's syndrome	Ruptured ovarian cyst
Perforation of a segment of strangulated bowel	Aneurysm of mesenteric vessels
Perforation of urinary bladder	Dissecting aneurysm of aorta
	Ruptured ectopic pregnancy
	Ovulatory bleed
	Endometriosis
	Spontaneous rupture of liver tumours
	Rectus sheath hematoma

2. NON-SURGICAL CAUSES

<p>1) Intra Abdominal</p> <p>Disease Of Liver</p> <ul style="list-style-type: none">- Liver Tumors- Hepatic Abscesses <p>Primary Peritonitis</p> <ul style="list-style-type: none">- Bacterial Peritonitis- Tuberculosis- Candida <p>Infective Conditions</p> <ul style="list-style-type: none">- Acute viral Gastroenteritis- Acute Food Poisoning- Typhoid Fever- Mesenteric Adenitis- Yersinia <p>2) Abdominal Wall Pain</p> <p>Rectus sheath hematoma</p> <p>Neurovascular enlargement</p> <p>3) Retroperitoneal Causes</p> <p>Pyelonephritis</p>	<p>5) Metabolic Disorders</p> <p>Diabetes</p> <p>Addison's disease</p> <p>Uremia</p> <p>Porphyria</p> <p>Haemochromatosis</p> <p>Hypercalcaemia</p> <p>Heavy metal poisoning</p> <p>6) Neurological Causes of Acute Abdomen</p> <p>Spinal Disorders</p> <p>Tables dorsalis</p> <p>7) Hematological Disorder</p> <p>Sickle cell anemia</p> <p>Hemolytic anemia</p> <p>Henoch-Schonlein purpura</p> <p>Leukemia</p> <p>Lymphomas</p> <p>Polycythaemia</p>
---	--

Acute hydronephrosis	Anticoagulant therapy
4) Intra Thoracic Causes	8) Immunological Disorders
Myocardial Infarction	Polyarteritis Nodosa
Pericarditis	Systemic lupus erythematosus
Spontaneous pneumothorax	9) Infections
Pleurisy	Infectious mononucleosis
Coxsackie B Virus	Herpes Zoster
Strangulation of diaphragmatic hernia	
Dissection of the aorta	

DIAGNOSIS OF ACUTE ABDOMEN

The diagnosis of acute abdomen includes (a) history taking (b) general and local examination (c) investigations.

History¹⁰³.

A proper history of the patient with acute abdominal pain must include appropriate family history, social history, drugs taken (licit and illicit) and past medical history in addition to history of the present condition.

The key elements of present history are :-

1) **Age²⁸** : Certain conditions are limited to or common in specific age groups.

Meconium ileus, meconium peritonitis etc. are common in new borns.

Kachroo et al (1984)⁵⁹ reported that duodenal perforation was common in age groups of 20 to 48 years. Rao DCM et al (1984)⁹² showed maximum incidence of ulcer perforation occurred between 21 to 40 years of age.

Fenyo G and Nacka (1982)³⁸ have reported an increase in incidence of malignancies as a cause of acute abdomen in elderly patients. Intussusception is common in children of age 2 years or less⁷².

Brayton D. and Norris W.G. (1954)¹⁶ showed that adult intussusception was commonly enteric (39%) as compared to ileocecal (94%) which was commonest in children.

Staniland J.R. et al (1972)¹⁰⁷ in their study of 600 patients with acute abdominal pain reported that 15% of perforated peptic ulcers were females.

- 2) **Sex** : Some conditions show a higher incidence in males while others in females. Rao DCM et al (1984)⁹² reported a high incidence of ulcer perforation in males (93%). Ileal perforations were less in females (5.5%) in their study.
- 3) **Pain**: Abdominal pain is the most frequent primary presenting complaint.

The points regarding pain to be elicited are:

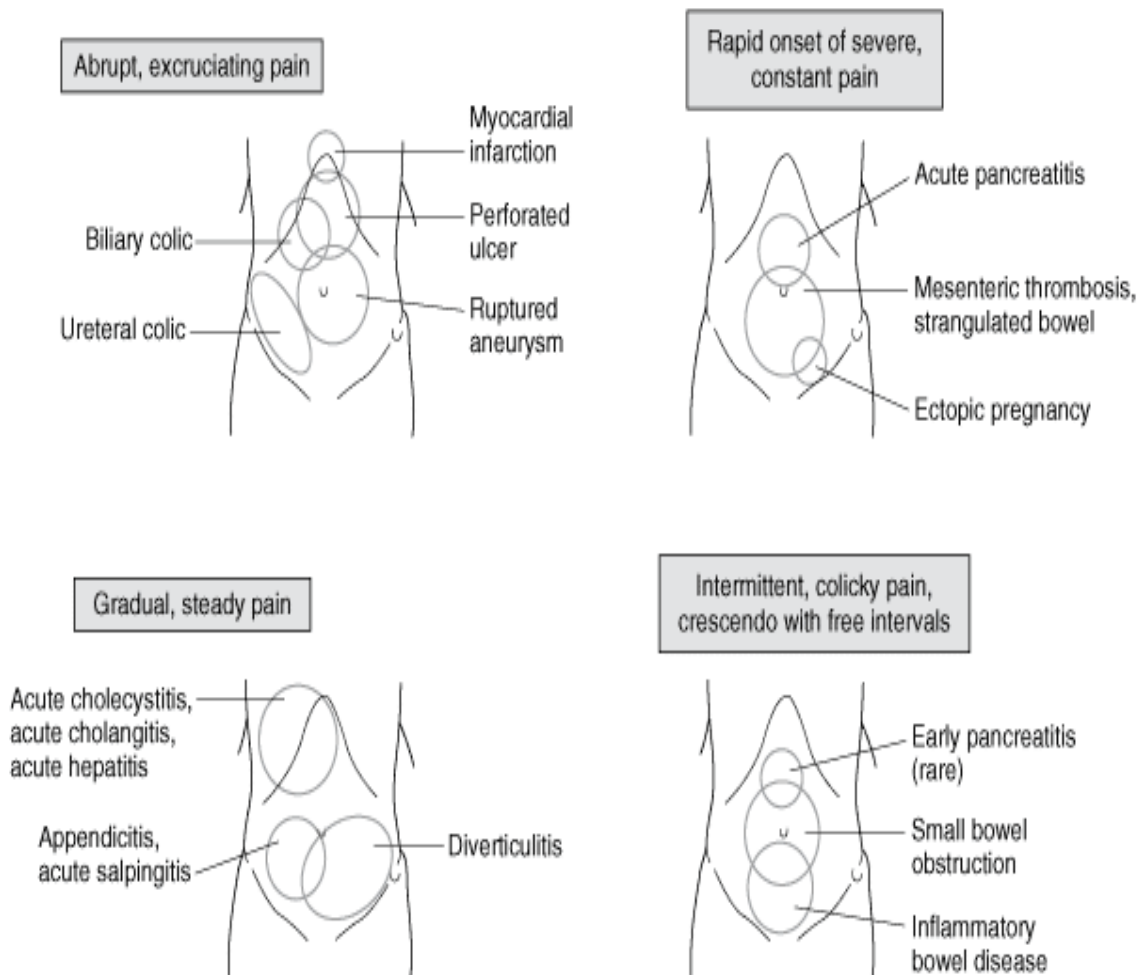
- a) **Location of pain**^{22, 103}: Visceral pain is usually distributed over the midline corresponding to foregut and hind-gut positions. It is not until visceral process becomes transmural and inflames the adjacent parietal peritoneum that pain localizes to area of the origin. The patient may often point a finger to the precise spot-pointing test. Pain can also be localized to any of the abdominal quadrants.
- b) **Onset and progression of pain**^{13, 72}: Mode of onset reflects the nature and severity of the inciting process. Onset may be explosive (within seconds), rapidly, progressed (with 1 to 2 hrs) or gradual over several hours. Pain that occurs suddenly or wakens a patient from sleep is frequently associated with GI perforations or strangulations.

Slow insidious onsets of pain suggest either inflammation of visceral peritoneum without inflammation of parietal peritoneum or a continued process such as an evolving abscess.

Many cases of intestinal obstruction are gradual in onset, culminating in an acute crisis. Strangulation of the gut however is accompanied by very acute symptoms from the beginning.

The pain is getting better is likely to resolve and reflects the body's defensive effort to cordon off an acute process. On the other hand, pain that is getting worse with accompanying systemic signs like tachycardia, tachypnoea, shock underscore the need for prompt resuscitation and surgical intervention.

In mesenteric artery embolism, pain is classically described as being out of proportion to physical examination.



Location and character of pain

- c) **Character of pain**^{13, 103}: This often helps to indicate the nature of seriousness of the condition.

This burning pain of perforated gastric ulcer, the agony of an acute pancreatitis, the 'sharp constricting pain' or 'breath taking' pain of biliary colic, the 'shearing' or 'tearing' pain of a dissecting aneurysms and the 'gripping pain' in many cases of intestinal obstruction in contrast with dull aching pain in many cases of appendicitis with abscess or dull constant, fixed pain of a pyonephrosis remain apt descriptions.

Colicky pain (coming and going every few minutes) is associated with complete or partial obstruction of a peristaltic organ. Agonizing pain denotes serious or advanced disease.

- d) **Shifting/Radiation/Localization of pain**^{13, 56, 103}: This is often significant and parallels course of the underlying conditions. The site of pain at onset should be distinguished from site at presentation.

In acute appendicitis initial visceral pain is usually felt centrally and then shifts to right lower quadrant when overlying the parietal peritoneum becomes inflamed.

John H et al (1993)⁵⁴: In their study reported that pain migration was a reliable symptom in acute appendicitis. In perforated peptic ulcer, pain almost begins in the epigastrium, but as leaked gastric contents track down the right paracolic gutter, pain may shift to right lower quadrant.

Retroperitoneal pain such as in acute pancreatitis will radiate to the back. Irritation of diaphragm will radiate to the shoulder. Ureteric colic will radiate from renal angle into the groin.

- e) **Aggravating and relieving factors**^{13, 22, 103}: In cases of peritonitis the patient prefers to lie still, while in colics the patient ‘pranks’ about or ‘climbs the wall with pain’.

Colicky pain is usually promptly relieved by analgesics. Ischemic pain due to strangulated bowel or mesentric infarction is only slightly assuaged even by narcotics. Pain of acute pancreatitis may be relieved temporarily by leaning forwards.

An occasional patient will deny, pain but may complain of a vague feeling of abdominal fullness that feels as though it might be relieved by a bowel movement. This visceral sign is called ‘gas stoppage sign’ eg. in retrocaecal appendicitis.

- 4) **Nausea and Vomiting**^{13, 100, 103, 114}: Nausea has no specific diagnostic value, but may indicate some derangement of gastro-intestinal function. Both nausea and vomiting are associated with a myriad of causes. The relationship of vomiting to pain, character and quantity of vomitus and frequency of vomiting all give a clue to the cause and possible level and site of the lesion.

Pain in acute surgical abdomen precedes vomiting while in medical conditions the reverse is true.

Recurrent vomiting, first of gastric contents, then bilious, then greenish yellow, and finally orange or brown feculent smelling fluid occurs sequentially at different levels of intestinal obstruction.

In some patients vomiting is surprisingly absent even with signs of peritonitis or intestinal obstruction. In such conditions a nasogastric aspiration may convert a doubtful clinical picture to certainly.

Ogata M and James R (1990)⁸⁴ Studied 50 patient with bowel obstruction, 48 of them had abdominal pain and 40 patients suffered from nausea and vomiting.

- 5) **Bowel Functions**^{13, 88, 95, 103}: Obstipation (absence of passage of both stool and flatus) strongly suggests mechanical bowel obstruction. Relative constipation is found in partial intestinal obstruction. Copious watery diarrhoea is characteristic of gastroenteritis. Blood stained diarrhoea may be found in necrotizing enteritis, ulcerative colitis, bacillary or amoebic dysentery. Haemoccult positive stools may be found in ischemic bowel syndromes. A typical 'Red current jelly' stool is seen in intussusception. Tenesmus and decreased calibre of stools should be also being sought for in suspected lesions of the large bowel.

Blake R.Lynn (1976)¹² in their study reported that heamatemesi and melena were commonly associated with gastric and duodenal ulcers.

6. **Micturition** : Increased frequency, dysuria, haematuria or cloudy urine may helpful when urinary tract infection or ureteric colic is suspected.
7. **Gynaecological Symptoms**¹³: A missed period may indicate pregnancy, ectopic or otherwise and vaginal discharge may indicate pelvic inflammatory disease.

Mid-cycle pain is suggestive of Mittel Schmerz. History of amenorrhea and shock is suggestive of ruptured ectopic gestation.

Other History:

History of previous surgery is important. Cox et al (1993)²⁶, in a retrospective analysis of 144 cases of small bowel obstruction from adhesions, reported that 80% had prior operations in the pelvis.

History of similar episodes of pain is also important. Hendry et al (1984) 48 reported higher incidences of peptic ulcer perforations in people who previously proved ulcer disease or previous history of dyspepsia. Previous drug history is of great significance.

Collier and Paine (1985)²⁴ showed perforated ulcers were common in patients who had consumed NSAIDS for long periods.

Ramesh C.Bharti et al (1996)⁹¹ reported a higher incidence of peptic ulcer perforation in smokers.

Physical Examination:

A methodical approach involving general physical examination and local abdominal examination is mandatory. Certain special signs described may help localize an acute abdominal lesion.

Some of the important aspects of examination are:

1. **General visual appearance** ^{13'35'95'103}: This often affords a fairly reliable indication of the severity of the clinical situation. Important aspects are:

- a. Facial Expression : The 'pale' or 'livid face' and 'sweating brow' may be seen in patients with perforated ulcer, acute strangulation, acute pancreatitis.
 - b. Attitude in bed: Patients with severe colics are often restless. While those with peritonitis remain motionless in bed. Flexion of right hip is adopted in case of inflamed retrocaecal appendix.
 - c. Signs of dehydration: Sunken eyes and hollow cheeks, dry tongue, may suggest dehydration (due to repeated vomiting from intestinal obstruction) or acute volume loss. In late stages, the above with anxious expression form a characteristic feature - 'Hippocratic facies'.
 - d. Breathing Pattern: Flaring of ala nasi, may suggest decreased movement of the diaphragm due to thoracic or upper abdominal pathology. In peritonitis, breathing may be shallow and more rapid.
2. **Systemic Signs**^{13'103}: Usually accompany rapidly progressive or advanced disorders. Extreme pallor, tachycardia, tachypnoea, sweating and hypotension suggest major intra-abdominal haemorrhage or gangrene of bowel. In intestinal obstruction, shock is due to fluid and electrolyte loss. In late cases septic shock may supervene because of bacterial peritonitis.
 3. **Temperature**^{13'28'103}: Low grade fever is common in inflammatory conditions such as acute cholecystitis, appendicitis and diverticulitis. High fever with lower abdominal tenderness in a young woman without signs of systemic illness suggests acute salpingitis.

In acute appendicitis, temperature is usually normal initially, later it may steadily rise to 100° F or 101°F.

Perforation is usually associated with slightly higher levels. In intestinal obstruction, the temperature is as a rule normal or sub-normal. Disorientation or extreme lethargy combined with a very high fever ($>102.2^{\circ}\text{F}$) often with chills and rigors signifies impending septic shock.

Abdominal Examination:

The basic steps in examination of the abdomen are outlined in the table. Brief descriptions of each are as follows:

1. **Inspection** ^{7/13'28}:- Abdomen is inspected for presence of distension, visible peristalsis, protrusions, hernias, incisions, pulsations, discoloration and position of the umbilicus. A tensely distended abdomen with an old surgical scar suggests both presence and the cause (adhesions) of small bowel obstruction. Local or asymmetrical distension may indicate pathology in a particular viscus.
2. **Palpation** ^{7, 33, 95}:-

Gentle palpation may reveal muscular rigidity or guarding in a setting of an inflamed parietal peritoneum.

Abdominal rigidity (reflex tonic contraction of the muscles of the abdominal wall) is a sign of utmost importance, since in most cases it indicates an intra-abdominal 'mischief' requiring immediate operation.

Intense, diffuse 'board-like' rigidity is found in severe peritonitis e.g., due to perforated viscus, chemical peritonitis. Localized tenderness or rigidity may reflect focal peritonitis over an inflamed organ or where the mischief is cornered 'off by adhesions. Guarding denotes voluntary muscle spasm, a protective reflex

by the patient. Mild diffuse tenderness is usually associated with conditions like gastroenteritis.

3. **Percussion**^{7,22,28} :- Tympany indicates excess intraluminal gas in intestinal obstruction or extraluminal gas in perforated hollow viscus.

Dullness to percussion is indicative of mass or ascites. Shifting dullness is present in ascites. In severe peritonitis, gentle percussion may elicit severe pain, it may provide more accurate information and localization than presence of rebound tenderness and is better tolerated by the patient¹⁰³. Obliteration of normal liver dullness in the midaxillary line suggests free intraperitoneal gas due to hollow viscus perforation^{28,103}.

4. **Auscultation**^{7, 8}: A normal sound consists of 'clicks' and 'gurgles' occurring at an estimated frequency of 5-34 / min. The loudness, pitch and frequency provide important information. 'Tingling' or 'metallic' sounds are suggestive of intestinal obstruction, 'decreased' or absent sound - 'silent abdomen' is a feature of paralytic ileus.

Abdominal bruits may indicate a vascular cause of acute abdominal pain.

Hyperactive bowel sounds or Borborygmi or the familiar 'stomach gurgling' heard without the stethoscope may be found in gastroenteritis.

Peritoneal Friction rub²¹ :- May be heard in early stages of peritonitis before the exudate has separated the inflamed surfaces. It is caused due to movement during breathing.

Rectal and pelvic examination^{28,72}:

Rectal examination is of utmost importance in all cases of acute abdomen. If a rectal exam is deferred, it means that 'the examiner has no fingers or the patient has no anus'.

Diffuse tenderness is non-specific, but one-sided (lateral) rectal tenderness is indicative of pelvic irritation such as that due to pelvic appendicitis or abscess. Presences of bulging (abscess), growth, blood, fecal impaction are also looked for. A properly performed pelvic examination is invaluable in differentiating acute pelvic inflammatory disease and acute appendicitis, twisted ovarian cyst or tubo-ovarian abscess.

The remainder of examination^{7,13,87}:-

Examination of hernial orifices, to rule out obstructed hernia. Cardiovascular system examination may help identify myocardial infarction as cause of acute abdomen. Examination of chest is important, as acute pneumococcal pneumonia may mimic acute abdomen. The male testis is examined looking for evidence of torsion or inflammation. A swollen testis with a varicocele may suggest a retroperitoneal process.

Neurologic exam should concentrate on assessing for signs of nerve root impingement.

Pneumonic for features of peritonitis¹⁰¹:-

- P - Pain - front, back, sides, shoulders
- E - Electrolyte fall, shock ensues
- R - Rigidity or rebound of anterior abdominal wall
- I - Immobile abdomen and patient
- T - Tenderness
- O - Obstruction
- N - Nausea and vomiting
- I - Increasing pulse and decreasing B.P.
- T - Temperature falls and then rises
- I - Increasing abdominal girth
- S - Silent abdomen (no bowel sounds)

A brief review of common clinical features, signs and symptoms was mentioned in the previous pages. All patients may not present with such 'typical' features, which can be correctly 'pattern-matched'. In an interesting study of 'clinical presentation of acute abdomen in 600 patients'. Stanilard J.P. et al (1972)¹⁰⁷ concluded that roughly only two thirds of the patients presented with 'typical features'. He made the following observations regarding history and physical findings:

STEPS IN PHYSICAL EXAMINATION FOR ACUTE

ABDOMEN¹³

- | | |
|------------------------------------|------------------------------------|
| 1. Inspection | 2. Palpation: |
| 3. Percussion | 4. Auscultation |
| 5. Cough tenderness | 6. Guarding/ Rigidity |
| 7. Punch Tenderness | One finger |
| Costal area | Rebound tenderness |
| Costovertebral area | Deep |
| 8. Special Signs | 9. External hernias and genitalia. |
| 10. Rectal and pelvic examination. | |

Signs	Description	Associated Conditions
1. Cullen	Ecchymosis around umbilicus	Haemoperitoneum, pancreatitis, ectopic pregnancy
2. Grey Turner	Ecchymosis of flanks	Haemoperitoneum, pancreatitis
3. Kehr	Abdominal pain radiating to left shoulder	Spleen rupture, renal calculi, ectopic pregnancy
4. Murphy	Abrupt cessation of inspiration on palpation of gall bladder	Cholecystitis
5. Dance	Absence of bowel sounds or emptiness on palpation in right lower quadrant	Intussusception
6. Romberg Howship	Pain down the medial aspect of thigh to the knees	Strangulated obturator hernia
7. Blumberg	Rebound tenderness	Peritoneal irritation, appendicitis
8. Markle (heel jar)	Patient stands with straightened knees, then rises up on toes relaxes and allows heel to hit floor, thus jarring the body.	Peritoneal irritation, appendicitis
9. Rovsing	Right lower quadrant pain intensified by left lower quadrant abdominal pressure	Peritoneal irritation, appendicitis
10. Ballance	Fixed dullness on percussion in left flank and dullness in right flank that disappears on change of position	Peritoneal irritation
11. Aaron	Pain or distress occurs in area of patient's heart or stomach on palpation of McBurney's point	Appendicitis
12. McBurney	Rebound tenderness and sharp pain when McBurney's point is palpated	Appendicitis
13. Copes Psoas test	Pain on hyperextension of the hip due to inflamed viscus irritating the psoas muscle	Retrocecal appendicitis psoas abscess, perforated Chron's enteritis
14. Obturator test	Pain caused by flexing the hip joint and externally or internally rotating the thigh	Pelvic appendicitis, strangulated obturator hernia

LABORATORY INVESTIGATIONS:

A. Blood Studies: Hemoglobin, hematocrit and white blood cells count taken on admission are highly informative.

Brewer R J et al (1976)¹⁷ in their study of 1000 cases of acute abdomen reported that leukocyte counts were greater than 10,000 per mm³ in 40% of the patients. John H et al (1993)⁵⁴ showed that appendicitis was associated with raised leukocyte counts. A low white blood cell count is a feature of viral infections such as mesenteric adenitis or gastroenteritis. Serum electrolytes, urea and creatinine are important especially if hypovolemia is expected.

A raised serum amylase level corroborates a clinical diagnosis of acute pancreatitis. Moderately elevated levels frequently accompany strangulated or ischemic bowel, perforated duodenal ulcer or twisted ovarian cyst^{13,100}.

Liver function tests are useful to differentiate medical from surgical hepatic disorders and gauge severity of underlying parenchymal disease. Clotting studies (platelet counts, prothrombin time, and partial thromboplastin time) and a peripheral blood smear may be necessary if the history hints a possible hematologic abnormality.

B- Urine Tests¹³: Microscopic hematuria or pyuria can confirm ureteric colic or urinary tract infection. Dark urine or a raised specific gravity reflects mild dehydration in patients with normal renal function. Dip stick testing (albumen, bilirubin, glucose and ketones) may reveal a medical cause of acute abdomen.

C- Stool Tests: A positive test for hemoccult blood may suggest a mucosal lesion and is also an useful indicator in cases of ischemic bowel syndromes⁸⁸. Stool samples for cultures are useful in gastroenteritis, dysentery or cholera.

DIAGNOSTIC RADIOLOGY

Plain Film radiography:

Imagining of the abdomen has traditionally begun with the plain film radiography⁵⁶⁵. Interpretation by plain abdominal X-ray is mainly based on demonstration of various patterns of gas; fluid; abnormal shadows etc., caused by differential absorption of x-rays by soft tissues, bone, gas, fat and fluid⁹⁵. Similar patterns may be seen in various benign conditions, however in the appropriate clinical setting, it can support the diagnosis⁷².

Radiographic Technique:

Various "acute abdominal series" have been recommended⁷⁹. The two most important films for detecting free air are upright abdomen and decubitus⁷⁰. In these projections air is interposed between the parietal peritoneum and visceral surface of the liver on the right side. Miller and Nelson (1971)⁷⁷ had shown that prior positioning of the patient in left lateral decubitus position, could detect amounts of gas as tiny as 1cc, under the right hemi-diaphragm on an erect abdominal radiograph. However Mirvis et al (1986)⁷⁹ in their study of 252 cases of acute abdomen, suggested that upright abdominal series could be eliminated.

In patients who are too ill or cannot stand, the left lateral decubitus can be asked for, the X-ray beam being in a horizontal cross table position. Quantities of air as small as 5-10 cc can be detected by this method⁹⁵. For patients whom even the lateral position is difficult, the supine film is the only alternative⁴⁰. However supine radiographs require large quantities of air for detection^{46, 77, 78}. Various signs of pneumoperitoneum on supine radiograph are shown in the table.

The patient should always remain in a given position for atleast 10 minutes, before radiograph is taken to allow air to rise to the highest point in the peritoneal cavity⁷⁷.

Bharghava S (1988)¹⁰, has emphasized that an upright chest x-ray should be routinely asked for, to rule out chest-conditions which can mimic an acute abdomen, as well as demonstrate free air under the diaphragm.

Normal Appearances^{40, 78, 95, 100}.

Relatively large amounts of gas are normally present in the stomach and colon, but only a small amount is usually seen in the small intestine. Most of the gas within the bowel has been swallowed (along with food), it normally reaches the colon within 30 minutes. Gas is also produced by fermentation of gut contents by normal bacterial flora (bacteroides and E-coli). At any given time, there is about 200 ml of gas in the intestinal tract. Like air, fluid (swallowed or from gut secretions) is also a normal content, and short fluid levels are not abnormal. Some of the normal appearances on x-rays are as follows (when distended with gas).

1. **Stomach:** gastric rugae can be seen on supine radiograph, and a long fluid level when erect. This is because the antrum and the body are normally contracted.
2. **Small Bowel :** There is rarely sufficient gas present in the small bowel to outline more than a short segment.
 - a) Jejunum: - is characterized by its valvulae conniventes, which completely pass across the width of the bowel and are regularly spaced.
 - b) Ileum :- distal ileum has been described as featureless.

c) Caecum :- a distended caecum, with a competent ileocecal valve may appear as a rounded gas shadow in the right iliac fossa.

d) Large bowel :- except for caecum, shows haustral folds and unlike valvulae conniventes are spaced irregularly and indentations are not placed opposite to one another.

Identification of kidneys, psoas muscle, bladder, posterior borders of the liver and spleen, is due to the fat around them. Gall bladder is not surrounded by fat and is therefore not normally visualized on plain x-ray.

X-ray findings in general pathologic conditions :-

Lee PWR, (1976)⁶⁵ in his study of five acute abdominal conditions namely (a) acute appendicitis (b) acute cholecystitis (c) acute pancreatitis (d) perforated duodenal ulcer (e) intestinal obstruction concluded specific radiographic features are present in 48% of the cases.

Some of the findings indicating pathologic process as follows:

1. PNEUMOPERITONEUM:

Free intraperitoneal air commonly develops in association with perforated hollow viscus. Intra-abdominal hollow viscera which commonly perforate lie in anatomic positions which favour rise of gas to the right flank/ hemi diaphragm. (Eg. stomach, duodenum, caecum, gallbladder)⁷⁷. Pneumoperitoneum can be visualized in 75% of the patients with a perforated peptic ulcer (commonest cause)⁹⁶. Keeffe Ej and Gagliard RA (1973)⁶⁰, reported that visceral perforation cause pneumoperitoneum in 80% of the patients and perforated peptic ulcer will result in pneumoperitoneum in 90% of the patients. Joseph et al (1983)⁵⁸ reported that pneumoperitoneum occurred in 14% of patients without a perforated viscus. Miller

and Nelson S.W. (1971)⁷⁷ reported 1 cc of air could be detected using appropriate techniques.

Stomach and colonic perforations produce large quantities of air. Pneumoperitoneum in appendicular perforations is rare^{40,78}. Perforations can also occur following bowel ischemia and necrosis, typhoid, colonic diverticulitis. In situations where clinical suspicion of perforation is high, but no free air demonstrated, air or 50 ml of oral water soluble contrast media can be injected via a naso-gastric tube and x-ray repeated, in L-left and R-right lateral views respectively⁴⁰. Conditions like Chilitis syndrome, pulmonary atelectasis, subdiaphragmatic fat may mimic pneumoperitoneum “pseudopneum peritoneum”^{40,78}. Sakai L et al (1981)⁹⁷, reported free air was detectable in 50 % of patients with colonic perforations. However about 30% of patients with perforated ulcers do not exhibit pneumoperitoneum on abdominal radiographs⁵⁰⁻⁹⁴.

2. DILATED LOOPS AND AIR-FLUID LEVELS :

Complete obstruction causes accumulation of air-fluid in the proximal segment with a reduction in calibre and a relatively empty distal segment. Plain film changes usually appear after 3-5 hours in complete obstruction. Emptying of small bowel and colon distal to an obstruction occurs in 12-24 hours. X-ray findings are therefore usually marked after 12 hours^{40, 78}.

Gammil SL and Nice CM (1972)⁴⁴ have reported that fluid levels are common in normal individuals. 3-5 fluid levels less than 2.5 cm may be seen . More than two fluid levels in dilated small bowel (>2.5 cms) is abnormal.

In adults two fluid levels may be regarded as normal-one near the duodenal cap and other near terminal ileum⁹⁵.

Diameter of a distended viscus is usually not diagnostic, but can give a clue to the underlying condition, clinically correlated⁹⁵. 9 cm is critical for the caecum, beyond which perforation can occur and 5.5 cm is the upper limit for diagnosing colitis of transverse colon, above which toxic megacolon should be suspected⁴⁰. The number of fluid levels is directly proportional to site of and degree of obstruction, i.e. increasing distally. Air fluid levels differing height in the same bowel loop are not reliable sign of mechanical obstruction^{40'78'95}.

In paralytic ileus or adynamic obstruction all fluid levels will be present throughout the gastro-intestinal tract. Some of the important signs/patterns described are;

- a. **Sentinel loops** : Non specific, short segment dilated loops suggesting an underlying inflamed viscera⁷⁸. Lee PWR (1976)⁶⁵ reported that the sentinel loop sign as most reliable diagnostic sign in acute pancreatitis in his study of x-ray of 277 patients.
- b. **String of beads appearance** : Originally described by Frimann Dahl in 1960, is caused by bubbles of air trapped under distended valve conniventes^{65'78}.
- c. **Coffee-bean sign of Mellins and Rigler** :- were described by these authors as specific for closed loop obstructions also referred to as pseudo-Tumor sign • (Frimann Dahl). Usual causes of closed loop obstruction are adhesions, volvular or incarcerated internal hernia^{65'78}.
- d. **Liver overlap sign** :- left flank overlap sign, a fluid ratio (>) more than 2:1 and pelvic overlap signs have been suggested in case of sigmoid volvulus⁷⁸.
- e. Finding a gas filled intestinal loop below the inguinal ligament with abdominal air fluid levels is suggestive of obstructed hernia²³.

3. INTRAPERITONEAL FLUID^{31'32} (blood, abscess) :-

Collects in its most dependent parts, usually the pelvis and Morrison's pouch. The mechanics of spread is based upon the anatomy of peritoneal spaces and reflections. As aptly described by Meyer "If the right paracolic space is a gutter, then Morrison's pouch is a sewer". The radiographic findings in intraperitoneal infections are a) extramural mass containing gas and on fluid b) fistulous tract c) loss of normal soft tissue fat interfaces d) generalized or focal elevation of the diaphragm e) pleural effusion f) edema of adjacent bowel g) focal ileus h) curvature of spine toward abnormal area. Large amounts of fluid cause a generalized haze over the abdomen, with scattering of radiation-ground glass appearance.

4. OBLITERATION OF PSOAS MARGIN^{13, 40, 78} :

Obliteration of the Psoas margin usually indicates retroperitoneal disease. Contraction of right flank, obliteration of psoas margin, curving of spine with concavity to the right (psoas spasm) are findings in perforated duodenal ulcer, acute appendicitis (Right) ureteric calculus. Similar findings on the other side is due to left ureteric calculus or ruptured spleen. A leaking abdominal aortic aneurysm may be detected as a central, soft tissue mass obscuring the psoas or renal shadows. However the (Right) psoas margin is blurred in 19% of normal individuals.

5. ABNORMAL SHADOWS AND ABNORMALITY OF NORMAL SHADOW^{13,40,78,114:}

- a) Calcified deposit may be of significance. It may be of diagnosis according to location and collaboration with clinical symptoms, only 15-20% of gallstones are radio-opaque, while about 90% of ureteric calculi are radio-opaque. In case of aortic aneurysm a curvilinear calcification may be seen on AP and

lateral radiographs. Phlebolith or fecoliths are normal calcifications which may give rise to some confusion.

- b) Presence of gas within the walls of a hollow viscus is found in cystic pneumatosis; pneumatosis coli etc. which are often cyst air spaces.

Linear gas shadows in the bowel wall is usually a sign of necrosis and in some cases of perforated ulcer. In cases of ischemic colitis, necrotizing enteritis hemorrhage and edema of the mucosa of the colon, will give rise to creosotic translucencies known as "thumb printing".

Campbell JPM and Gunn AA19 (1988) in their 4 year study of 5080 patients with acute abdominal pain concluded that plain x-rays have a high 'false-positive' rate and if initial diagnosis is suspected appendicitis, UTI or non-specific abdominal pain, there is little value in routine use of abdominal radiographs.

Distinction between small bowel and large bowel dilatation⁴⁰:

Characteristics	Small Bowel	Large Bowel
1. Haustra	Absent	Present
2. Valvulae Conniventes	Present	Absent
3. Number of loops	Many	Few
4. Distribution of loops	Central	Peripheral
5. Radius of curvature of loop	Small	Large
6. Diameter of loop	30-50 mm	50mm +
7. Solid feces	Absent	May be present

Signs of pneumoperitoneum on supine radiograph ^{66,78}:

Sign	Characteristic features
1. Rigler's sign	Double wall sign, Intra luminal and extra luminal air outline the mucosal and serosal surfaces, respectively. (S-32%)
2. Right upper quadrant signs	
a) Perihepatic sign	Free air around the liver may collect between liver and anterior edge of (R) lobe, as a tapered oblique collection – subhepatic (S-41%).
b) Morrison's Pouch sign	Air fills the posterior subhepatic space to outline the superior margin of the right kidney.
c) Falciform Ligament sign	Falciform ligament is outlined by air and appears as an oblique linear density, from inferior border of liver to (R) side of the spine. (S-2%).
3. Inverted V or umbilical sign	Lateral umbilical ligaments are outlined in the lower abdomen (S-0%).
4. Urachus sign	Outlined by air between umbilicus and bladder.
5. The triangle sign	Air is trapped between 3 adjoining loops of bowel or two loops of bowel and parietal peritoneum.
6. Football or air dome sign	Large air collections, forms an ellipsoid lucency against a background of free intraperitoneal fluid. S-2%.
7. Cupola sign	Air beneath central tendon of the diaphragm.
8. Scrotal Air	In neonates, air may percolate into open saccus vaginalis.

1 and 2a are the commonest. Others are rare and usually require large air collections. Levine et al (1997)⁶⁶ in their study of supine radiographs in pneumoperitoneum have shown an overall sensitivity of 59% for these signs.

S = Sensitivity

ULTRASONOGRAPHY

The indication for the use of ultrasonography in the evaluation of the acute abdomen has increased dramatically in the past decade^{25,96}. Sonography is a valuable imaging tool in patients who may have specific G.I.T. disease such as acute appendicitis or acute diverticulitis; however its contribution to the assessment of patients with possible gastro intestinal tract disease is less certain⁵⁴. However, a 'normal' appendix is visualized in 10-15% of the patients¹¹⁴.

Abu-Yousef et al (1987)¹ too reported that the normal appendix could be visualized sonographically.

Jeffrey et al (1988)⁵³, in their study of 250 cases, using high resolution ultrasonography with graded compression, revised the criteria. A wall thickness of 6 mm or more was considered diagnostic, in addition to other features like a blind, fluid filled, aperistaltic, non-compressible tubular structure off the inferior aspect of the caecum. They reported an overall accuracy of 93% confirmed surgically.

An inflamed appendix on cross-sectional scan shows fixed concentric circle "target appearance" formed by hypoechoic lumen surrounded by hyperechoic inflamed bowel wall⁸⁵.

John H, et al (1993)⁵⁴ reported that ultrasonography was most valuable in diagnosing periappendicular abscess. Nevertheless, they also reported sonographic results inferior to those of clinical assessment.

Appendicoliths casts posterior shadows⁸⁵.

Lee et al (1990)⁶⁴ showed that pneumoperitoneum could be successfully identified by ultrasonography and is an important sign of perforated viscus. Also the cause was identified in 4 out of 5 patients studied. Air appeared as ringdown or

'reverberation artifacts'. Findings were best observed in left lateral decubitus positions.

Meiser G. (1993)⁷³ reported that a combination of sonography and plain x-ray films gave a diagnostic accuracy of 91% for detecting free air.

Ogata M et al (1996)⁸⁴ reported that sonography as sensitive as but more specific than plain x-rays in diagnosing bowel obstruction. They were able to detect small bowel obstruction, early strangulation, ileus and also incarcerated inguinal hernia, carcinoma, peritoneal carcinomatosis which were not demonstrated clinically or by plain x-ray.

Addison N.V. and Finnan P.J. (1988)² reported that the most valuable investigation in diagnosis of acute cholecystitis was ultrasound carried out in the first 48 hours, with positive results in 83% of those examined. The gall bladder is easily visualized owing to its superficial position, unobscured by bowel gas and inferior to the liver which serves as an excellent 'acoustic window'.

Gall stones appear as bright intraluminal echogenic structures, with acoustic shadowing and change with the position of patient⁸⁵.

Ultrasonography is excellent in the diagnosis of intraperitoneal collections (fluid, blood, ascites)^{10,52}. Fluid accumulates in the most dependent positions of the peritoneal cavity (Eg. Morrison's pouch, pouch of Douglas)^{74,75}.

Simeone et al (1985)¹⁰⁴ has shown that free fluid characteristically shifts with change in patients position. Fecal contamination may appear as 'Floppy blotched' particles in the fluid. However sonographic appearance of both sterile and infected fluid collections are not specific and can overlap^{33,73}.

Hematomas usually appear as a cystic or complex mass and may give a characteristic honeycomb appearance, which doesn't shift with position^{99,104}.

Lim JH et al (1994)⁶⁷ reviewed sonograms of 81 patients with inflammatory bowel disease and showed that evidence of mural thickening with paucity of luminal contents were important findings.

Middleton et al (1988)⁷⁶ demonstrated that sonography has a high sensitivity for renal stone detection which was slightly inferior to a combination plain radiography with tomography.

Detection of ureteric calculi can be difficult because of overlying bowel gas and retroperitoneal location of the ureter.

Aortic and visceral artery aneurysms, thrombi within veins, artero-venous fistulas are amenable to evaluation with modern ultrasound equipment. But because of the frequently occurring adynamic ileus in cases of acute abdomen large areas of the abdomen will be inaccessible for ultrasound evaluation due to interposed gas, which poorly transmits sound waves⁹⁶.

COMPUTED TOMOGRAPHY

CT scanning is usually performed after simpler investigations such as plain film or ultrasonography, where clinical diagnosis is still under query⁹⁵.

In abdomen, it has been established that helical CT demonstrates superior vascular opacification reduces respiratory artifacts and decreases contrast volume requirement³⁶.

Malone AJ et al (1993)⁷¹ in his study of 211 case of acute appendicitis, reported an accuracy of 93% using unenhanced CT. An inflamed appendix was diagnosed on observing

signs such as periappendicular fat streaking, a calcified appendicolith within a thickened appendix, fat obliteration anterior to the psoas muscle and a thickened appendix (> 6mm).

Rao P.M. et al (1977)⁹³ have reported the 'arrow head sign' as a common appearance in CT, in case of appendicitis, (using oral contrast media).

CT has also been shown to be sensitive in identifying bowel obstruction. Maglante DDT et al (1993)⁷⁰ in their study of small bowel obstruction, were able to identify correctly 81% of high grade and 48% of low grade small bowel obstruction. A loop of small bowel wider than 2.5 cm was considered to be distended and a transitional change in calibre was also considered to be of diagnostic importance.

Wills JS (1992)¹¹² has shown that CT findings can be used to diagnose closed loop obstruction prior to vascular compromise.

Fukoya T et al (1992)⁴² have reported the efficacy of CT in detecting presence of high grade of SBO and also determining the cause of obstruction.

CT is also particularly helpful in studying pancreatic and retroperitoneal lesions. Findings in pancreatitis are categorized into pancreatic and peripancreatic lesions⁹⁶. However in early stages, it may provide no useful information¹⁰³.

CT with intravenous contrast media can demonstrate mesenteric venous thrombosis and non enhancement of arteries in acute mesentric ischaemia⁷².

Smerud MJ et al (1990)¹⁰⁶ in their comparative study of plain X-rays and CT for bowel infarction concluded that plain films remain an important tool in patients suspected of mesentric infarction and can provide information that is complementary to computed tomography.

Federle MP and Jeffrey RB (1983)³⁷ have reported that CT can usually help to distinguish between haemoperitoneum from other types of ascites. Fresh blood may demonstrate a 'haematocrit effect' caused by layering of heavier cellular elements and clot beneath the supernatant serum.

CT has been found to be sensitive for a wide variety of diagnosis like appendicitis, diverticulitis intestinal ischemia, pancreatitis, intestinal obstruction and perforated viscus^{52,72}.

**DIFFERENTIAL DIAGNOSIS OF SOME OF THE COMMON
CAUSES OF ACUTE ABDOMINAL PAIN**

Disease	Location of pain and prior attacks	Mode of onset and type of pain	Associated gastro intestinal symptoms	Physical Examination	Helpful tests and examinations
ACUTE APPENDICITIS	Periumbilical or localized generally to right lower abdominal quadrant	Insidious to acute and persistent	Anorexia common; nausea and vomiting in some	Low-grade fever. Epigastric tenderness initially; later, right lower quadrant	Slight leukocytosis. no specific or sensitive diagnostic test available
INTESTINAL OBSTRUCTION	Diffuse	Sudden onset Crampy	Vomiting common	Abdominal distention; high pitched rushed	Dilated, fluid filled loops of bowel on abdominal x-ray
PERFORATED DUODINAL ULCER	Epigastric. History of ulcer in many	Abrupt onset Steady	Anorexia; nausea and vomiting	Epigastric tenderness. Involuntary guarding	Upright abdominal x-ray shows air under diaphragm water soluble contrast study shows
DIVERTICULITIS	Left lower quadrant History of previous attacks	Gradual onset Steady or crampy	Diarrhoea common	Fever common, mass and tenderness in left lower quadrant	Barium enema shows divertic ulitis. CT scan or gallium scan shown inflammatory mass
INFLAMMATORY BOWEL DISEASE	Diffuse; primarily in lower abdomen. Prior attacks common.	Gradual onset Often crampy.	Diarrhoea common, often with blood and mucus	Fever. Diffuse abdominal tenderness	Blood and leucocytes in stool. Abnormal results on proctosigmoidoscopy or barium enema.
ACUTE CHOLECYSTITIS	Epigastric or right upper quadrant; may be referred to right shoulder	insidious to acute	Anorexia; nausea and vomiting	Right upper quadrant tenderness	Right upper quadrant Sonography shows gall stones. Radionuclide scan shows nonvisualization of gall
BILIARY COLIC	Intermittent right upper quadrant Prior attacks common	Often abrupt onset Dull to sharp	Anorexia; nausea and vomiting common	Right upper quadrant tenderness	Sonography shows gall stones; oral cholecystogram shows stones or nonvisualization on

ISCHEMIC COLITIS	Epigastric Diffuse. Prior attacks common	Often abrupt Crampy	Diarrhoea commonly bloody	Diffuse abdominal tenderness. Vascular disease	X-ray shows thumb printing of mucosa. Visceral angiography shows vascular obstruction
RUPTURED ABDOMINAL AORTIC ANEURYSM	Epigastrium and back	Abrupt Sharp and severe	Variable; may be none	hypotension or shock Abdominal aneurysm	Lateral abdominal x-ray shows calcification in aneurysm Sonography, CT scan or angiography shows aneurysm
RENAL COLIC	Costovertebral or long course of ureter	Sudden. Severe and sharp	frequently nausea and vomiting -	Flank tenderness	Hematuria. Abnormal excretory urogram (stones, hydronephrosis)
ACUTE PANCREATITIS	Epigastric penetrating to back	Acute, persistent, severe	Anorexia; nausea and vomiting common	Epigastric tenderness.	Elevated serum amylase. CT scan shows pancreatic inflammation

MATERIALS AND METHODS

This study “DIAGNOSTIC ACCURACY OF RADIOLOGICAL INVESTIGATIONS IN ACUTE ABDOMEN” was carried out at BLDE UNIVERSITY SHRI B.M.PATIL MEDICAL COLLEGE HOSPITAL, BIJAPUR. from October 2008 to May 2010.

The 100 patients who form the basis of this study were randomly selected, fulfilling the inclusion and exclusion criteria. These comprised of patients who presented with acute abdominal pain (of non-traumatic origin) at the emergency department, surgical out patient department, surgical wards and patients referred from other departments.

Only those cases that underwent surgery have been included in this study, as the correct diagnosis could be established only then.

Each case was assessed with the help of a specially designed proforma. All cases were subjected to a detailed history and a thorough physical examination to arrive at a clinical diagnosis. The details recorded in the proforma and analysed.

The radiological investigations comprised of plain abdominal x-ray, ultrasonography and CT scan for which no ordering protocol was followed. It was left to the discretion of the treating unit to order the investigation which they felt most appropriate for each case. Radiologic diagnosis was made after the official report by the radiologist. The radiologic investigations were divided into two categories, ones with positive findings were considered diagnostic and the others considered inconsistent.

All the final diagnoses were operative. In all cases the operative findings and post-operative diagnosis were recorded. Histopathological examination was called for where necessary.

As soon as possible after admission routine investigations namely: - Hb%, TC, DC, ESR, Urine routine were carried out. A relevant procedure like four quadrant aspiration was carried out in some cases. A Widal test was done in suspected cases of enteric fever.

The pre-operative preparation essentially consisted of treating shock, correction of dehydration, gastric aspiration and antibiotic administration.

Treatment was instituted according to the cause of acute abdomen. Complications if any were noted and managed accordingly.

Inclusion Criteria:

Only patients undergoing surgery are included.

Exclusion Criteria:

1. Pediatric age group (i.e., 12 years and below)
2. Traumatic cases (blunt and penetrating)
3. Acute abdomen in pregnancy and gynecological causes of acute abdomen.
4. Conservatively managed cases.

Tools Used:

1. X2 Test: Chi-square is calculated with the help of the following formula

$$X^2 = \frac{\Sigma(O - E)^2}{E}$$

Where O is the observed (=actual) frequency and E is the expected frequency. The latter is calculated on the basis of "null hypothesis". According to the hypothesis, there is no difference in the frequency of the attribute in the 2 (or more) samples.

The P value is obtained by referring to the table of χ^2 values across the appropriate 'degree of freedom'. The latter is calculated with the help of the following formula:

degree of freedom = (C-1) (r-1) where 'C' is the number of columns and r is the number of rows.

2. 't' Test:

The value of 't' is found out with the following formula

$$t = \frac{\bar{X}_1 - \bar{X}_2}{\sqrt{SP_2 \left(\frac{1}{n_1} + \frac{1}{n_2} \right)}}$$

Where \bar{X}_1 is the mean of first sample
 \bar{X}_2 is the mean of second sample
 n_1 is the size of first sample
 n_2 is the size of second sample

$$SP^2 = \frac{\Sigma(X_1 - \bar{X}_1)^2 + \Sigma(X_2 - \bar{X}_2)^2}{n_1 + n_2 - 2}$$

The P value is determined by looking horizontally along the degree of freedom in a table of 't' values. The degree of freedom equals ($n_1 + n_2 - 2$).

Any 'p' value of 0.05 or less is regarded as significant at 95° confidence level.

OBSERVATIONS AND RESULTS

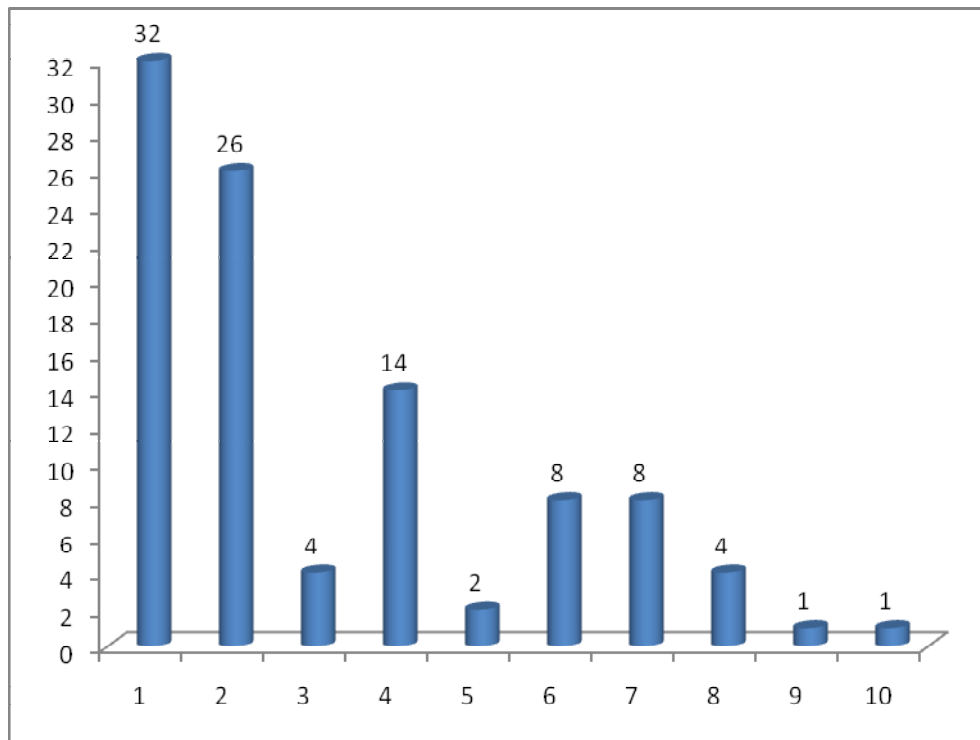
1) CAUSES OF ACUTE ABDOMEN :

The study consisted of 100 cases of acute abdomen. The true causes of these, as noted at operation, are presented in table-1 and figure-1.

Table-1 Causes of acute abdomen as noted at operation

Causes of acute abdomen	No. of cases	Percentage
Acute appendicitis	32	32
Perforated duodenal ulcer	26	
Perforated gastric ulcer	4	
Perforated Peptic Ulcer	30	30
Intestinal obstruction, small bowel	14	
Intestinal obstruction, large bowel	2	
Intestinal obstruction	16	16
Acute cholecystitis	8	8
Ileal perforation	8	8
Obstructed hernia	4	4
Necrotizing pancreatitis	1	1
Colonic perforation	1	1

Figure -1 causes of acute abdomen as noted at operation.



- 1 Acute appendicitis
- 2 Perforated duodenal ulcer
- 3 Perforated gastric ulcer
- 4 Intestinal obstruction, small bowel
- 5 Intestinal obstruction, large bowel
- 6 Acute cholecystitis
- 7 Ileal perforation
- 8 Obstructed hernia
- 9 Necrotizing pancreatitis
- 10 Colonic perforation

2. AGE AND SEX:

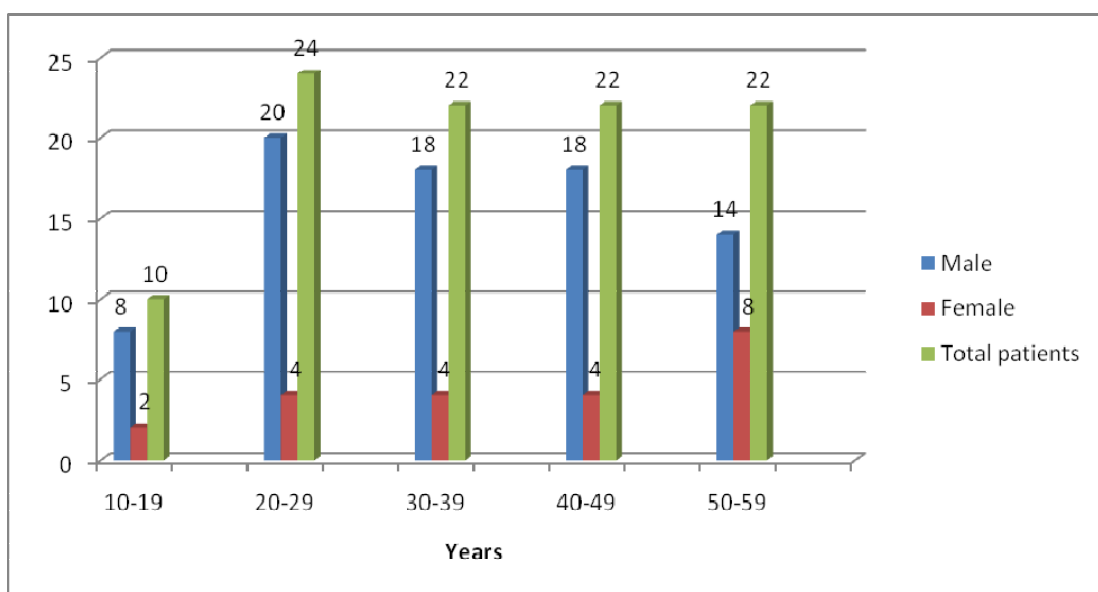
The age and sex distribution of the 100 cases of acute abdomen is depicted in table-2 and figure-2.

Duodenal and gastric ulcer groups are treated as one category (peptic ulcer perforation), small and large bowel obstruction are regarded as a single group (intestinal obstructions). Obstructed hernia, Necrotizing pancreatitis, and Colonic perforation are clubbed to form the miscellaneous group.

Table-2 Age and sex distribution of 100 cases of acute abdomen

Age Group	Males	Females	Total	Cumulative Frequency
10-19	8	2	10	10%
20-29	20	4	24	34%
30-39	18	4	22	56%
40-49	18	4	22	78%
50-59	14	8	22	100%
Total	78	22	100	100%

Figure-2 Age and sex distribution of 100 cases of acute abdomen.



3. AGE :

The mean age of the 100 cases of acute abdomen was 35.88 years with a standard deviation (SD) of 12.55 years.

The mean age and SD of causes of acute abdomen are shown in table-4.

The age differences in the causes of acute abdomen as a whole are not significant ($p = 0.073$). The difference in the mean age of acute appendicitis and perforated ulcers is significant ($p = 0.0273$). The difference between acute appendicitis and intestinal obstruction too is significant ($p=0.0153$) and that between acute appendicitis and acute cholecystitis too is significant. ($p = 0.0350$)

The age distribution of the two largest groups, acute appendicitis, (32 cases) and peptic ulcer perforation, (30 cases) is compared in table-3 and figure-3.

Cases of acute appendicitis are more common below 30 years, whereas those of peptic ulcer perforation are more frequent above 30 years. In other words, with the rise in age, the proportion of peptic ulcer perforation in relation to acute appendicitis steadily increases.

Table-3 Comparative age distribution of acute appendicitis and peptic ulcer perforation:-

Age Group	Acute Appendicitis	Peptic ulcer Perforation
10-19	8	2
20-29	10	4
30-39	8	10
40-49	4	8
50-59	2	6

Figure-3 Comparative age distribution of acute appendicitis and peptic ulcer perforation:-

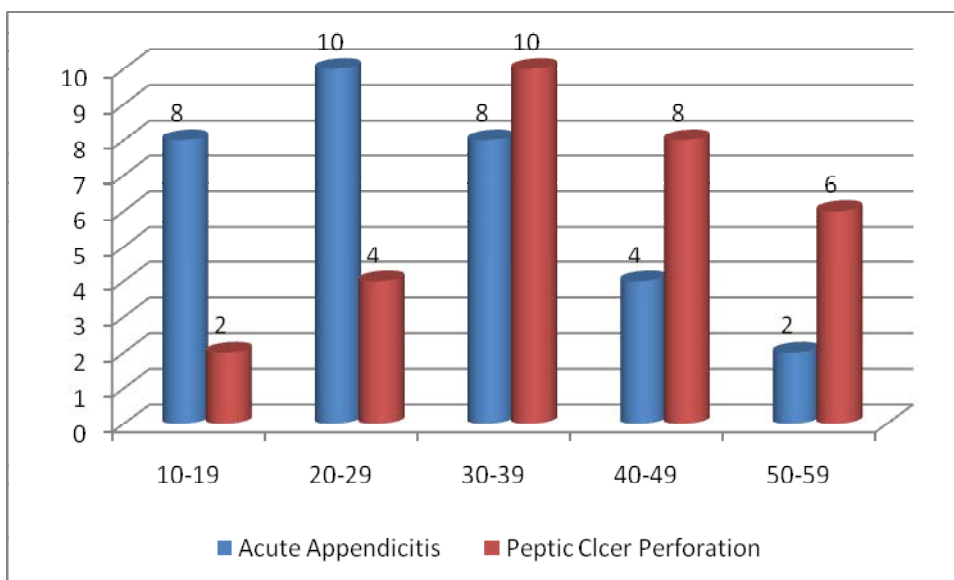


Table 4 : The mean age and SD of causes of acute abdomen

Cause	Mean age Yrs.	SD Yrs.
Acute Appendicitis	28.6	11.73
Peptic ulcer perforation	38.53	11.6
Intestinal Obstruction	42.13	9.1
Ileal perforation	36.7	18.32
Miscellaneous	33	10.81

4. SEX RATIO :

The overall sex ratio is 39:11, males to females. Males are 3.55 times as likely to suffer from acute abdomen as females. Male preponderance is true of all age groups from 10 to 50.

The sex ratio by cause of acute abdomen is shown in table-5.

Males predominate in all categories except acute cholecystitis which has affected only females. These differences are statistically highly significant ($p=0.004$).

Table-5 Sex ratio by causes of acute abdomen.

Cause of acute abdomen	Sex Ratio (Males: Females)
Acute appendicitis	2.6: 1
Peptic ulcer perforation	5 : 1
Intestinal obstruction	3.2:1
Illeal perforation	3.5: 0
Acute cholecystitis	0:8
Miscellaneous	2:1

5. SYMPTOMS :

The presenting symptoms in 100 cases of acute abdomen are presented in table 6 and figure-4.

The most prominent symptom was pain. This was present in the all cases of 'acute abdomen', both at onset of attack and at hospitalization.

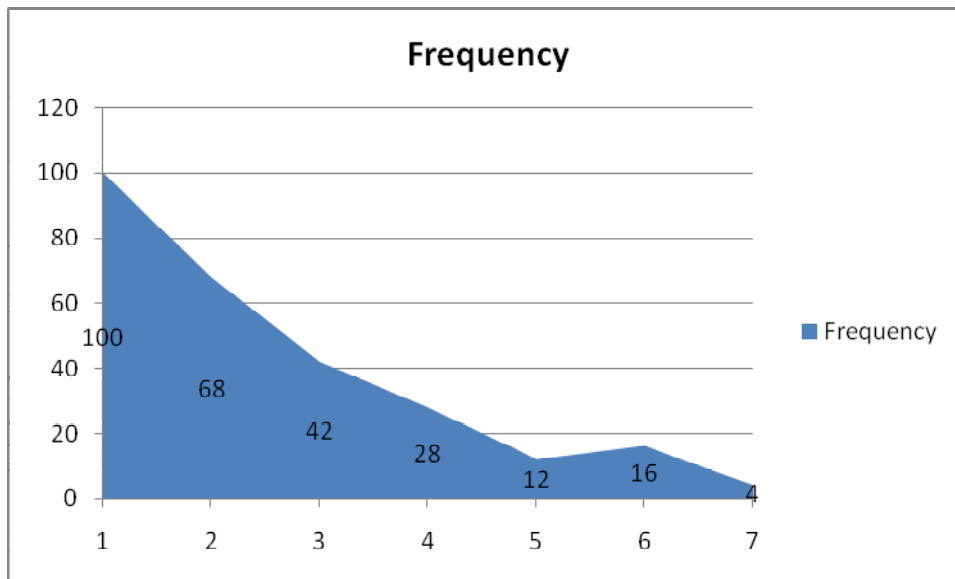
The mean duration of pain in the 100 cases of acute abdomen was 53.76 hours with SD of 19.84 hours. The mean and SD of the cases by type of acute abdomen is depicted in table-7.

The duration of pain was longest in ileal perforation, and the shortest in acute cholecystitis. The differences in the mean duration of pain by type of acute abdomen, however, is not statistically significant ($p=0.211$).

Table-6 The presenting symptoms in 100 cases of acute abdomen:-

Symptom	Frequency	Percent
Pain	100	100
Vomiting	68	68
Constipation	42	42
Fever following pain	28	28
Fever before pain	12	12
Diarrhoea	16	16
Blood in stools	4	4

Figure -4 The presenting symptoms in 100 cases of acute abdomen:-



1. Pain
2. Vomiting
3. Constipation
4. Fever following pain
5. Fever before pain
6. Diarrhoea
7. Blood in stools

SITE OF PAIN:-

Site of pain at onset varied according to the underlying cause of acute abdomen. It was umbilical in cases of acute appendicitis and intestinal obstruction. It was epigastrium in peptic ulcer perforation. And in acute cholecystitis, it was the right hypochondrium.

The preferred site of pain at admission to hospital was right iliac fossa in cases of acute appendicitis. It was diffuse all over the abdomen in cases of peptic ulcer perforations, ileal perforation, and necrotizing pancreatitis. In acute cholecystitis, the commonest site of pain at admission was the right hypochondrium.

TYPE OF PAIN:

In 70 cases pain was continuous in nature, and in the rest it was intermittent. Continuous pain was a feature in acute appendicitis and peptic ulcer perforations. Radiation of pain to the back was found in 8% of the cases and was an important feature in acute cholecystitis.

Table-7 Duration of pain in acute abdomen by cause:-

Cause of acute abdomen	Mean (Hr.)	SD Hr.
Acute Appendicitis	58.5	17.5
Peptic ulcer perforation	43.2	22.92
Intestinal obstruction	57.0	17.86
Ileal perforation	66.0	12.0
Acute cholecystitis	48.0	19.6
Miscellaneous	64.0	13.86

SIGNS:-

Table-8 and Fig-5 gives the frequency of different signs in 100 cases of acute abdomen.

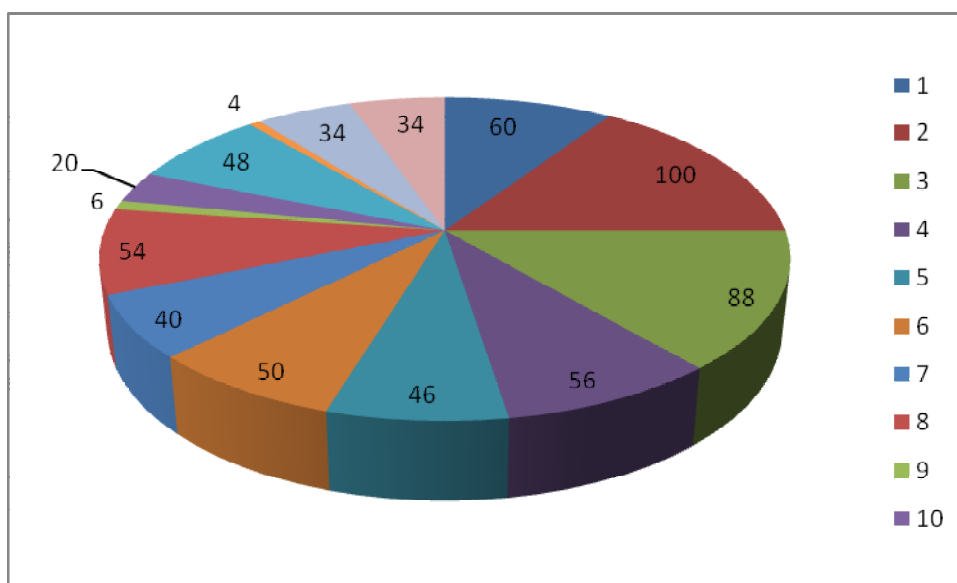
Tenderness was positive in all cases. The next common features were guarding, abdominal distension, abnormal bowel sounds and tachycardia.

The leading signs in different kinds of acute abdomen are presented in table-9.

Table-8 Signs in 100 cases of acute abdomen:-

Sign	Frequency	Percent
Abdominal distension	60	60
Tenderness	100	100
Guarding	88	88
Rigidity	56	56
Liver dullness obliteration	46	46
Free Fluid	50	50
Fever	40	40
Tachycardia	54	54
Abdominal mass	6	6
Tenderness per rectum	20	20
Abolished/ diminished bowel sounds	48	48
Increased bowel sounds	4	4
Shock	34	34
Dehydration	34	34

Figure-5 Signs in 100 cases of acute abdomen:-



Past History of Pain:

A past history of pain was elicited in 52% cases. None of the cases of ileal perforations and necrotizing pancreatitis had a past history of pain. All cases of cholecystitis had history of dyspepsia and abdominal pain. The proportion of patients having past history of pain was 53.3% in peptic ulcer perforation and 50% in acute appendicitis.

Four Quadrant Aspiration:-

This was done in 21 cases. Bile was aspirated in all 15 cases of peptic ulcer perforation. Pus was obtained in 1 case of acute appendicitis. Fecal matter was seen in 3 cases of ileal perforations.

Table-9: Four leading signs in different kinds of acute abdomen:-

Type of acute abdomen	First leading feature	Second leading feature	Third leading feature	Fourth leading feature
Acute appendicitis	Tenderness (100%)	Guarding (75%)	Tachycardia (68.8%)	Fever (43.8%)
Peptic Ulcer Perforation	Tenderness (100%)	Obliteration of liver dullness (100%)	Guarding (100%)	Rigidity (100%)
Intestinal Obstruction	Tenderness (100%)	Guarding (87.5%)	Abnormal bowel sounds (87.5%)	Abdominal Distention (75%)
Ileal Perforation	Tenderness (100%)	Fever (100%)	Guarding + Rigidity (100%)	Obliteration of liver dullness (100%)
Acute Cholecystitis	Tenderness (100%)	Guarding (100%)	-	-

Characteristics of the 3 major groups:

1. **Acute Appendicitis:** Acute appendicitis accounted for 32% of all cases of acute abdomen. The mean age was 28.6 years. The majority were in the 10-39 year group. The peak of incidence was in the 20-29 group. Males were 3 times as many as females. Pain was present in all the 32 cases. At the time of onset, pain was mostly over the umbilical region. At the time of admission, the commonest site was the right iliac fossa.

On examination, the tenderness was found in the right iliac fossa in the majority of cases. Other common features included tachycardia, guarding, rigidity and fever.

2. **Peptic Ulcer Perforation:** Peptic ulcer perforation was responsible for 30% of attacks of acute abdomen. The mean age was 38.53 years. Most of the patients were over 30 years. The peak of incidence was in the 30-39 year group. Males outnumbered females by 6.5 times. At onset, pain was felt commonly in the epigastrium. At admission, it was diffuse and present all over abdomen.

Past history of pain was available in about half the cases. Tenderness was diffuse all over the abdomen and was accompanied with guarding, rigidity and obliteration of liver dullness. Free fluid and abolished bowel sounds also were common.

3. **Intestinal Obstruction:** Intestinal obstruction was responsible for 16% of acute abdomen. The mean age was 42.13 years. Males were 7 times as many as females. Pain at onset was commonly located at the umbilical region. Pain at the time of admission tended to be diffuse. Vomiting and constipation were the commonest symptoms.

The past history of pain was given by most patients. One quarter cases gave the history of past operation. On examination, the common findings were abdominal distension, diffuse tenderness, guarding, rigidity and abnormal bowel sounds.

X-RAY EXAMINATION:

Plain x-ray of abdomen was taken in 60 cases of acute abdomen. The break down of these is shown below:

Peptic ulcer perforation	30
Intestinal obstruction	14
Ileal perforation	08
Obstructed hernia	04
Acute appendicitis	04
TOTAL	60

FINDINGS:

Findings are discussed according to the type of acute abdomen.

Peptic Ulcer Perforation:

In the plain x-ray of all the 30 cases of peptic ulcer perforation, gas under either one diaphragm (80%) or under both diaphragms (20%) was visualized. In 16 cases (53.3%), additionally, multiple air-fluid level within bowel was present. Other rare associated findings were air fluid level below diaphragm (26.6%), ground glass appearance (20%), free fluid around bowel (13.3%), and free fluid below the diaphragm (26.6%), ground and free fluid in pelvis (6.6%).

Intestinal Obstruction:

Plain x-ray examination of abdomen in all 14 cases of intestinal obstruction showed multiple air-fluid level within bowel. In 8 cases (57.3%), additionally, distended small bowel segments were seen.

Ileal Perforation:

In 6 of the 8 cases, gas under the diaphragm was seen. The other findings were free fluid in the flank, free fluid around the liver, paralytic ileus and ground glass appearance.

Obstructed hernia :-

The x-ray of two cases of obstructed hernia showed multiple fluid levels, and ground glass appearance. The other two cases showed only multiple air-fluid levels in the bowel.

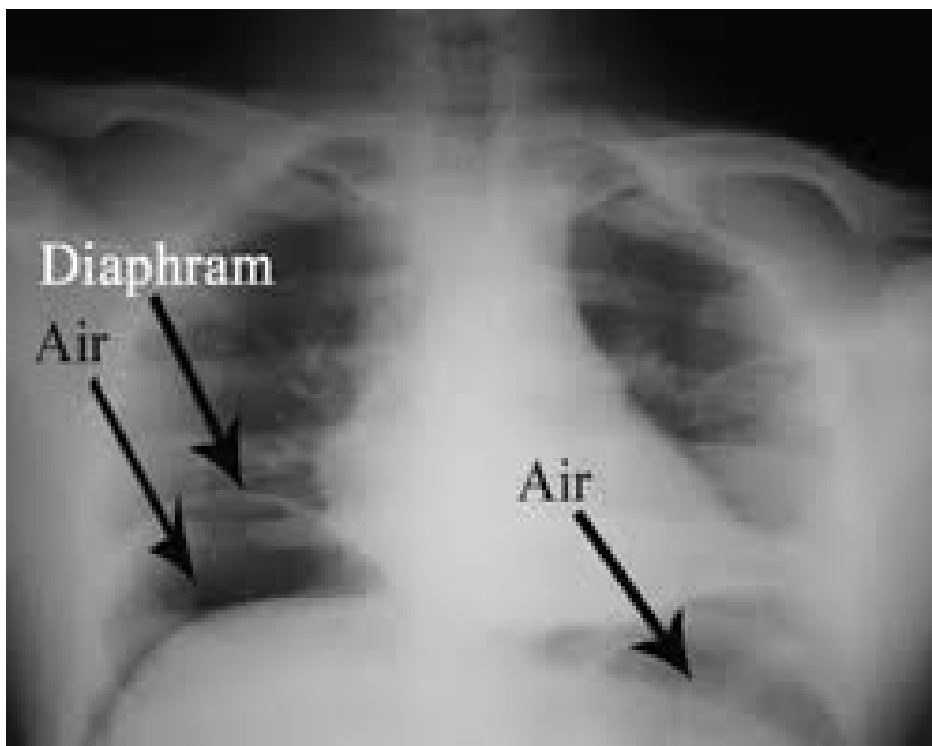
Acute Appendicitis:

The skiagram of the first case showed gas under one diaphragm, ground glass appearance, localized ileus, psoas obliteration and convex lumbar scoliosis. The other cases showed multiple air-fluid level and local ileus.

Figure-6: picture showing multiple air fluid levels

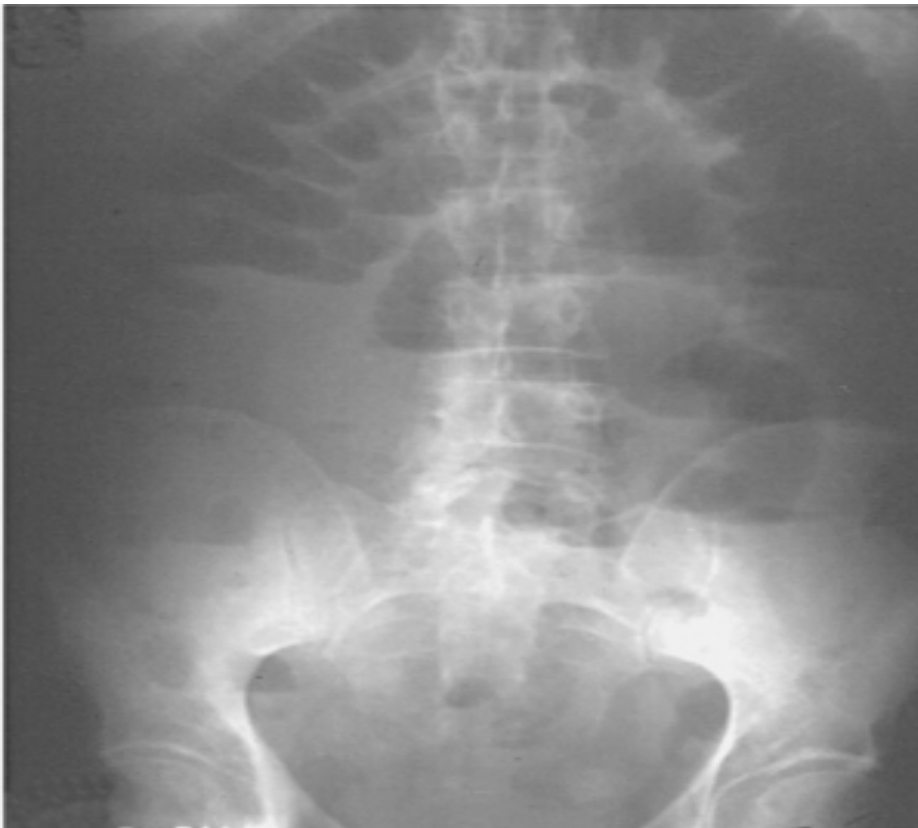

Figure-7: picture showing gas under both domes of diaphragm



ACCURACY OF PLAIN X-RAY EXAMINATION

The x-ray examination was inconclusive in 12 cases. It correctly diagnosed the type of acute abdomen in the remaining 48 cases. The correlation of clinical and radiological diagnosis is presented in table-10 and fig-8 and 9.

Table-10 Correlation between clinical and x-ray diagnosis in 60 cases:-

True type of acute abdomen	Number of cases x-	Clinical Diagnosis		X-ray diagnosis	
		Correct	Wrong	Correct	Wrong
Peptic ulcer perforation	30	30	0	30	0
Intestinal obstruction	14	12	2	10	4
Ileal perforation	8	8	0	6	2
Obstructed hernia	4	0	4	0	4
Acute Appendicitis	4	2	2	2	2
TOTAL	60	52	8	48	12

Figure -8 Correlation between clinical diagnosis and no of patients x-rayed:-

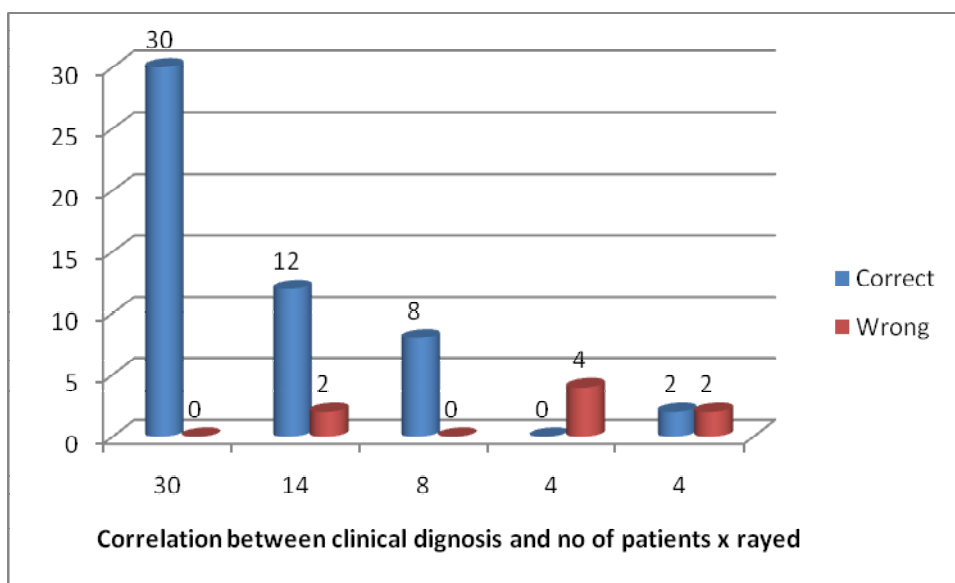
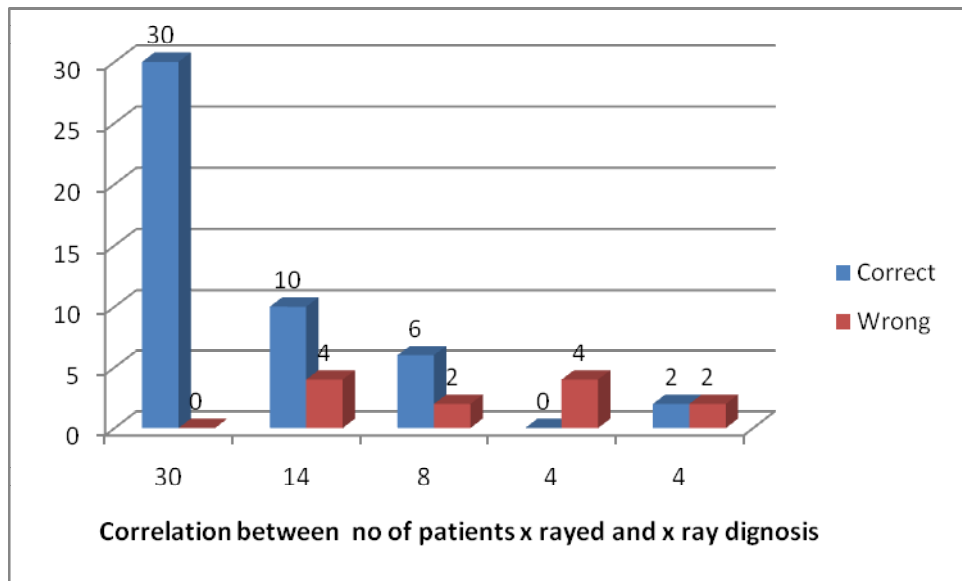


Figure -9 Correlation between x-ray diagnosis and no of patients x-rayed:-



DIAGNOSTIC ACCURACY CLINICAL VS X-RAY:

The clinical diagnostic accuracy for the above 60 cases was

$$\frac{52}{60} \times 100 = 86.6\%$$

The x-ray diagnostic accuracy for the cases => $\frac{48}{60} \times 100 = 80\%$

ULTRASONOGRAPHY:-

This test was carried out in 44 cases. The breakdown of these cases is given below:

Acute appendicitis	32
Acute cholecystitis	08
Intestinal obstruction	02
Miscellaneous	02
TOTAL	44

The correlation between clinical and ultrasonographic diagnosis is presented in table-11.

Table-11 Correlation between clinical and ultrasonographic diagnosis in 44 cases

True type of acute abdomen	number of ultrasonographies	Clinical Diagnosis		USG diagnosis	
		Correct	Wrong	Correct	Normal/equivocal
Acute Appendicitis	32	30	2	24	8
Acute cholecystitis	8	6	2	6	2
Intestinal obstruction	2	0	2	0	2
Meckel's diverticulitis	2	0	2	0	2
TOTAL	44	36	8	30	14

The clinical diagnostic accuracy in the above 44 cases is $\frac{36}{44} \times 100 = 81.81\%$

The ultrasonographic diagnostic accuracy is $\frac{30}{44} \times 100 = 68.18\%$

Figure -10 picture showing normal appendix on ultrasonography

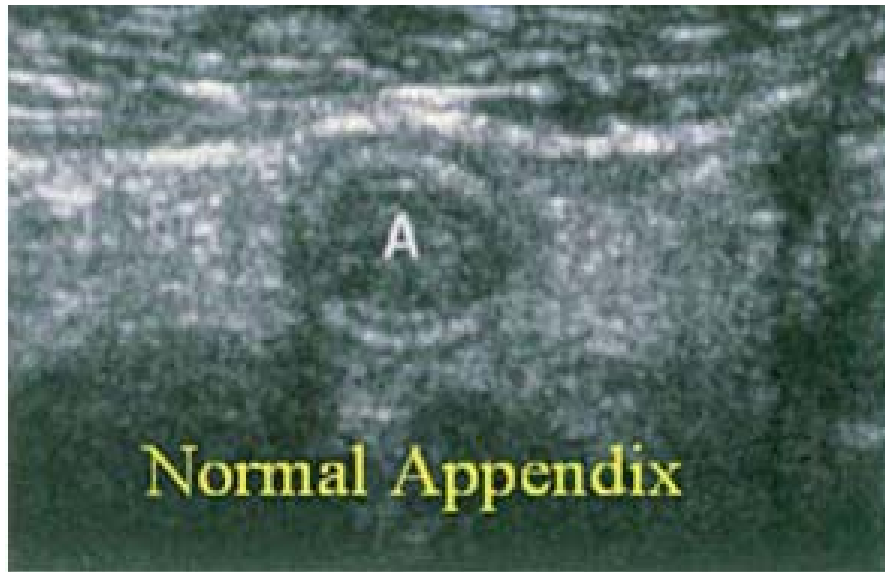
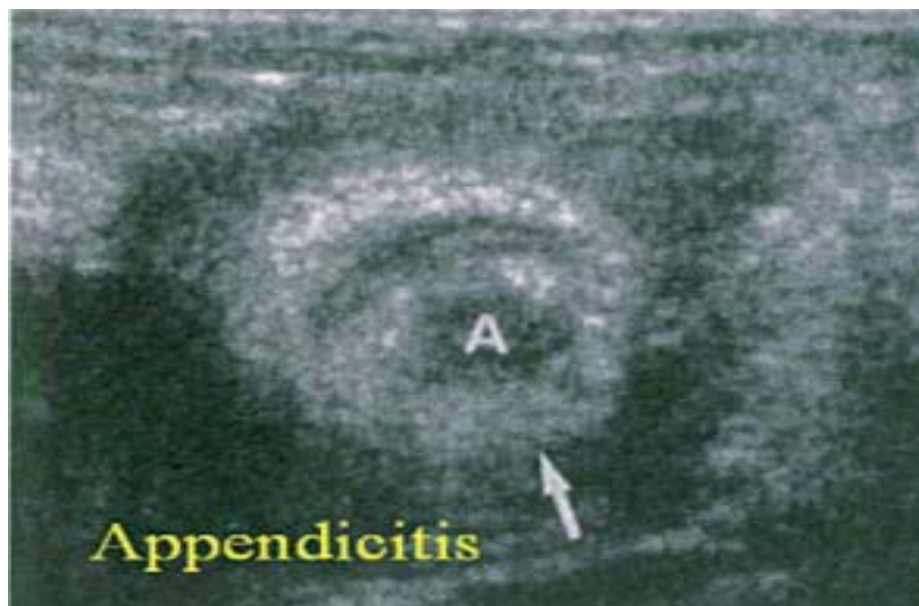


Figure -11 picture showing inflammed appendix on ultrasonography



DISCUSSION

This study was conducted in BLDE UNIVERSITY's Shri B M Patil Medical College Hospital & Research Centre, Bijapur . A total of one hundred patients were randomly selected, fulfilling selection criteria and studied.

Causes of acute abdomen:

The true causes of acute abdomen as noted at the time of operation are presented in Figure 1 and Table-1. From this, it is seen that the leading cause of acute abdomen in this study was acute appendicitis, constituting 32% of the cases.

The second common cause was perforated duodenal ulcer (26%). Intestinal obstruction accounted for 16% of the cases. The commonest cause of which, being adhesions and obstructed hernia. Adhesions and obstructed hernias have been documented as the commonest cause for small bowel obstructions and are of particular importance because they are the two main causes of strangulation of bowel^{3'6'23'51-56}.

In the present study two (one epigastric and one inguinal) out of four hernias underwent strangulation. These cases presented with more than 24 hours after onset of pain. Bussemaker and Lindeman (1972)¹⁸ in their experimental study showed that the canine mucosa could tolerate ischemia up to 4 - 6 hours and after 8 hours, the non-viable bowel perforated. Bowsman (1951)¹⁵ noted that he did not see gangrenous bowel if the duration of strangulation did not exceed 24 hours.

Large bowel obstruction was caused by a malignant growth in the descending colon.

In case of gastro-intestinal perforations the commonest anatomical site involved was duodenum (59%), followed by ileal (18%), appendicular (13.6%) and gastric (9%) perforations.

Dandapat M.C. et al (1991)²⁷ in their study of 340 cases of gastro intestinal perforations found duodenum as the commonest site involved (72.94%) followed by small intestine (ileal) (10%) stomach (8.23%) appendix (6.47%) and colon (2.5%).

Similar results were observed in a study conducted by Rao D.C.M.et al (1984)⁹² where the incidence of duodenal ulcer perforation was the highest (43.5%) followed by ileal, gastric and appendicular perforations. Sharma et al (1991)¹⁰² also reported that peptic ulcer perforations to be the commonest cause, while typhoid perforations (ileal) was the second common cause.

Acute cholecystitis constituted 8% of the cases. Obstructed hernia comprised 4% of the cases. There was one cases of necrotizing pancreatitis.

Age and sex distribution:

Age: Maximum number of cases were seen in age groups of 20-29 years accounting for 24% of the cases. The youngest patient was 11 years old and the eldest was 60 years.

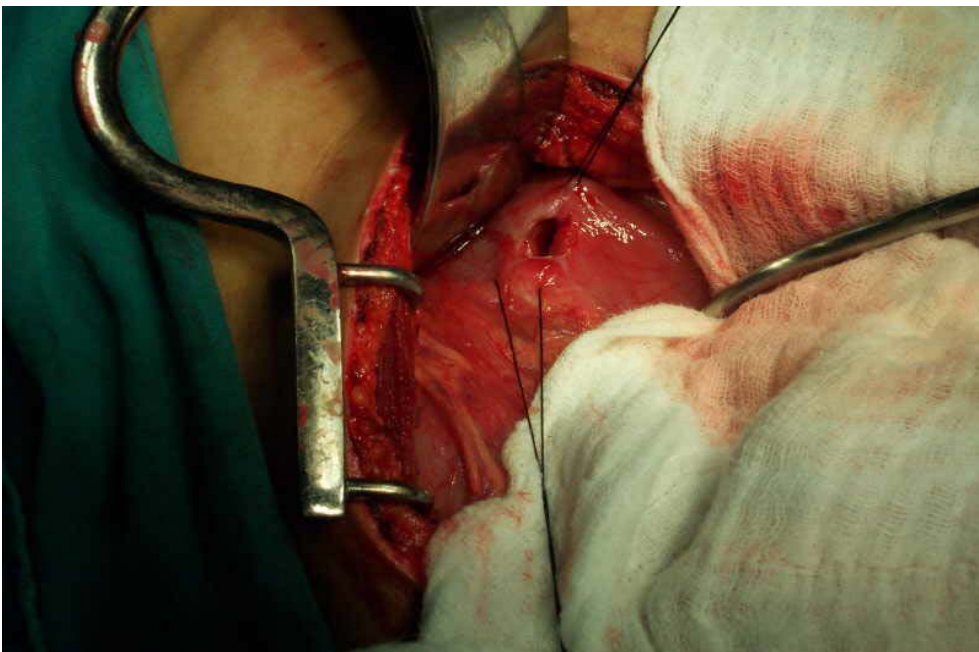
Peptic ulcer perforations (duodenal and gastric ulcers) commonly occurred between 30-49 years, accounting for 60% of the cases in this category. Kholi V. et al (1988)⁶¹ obtained similar results in their study, where the commonest age of presentation was between 30-50 years (66%).

Ramesh C.Bharti etal (1996)⁹¹ and Rao D.C.M et al⁹² (1984), reported high incidence of ulcer perforations in age groups of 31-40 years and 21-40 years respectively.

Figure -12 picture showing duodenal ulcer perforation

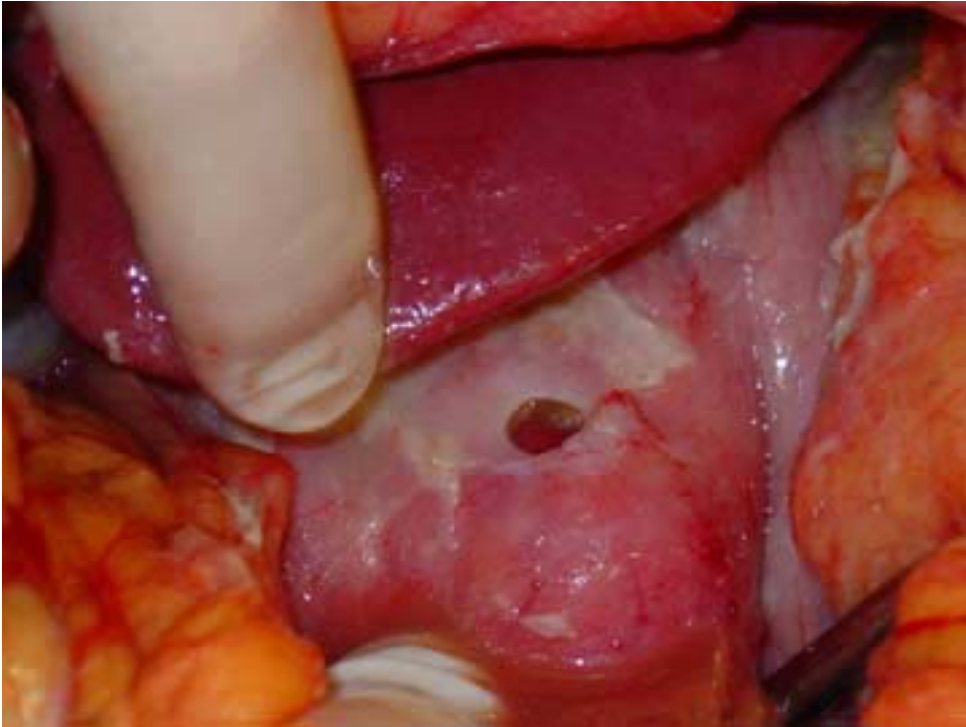

Figure -13 picture showing closure of the perforation



In our study only 15.38% of cases developed duodenal ulcer perforations below 30 years of age, which is close to figures quoted by Boey J. (1987)¹⁴ in his study (17%), emphasizing the rarity of this condition in the young.

The age distribution of the two largest groups, acute appendicitis and acute peptic ulcer perforation have been compared. From this it can be seen that:

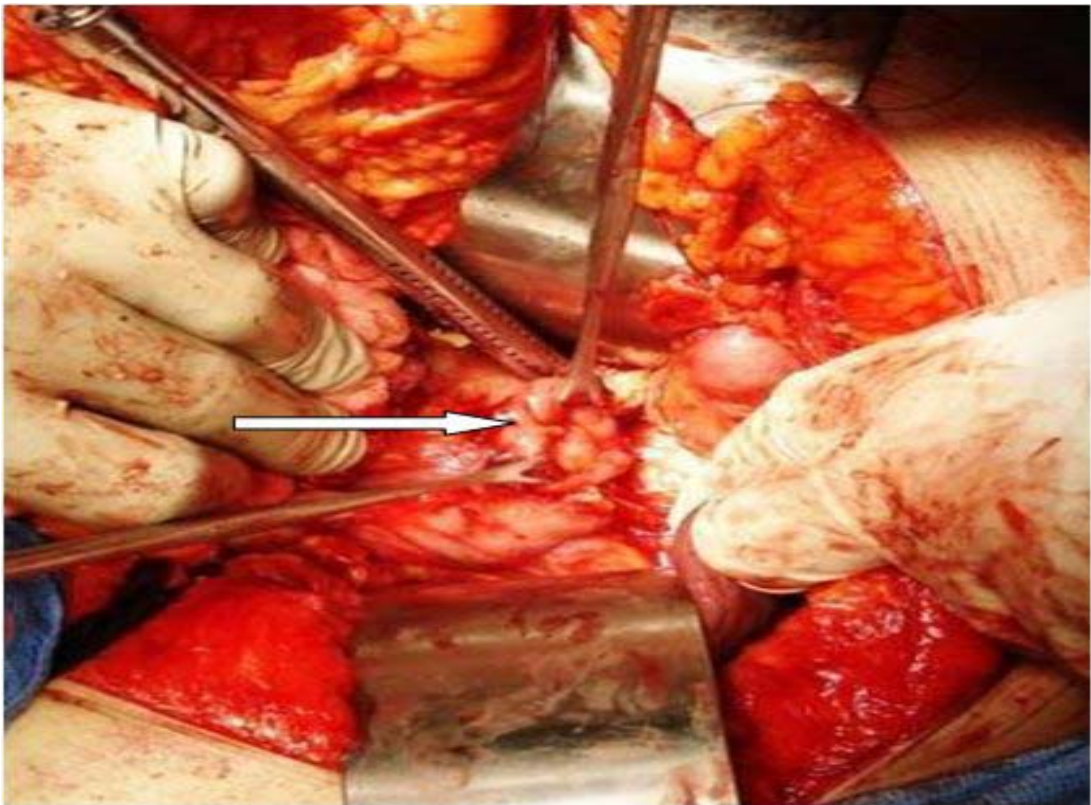
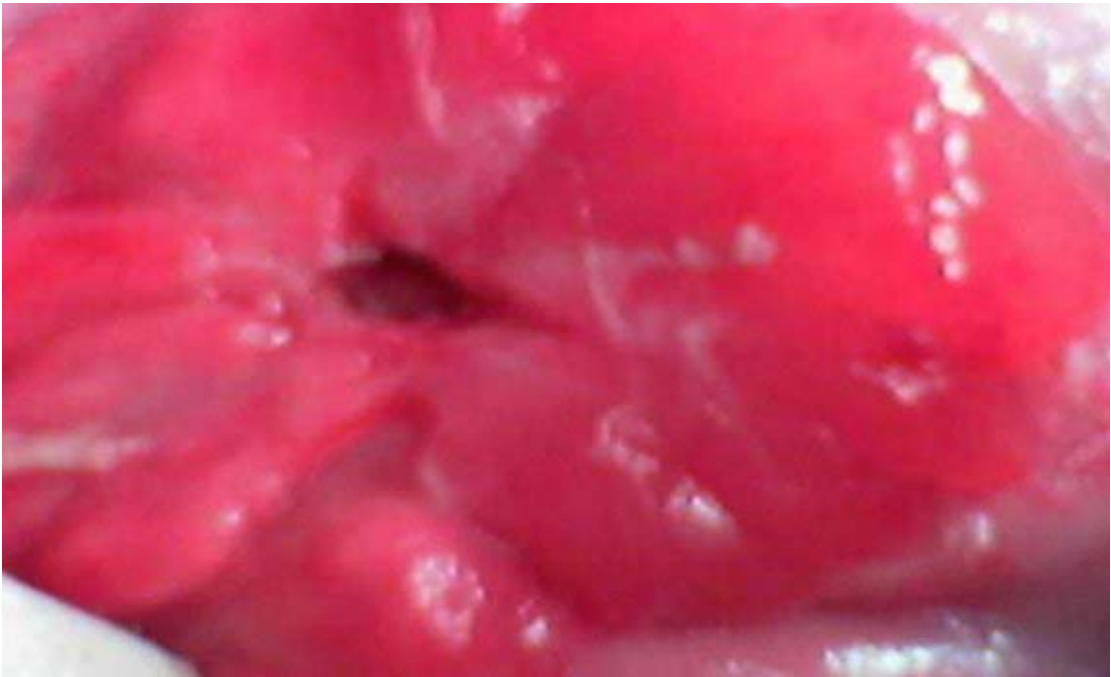
- a) Acute appendicitis was more common below 30 years, while peptic ulcer perforations were more frequent above 30 years.
- b) However there is a steady decline in incidence of ulcer perforations from 30 to 60 years. Rao D.C.M (1984)⁹² too observed a decline beyond 40 years of age in his study.

The mean age of different causes of acute abdomen have been studied. The age differences in the causes of acute abdomen on the whole are not significant ($p=0.073$), but the difference between:

- a) Acute appendicitis and perforated duodenal ulcer is significant ($p=0.0273$)
- b) Acute appendicitis and intestinal obstruction is significant ($p=0.0153$)
- c) Acute cholecystitis and acute appendicitis too is significant ($p=0.0350$)

In case of intestinal obstructions, the mean age was 42.15 years. Bhudaraja (1976)¹¹ reported maximum incidence between 21 - 50 years. However other Indian authors have reported maximum incidence between 21 - 30 years⁵¹.

Figure -14 pictures showing gastric ulcer perforation



SEX INCIDENCE:

In the present study, the overall sex ratio, males to females is 39:11, hence males are more than 3.5 times as likely to suffer from acute abdomen as females.

Males predominated in all categories except acute cholecystitis which had affected only females, the differences being statistically highly significant ($\chi^2=17.317$, $p=0.004$). Addison N.V. and Finnan P.J. (1988)² too showed acute cholecystitis to predominate in females.

With perforated peptic ulcers, majority were males and with only six females in this study. The ratio of men to women, with regards to perforated duodenal ulcers was 5:1. Since the beginning of the 20th century, perforated duodenal ulcer has mainly been a disease of men, but over the years the M: F ratio has been falling⁵⁶.

According to Western data, in 1924-1933, the ratio of males to females was 19:1 whereas by 1964-1973 the ratio had fallen to 4.4:1, as observed by Mackay^{68,69}. In a recent Western study by Jibril et al (1994)⁴⁹, a further change was demonstrated between 1975 and 1990. The M: F ratio of duodenal ulcer perforations was 3.7:1 and 1.5:1 respectively.

Similar trends have been observed in Indian studies too, Mishra S.B. et al (1982)⁸⁰ reported a M: F ratio as 49:1, Ramesh C. B. et al (1996)⁹¹ found a M: F ratio of 24:1 while Ladha S. (1998)⁶² reported a M: F 19:1.

The much higher incidence in males may be due to the fact that the males are more susceptible and prone to peptic ulcer and that alcohol and smoking are more common in males⁹¹.

The sex ratio in case of intestinal obstructions was 2.8:1, male: female in this study. Observations by Bhudharaja S.N. (1976)¹¹ are different; the sex ratio in this study was 4.1:1. This may probably due to less number of cases in our study.

With regard to acute appendicitis, in the present study the male: female ratio was 3:1.

In case of ileal perforations there were two females in this study. Rao D.C.M. (1984)⁹² too pointed out that incidence of ileal perforations to be less in females. As with necrotizing pancreatitis, in our study the patient was male falling in the 20-49 years age group. Pujari B (1987)⁸⁸ has documented that males are most frequently affected and the maximum incidence is between 20-45 years.

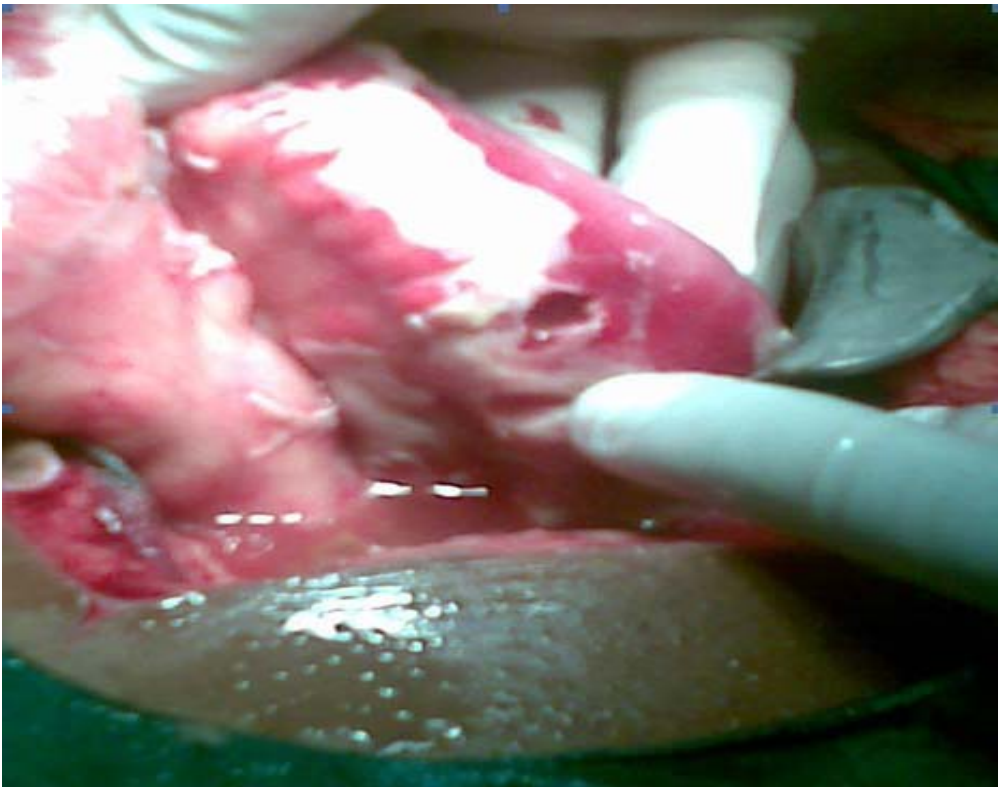
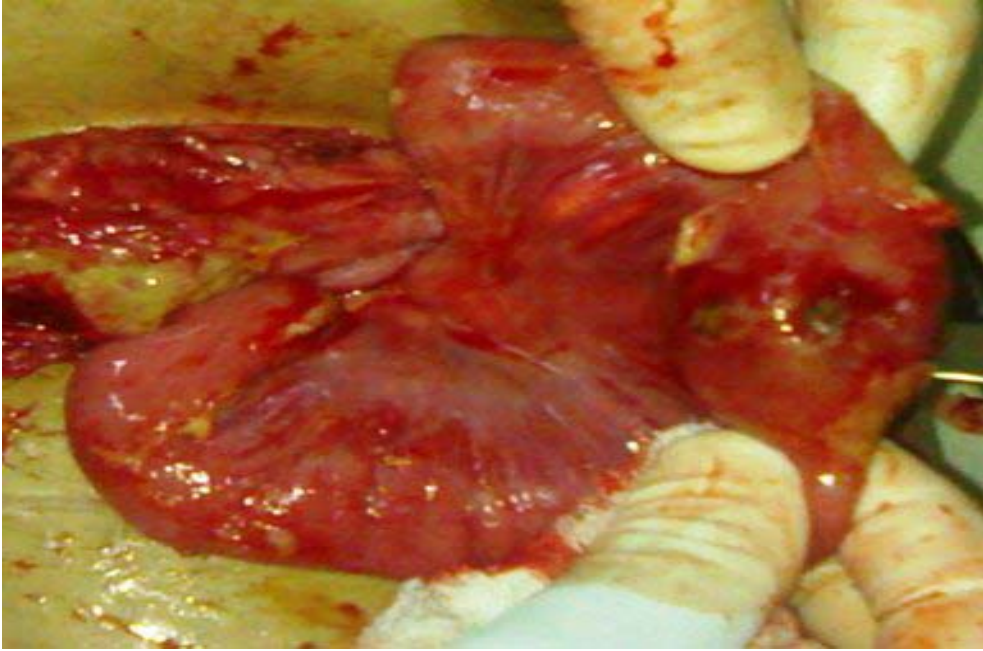


Figure -15 pictures showing ileal perforation

ABDOMINAL EXAMINATION

The abdominal physical findings in the 100 cases of acute abdomen in the present study have been analyzed.

- 1. Tenderness:** Tenderness was universally present in all the cases, but the site of tenderness varied according to the underlying cause of acute abdomen. The commonest site of tenderness in acute appendicitis was the right lower quadrant. In acute cholecystitis tenderness was localized to the right upper quadrant. In majority of the cases of acute appendicitis (without peritonitis) classical Mc Burney's tenderness was elicited except for a few who had diffuse right iliac fossa tenderness.
- 2. Guarding:** Guarding defined as moderate resistance to palpation was found in 88% of the patients. This involuntary tightening of muscles of the abdominal wall over an area of parietal peritoneal irritation is a more valuable sign because it is more objective than tenderness⁵⁶.
- 3. Abdominal rigidity:** Abdominal rigidity was present in all cases of perforations in this study. Kohli V. et al (1988)⁶¹ reported rigidity to be present in all 50 cases of perforated peptic ulcers, in his study making this sign to be an important indicator of peritonitis.
- 4. Abnormal bowel sounds:** Abnormal bowel sound (absent/ hypoactive/ hyperactive) were found in 52% of the cases, but as would be expected were most frequent in patients with intestinal obstruction (87.5%).
- 5. Rectal Examination:** - Tenderness on rectal examination was found in 31.25% of the patients with acute appendicitis, but in an insignificant percentage of the patients with other diagnosis. These are in accordance the findings of Brewer et al (1976)¹⁷ who in their acute abdominal series reported maximum frequency of

abnormal bowel sounds in cases of intestinal obstruction (93%). They also showed rectal tenderness to be positive in 30% of cases of acute appendicitis. But Dixon J.M. et al (1991)³⁰ have questioned the value of rectal examination in presence of other more important abdominal signs.

6. Obliteration of liver dullness:- Reflects presence of free intraperitoneal air in case of hollow viscus perforations^{28,56}. In the present study liver dullness was obliterated in all cases peptic ulcer perforations and ileal perforations. The sign was present only in one case of appendicular perforation with peritonitis. Overall liver dullness was obliterated in 91.6% of GIT perforations, emphasizing it to be a valuable indicator of hollow viscus perforations.

Kachroo et al (1984)⁵⁹ in their series found liver dullness to be obliterated in all cases of upper GI perforations. Belding M. (1957)⁹ too reported similar findings in cases of peritonitis due to perforation. However Nair S.K. et al (1981)⁸² reported the sign to be positive only in 63.63% of cases of ileal perforations.

7. Presenting Symptoms:

The presenting symptoms in 100 cases of acute abdomen have been studied. The commonest presenting symptom was abdominal pain (100%) which was present both at onset and at admission. The other predominant symptoms were vomiting (68%) constipation (42%) and fever (40%).

8. Duration of Pain:

Most of the patients suffered from pain between 6 hours to 72 hours before admission. The mean duration of pain was 53.76 hours. This was probably because substantial proportion of the patients reached the hospital after a

prolonged period of observation at home or after conservative treatment at local clinics.

The mean duration of pain in duodenal perforations was 43.2 hours. In patients with ileal perforations, the duration of pain was the longest (66 hours). Similar results were observed by Kachroo et al (1984)⁵⁹ where mean duration in case of duodenal perforations was 36 hours and ileal perforations ranked the longest (96 hours).

Stanland J.R. et al (1972)¹⁰⁷ in their study of 600 cases of acute abdomen showed most of the patients presented between 12 and 48 hours of pain onset. Temple C.L. et al (1995)¹⁰⁸ emphasized that appendicular perforations was a time related phenomenon, mean duration being 57.13 hours.

9. Site of Pain: The site of pain varied according to the underlying cause of acute abdomen. In cases of duodenal perforations the pain was 'stereotyped' as emphasized by Jordan P.H. and Morrow C. (1988)⁵⁷ as an abrupt onset of severe epigastric pain, that rapidly involves the entire abdomen.

In case of acute appendicitis, onset of pain was umbilical in 62.5% of the cases, and in 31.25% of the patients pain was felt solely in the right iliac fossa. Right hypochondrium was the preferred site of pain for patients with acute cholecystitis. It was presented in 6 out of 8 patients. However Stanland J.R. et al (1972)¹⁰⁷ reported that only 38% of their patients had pain localized in the right upper quadrant in acute cholecystitis and questioned its reliability.

In cases of acute intestinal obstruction, pain was over the swelling in case of obstructed hernias and umbilical due to other causes, reflecting the phenomenon of visceral pain and embryonic innervations of gut origin.

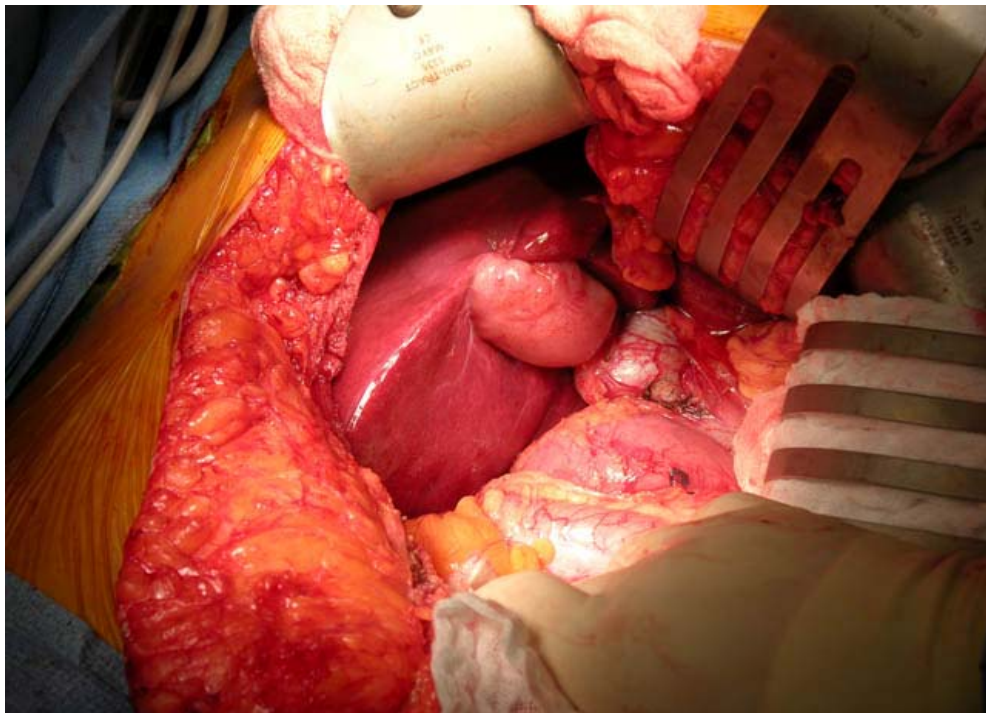
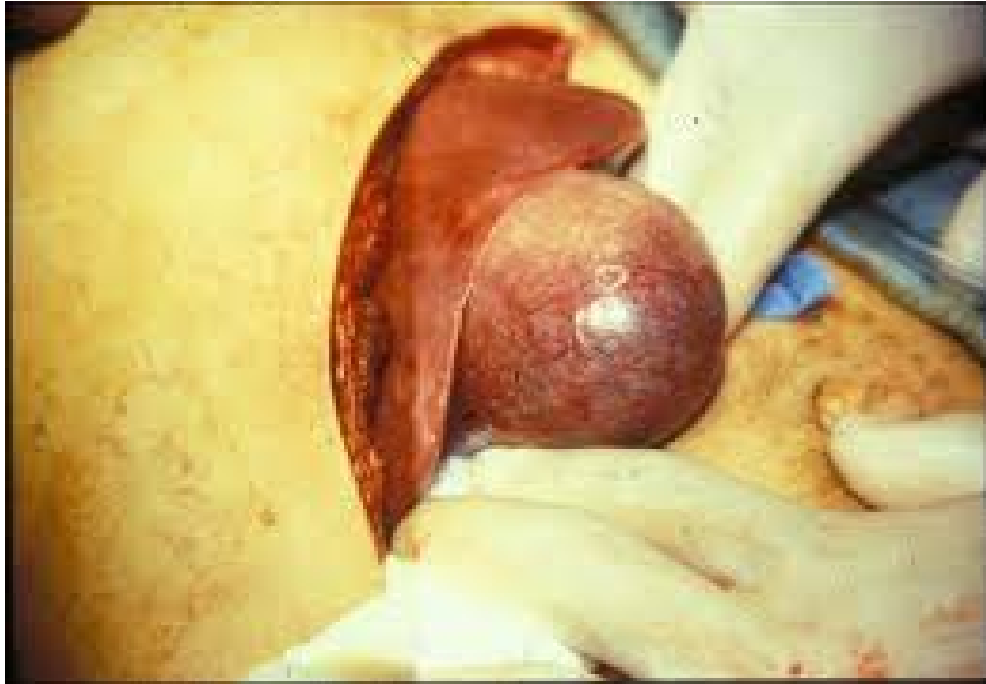

Figure -16 pictures showing acute cholecystitis

10. Type of Pain:

In 70% of cases the pain was continuous and in the rest it was intermittent. In acute appendicitis pain was predominantly continuous reflecting a progressing inflammatory process. Colicky and intermittent pain was commonly found in cases of intestinal obstruction. However in cases of strangulation the pain had become continuous.

11. Shift of Pain:

The characteristic shift of pain in case of acute appendicitis (umbilical to right lower quadrant) was found in 43.75% of the patients. John H. et al (1993)⁵⁴ reported pain migration to be a reliable symptom in acute appendicitis. In 31.25% of the patients pain was felt solely in the right iliac fossa from the time of onset. Jones P.P. and Bagley F.H. (1988)⁵⁶ have emphasized that in 25-30% of the patients will not experience shift of pain, in case of acute appendicitis. Radiation of pain to the back was commonly seen in case of acute cholecystitis in the present study.

As mentioned earlier the other predominant symptoms, in the study were vomiting, constipation and fever. Desa LA. et al (1983)²⁹ from Bombay showed that the common presenting symptoms were pain, followed by vomiting, abdominal distension, fever and constipation.

12. Fever: Fever prior to the onset of pain was present in 6 out of 8 cases of typhoid ileal perforations. Pain started in the lower abdomen and became generalised. History of fever for several days followed by severe abdominal pain with rapid deterioration in general condition is the most significant feature in cases of perforations due to enteric fever⁸².

13. Vomiting and Bowel Habits: Vomiting was an important symptom in acute intestinal obstruction and was present in 75% of these patients.

14. Past History of Pain: Two features of patients previous history namely the proportion of patients experiencing previous abdominal pain and those who had had previous abdominal surgery, are worthy of comment. In acute appendicitis about half the patients experienced similar episodes of abdominal pain and most of them underwent conservative treatment at various clinics.

Past history of peptic ulcer symptoms was present in 53.3% of the cases with perforated peptic ulcers. An ulcer history for a varying period was recorded in 30 cases by Mishra S.B. et al (1982)⁸⁰ in their study of 53 cases. In a review of 50 cases by Ramesh C.B. et al (1996)⁹¹, peptic ulcer history was present in 78% of the patients. Most of the patients were smokers, alcohol consumers or both. In a Western series by Stainland J.R. et al (1972)¹⁰⁷, 50% of the patients did not give previous history of abdominal pain. All the patients with acute cholecystitis gave a previous history of dyspepsia and abdominal pain and most of them had undergone treatment for acid peptic disease.

Past history of surgery:

Cox et al (1993)²⁶ in a retrospective study of 144 cases of small bowel obstruction from adhesions, reported that 80% had prior operations in the past. It is documented according to Jones P.P. and Keenan R.A.⁵⁶, 9 out of every ten patients with adhesive intestinal obstructions will have had a previous laparotomy and 2/3rds of these will have been performed on the appendix or other pelvic organs. 10% of the patients however will not have a history of laparotomy and the bands may be congenital or inflammatory.

In the present study we encountered 6 cases of adhesive intestinal obstruction. Four out of six cases had a previous laparotomy. Out of which two had an appendectomy three years back. However one patient did not give previous history of surgery and the band found at surgery was probably congenital in origin.

None of the patients with peptic ulcer perforations had previous surgery for peptic ulcer. The decline in the number of patients with peptic ulcer who require operation can be attributed in part to treatment with H₂ antagonists⁵⁷ and PPI's.

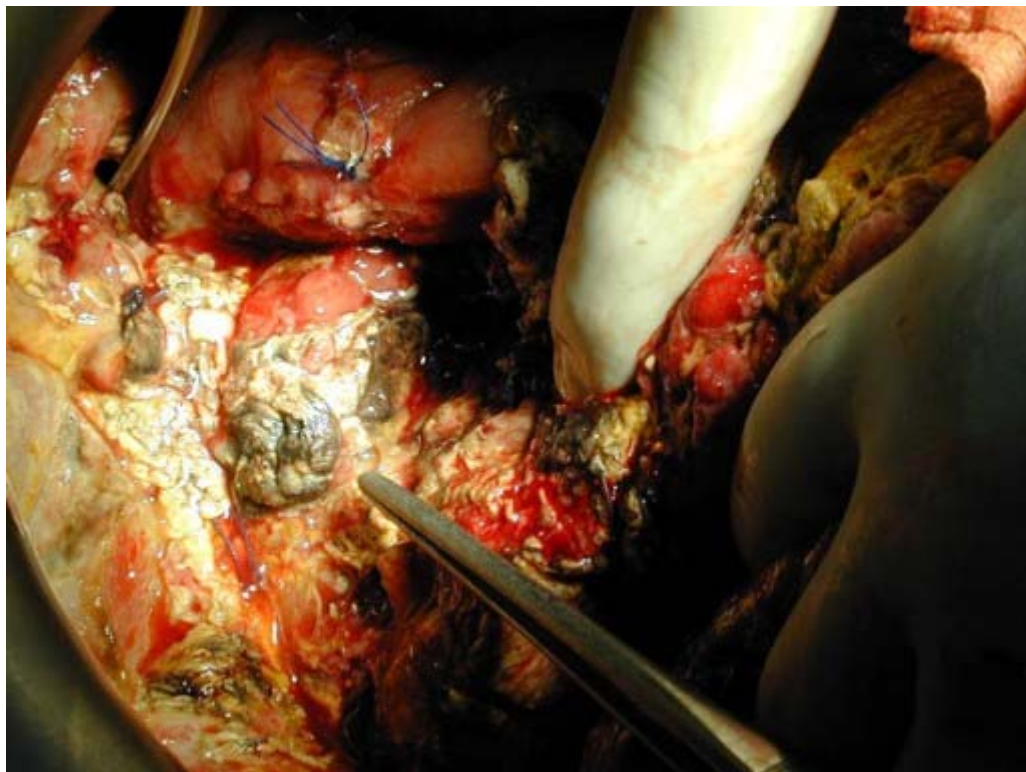
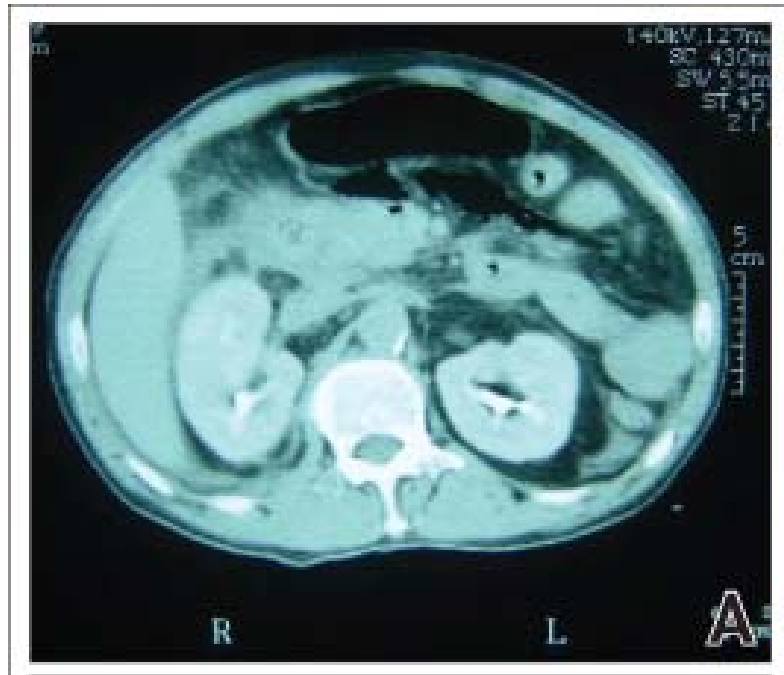

Figure -17 pictures showing acute necrotizing pancreatitis

X-RAY EXAMINATION

Peptic Ulcer Perforation (Duodenal and Gastric Ulcers) :

Plain x-ray of the abdomen, showed evidence of pneumoperitoneum in all 30 cases (100%) of the peptic ulcer perforation. Gas under either one dome of the diaphragm (80%) or under both domes (20%) was visualized. This agrees with the observations of Mishra et al (1982)⁸⁰ who in their study noted free gas under the diaphragm in all the cases. Similarly Kachroo et al (1984)⁵⁹, reported liver dullness to be obliterated in all cases of upper G.I. perforations and gas under diaphragm in x-rays of duodenal perforations. However Kohli V. et al (1988)⁶¹ reported that pneumoperitoneum which was the hall mark of peptic ulcer perforation could be demonstrated only in 82% of the cases they studied.

In a Western study Keefle EJ and Gagliarde RA (1973)⁶⁰ observed free intraperitoneal gas in 90% of the patients with perforated peptic ulcers. Belding (1957)⁹ too reported similar findings in case of perforations.

The other associated findings were multiple fluid levels (53.3%) suggestive of accompanying paralytic ileus and ground glass appearance (20%) due to peritonitis.

Various other findings observed in plain x-ray in cases of perforated duodenal ulcer are shown in the table and compared with findings of Lee (1976)⁶⁵.

All the 30 cases were diagnosed as peptic ulcer perforations clinically. At surgery four of these cases were found to be gastric ulcer perforations and the majority being duodenal ulcer perforations. X-ray abdomen erect or lateral decubitus were taken after the clinical diagnosis was made. Identification of pneumoperitoneum helped to confirm the diagnosis, of perforated bowel. In no case did the x-ray alter the clinical diagnosis.

Table-12: Radiologic signs in cases of perforated 'duodenal ulcer' (Plain x-ray abdomen)

Radiological Sign	Present Study	Study by Lee PWR
	% of cases	% of cases
1. Gas under diaphragm (single dome)	92.3	28
2. Gas under diaphragm (double dome)	7.69	28
3. Gas under liver	7.69	9
4. Gas on lateral x-ray	7.69	0
5. Free Fluid Around Stomach	0	9
6. Free fluid around liver	7.69	0
7. Free Fluid around bowel	15.3	9
8. Free fluid in flank	0	6
9. Free fluid in pelvis	7.69	3
10. Paralytic Ileus	53.8	3
11. Ulcer shown as niche	0	3
12. Ulcer shown by distorted duodenum	0	0

The diagnosis of Ileal perforations was mainly based on a history of fever prior to onset of abdominal symptoms, clinical signs like abdominal distension, rigidity, absent bowel sounds, faecal aspirate on four quadrant aspiration and a widal positive test (for somatic 'O' and flagellar 'H' antigen) suggestive of enteric etiology.

Similar conclusions were drawn by Chauhan and Pande (1982)²⁰, S.K. Nair et al (1981)⁸², Vaidyanathan S. (1986)¹⁰⁹ and Archampong (1976)⁴. They also reported that free-gas should be demonstrated intraperitoneally in 70-80% of ileal perforations.

Thus X-ray abdomen was helpful in providing evidence of a perforated viscus with peritonitis, which along with the clinical signs, symptoms and other investigations helped to identify the pathology.

Intestinal Obstruction:

The most frequent signs observed were multiple gas fluid levels and disproportionate gaseous distension of the bowel segments on erect abdominal X-ray, which was taken in 14 cases. "Step - ladder pattern" of small bowel obstruction were seen in some of the cases.

The "string of beads" sign described by Frimann Dahl in 1960⁶⁵⁻⁷⁸, caused by bubbles of air trapped under distended valvula conniventes of the small bowel, was found only in 14.2% of the cases. The "coffee-bean" sign of Mellins and Rigler (1954) and the pseudotumour of Frimann - Dahl (1944)^{65,78} described by these authors as specific signs of a strangulated bowel loop were not identified in this study. Plain x-ray abdomen was not helpful in diagnosing large bowel obstruction, which was eventually diagnosed by CT scan.

The diagnosis of intestinal obstruction was mainly based on history of colicky abdominal pain, vomiting and clinical signs of tenderness (100%), abnormal bowel sounds (87.5%) and abdominal distension (75%). The X-rays helped to confirm the suspected diagnosis in 71.4% of the cases and in the rest it was inconsistent. In no way was the clinical diagnosis altered by abdominal radiographs.

DEMONSTRATION OF PNEUMOPERITONEUM

Most series show that in only 75-80% of perforations free gas is demonstrable^{29, 12, 96}.

In the present study pneumoperitoneum was present in 83.3% of the perforations. In the remaining cases free gas was not demonstrable either due to sealing of the perforation, lack of gas at the site of perforation or adhesions around the site of perforation⁴⁰⁻⁷²⁻⁷⁸.

During the first 8 hours after perforation, around 50-60% of the patients will show positive for pneumoperitoneum and after 8 hours free gas is in over 80% of the patients⁵⁶. Most of our patients presented with more than 8 hours of perforation.

Free gas was demonstrated in 100% of peptic ulcer perforations, 75% of ileal perforations, and 33.33% of appendicular perforations.

From the above observations it was found that higher the site of perforation more is the number of cases demonstrating pneumoperitoneum.

Absence of pneumoperitoneum, thus however does not rule out hollow viscus perforation. In the appropriate clinical setting pneumoperitoneum is an ominous indicator of perforated bowel.

DIAGNOSTIC ACCURACY - CLINICAL AND X-RAY

In the present study, the surgeon's clinical diagnostic accuracy has been compared with the diagnostic accuracy of plain abdominal radiograph. The clinical diagnostic accuracy (86.6%) scored over that of plain X-ray (80%).

A number of articles have been published assessing usefulness of plain abdominal radiographs in cases of acute abdomen.

Lee P.W.R. (1976)⁶⁵ has advocated the routine use of plain abdominal x-rays in cases of acute abdominal pain, as he found positive radiologic features in 48% of the radiographs. However others like Brewer et al (1976)¹⁷ have contradicted this statement, saying that plain x-ray findings did not change nor contribute to a significant change in diagnosis or management. Mirvis et al (1986)⁷⁹ found only 20% of the x-rays to have positive findings in their study.

In our study, the clinical diagnosis was made after a proper history taking and physical examination. In some cases a differential diagnosis was made. X-rays were ordered for, after the clinical diagnosis was made. Abdominal radiographs are usually ordered to exclude or confirm a clinical diagnosis.

We found 80% of the x-rays to have positive findings and thus helpful in confirming the suspected diagnosis. In other words, positive x-rays outnumbered the inconsistent ones. And from the previous discussion it is obvious that none of the x-rays changed the clinical diagnosis already made.

The large number of positive radiographs in this study can be attributed to the fact that all cases presenting with acute abdomen were not x-rayed. The cases initially x-rayed included suspected cases of duodenal ulcer perforations, gastric ulcer perforations, ileal perforations, intestinal obstructions, peritonitis and appendicular perforations. Ultrasonography was used as the initial radiologic investigation in suspected cases of acute cholecystitis and appendicitis. Moreover, gynecologic cases, urologic and conservatively managed cases were not included. If all these cases were to be considered, the figures would probably be different.

Thus, plain abdominal radiographs are most helpful in confirming the presence of perforated hollow viscus and intestinal obstruction, and should be the initial imaging study in these cases. This is in agreement with observations made by other authors^{5,10,65,72}.

As Prof. Bhargava (1988)¹⁰ rightly says "Do proper plain x-rays of the abdomen first and the answer is mostly there, only one has to look for it, for eyes see only what the mind knows. One should know what to look for. Further investigations should be based on clinical cum plain film findings".

ULTRASONOGRAPHY

Acute Appendicitis:

Ultrasonography has changed the approach to the diagnosis of acute appendicitis, as evidenced by multiple studies over the past 12 years and continued debate regarding its usefulness persists^{72,96,99}. Opinion varies from recommending this study in all patients with suspicion of acute appendicitis, to questioning its use because of added cost without improved clinical outcome⁴¹.

In a report by Schwerek et al (1990)⁹⁹, the overall accuracy of ultrasonography was 96.3% in diagnosing acute appendicitis. Nevertheless, for John et al (1993)⁵⁴, in 74.8% of the cases ultrasound examination had no influence on the clinical decision making.

In our study, in 24 (75%) of the patients with surgically confirmed acute appendicitis, the appendix or its complications, namely abscess could be visualized unequivocally. The inflamed appendix is identified by its size, shape, location, non-compressibility, and presence of peri-appendicular fluid, abscess, or appendicolith^{1,89,99}.

In most of the patients the point of maximal tenderness (probe tenderness) could be elicited. One may call this as "Mc Burney's Sign"⁸⁹. In two patients in addition to visualized appendix, enlarged mesenteric lymph nodes could be demonstrated, and they were biopsied per-operatively.

Ultrasonography correctly identified appendicular abscess due to perforated appendix in all six cases of appendicular perforations, in which clinical diagnosis was uncertain. Additionally, in three cases it helped to rule out the possibility of other suspected pathologies like ureteric colic (two cases) and acute pancreatitis (one case).

However, 25% (eight cases) of the patients with normal ultrasound findings were ultimately found to have appendicitis at operation. These patients were operated solely on high clinical suspicion.

Several studies have compared the surgeon's clinical impression with ultrasonography. One study found clinical examination superior to ultrasonography, but noted ultrasonography as a useful adjunct in unclear or doubtful cases⁵⁴. Another study reported ultrasound to be superior to the surgeons' initial clinical impression, but they also found that 24% of the patients with normal scans had appendicitis at surgery; emphasizing the point that ultrasonography cannot be relied on to the exclusion of the surgeons careful and repeated examination¹¹⁰.

Ramachandra P. et al (1996)⁹⁰, too recommended ultrasonography as a useful adjunct in clinically equivocal cases.

In our study too, ultrasonography did not alter the clinical diagnosis in typical cases. It was found to provide helpful information in doubtful cases, and also identified complications with ease.

It would be appropriate to conclude however that ultrasonography is not superior to clinical assessment in "typical cases" of appendicitis and its main use is in

those patients with a doubtful clinical picture. Moreover ultrasonography must be used in association with the clinical picture and in this context serve to assist the surgeon's clinical judgement rather than to replace it.

Ultrasonography in Acute Cholecystitis:

The biliary system has been one of the primary areas of evaluation with ultrasound since 1980's. The gall bladder is easily visualized owing to its superficial position, un-obscured by bowel gas and inferior to the liver which serves as an excellent acoustic window⁸⁵. Hence it is the primary tool in the evaluation of gall bladder diseases^{10, 81}.

For better visualization of the gall bladder and intraluminal or wall abnormalities it is desirable to perform the ultrasound after an overnight fast whenever possible. Acute cholecystitis is demonstrated on ultrasound by tenderness at ultrasonic Murphy's point, gall bladder wall thickness more than 3.5 mm, intraluminal changes like echogenic bile and sludge, the stones may or may not be seen¹⁰⁸⁵. These findings were observed in our study also.

Ultrasound has been described as the better choice for investigating patients with right hypochondriac pain with diagnostic accuracies up to 95%⁵³. Accuracies up to 97.5% were obtained by Sarin N.K. et al (1990)⁹⁸ in the evaluation of gall bladder diseases, since gall stones could be easily identified in the fluid filled lumen. Addison N.V. and Finnan P.J. (1988)² obtained positive results in 83% of patients with acute cholecystitis.

In our study ultrasonography correctly diagnosed 75% of the cases with acute cholecystitis. In one case, it changed the clinical diagnosis from acute appendicitis to acute cholecystitis, which was confirmed surgically. Gall stones appeared as bright

intraluminal echogenic structures, with acoustic shadowing and changes with the position of the patient.

It can be thus concluded that ultrasonography can be used as the initial diagnostic investigation for acute cholecystitis; it is independent of biliary and hepatic function unlike cholecystography, cholangiography and scintigraphy. The lower rate of accuracy in our study could be probably attributed to the lesser number of cases studied.

Diagnostic accuracy clinical and ultrasonography:

In the present study the overall diagnostic accuracy for ultrasonography was 68.6%, compared to a clinical diagnostic accuracy of 81.18%. However, if only cases of acute appendicitis and acute cholecystitis were considered, the ultrasonographic accuracy rises to 75%. Failure to visualize an inflamed appendix was probably due to dilated bowel loops obstructing the field of study, in these cases. An overall accuracy of 64% was reported by Drew B. et al (1990)³⁴ with cases of acute appendicitis.

Worrels et al (1990)¹¹³ does not recommend the use of ultrasonography as the only screening test due to its low accuracy, but does recommend it in a diagnostic role after initial clinical screening for appendicitis.

In our study ultrasonography was of no help in cases of intestinal obstruction, helpful information was provided by plain-abdominal radiographs. However some studies have reported ultrasonography to accurately detect small bowel obstruction, early strangulation, carcinoma and incarcerated inguinal hernia⁵⁰. The assessment of the intestinal status was difficult due to the gas in bowel loops obstructing the path of ultrasonic waves.

Thus from our study we can conclude that ultrasonography to be the initial radiologic investigation for acute appendicitis, especially in clinically doubtful cases and also in acute cholecystitis.

COMPUTERISED TOMOGRAPHY SCAN

The advent of computed tomography has enabled the diagnostic power of the radiographic beam to advance greatly⁵. CT scan has established itself as a sensitive study for wide variety of diagnosis, including appendicitis, diverticulitis, intestinal ischemia, pancreatitis, intestinal obstruction and perforated viscus^{52,72}.

Rao P.M. et al (1997)⁹³ have reported "the arrow head sign" to be a common appearance on CT in acute appendicitis. This relates to intra-mural configuration of ileocaecal contrast media secondary to mural edema and does not refer to the appearance of the appendix itself. Accuracies upto 93% in visualizing the appendix have been reported by others⁷¹.

In our study, CT scan was called for only in three cases. In two cases it helped to diagnose the cause of acute abdomen. In one case it confirmed the clinical diagnosis of acute cholecystitis, where ultrasonography was normal. In the other case, it picked up a growth in the descending colon. However, CT scan was helpful to diagnose infected pancreatic necrosis in the third case.

The use of CT scan as an imaging tool in acute appendicitis is still under debate, and some authors have reported that its influence on clinical decision making is limited⁵⁵.

It would be thus apt to suggest this investigation where the diagnosis is difficult and where x-ray and ultrasonography are inconclusive. This is in agreement with many others^{10, 55, 72}. Even more compelling is the fact that CT scan involves the

exposure to a significant dose of radiation which would approximately be forty times the dose received in plain abdominal radiography and 100 times the dose in postero-anterior chest radiography⁵⁵.

OPERATIVE PROCEDURES PERFORMED:

1. Perforated duodenal ulcer: Closure of perforation with omental patch and peritoneal toilet.
2. Gastric perforation: Simple closure of perforation with peritoneal toilet.
3. Ileal Perforation: Simple closure of perforation with peritoneal drainage.
4. Appendicitis: Appendectomy.
5. Appendicular Perforation: Appendectomy with peritoneal drainage.
6. Intestinal Obstruction:
 - a) Adhesions: Adhesiolysis.
 - b) Hernias - Release of obstruction and herniorraphy. In cases of strangulated hernia, resection of non-viable bowel segment and end to end anastomosis
 - c) Malignancy resection and colostomy.
7. Necrotizing pancreatitis – Pancreatic necrosectomy and drainage.

SUMMARY

- The most common acute abdominal condition is acute appendicitis, followed by duodenal ulcer perforations.
- Males, in all age groups are, are more likely to suffer from acute abdominal conditions when compared to females.
- With rise in age, the proportion of peptic ulcer perforation in relation to acute appendicitis steadily increases.
- The ratios of men to women, in case of perforated peptic ulcers have declined, over the years.
- The duodenum is the most frequent anatomical site involved in perforations, followed by ileal, gastric and appendicular.
- Hollow viscus perforations and small bowel obstructions, regardless of the cause can be accurately diagnosed clinically.
- Sudden onset of epigastric pain, becoming generalized, continuous in nature associated with diffuse tenderness, guarding, abdominal rigidity along with obliteration of liver dullness are important clinical features of perforated peptic ulcers.
- A history of fever prior to onset of abdominal pain is one of the most useful clinical indicators to differentiate typhoid enteric perforations from other perforations.
- Bloody diarrhoea is an important early symptom in perforation is a feature of advanced stage of this disease. Migration of pain from umbilical region to right lower quadrant, along with localized guarding, tenderness, fever and tachycardia are important clinical features of acute appendicitis.

- Symptoms of colicky intermittent abdominal pain, associated with vomiting and constipation, along with clinical findings of guarding, abnormal bowel sounds and abdominal distension, are common features of intestinal obstruction.
- History of previous abdominal surgery is an important indicator of adhesions as the cause of small bowel obstruction.
- A past history of abdominal pain is commonly encountered in cases of cholecystitis, peptic ulcer perforations and acute appendicitis.
- Positive x-ray findings are found in 80% of the cases of acute abdomen.
- Pneumoperitoneum is present in 83.3% of gastro-intestinal tract perforations and along with the clinical findings of obliterated liver dullness is an ominous indicator of perforated hollow viscus.
- Higher the site of perforation more is the number of cases demonstrating pneumoperitoneum.
- Absence of pneumoperitoneum does not rule out hollow viscus perforation.
- Multiple air fluid levels and disproportionately dilated small bowel pattern on plain abdominal radiographs are important indicators of mechanical obstruction.
- Plain abdominal radiographs are indispensable in cases of hollow viscus perforation and intestinal obstructions, and therefore should be the initial radiologic investigation in clinically suspected cases.
- Acute appendicitis can be accurately diagnosed clinically in majority of the cases.
- Ultrasonography should be the initial radiologic investigation for acute cholecystitis and acute appendicitis. It is most useful in clinically doubtful cases.
- Computed tomography need not be used as a routine investigation in acute

abdominal conditions. It should be reserved for cases where the clinical diagnosis is difficult and when plain x-ray and ultrasound is inconclusive.

- The surgeon's clinical diagnostic accuracy is superior to the radiologic diagnostic accuracy.
- The clinical and radiological findings are complementary to each other.
- A good history and a proper clinical examination are the most important components in diagnosing patients with an acute abdomen.

CONCLUSION

The clinical diagnostic accuracy was superior to the diagnostic accuracy obtained by radiological investigations. The diagnosis of acute abdominal pain depends on optimal clinical assessment. There is no substitute for skill in interviewing patients and eliciting physical signs. While further imaging is usually not necessary for patients presenting with classic signs and symptoms of various acute abdominal pathologies, it is the atypical patients that require careful, appropriately tailored diagnostic imaging.

Plain abdominal radiographs were most useful in confirming the diagnosis of gastro-intestinal tract perforations and intestinal obstructions, regardless of the cause. Ultrasonography was useful in acute inflammatory conditions like acute appendicitis and acute cholecystitis, especially where the clinical picture was not 'stereo typed'. Computed tomography had a limited role as a routine imaging tool. To conclude there is no substitute for clinical diagnosis as it is superior to the diagnostic accuracy obtained by radiological investigations.

BIBLIOGRAPHY

- 1) Abu - Yousef MM, Bleicher JJ, Mather JW, Uradenetta LF, Franken EA Jr., Metacalf AM. 'High resolution sonography of acute appendicitis'. AJR; 163;11-14.
- 2) Addison NV and Finnan PJ. 1988. "Ultrasound and early cholecystectomy for acute gall bladder disease" BJS; 75:141-143.
- 3) Andrews NJ. 1981: "Presentation and outcome of strangulated external hernia in a distinct general hospital": BJS; 68: 329-332.
- 4) Archampong EV. 1976: "Typhoid ileal perforations, why such mortalities?" BJS 53 : 31 7.
- 5) Baker R.S. Nov.1993: "The abdominal plain film. What will be its role in the future? The alimentary tract?": Radiologic clinics of North Am.: Vol-31 No.6:1335-1344.
- 6) Bass KM, Bronwyn Jones, Gregory B. Blakely: 1998: "Current management of small bowel obstruction" Advances in surgery; 31:1-5.
- 7) Battle H.E. and Yeaton P 'Abdominal Pain'. Brandt LJ (Ed.), Clinical gastroenterology Vol-1, Philadelphia, Churchill Livingstone 1999; 210-214.
- 8) Beckley LS, Bates guide to physical examination and history taking. 7th Edition. New York, Lippincott Williams and Wilkins, 1999, 359-379.
- 9) Belding M. 1957: "Acute perforated diverticulitis of sigmoid colon with generalized peritonitis". Arch. Surg.: 74: 511-515.
- 10) Bhargava S. Dec. 1988: "Imaging in Acute abdomen in adults". IJS. 461-468.
- 11) Bhudaraja S.N. et al. 1976: "Acute intestinal obstruction in Pondicherry". IJS. ; 38: 3-

- 12) Blake Rand Lynn J. 1976 "Emergency abdominal surgery in the aged". BJS; 63:956-960.
- 13) Boey HJ. "Acute abdomen". Way LW (Ed) Current surgical diagnosis and treatment. 8th Edition, USA, Appleton and Lange 1988: 393-403.
- 14) Boey J. and Wong J. 1987: "Perforated duodenal ulcers". World. J. Surg.: 11. No.3. 319-324.
- 15) Bowesman C. Reduction of strangulated inguinal hernia Lancet (I) 1396-1397.
- 16) Brayton D. and Morris W.J. 1954: "Intussusception in adults". AJS. 32-42.
- 17) Brewer RJ et al. 1976: "Abdominal pain. An analysis of 1,000 consecutive cases in a university hospital emergency room". Am. J. Surg.; 131: 219-223.
- 18) Bussemaker JB and Lindeman. 1972: "Comparison of methods to determine viability of small intestine". Ann of Surg.: 176: 97-101.
- 19) Campell JPM and Gun AA. 1988: "Plain abdominal radiographs and acute abdominal pain". BJS; 75; 554-556.
- 20) Chauhan MK and Pande SK. 1982: Typhoid enteric perforation'. BJS; 69 -.173.
- 21) Christeen J. "Abdominal pain". Kumar D and Christen (Eds), Diagnostic guide to clinical gastroenterology, Newyork, Churchill Livingstone, 1996: 281-296.
- 22) Clain-A. "The acute abdomen". Hamilton Baileys Demonstration of Physical signs in clinical surgery. 17th Edition, ELBS, IOP Publishing Let. : 1986: 294-330.
- 23) Coleman MG and Maran BJ. : "Small bowel obstruction". Taylor L and Johnson CD (Edts.). Recent advances in surgery 22. Edinburg, Churchill Livingstone: 1999: 87-97.
- 24) Collier DSJ and Paine JA. 1985: "Non-steroidal anti-inflammatory drugs and peptic ulcer perforation". Gut. 26 : 359-363.

- 25) Cosgrove DO. "Ultrasound general principles". Grainer G and Allison D Eds. Diagnostic Radiology. A text book of Medical Imaging, 3rd Edition, Vol-I, Churchill Livingstone, 1997.
- 26) Cox MA, Gunn M.C., Eastman R.F. et al. 1993a. "The operative etiology and types of adhesions causing small bowel obstruction". Aust N.Z. J. Surg.: 63:848-852.
- 27) Dandapat MC et al. 1991: "Gastrointestinal perforations". IJS; 53; 189-93.
- 28) Das S.: "A manual on clinical surgery", 4th Edt, Calcutta. Published by Dr.S. Das Publications, 1996.
- 29) Desa LA et al. Peritonitis: 1983: "A study of factors contributing to mortality". IJS. Oct-Nov.: 593-604.
- 30) Dixon JM, Elton RA, Rainly JB. "Rectal examination in patients with pain in right lower quadrant of the abdomen". BMJ; 302; 386-388.
- 31) Doran FSA: 1961 "Observation of referred pain from the posterior abdominal wall and plexus". BJS; 49: 376.
- 32) Doran FSA: 1967 "The sites to which pain is referred from common bile duct in man and its implications. Theory of referred pain". BJS; 54: 599-605.
- 33) Dust BD, Quiroz F, Stewart JM: 1977: "Ultrasonic distinction of abscess from other intraabdominal fluid collections". Radiology; 125: 213-218.
- 34) Drew B, Truong S, Riesener et al. 1990: "The value of Sonography in diagnosis of appendicitis - a prospective study of 100 patients". Chirurg; 61(12): 880-6.
- 35) Dudley H. "French index of differential diagnosis". Indian Edition, Bombay. K.M. Varghese Company: 1985.
- 36) Dupuy DE, Costello P, and Ecker CP: 1992: "Spiral CT of the pancreas radiology"; 183: 815-818.

- 37) Federle MP and Jefferey RB, Haemoperitoneum: 1983: "Studied by computed tomography". Radiology; 148:187-192.
- 38) Fenyo G and Naka. 1982: "Acute abdominal disease in the elderly. Experience from 2 series in Stockholm". Am. J. Surg, June, 143: 751-753.
- 39) Field HL and Martin JB. Pain: "Pathophysiology and management". Fauci SA, Braunwald E, Isselbacher et al (Eds). Harrison's principles of internal medicine. Vol-1, 14th Edt. USA, McGraw Hill: 1998: 53-57.
- 40) Field S.: "The abdomen - The plain abdominal radiograph - the acute abdomen". Grainger R.G. and Allison D.J. (Eds). 3rd Edition, Vol-2. Diagnostic Radiology - a text book of medical imaging, New York, Churchill Livingstone: 1997: 883-884.
- 41) Ford RD, Passinult WJ, and Morse ME: 1994: "Diagnostic ultrasound for suspected appendicitis. Does the added cost produce a better outcome?" Am. J. Surg.: 60: 895.
- 42) Fukoya T, Howes DR, and Luce et al. 1992: "CT diagnoses of small bowel obstruction. Efficacy in 60 patients". Am. J. Roentgen; 158: 765-772.
- 43) Gallegos NC and Hobsley M. 1990: "Abdominal wall pain, an alternative diagnoses". BJS; 77:1167-1170.
- 44) Gammil SL, Nice CM. 1972: "Air fluid levels, their occurrence in normal patients and their role in analysis of ileus". Surgery; 71: 771-780.
- 45) Ganong FW. : "Review of medical physiology". 16th EDT, USA, Appleton and Lange; 1993:124-129.
- 46) Gary G. Ghahremans. 1993: "Radiologic evaluation of suspected gastrointestinal perforations". Radiol clinics North. Am.: Vol.31 -.1219-1233.
- 47) Gupta RL. : The acute abdomen in tropics and sub-tropics'. Recent advances in

- Surgery No.1, New Delhi, Jaypee Brothers; 1987:156-169.
- 48) Hendry W.S. Valerio D. and Kyle. J. (1972-1981): "Perforated peptic ulcer in North East Scotland". Part-I: Epidemiology.J.R. Coll Surg. Edin. : 2: 69-72.
- 49) Jibril JA, Redpath A. and Macintyre.1994: "Changing pattern of admission and operation for duodenal ulcer in Scotland". BJS; 81: 87-89.
- 50) Jacobs JM, Hill MC, and Steinberg WM: 1991: "Peptic ulcer disease CT evaluation". Radiology; 178: 745-748.
- 51) Jain BL and Mahindra Prasad. 1956: "Intestinal obstruction, a clinical study". IJS: 635-640.
- 52) Jeffrey RB, Federle MP, Wall S. 1983: "Value of computed tomography in detecting occult gastrointestinal perforation". J.Com put.Assist.Tomogr. 7:825-827.
- 53) Jeffrey RB, Jr., Laing EC and Townsend RR. 1988: "Acute appendicitis. Sonographic criteria based 250 cases". Radiology; 167: 327-329.
- 54) John H, Neff U, Kelmen M. 1993: "Appendicitis. Diagnosis Today. Clinical and ultrasonic deductions". World. J. Surg.: 17: 243-249.
- 55) Jones P.F. 2001: "Suspected acute appendicitis Trends in management over 30 years". BJS. : 88:1570-1577.
- 56) Jones PF, Krukouski ZH, Youngson GG.: "Emergency abdominal surgery". 3rd EDT, London, Champman and Hall Medical: 1998.
- 57) Jordan PH and Morrow C. 1988: "Perforated peptic ulcer". Surg. clinics. North Am., Vol-68, April No.2: 315-325.
- 58) Joseph J, John S et al: 1983: "Value of pneumoperitoneum in diagnosis of visceral perforation". Am. J. Surg.; 146: 830-833.
- 59) Kachroo R, Ahmd MN, Zorgar HV. 1984: "Peritonitis an analysis of 90 cases":

- IJS; April. 46 : 204-210.
- 60) Keefle EJ and Gagliards RA. 1973: "Significance of ileus in perforate viscus".
AJR; 117: 275-280.
- 61) Kohli V, Langer CJ, Goswamy HL. 1988: "Evaluation of prognostic factors in perforated peptic ulcer". IJS. : May-June: 184-186.
- 62) Ladha S. Dec.: Gastrointestinal perforations. IJS. : 500-507.
- 63) Laing EC.: "Diagnostic evaluation of patients with suspected cholecystitis". Surg. Clinics of North Am. 1984: 64(1): 3-22.
- 64) Lee DH, Lim JH, Koyt. 1990: "Sonographic detection of pneumoperitoneum in patients with acute abdomen". Am. J.R.; 154: 107-109.
- 65) Lee PWR. 1976: "The plain x-ray in the acute abdomen. A surgeon's evaluation". BJS; 73: 763-766.
- 66) Levine MS, Scheiner JD, Rubesin SE et al. 1997: "Diagnosis of pneumoperitoneum on supine abdominal radiographs". Am. J. Roentgenol; 168: 405-409.
- 67) Lim JH, Young TK, Dong HL et al. 1994: "Sonography of inflammatory Bowel disease. Findings and value in differential diagnosis". AJR. 163 : 343-347.
- 68) Mackay AJ and Me Ardle CS, 1982: "Cimetidine and perforated peptic ulcer". BJS: 69:319-320.
- 69) Mackay C, 1996: "Perforated peptic ulcer in West of Scotland". 1954-63. BMJ; 1: 701-705.
- 70) Maglinte DOT, Balthazaar, Kelvin FM et al. 1993: "Obstruction of small intestine. Accuracy and role of CT in diagnosis". Radiology; 188: 61-64.
- 71) Malone AJ, Wolf CR, Maimed AS et al. 1993: "Diagnosis of acute appendicitis. Value of unenhanced CT". AJR; 160: 763-766.

- 72) Martin RF and Rossi RL: "Abdominal emergencies. Has anything changed?"
Surg. Clinic. North. Am., 1997 Dec.: 77(6): 1227-1264.
- 73) Meiser G. 1993: "Current standards in gastrointestinal ultrasound diagnosis - A surgical review". IJ gastroenterol; 2: 49-55.
- 74) Meyers, MA et al. 1987: "The peritoneal ligaments and mesenteries -pathways of intraabdominal spread of disease". Radiology; 163: 593.
- 75) Meyers, MA. 1970: "The spread and localization of acute intraperitoneal effusions". Radiology; 95: 547-554.
- 76) MiddletonWD, DoddsWJ, LawsonTLetal. 1988: "Renalcalculi sensitivity for detection with US. Radiology"; 167: 239-244.
- 77) Miller RE and Nelson SW: 1971: "The roentgenologic demonstration of tiny amounts of free intraperitoneal gas. Experimental and clinical studies". Am.J. Roentgenol; 112; 574-585.
- 78) Mindelzun R.E. and Mccort J.J. "Acute Abdomen". Margulis A.R. and Burhene H.J. (Eds). Alimentary Tract Radiology Vol-1, 4th Edn. Baltimore, CV Mosby Company, 1989: 291-362.
- 79) Mirris SE, Young JW, Keramati B et al. 1986: "Plain film evaluation of patients with abdominal pain. Are 3 radiographs necessary?" Am. J. Roentgenol; 147: 501-503.
- 80) Mishra S.B. et al. 1982: "Surgical management of acute perforated duodenal ulcer", IJS Oct-Nov; 705-707.
- 81) MittelsteadtCA. The biliary system'. Abdominal ultrasound. Eds. Hurley RA, Churchill Livingstone Press, New York, 1987: 81-85.
- 82) Nair S.K. etal. 1981: "Non-traumatic intestinal perforations": IJS, May: 371-377.
- 83) Newman PC and Rozycki CS.: The history of ultrasound. Surgeon performed

- ultrasound use in clinical practice'. Surg. Clinic. North. Am., Apr. 1998: Vol 78(2): 179-197.
- 84) Ogata M., James RM. 1996: "Prospective evaluation of abdominal sonography for diagnosis of bowel obstruction". Annals of Surgery; 223: 237-241.
- 85) Palmer PES: "Manual of diagnostic ultrasound, WHO, Geneva in collaboration with World Federation for ultrasound in Medicine and Biology". 1995: 141-148.
- 86) Paterson - Brown S and Vipond MN: 1990: "Modern aids to clinical decision making in the acute abdomen". BJS; 77:13-18.
- 87) Paterson Brown. The peritoneum, the mesentery, the greater omentum and the acute abdomen, Burnand KG and Young AE (Eds.). The New . Aird's Comparison in surgical studies, 2nd Ed., Great Britain, Churchill Livingstone, 1998: 754-755.
- 88) Pujari B. "Necrotising enteritis". Roshlal Lal Gupta (Ed.). Recent advances in surgery No.1, New Delhi, Jaypee Brothers, 1987: 170-180.
- 89) Puyleart JBCM: 1986: "Acute appendicitis: US evaluation using graded compression". Radiology; 158: 355-360.
- 90) Ramachandran P, Sivit CJ, Newman KD et al. 1996: "Ultrasonography as an adjunct in the diagnosis of acute appendicitis. A 4 year experience". J. Pead.Surg; 31:164.
- 91) Ramesh C. Bhartetal. 1996: "Immediate definitive surgery in perforated duodenal ulcer". IJS, Sept. - Oct.: 275-279.
- 92) Rao DCM, Mathur JC, Ramu D, Anand M. 1984: "Castro intestinal tract perforations. A study of 46 cases". IJS. Feb; 46: 94-96.
- 93) Rao PM, Wittenberg J, McDowell Rk et al 1997: "Appendicitis: Use of Arrowhead sign for diagnosis at CT". Radiology; 202: 363-366.

- 94) Rice RP, Thompson WN, and Gedgaudas RK.: "The diagnosis and significance of extraluminal gas in the abdomen". Radiol Clinics. North Amm. : 1982: Vol-20-819-837.
- 95) Russell RCG, Williams SN, Bulstrode CJK, Bailey and Love's. 2000: "Short practice of surgery", 23rd EDT, Londin, Arnold, a member of Hodder headline grou.
- 96) Sabiston D.C. Jr. and Lyerly K.M. Text book of Surgery. The biologic basis of modern surgical practice. 15th Edition, Harcourt Asia PTE Ltd., W.B. Saunders Company, 1997.
- 97) Sakai L, Daake J, Kaminski DL 1981: "Acute perforation of sigmoid diverticulitis". Am. J. Surg.; 142: 712-716.
- 98) Sarin NK, Dhuman DS, Kaushik NK etal. 1990: "Role of ultrasonography in gall bladder diseases". Ind. J. Radiol imaging; 44:109-111.
- 99) Schwerk WB et al. 1990 : "Acute and perforated appendicitis. Current experience with ultrasound aided diagnosis". World. J. Surg.; 14:271-276.
- 100) Schwartz SI, Shires GT, Spencer FC. "Principles of Surgery". 7th Edt. USA, Me Graw Hill Inc. 1999.
- 101) Seidel M.H. et al. "Mosby's guide to physical examination". 3rd Edition, Mosby Publications, 1995: 471 -503.
- 102) Sharma L et al. 1991: "Generalized peritonitis in India. The tropical spectrum". IJS. May 21 (3); 272-277.
- 103) Silen W: "Copes early diagnosis of acute abdomen", 20th EDT, New York, Oxford University Press, 2000.
- 104) Simeone JF, Novelline RA, Ferucci JT et al. 1985: "Comparison of sonography and plain films in evaluation of the acute abdomen". AJR; 144: 49-52.

- 105) Sinnatumby C.S. Last's anatomy regional and applied, 10th Edt, Edenbergh, Churchill Livingstone, 1999, 282-232.
- 106) Smerud MJ, Johnsom CD, Sterens DH1990: "Diagnosis of bowel infarction a comparison of plain films and CT in 23 cases": AJR; 154; 99-103.
- 107) Stainland JR, Ditchburn J, De Dombal FT.: 1972: "Clinical presentation of acute abdomen study of 600 patients". BMJ; 3: 393-398.
- 108) Temple CL, Shirley A, Temple JW. 1995: "Natural history of appendicitis adults. A prospective study. Annals of Surgery"; 221: 278-281.
- 109) Vaidhyathan S, 1986: "Surgical management of typhoid ileal perforation". IJS Perforation. IJS. Sept: 335-341.
- 110) Wade DS, Marrow SE et al: 1993: "Accuracy of ultrasound in diagnosis of acute appendicitis, compared with the surgeons clinical impression". Arch. Surg.; 128: 1039.
- 111) Williams PL, Warwick Roger, Dyson N, Bannister LH. Gray's anatomy. 37th Edt. UK, Churchill Livingstone: 1989: 1333-1344.
- 112) Wills JS: 1992: "Closed loop and strangulating obstruction of small intestine: a new twist": Radiology; 185: 769-785.
- 113) Worels JA, Drolshagen LF, Kelly TC et al. 1990: "Graded compression ultrasonography in diagnosis of appendicitis - a comparison of diagnostic criteria".]. Ultrasound. Med.: 9(3): 145-150.
- 114) Zinner L.W., Schwartz, Ellis H.: Maingots abdominal operation. 10th Edition, USA, Appleton and Lange: 1997.

PROFORMA

Case No.: I.P. No.: Ward:
Name: Age: Sex:
Occupation : Address :
Date of Admission : Date of operation :
Date of Discharge / Death:

1. COMPLAINTS/ PRESENTING SYMPTOMS:

A. Pain Abdomen

- a) Duration
- b) Type of pain - Colicky / Steady / Intermittent / Sharp / Dull
- c) Mode of onset: Sudden / gradual
- d) Site of pain at onset: d) Site now:
- e) Radiation:
- f) Aggravating / Relieving factors:
- g) Others

B) VOMITING: a) Frequency

- Yes / No b) Relation to pain
- c) Vomits: Bilious / Blood / Fecal / Clear/ Otherwise
- d) Amount:

C) FEVER: a) Duration

- Yes / No b) Degree
- c) Type: Remittent/ Continuous/ Intermittent
- d) Chills /Rigors
- e) Prior to onset of pain f) After onset of pain

D) Distension of Abdomen: Yes/No

E) Bowel Habits: Normal
 Diarrhoea
 Constipation
 Melena/ Blood in stool
 Others

F) Urinary Symptoms: Frequency
 Dysuria
 Heamaturia Others

G) Other Complaints (if any)

H) Passed Flatus: Yes / No

2) PAST HISTORY

1. Pain Abdomen Yes/ No
2. Acid Peptic Disease Yes / No
3. Previous Abd / Pelvic Surgery Yes / No
4. Drug History:
5. Others:

3) PERSONAL HISTORY

1. Diet : Mixed / Veg
2. Appetite : Good / Impaired
3. Habits : Smoker : Yes/No
 Alcohol Consumer : Yes / No

4) MENESTRUAL HISTORY: LMP
 Cycle
 Vaginal Discharge YES / NO
 Others

5) FAMILY HISTORY:

6) EXAMINATION:

7) GENERAL PHYSICAL EXAMINATION:

- a) Vital Signs: Pulse: B.P.
 Temp: Respiratory Rate:
- b) Built + nutrition: Dehydration: Yes / No
- c) Shock: Yes / No
- d) Pallor / Cyanosis / Jaundice / Pedal Edema / Lymphadenopathy
- e) Attitude in bed: Calm / Restless

8) EXAMINATION OF ABDOMEN:

- A) Inspection: Shape

 Umbilicus

 Skin: Colour Changes

 Movement with respiration: Decreased/ Increased/Normal

 Visible Pulsations / Visible Peristalsis

 Distension

 Hernia Orifices

 External Genitalia

 Scars

 Others

B) Palpation:

- a) Site of tenderness i) Localized ii) Diffuse
- b) Guarding : Yes / No
- c) Rigidity : Yes / No
- d) Rebound Tenderness : Yes / No
- e) Site of mass if any :

C) Percussion

a) Obliteration of liver dullness Yes / No

b) Evidence of free fluid in peritoneal cavity Yes / No

D) Auscultation:

Bowel Sounds: Present/Absent /Tingling/ Fast/Sluggish

Vascular Sounds

9) Digital Rectal Examination

10) Per Vaginal Examination

11) Other Systems

a) Cardiovascular

b) Respiratory

c) Central Nervous System

12) Four Quadrant Aspiration: Positive / Negative

Bilious / Blood / Fecal / Purulent Others

13) Investigations:

a) Routine : Hb

Blood TC

BT/CT

Bid Group Sug

Urine: Sug : Aib: Micro :

Others :

14) Radiological Investigations:

a) Plain X-ray Abdomen: Erect/Supine/Lateral

Decubitus

Findings:

b) Ultrasound abdomen / pelvis findings

c) Computerized Tomography Scan:

- 15) Clinical Diagnosis
- 16) Radiologic Diagnosis
- 17) Operative Findings
- 18) Operative Diagnosis
- 19) Complications

SAMPLE INFORMED CONSENT FORM

TITLE OF PROJECT : “DIAGNOSTIC ACCURACY OF
RADIOLOGICAL
INVESTIGATIONS IN ACUTE
ABDOMEN”

GUIDE : Prof Dr.M.B.PATIL

P.G.STUDENT : Dr.S,D,SHIGIHALLI .

PURPOSE OF RESEARCH :

I have been informed that this study will analyze the clinical study and management of acute abdomen. This study will thus help the investigator better understand for the management of above condition.

PROCEDURE :

I understand that acute abdomen is a serious condition. I am aware that in addition to the ordinary care received, I will be examined and asked a series of questions by the investigator. I have been asked to undergo the necessary investigations, which would help the investigator to give the appropriate treatment.

RISK AND DISCOMFORTS

I understand that I may experience some pain and discomfort during the examination or during my treatment. This mainly the result of my condition and the procedures of this study are not expected to exaggerate these feelings, which are associated with the usual course of treatment.

BENEFITS

I understand that my participation in the study will have no direct benefit to me other than potential benefit of the treatment.

CONFIDENTIALITY

I understand the medical information produced by this study will become part of my hospital record and will be subjected to the confidentiality. Information of sensitive personal nature will not be part of the medical record, but will be stored in the investigator’s research file. If the data are used for publication in the medical literature or for the teaching purpose, no names will be used and other identifiers, such as photographs will be used only with my special written permission. I understand that I may see the photograph before giving the permission.

REQUEST FOR MORE INFORMATION

I understand that I may ask more questions about the study at any time, Dr.S.D.Shigihalli, at the Department of General Surgery is available to answer my questions or concerns. I understand that I will be informed of any significant new findings discovered during the course of the study, which might influence my continued participation. A copy of this consent form will be given to me to keep for careful reading.

REFUSAL FOR WITHDRAWAL OF PARTICIPATION

I understand that my participation is voluntary and that I may refuse to participate or may withdraw consent and discontinued participation in the study as any time without prejudice. I also understand that Dr.S.D.Shigihalli, may terminate my participation in the study at any time after he has explained the reasons for doing so.

INJURY STATEMENT

I understand that in the unlikely event of injury to me resulting directly from my participation in this study, if such injury were reported promptly then appropriate treatment would be available to me. But no further compensation would be provided by the hospital. I understand that by my agreements to participate in this study and not waiving any of my legal rights.

I have explained to _____ the purpose of the research, the procedures required and the possible risks to the best of my ability.

Dr.S,D,SHIGIHALLI

(Investigator)

Date

I confirm that Dr. Dr.S,D,SHIGIHALLI has explained to me the purpose of research, the study procedure, that I will undergo and the possible discomforts as well as benefits that I may experience in my own language. I have been explained all the above in detail in my own language and I understand the same. Therefore I agree to give consent to participate as a subject in this research project.

(Participant)

Date

(Witness to signature)

Date

KEY TO MASTER CHART

A	Absent	AFLF	Fluid in flank
AA	Acute appendicitis	FQA	Four Quadrant Aspiration
AD	Abdominal distension	FF	Free Fluid
AFD	Air fluid below diaphragm	FS	Fluid around Stomach
AC *	Acute cholecystitis	FLP	Fluid in Pelvis
AP	Appendicular perforation	G	Guarding
B	Bilious	GUD1	Gas under one dome of Diaphragm
BH	Bowel habits	GUD2	Gas under both domes of Diaphragm
BS	Bowel sounds	GA	Ground glass appearance
FP	Fever prior to onset of pain	GUP	Gastric Ulcer Perforation
C	Continuous	HG	Hypogastrium HR Hours
CO	Constipation	HVP	Hollow Viscus Perforation
CL	Convex Lumbar scoliosis	I	Intermittent
Back	Pain radially to the back	IP No.	Inpatient Number
D	Diffuse	LI	Local Ileus
DH	Diarrhoea	LIF	Left iliac fossa
DOA	Date of admission	LH	Left hypochondrium
Dehyd	Dehydration	LL	Left Lumbar
DRE	Digital Rectal Examination	LBO	Large Bowel Obstruction
DSB	Dilated Small Bowel	M	Male
DUP	Duodenal Ulcer Perforation	ME	Melena/ Blood In stool
OOP	Duration of Pain	MFL	Multiple air-fluid levels in bowel
E	Epigastrium	MD	Meckel's Diverticulitis
EF	Enteric Fever	N	Normal
F	Female	NE	Necrotizing Enteritis
FE	Faecal	OLD	Obliteration of Liver Dullness
FB	Fluid around Bowel		
FV	Fever		
FL	Fluid around liver		

OT	Others	Sl.No.	Serial Number
P	Acute Pancreatitis	SPP	Site of Pain at Presentation to Hospital
PF	Fever after onset of pain	SOT	Site of Tenderness
PO	Obliteration of Psoas Shadow	SOM	Site of Mass
PHP	Past Hi story of Pain	Shock	Shock
PHS	Past History of Surgery	SB	String of beads appearance
PR	Pulse Rate	T	Tender
PI	Paralytic Ileus	TOP	Type of Pain
PUP	Peptic Ulcer Perforation	TEM	Temperature
PU	Pus	IO	Intestinal Obstruction
RL	Right Lumbar Region	IP	Ileal Perforation
R	Raised	APD	Acid Peptic Disease
Rl	Rigidity	UC	Ureteric Colic
Ra/Sh	Radiation / Shift of pain	U	Umbilical Region
RG	Higglers Double Wall Sign	V	Vomiting
RIF	Right Iliac Fossa	VP	Visible Peristalsis
RIL	Right Inguinal Region	+	Positive / Present
RH	Right Hypochondrium	-	Negative
S	Sluggish	++	Hyperactive bowel sound
SOP	Site of Onset of Pain		

MASTER CHART

					SYMPTOMS											SIGNS																
										FV			TOP																			
SL NO	NAME	IP NO	AGE	SEX	DOP	SOP	SPP	Ra/SH	V	FP	PF	BH	C	I	PHP	PHS	AD	SOT	G	RI	OLD	FF	BS	DRE	PR	TEM	SOM	FQA	VP	SHOCK	DEHYDR	
1	SHRISHAIL	11104	34 Y	M	36 HR	U	RIF	SH	-	-	-	N	+	-	-	-	-	RIF	+	-	-	-	N	-	N	N	-	-	-	-	-	
2	PRAKASH	14547	24 y	M	48 HR	U	RIF	+	+	+	N	+	-	+	-	-	RIF	+	-	-	-	N	T	R	R	-	-	-	-	-		
3	RAMANAGOUDA	12230	15 Y	M	36 HR	U	D	-	+	-	+	CO	+	-	-	-	+	D	+	+	+	+	A	-	R	R	-	-	-	-	+	
4	GEETA	17003	17 Y	F	42 HR	U	RIF	SH	+	-	-	N	-	-	-	-	RIF	-	-	-	-	N	-	R	R	-	-	-	-	-		
5	SOMAPPA	14535	50	M	48 HR	E,RH	D	-	-	-	+	CO	+	-	+	-	+	D	+	+	+	+	A	-	R	N	-	ND	-	-	+	
6	AMMASEWWA	11783	55 Y	F	72 HR	E,RH	D	-	+	-	-	CO	-	-	-	-	+	D	+	+	+	+	A	-	R	N	-	B	-	-	+	
7	SHARANAMMA	18898	32 Y	F	72 HR	E,RH	D	-	+	-	+	CO	-	-	-	-	+	D	+	+	+	+	A	T	R	R	-	-	-	+	+	
8	SUBHASH	12520	25 Y	M	48 HR	E	D	-	+	-	+	N	-	-	+	-	+	D	+	+	+	+	A	-	R	R	-	B	-	-	+	
9	ESHWAR	15212	32 Y	M	72 HR	RH	D	SH	+	+	-	DH	+	-	-	+	+	D	+	-	-	+	N	T	R	R	-	-	-	+	+	
10	BHOGAPPA	10414	45 Y	M	36 HR	E U	D	SH	+	-	-	N	-	-	+	-	+	D	+	-	+	+	A	-	N	N	-	B	-	-	+	
11	BABASAHEB	13119	49 Y	M	42 HR	E D	D	-	-	-	-	CO	-	-	+	+	+	D	+	+	+	+	A	-	N	N	-	-	-	-	+	
12	NINGANNA	16184	30 Y	M	24 HR	E	D	-	+	-	-	N	-	-	+	-	+	E	+	-	+	-	N	-	N	N	-	-	-	-	-	
13	SHANKREPPA	17928	38 Y	M	32 HR	E RH	D	SH	-	-	-	CO	-	-	+	-	+	D	+	+	+	+	A	-	R	R	-	B	-	-	+	
14	SOPHISAB	18254	19 Y	M	18 HR	E	D	-	-	-	-	N	-	-	-	-	+	D	+	+	+	+	N	-	N	N	-	-	-	-	-	
15	SAIRABANU	19435	28 Y	F	72 HR	E D	D	SH	-	-	+	CO	+	-	+	+	+	D	+	-	+	+	A	-	R	R	-	-	-	-	+	
16	PARASU	15229	29 Y	M	48 HR	E	E	-	+	-	-	N	-	-	+	-	+	D	+	+	+	+	A	T	R	N	-	-	-	-	+	
17	GURUNATH	14443	22 Y	M	72 HR	U RIF	D	-	-	+	-	DH	+	-	+	-	+	RIF	+	+	-	+	N	T	R	R	-	-	-	-	+	
18	KULUSMA	15169	35 Y	F	48 HR	U	U	-	+	-	-	CO	-	-	-	+	+	U	-	-	-	-	++	-	N	N	-	-	-	-	-	
19	NAGANNA	14847	55 Y	M	72 HR	u	u	-	+	-	-	CO	-	-	-	+	+	D	+	-	-	-	++	-	R	R	-	-	-	-	+	
20	RAHUL	14182	44 Y	M	48 HR	RIF	U	-	+	-	-	CO	-	-	-	-	+	D	-	-	-	-	N	-	N	N	-	-	-	-	+	
21	RAMSINGH	16516	25 Y	M	36 HR	U	D	-	+	-	-	CO	-	-	-	-	+	D	-	-	-	-	+	-	R	R	-	-	-	-	+	
22	NIRMALA	14225	30 Y	F	24 HR	E,RH	E,RH	+SH	-	-	+	N	-	-	+	-	-	RH	+	-	-	-	N	-	R	R	-	-	-	-	-	
23	SAVITRI	14568	48 Y	F	30 HR	E,RH	E,RH	-	+	-	+	N	-	-	+	-	-	RH	+	-	-	-	N	-	R	R	-	-	-	-	-	
24	ANUPAMA	14950	47 Y	F	20 HR	E	E,RH	-	-	-	-	DH	-	-	+	-	-	RH	+	-	-	-	N	-	R	R	-	-	-	-	-	
25	SURESH	15347	28 Y	M	12 HR	RIF	RIF	-	-	-	-	CO	-	-	+	+	-	RIF	-	-	-	-	++	-	N	N	-	-	-	-	-	
26	ROMA	10658	19 Y	F	24 HR	U,RIF	RIF	+SH	-	-	-	N	-	-	-	-	-	RIF	+	-	-	-	+	-	R	R	-	-	-	-	+	
27	GANGUBAI	16145	57 Y	F	18 HR	RIF	RIF	-	+	-	+	N	-	-	+	-	-	RIF	+	-	-	+	N	-	R	R	-	-	-	-	+	
28	BHIMAPPA	16704	58 Y	M	36 HR	U,RIF	RIF	SH	-	-	+	++	+	-	+	-	-	RIF	+	-	-	-	++	-	R	R	-	-	-	-	+	
29	BASAPPA	17248	55 Y	M	36 HR	E	D	-	+	-	+	CO	+	-	+	+	+	D	+	+	+	+	-	R	R	-	-	-	-	-	-	
30	BARMU	14762	49 Y	M	42 HR	E,RH	D	SH	-	-	-	CO	-	-	-	+	+	D	+	+	+	+	-	-	R	R	-	-	-	+	++	
31	SIDDAPPA	15281	35 Y	M	70 HR	E,RH	D	-	-	-	-	CO	-	-	-	+	+	D	+	+	+	+	-	-	R	R	-	-	-	+	+	
32	MEHABUBSAB	12837	38 Y	M	48 HR	E,RH	D	-	-	-	-	CO	-	-	-	+	+	D	+	+	+	+	-	-	N	N	-	-	-	+	+	
33	SUNANDA	10629	39 Y	F	38 HR	E,RH	D	-	-	-	-	CO	-	-	-	+	+	D	+	+	+	+	-	-	R	R	+	-	-	+	+	
34	BALABHIM	12396	13 Y	M	24 HR	RIF	RIF	SH	-	-	-	DH	-	-	+	+	-	D	+	-	-	-	N	-	R	R	-	-	-	-	+	
35	SHIVANAND	14985	22 Y	M	36 HR	RIF	RIF	SH	-	-	-	N	-	-	+	+	-	RIF	-	+	-	-	N	-	R	R	-	-	-	-	+	
36	SHABBIR	16784	32 Y	M	48 HR	E,D	D	SH	+	-	-	CO	-	-	-	-	+	D	+	+	+	+	N	-	R	R	-	-	-	+	+	
37	SUNITHA	10571	37 Y	F	36 HR	RIF	RIF	-	-	-	-	N	-	-	+	-	-	RIF	-	-	-	-	N	-	R	R	-	-	-	-	-	
38	AMITH	8930	11 Y	M	24HR	U,RIF	RIF	SH	-	-	-	N	+	-	+	+	-	RIF	-	-	-	-	N	-	N	N	-	-	-	-	-	
39	SOMA	6575	40 Y	F	48HR	RIF	RIF	-	-	-	-	DH	+	-	+	+	-	RIF	-	-	-	-	N	-	R	R	-	-	-	-	+	
40	BASANAGODA	5960	40 Y	M	36HR	RIF	RIF	-	-	-	-	N	-	-	+	-	-	RIF	-	-	-	-	N	-	N	N	-	-	-	-	+	
41	HASEENABAI	16938	42 Y	F	58HR	U	D	-	-	-	-	CO	-	-	-	-	+	D	+	+	+	+	-	-	N	N	-	-	-	+	+	
42	BASAPPA	7249	29 Y	M	24HR	U	D	-	-	-	+	CO	-	-	+	-	+	D	+	+	+	+	-	-	R	R	-	B	-	-	+	
43	RAJARAM	7014	36 Y	M	48HR	E,D	U,D	-	-	-	+	CO	-	-	+	+	+	D	+	+	+	+	-	T	R	R	-	-	-	-	+	
44	ANAND	8322	20 Y	M	12HR	RIF	RIF	-	-	-	-	N	-	-	+	+	-	RIF	-	-	-	-	N	-	R	R	-	P	-	+	-	
45	VASUMATHI	6629	40 Y	F	24HR	U	RIF	SH	-	-	-	N	+	-	-	+	-	RIF	-	-	-	-	+	N	-	N	N	-	-	-	-	-
46	AMEENSAB	6542	40 Y	M	72HR	E,D	D	-	+	-	-	CO	+	-	-	+	+	D	+	+	+	+	A	-	N	N	-	-	-	+	+	
47	BHIMAWWA	5298	59 Y	F	48HR	RIF	RIF	-	+	+	-	N	-	-	+	-	-	RIF	-	-	-	-	N	T	R	R	-	-	-	-	+	

48	KALLAPPA	9847	58 Y	M	24HR	U	D,	-	+	+	-	CO	-	-	+	+	+	D	+	+	+	A	T	R	R	-	F	-	+	+	
49	SHANTAYYA	9827	40 Y	M	48HR	E	D	-	+	-	-	CO	-	-	-	+	+	D	+	+	+	A	-	N	N	-	-	-	-	+	
50	BHIMSHA	8430	55 Y	M	72HR	E,LH	D	-	+	-	-	CO	-	-	-	-	+	D	+	+	+	A	-	N	N	-	-	-	-	+	
51	GOURAWWA	15833	28 Y	F	48HR	RH	RH	-	+	-	-	N	-	-	-	-	RH	+	+	-	-	N	-	R	R	+	-	-	-	+	
52	SUDARANI	13463	26 Y	F	56HR	RH	RH	SH	+	-	-	N	+	-	-	-	RH	+	-	-	-	N	-	R	R	-	-	-	-	+	
53	REVAPPA	7680	40 Y	M	36HR	U	D	SH	+	-	+	CO	+	-	+	-	+	D	+	+	+	+	A	-	N	N	-	-	-	+	+
54	MAHANTESH	16710	40 Y	M	26HR	U,E	U,D	-	+	-	+	CO	+	-	+	-	+	U	+	+	-	A	-	N	N	-	-	+	-	-	
55	MAYAWWA	17225	35 Y	F	30HR	E	D	-	+	-	-	CO	+	-	+	+	+	D	+	-	-	++	-	R	R	-	-	-	-	+	
56	LALITHA	11786	2 Y	F	24HR	E,U	D	-	+	-	-	CO	+	-	+	+	+	D	+	-	-	+	-	N	N	-	-	-	-	+	
57	SIDDAPPA	14906	51 Y	M	72HR	E	E,RH	-	+	-	-	CO	+	-	-	-	+	E,D	+	-	-	++	T	N	N	-	-	+	-	-	
58	GURUNATH	18765	18 Y	M	48HR	E	D	-	+	-	-	N	+	-	-	-	+	D	+	+	+	+	A	T	N	N	-	B	-	-	+
59	NEELAMMA	2671	58 Y	F	48HR	E,RI	D	-	+	-	-	CO	+	-	-	+	+	D	+	+	+	A	-	R	R	-	-	-	+	+	
60	MAHADEVAPPA	7072	38 Y	M	48HR	RIF	RIF	-	+	-	-	N	+	-	-	-	-	RIF	+	-	-	-	N	-	R	R	-	-	-	-	+
61	MUZAMBIL	3798	15 Y	M	36HR	RIF	RIF	-	+	-	-	N	+	-	-	+	-	RIF	+	-	-	-	N	-	R	R	-	-	-	-	-
62	SHIVAPRASAD	3909	55 Y	M	24HR	U,E	U	R	+	-	-	N	+	-	-	-	+	U	+	-	-	A	-	N	N	-	-	-	-	+	
63	SHANTAWWA	14951	59 Y	F	26HR	RH	RH	-	+	+	-	N	+	-	-	-	-	RH	+	-	-	-	N	-	R	R	-	-	-	-	+
64	HUVALINGAWWA	15660	55 Y	F	72HR	RH	RH	-	+	+	+	N	-	-	-	-	-	RH	+	-	-	-	N	-	R	R	-	-	-	-	+
65	ALISAB	4466	50 Y	M	42HR	E	D	-	+	+	-	CO	-	-	+	-	+	D	+	+	+	+	A	-	N	N	-	-	-	-	+
66	MALLAPPA	3100	38 Y	M	42HR	RIF	RIF	-	+	+	-	N	-	-	+	+	-	RIF	-	-	-	-	N	-	R	R	-	-	-	-	-
67	SANGEETA	16015	21 Y	F	12HR	RIF	RIF	-	+	-	-	N	-	-	-	+	-	RIF	+	-	-	-	N	T	N	N	-	-	-	-	-
68	SHESHAPPA	5521	41 Y	M	36HR	E,U	D	-	+	-	-	CO	+	-	+	-	+	D	+	+	+	+	A	=	N	N	-	B	-	+	+
69	SUREKHA	1583	10 Y	F	36HR	U	D	SH	+	-	-	CO	-	-	+	-	+	D	+	+	+	+	A	-	R	R	-	F	-	-	+
70	PARASAPPA	3974	57 Y	M	24HR	E,U	D	SH	+	-	-	CO	-	-	+	-	+	D	+	+	+	+	A	-	N	N	-	B	-	-	+
71	NABIRASUL	17788	25 Y	M	36HR	E	D	-	+	-	-	CO	-	-	+	+	-	D	-	-	-	-	N	-	N	N	+	-	-	-	+
72	BALAPPA	15359	48 Y	M	72HR	RIF	RIF	-	+	-	-	N	-	-	-	+	+	RIF	-	-	-	-	N	-	N	N	-	-	-	-	+
73	NEELAWWA	2220	16 Y	F	48HR	RIF	RIF	-	+	-	-	N	-	-	-	+	-	RIF	+	-	-	-	N	-	R	R	-	-	-	-	-
74	SANTOSH	4179	24 Y	M	48HR	RIF	U,RIF	-	+	-	-	N	+	-	-	-	-	RI,U	+	-	-	-	N	-	R	R	-	-	-	-	-
75	MALLIKARJUN	5349	22 Y	M	36HR	U	RIF	-	+	-	-	N	+	-	-	-	-	RIF	+	-	-	-	N	-	R	R	-	-	-	-	-
76	NIRMALA	6557	42 Y	F	30HR	U	RIF	-	+	-	-	N	+	-	+	-	-	RIF	+	-	-	-	N	-	R	R	-	-	-	-	+
77	NAGESH	6857	22 Y	M	48HR	U	RIF	SH	+	-	+	N	+	-	+	-	-	RIF	+	-	-	-	N	-	R	R	-	-	-	-	-
78	AYYAPPA	8849	28 Y	M	46HR	U,RIF	RIF	-	+	-	-	N	+	-	+	-	-	RIF	+	-	-	-	N	-	N	N	-	-	-	-	-
79	BANDENAWAZ	7752	33 Y	M	42HR	U	RIF	-	+	-	-	N	-	-	+	-	-	RIF	+	-	-	-	N	-	N	N	-	-	-	-	+
80	M A PATIL	4976	39 Y	M	48HR	U,E	RIF	-	+	-	-	N	-	-	+	-	-	RIF	+	-	-	-	N	-	R	R	-	-	-	-	-
81	SHANKAR	680	35 Y	M	28HR	E,U	D	-	+	-	-	N	-	-	+	-	+	D	+	+	+	+	A	-	N	N	-	B	-	+	+
82	AZARUDDIN	1397	22 Y	M	48HR	E	D	-	+	-	+	CO	-	-	+	-	+	D	+	+	+	+	A	-	R	R	-	-	-	+	+
83	BABU	1058	30 Y	M	24HR	E	D	-	+	-	+	CO	-	-	+	-	+	D	+	+	+	+	A	-	N	N	-	-	-	-	+
84	BASAMMA	1989	48 Y	F	36HR	U	D	-	+	-	+	CO	-	-	-	-	+	D	+	+	+	+	A	-	N	N	-	B	-	-	+
85	IBRAHIM	770	25 Y	M	36HR	RIF	RIF	-	+	-	-	N	-	-	-	-	-	RIF	+	-	-	-	N	-	N	N	-	-	-	-	+
86	INDIRA	8318	20 Y	F	48HR	U	RIF	SH	+	-	-	N	-	-	-	-	-	RIF	+	-	-	-	N	-	R	R	-	-	-	-	-
87	SAVITRI	4320	32 Y	F	12HR	U	RIF	-	+	-	-	N	-	-	-	-	-	RIF	+	-	+	-	N	-	R	R	-	-	-	-	-
88	MANTESH	7539	22 Y	M	36HR	E	D	-	+	-	-	CO	+	-	-	-	+	D	+	-	-	++	-	N	N	-	-	+	-	-	
89	TARABAI	3748	40 Y	F	48HR	U,E	RIF	-	+	-	-	N	+	-	-	-	-	RH	+	-	-	-	N	-	R	R	-	-	-	-	+
90	CHANDAWWA	4444	60 Y	F	40HR	E,U	D	-	-	-	-	CO	+	-	+	-	+	D	+	-	-	++	-	N	N	-	-	+	-	+	
91	AJIAIZ	1049	19 Y	M	36HR	U	RIF	SH	-	-	-	N	+	-	+	+	-	RIF	+	-	-	-	N	-	R	R	-	-	-	-	-
92	RAJESH	7255	50 Y	M	36HR	U	D	-	+	-	-	CO	+	-	+	-	+	D	+	+	+	+	A	-	R	R	-	F	-	+	+
93	SHRIDEVI	4003	30 Y	F	24HR	RIF	RIF	-	+	-	-	N	-	-	+	-	-	RIF	+	-	-	-	N	-	N	N	-	-	-	-	-
94	GOURABAI	225	39 Y	F	48HR	U	D	-	+	-	-	CO	-	-	+	+	+	D	+	+	+	+	A	-	N	N	-	B	-	+	+
95	RAMESH	10211	21 Y	M	48HR	E	U,D	-	+	-	-	CO	-	-	+	-	+	U	+	-	-	-	A	-	N	N	-	-	-	-	+
96	NILAMMA	2880	32 Y	F	48HR	E,U	U	-	+	-	-	N	-	-	+	-	+	U	+	-	-	-	N	-	N	N	-	-	-	-	+
97	PARASAPPA	450	30 Y	M	28HR	E,U	D	-	+	-	-	CO	-	-	+	-	+	D	+	-	-	++	-	N	N	-	-	+	-	-	
98	SANGAMESH	1679	35 Y	M	42HR	U	D	-	+	-	-	CO	-	-	-	-	+	U	+	-	-	+	-	N	N	-	-	-	+	+	
99	SIDDAMMA	3181	29 Y	F	42HR	U	D	-	+	-	-	DH	-	-	-	-	+	D	+	-	-	++	-	N	N	-	-	-	-	+	
100	MANJUNATH	984	49 Y	M	24HR	E,U	D	-	+	-	-	N	-	-	-	-	+	D	+	-	-	++	-	N	N	-	-	-	-	+	

OT	CLINICAL DIAGNOSIS			X RAY DIAGNOSIS			USG DIAGNOSIS			CT SCAN DIAGNOSIS			OPERATIVE DIAGNOSIS
	DIAGNOSIS	EQUIVOCAL	NOT DONE	FINDINGS	DIAGNOSED AS	INCONSISTANT	NOT DONE	DIAGNOSIS	INCONSISTANT	NOT DONE	DIAGNOSED AS	INCONSISTANT	
-	AA	-	-	-	-	-	-	AA	-	-	-	-	AA
-	AA	-	-	-	-	-	-	AA	-	-	-	-	AA
-	HVP	-	-	GUD1	HVP	-	-	-	-	-	-	-	AA
-	AA	-	-	-	-	-	-	AA	-	-	-	-	AA
-	PUP	-	-	GUD1	HVP	-	√	-	-	√	-	-	DUP
-	PUP	-	-	GUD2	HVP	-	-	-	-	-	-	-	DUP
-	PUP	-	-	GUD1	HVP	-	-	-	-	-	-	-	GUP
-	PUP	-	-	GUD1	HVP	-	-	-	-	-	-	-	DUP
-	HVP	-	-	-	-	AP	-	AP	-	-	-	-	IP
-	PUP	-	-	GUD1	HVP	-	-	-	-	-	-	-	DUP
-	PUP	-	-	GUD1	HVP	-	-	-	-	-	-	-	DUP
-	PUP	-	-	-	-	-	-	-	-	-	-	-	DUP
-	PUP	-	-	GUD1	HVP	-	-	-	-	-	-	-	DUP
-	-	+	-	GUD1	HVP	-	-	-	-	-	-	-	DUP
-	PUP	-	-	GUD1	HVP	-	-	-	-	-	-	-	DUP
-	PUP	-	-	GUD2	HVP	-	-	-	-	-	-	-	DUP
-	HVP	-	-	-	-	AA	-	AA	-	-	-	-	IP
-	IO	-	-	MFL	IO	-	-	IO	-	-	-	-	IO
-	IO	-	-	MFL	IO	-	-	-	-	-	-	-	IO
-	IO	-	-	MFL	IO	-	-	IO	-	-	-	-	IO
-	IO	-	-	MFL	IO	-	-	IO	-	-	-	-	IO
-	AC	-	-	-	-	-	-	AC	-	-	-	-	AC
-	AC	-	-	-	-	-	-	AC	-	-	-	-	AC
-	AC	-	-	-	-	-	-	AC	-	-	-	-	AC
-	OH	-	-	-	-	-	-	IO	-	-	-	-	OH
-	AA	-	-	-	-	-	-	AA	-	-	-	-	AA
-	AA	-	-	-	-	-	-	AA	-	-	-	-	AA
-	OH	-	-	-	-	-	-	IO	-	-	-	-	OH
-	PUP	-	-	DUD 1	HVP	-	-	-	-	-	-	-	DUP
-	PUP	-	-	GUD1	HVP	-	-	-	-	-	-	-	DUP
-	PUP	-	-	GUD1	HVP	-	-	-	-	-	-	-	DUP
-	PUP	-	-	GUD2	HVP	-	-	=	-	-	-	-	DUP
-	PUP	-	-	GUD,N	HVP	-	-	-	-	-	-	-	DUP
-	AA	-	-	-	-	-	-	AA	-	-	-	-	AA
-	AA	-	-	-	-	-	-	AA	-	-	-	-	AA
-	PUP	-	-	-	-	INCONSIS	-	AP	-	-	ANP	-	ANP
-	AA	-	-	-	-	-	-	AA	-	-	-	-	AA
-	AA	-	-	=	-	-	-	AA	-	-	-	-	AA
-	AA	-	-	=	-	-	-	AA	-	-	-	-	AA
-	AA	-	-	=	-	-	-	I	-	-	-	-	AA
-	PUP	-	-	GUD	HVP	-	-	-	-	-	-	-	CO P
-	PUP	-	-	GUD1	HVP	-	-	-	-	-	-	-	DUP
-	PUP	-	-	GUD	HVP	-	-	AA	-	-	-	-	IP
-	AA	-	-	-	-	-	-	AA	-	-	-	-	AA
-	AA	-	-	-	-	-	-	AA	-	-	-	-	AA
-	PUP	-	-	GUD	HVP	-	-	-	-	-	-	-	DUP
-	AA	-	-	=	-	-	-	AA	-	-	-	-	AA

