

**“ACOUSTIC RADIATION FORCE IMPULSE  
ELASTOGRAPHY FOR ASSESSING LIVER FIBROSIS  
IN ALCOHOLIC LIVER DISEASE”**

By

**DR. IRANNA MALLAPPA HITTALAMANI**

Dissertation submitted to the

**B.L.D.E. (DEEMED TO BE UNIVERSITY) VIJAYAPUR,  
KARNATAKA**



In partial fulfilment of the requirements for the degree of

**DOCTOR OF MEDICINE**

In

**RADIO-DIAGNOSIS**

Under the guidance of

**DR. RAMESH C PATTANSHETTI**

PROFESSOR,

DEPARTMENT OF RADIO-DIAGNOSIS

**B.L.D.E.(DEEMED TO BE UNIVERSITY) SHRI B. M.PATIL**

**MEDICAL COLLEGE**

**HOSPITAL & RESEARCH CENTRE, VIJAYAPUR**

**KARNATAKA**

**2018**

**B. L. D. E. (DEEMED TO BE UNIVERSITY)**  
**SHRI B. M. PATIL MEDICAL COLLEGE, HOSPITAL &**  
**RESEARCH CENTRE, VIJAYAPURA**

**DECLARATION BY THE CANDIDATE**

I, **Dr. IRANNA MALLAPPA HITTALAMANI**, hereby declare that this dissertation entitled “**ACOUSTIC RADIATION FORCE IMPULSE ELASTOGRAPHY FOR ASSESSING LIVER FIBROSIS IN ALCOHOLIC LIVER DISEASE**” is a bonafide and genuine research work carried out by me under the guidance of **DR. RAMESH C PATTANSHETTI** Professor, Department of Radiodiagnosis, B.L.D.E. (Deemed To Be University) B. M. Patil Medical College Hospital and Research Centre, Vijayapur.

Date:

Place: Vijayapur

**Dr. IRANNA MALLAPPA  
HITTALAMANI**  
Post Graduate Student,  
Department of Radiodiagnosis,  
B.L.D.E. (Deemed To Be University)  
Shri B. M. Patil Medical  
College, Hospital & Research Centre,  
Vijayapur.

**B. L. D. E. (DEEMED TO BE UNIVERSITY)**  
**SHRI B. M. PATIL MEDICAL COLLEGE, HOSPITAL &**  
**RESEARCH CENTRE, VIJAYAPURA**

**CERTIFICATE BY THE GUIDE**

This to certify that the dissertation entitled “**ACOUSTIC RADIATION FORCE IMPULSE ELASTOGRAPHY FOR ASSESSING LIVER FIBROSIS IN ALCOHOLIC LIVER DISEASE**” is a bonafide research work done by **DR. IRANNA MALLAPPA HITTALAMANI**, under my overall supervision and guidance, in partial fulfilment of the requirements for the degree of M. D. in Radiodiagnosis.

Date:

Place: Vijayapur

**DR. RAMESH C PATTANSHETTI**<sup>M.D.</sup>  
Professor Department of Radiodiagnosis,  
B.L.D.E. (Deemed To Be University)  
Shri B. M. Patil Medical  
College, Hospital & Research Centre,  
Vijayapur.

**B. L. D. E. (DEEMED TO BE UNIVERSITY)**  
**SHRI B. M. PATIL MEDICAL COLLEGE, HOSPITAL &**  
**RESEARCH CENTRE, VIJAYAPURA**

**ENDORSEMENT BY THE HEAD OF DEPARTMENT**

This to certify that the dissertation entitled "ACOUSTIC RADIATION FORCE IMPULSE ELASTOGRAPHY FOR ASSESSING LIVER FIBROSIS IN ALCOHOLIC LIVER DISEASE" is a bonafide research work done by **DR. IRANNA MALLAPPA HITTALAMANI** under the guidance of **DR. RAMESH C PATTANSHETTI**, Professor, Department of Radiodiagnosis at B.L.D.E. . (Deemed To Be University) Shri B. M. Patil Medical College Hospital and Research Centre, Vijayapur.

Date:

Place: Vijayapur

**DR. BHUSHAN N LAKHKAR** M.D.  
Professor and HOD  
Department of Radiodiagnosis,  
B.L.D.E. (Deemed To Be University)  
Shri B. M. Patil Medical  
College, Hospital & Research Centre,  
Vijayapur.

**B. L. D. E. (DEEMED TO BE UNIVERSITY)**  
**SHRI B. M. PATIL MEDICAL COLLEGE, HOSPITAL &**  
**RESEARCH CENTRE, VIJAYAPURA**

**ENDORSEMENT BY THE PRINCIPAL**

This to certify that the dissertation entitled "ACOUSTIC RADIATION FORCE IMPULSE ELASTOGRAPHY FOR ASSESSING LIVER FIBROSIS IN ALCOHOLIC LIVER DISEASE" is a bonafide research work done by **DR. IRANNA MALLAPPA HITTALAMANI** under the guidance of **DR. RAMESH C PATTANSHETTI**, Professor, Department of Radiodiagnosis at B.L.D.E.U's Shri B. M. Patil Medical College Hospital and Research Centre, Vijayapur.

Date:

Place: Vijayapur.

**DR. S. P. GUGGARIGUDAR** M.S.  
Principal,  
B.L.D.E. (Deemed To Be University)  
Shri B. M. Patil Medical  
College, Hospital & Research Centre,  
Vijayapur.

**B. L. D. E. (DEEMED TO BE UNIVERSITY)**  
**SHRI B. M. PATIL MEDICAL COLLEGE, HOSPITAL &**  
**RESEARCH CENTRE, VIJAYAPURA**

**COPYRIGHT**

**DECLARATION BY THE CANDIDATE**

I hereby declare that the B.L.D.E. UNIVERSITY, VIJAYAPUR, Karnataka shall have the rights to preserve, use and disseminate this dissertation/thesis in print or electronic format for academic/research purposes.

Date:

Place: Vijayapur

**Dr. IRANNA MALLAPPA  
HITTALAMANI**  
Post Graduate Student,  
Department of Radiodiagnosis,  
B.L.D.E. (Deemed To Be University)  
Shri B. M. Patil Medical  
College, Hospital & Research Centre,  
Vijayapur.

**© BLDE UNIVERSITY VIJAYAPUR, KARNATAKA**

## **ACKNOWLEDGEMENT**

*This piece of work has been accomplished with the grace of almighty God. It gives me immense pleasure to express my heartfelt gratitude to all. I dedicate this thesis to each and everyone who has helped me explore the expanses of knowledge.*

*I express my profound gratitude and sincere thanks to my guide **Dr. R.C Pattanshetti**<sub>M.D.</sub>, and **Dr. Bhushan Lakhkar** <sub>M.D.</sub>, Professor & Head, Department of Radiodiagnosis, B.L.D.E. (Deemed To Be University) Shri B. M. Patil Medical College, Vijayapur, for their constant and unfailing support, professional insight, valuable suggestions, motivation and exemplary guidance to carry out and complete this dissertation. I am deeply grateful to him for providing me necessary facilities and excellent supervision to complete this work.*

*I offer my sincere thanks to **Dr. M. S. Biradar**<sub>M.D.</sub>, Vice Chancellor, B.L.D.E. (Deemed To Be University) Shri B. M. Patil Medical College, Vijayapur, for his support and inspiration.*

*I offer my sincere thanks to **Dr. S. P. Guggarigoudar**<sub>M.S.</sub> Principal, B.L.D.E. (Deemed To Be University) Shri B. M. Patil Medical College, Vijayapur, for his support and inspiration.*

*I am deeply indebted and grateful to my professors and **Dr. M. M Patil**, Department of Radiodiagnosis, B.L.D.E. (Deemed To Be University) Shri B. M. Patil Medical College, Vijayapur, who with their valuable suggestions and constant guidance supported me throughout the preparation of this dissertation work.*

*My thanks to **Dr S. V Patil**<sub>M.D.</sub>, **Dr. Satish Patil** <sub>M.D.</sub>, Associate Professors, **Dr. Bhushita Lakhkar** <sub>M.D.</sub>, **Dr. Veeresh Hanchinal**<sub>M.D.</sub> Assistant Professors and **Dr. Suresh Kanamadi**<sub>MD</sub>, **Dr. Vishal N.S**<sub>DNB</sub> **Dr. Ravikumar**<sub>DNB</sub> and **Dr. Chandalingappa Kuri**<sub>M.D DNB.</sub> Senior Residents, Department of Radio-diagnosis,*

*B.L.D.E. (Deemed To Be University) Shri B. M. Patil Medical College, Vijayapur, for their valuable suggestions and encouragement which have definitely helped me improve my research work.*

*I acknowledge my gratitude to, **Dr. Karthik Adiraju, Dr. Namit Garg, Dr. Shivu Jayadev**, Postgraduate colleagues, Department of Radiodiagnosis, B.L.D.E. (Deemed To Be University) Shri B. M. Patil Medical College, Vijayapur, for their support, advice and help in data collection.*

*I also thank all my seniors **Dr. Rohini Pattanashetti, Dr. Parth Vaishnav, Dr. Holebasu Ballur, Dr. Avinashkumar Garg, Dr. Nandish H R, Dr. Suresh K, Dr. Naveen Sheelavant and Dr. Saurabh Rathi**, my juniors **Dr. Shantala, Dr. Siddaling, Dr. Srikalyan, Dr. Suhas, Dr.Arjun, Dr.Mohit, Dr.Prakriti and Dr.Shabarish** for their help and co-operation during the preparation of this dissertation.*

*I thank **Mrs. Vijaya Sorganvi**, Statistician for her masterly guidance and statistical analysis. I sincerely acknowledge the support and kindness shown towards me by all the staff of Central Library, Shri B. M. Patil Medical College, Vijayapur, at all times. I am thankful to all the Technical and non-teaching Staff of the Department of Radiodiagnosis including **Mrs. Sapna Savalsang, Mrs. Vijayalaxmi and Mr. Patil**, B.L.D.E. (Deemed To Be University) Shri B. M. Patil Medical College, Vijayapur, for their help and co-operation.*

*My heartfelt thanks to my beloved parents **Shri M S Hittalamani, Smt Vijaya M Hittalamani**, my family **Mr Supreeth & Mrs Chetana Jamagouda** and **Miss. Vinuta Hittalamani**, my friends and loved ones **Dr. Arkesh M L, Dr. K.Pramod, Dr Amruthavarshinin Inamdar, Dr Vivek J, Dr.Amogh Bidari, Dr. Anand Kundagol, Dr.Bhooshan Bannuri, Dr.Harish Mudashi, Dr Karthik Dhulakhed, Dr. Pavit Patil**,*



*Dr Sagar S B, Dr Madhu G R, Dr. Sagar Patil Dr. Shridhar Aski, Dr.Sujith Patil,  
Dr Tejas Halkude for their encouragement, support and sacrifices.*

*I thank **Preeti Net Zone**, for their meticulous computerized layout of this  
dissertation.*

*Last but not the least, my sincere thanks to all the patients of this study for  
their cooperation without which this study would not have been possible.*

*Date-*

*Place:*

**DR. IRANNA MALLAPPA HITTALAMANI**

## **ABBREVIATIONS**

*ARFI- Acoustic radiation force impulse elastography*

*V<sub>s</sub>-Median Shear Wave Velocity*

*pSWE-point Shear Wave Elastography*

*TE- Transient Elastography*

*APRI- Aspartate to platelet ratio index.*

*SWV- Shear wave velocity*

*IQR- Interquartile Range*

*AUROC- Area under receiver operating characteristic curve*

*Se- Sensitivity*

*Sp- Specificity*

*OR-Odds Ratio*

*CI-Confidence Interval*

*+LR- Positive Likelihood Ratio*

*HSC-Hepatic Stellate Cells*

*MMP2-Matrix Metalloproteinase 2*

*NAFLD-Non Alcoholic Fatty Liver Disease*

*R<sup>2</sup>- Coefficient of Determination*

*CAP- Controlled Attenuation Parameter*

*LS-Liver Stiffness*

*ICG-R15 - Indocyanin green retention after 15 min*

*ICG-k- Indocyanin green clearance rate.*

*CP- Child-Pugh score*

## TABLE OF CONTENTS

<b>TOPICS</b>	<b>PAGE NO.</b>
1. INTRODUCTION	1-2
AIMS & OBJECTIVES	3
2. METHODOLOGY	4-7
3. REVIEW OF LITERATURE	8-44
4. RESULTS AND OBSERVATIONS	45-56
5. IMAGING GALLERY	57-59
6. DISCUSSION	60-72
7. SUMMARY	73
8. CONCLUSION	74-75
9. BIBLIOGRAPHY	76
10. ANNEXURES	
I. ETHICAL CLEARANCE CERTIFICATE	89
II. PROFORMA	90
III. CONSENT FORM	92
11. MASTER CHART	95

## LIST OF TABLES

SL. NO.	TABLES	PAGE
1	Table 1 Couinaud & Bismuth Classification of segments of Liver	10
2	Table 2 Histological grades of fibrosis according to METAVIR staging.	23
3	Table 3 Histological grades of activity according to METAVIR staging.	23
4	Table 4 Typical parameters used for ARFI imaging <sup>(64)</sup>	33
5	Table 5 Shear Wave Velocities in different age groups	35
6	Table 6 Comparison of Diagnostic performance of Transient Elastography & Acoustic radiation force impulse elastography.	41
7	Table 7 Cut off values for shear wave velocity to quantify liver fibrosis.	42
8	Table 8 Shear wave velocities in patients with and without elevated ALT levels.	44
9	Table 9 Diagnostic performance of acoustic radiation force impulse for the different liver fibrosis stages	44
10	Table 10 APRI grades of fibrosis Distribution of cases according stratified on the basis of FIB-4 Index	47
11	Table 11 FIB-4 grades of fibrosis Distribution of cases according to their pathological stages of Fibrosis	47
12	Table 12 Pathological grades of fibrosis	48
13	Table 13 Shear wave elastography grades of fibrosis	49
14	Table 14 Grouping of the Cases for comparison	51
15	Table 15 Diagnostic performance of APRI Index vs ARFI Elastography (Median Vs) vs FIB-4 Index using the cut-offs suggested by M. Friedrich-Rust et al for Liver Fibrosis(84)	52
16	Table 16 Comparison of Median Shear Wave (Vs) speed	52

	measurements for different pathological stages of fibrosis.	
17	Table 17 Cut-off values obtained from the AUROC analysis by Maximising the Youden's Index	53
18	Table 18 Diagnostic performance of ARFI Elastography (Median Vs) using the cut-offs obtained based on our observations	55
19	Table 19 Comparison of Pathological groups of Studies available in Literature.	63
20	Table 20 Distribution of cases based on ARFI elastography using suggested cut-offs (84)	65
21	Table 21 Mean of the Median Shear Wave Speed values with pathological diagnosis as the reference	66
22	TABLE 22 Comparison of Cut-offs and Diagnostic performance of Present Study with Available meta-analysis	68

## LIST OF PICTURES

SL. NO.	PICTURES	PAGE NO
1.	Figure 1 A. Diaphragmatic surface of liver	9
2.	Figure 1 B. Visceral Surface of liver.	9
3.	Figure 2.A Caudate lobe of liver above the inferior vena cava	11
4.	Figure 2. B Cross sectional view showing caudate lobe of liver	12
5.	Figure 3 Portal vein and hepatic veins dividing segments of liver	13
6.	Figure 4 A Hexagonal Functional Unit of the liver showing zones of vascularisation	13
7.	Figure 4 B Functionally Important cells of liver	14
8.	Figure 5 Metabolism of alcohol in the liver.	16
9.	Figure 6 Effects of alcoholism on Liver.	24
10.	Figure 7 PR-stained sections (100 magnification) obtained from patients' livers with different degrees of fibrosis from F0 to F4.	26
11.	Figure 8 A. Normal liver hypoechoic to the right renal cortex	26
12.	Figure 8 B. Normal liver hypoechoic to the spleen	27
13.	Figure 9 The main lobar fissure (White line) dividing the right and left lobe of the liver LEFT LOBE(LL), Right Lobe (RL), Gall bladder(GB) and Inferior Vena Cava (IVC)	28
14.	Figure 10 Sub-costal view showing the hepatic veins	
15.	Figure 11. Acoustic waves: Longitudinal waveform	30
16.	Figure 12. A shear wave model	31
17.	Figure 13. Exciting a region with acoustic radiation force. Transducer (T) Region of excitation(ROE) Shear wave (SW)	32
18.	Figure 14. Tracking Pulse (Blue line) and Push Pulse (Red dotted line) aligned in same axis	32
19.	Figure 15 Overview of Shear wave based elastography	33
20.	Figure 16 depicting Bar diagram of age distribution of patients in our study	45
21.	Figure 17 Distribution of cases according to clinical diagnosis	46
22.	Figure 18 Distribution of cases based on pathological stages of fibrosis	48

23.	Figure 19 Distribution of cases based on pathological stages of fibrosis	49
24.	Figure 20 Showing AUROC curves using APRI Index (Red Line), ARFI elastography (Blue Line) & FIB-4 index (Green Line) as test curves in diagnosis of Significant Fibrosis & No/Non significant fibrosis Considering histopathological outcomes (Liver Biopsy) the standard value curve represented in Purple.	50
25.	Figure 21 Showing AUROC curve using APRI Index (Red Line), ARFI elastography (Blue Line) & FIB-4 index (Green Line) as test curves in diagnosis of Severe Fibrosis & Significant Fibrosis Considering Histopathological outcomes (Liver Biopsy) as the standard value curve represented in Purple.	50
26.	Figure 22 Showing AUROC curve using APRI Index (Red Line), ARFI elastography (Blue Line) & FIB-4 index (Green Line) as test curves in diagnosis of Severe	51
27.	Figure 23 Box Plots of the observed median shear wave velocities.	53
28.	Figure 25 Showing AUROC curve using APRI Index (Red Line), ARFI elastography (Blue Line) & FIB-4 index (Green Line) as test curves in diagnosis of Severe Fibrosis & Significant Fibrosis Considering Histopathological outcomes (Liver Biopsy) as the standard value curve represented in Purple.	54
29.	Figure 26 Showing AUROC curve using APRI Index (Red Line), ARFI elastography (Blue Line) & FIB-4 index (Green Line) as test curves in diagnosis of Severe Fibrosis & Cirrhosis Considering Histopathological outcomes (Liver Biopsy) the standard value curve represented in Purple.	55
30.	Figure 27 correct placement of the ultrasound transducer perpendicular to the surface of the body with the patient in the left lateral decubitus position	57
31.	Figure 28 selecting the correct placement of ROI (region of interest) in a homogenous liver parenchyma devoid of any vessels and the ROI line is placed perpendicular to the surface.	58

32.	Figure 29 Display of the observed shear wave velocities and the depth from surface at which they are measured. The median shear wave velocity ( $V_s$ ) is also displayed along with the mean, standard deviation and interquartile range (IQR)	59
33.	Figure 30 Case Distribution according to METAVIR staging of fibrosis showing group of interest.	63



## **ABSTRACT**

### **BACKGROUND:**

Chronic alcoholism is one of the major cause of liver disease in India with an estimated prevalence of 5.1 % and a high mortality of 62.9%. Liver fibrosis occurs in several stages which are diagnosed on the basis of several biochemical indices, liver biopsy and elastography. Acoustic Radiation Force Impulse (ARFI) elastography is a non invasive, quantitative and relatively a newer technique that has been gaining popularity in diagnosis of liver fibrosis. To our knowledge there are only TWO other studies in the reported literature, which have evaluated this technique in the alcoholic liver disease for diagnostic utility.

### **AIMS & OBJECTIVES OF THE STUDY:**

The aim of this study is to evaluate the usefulness of ARFI (acoustic radiation force impulse) for assessing liver fibrosis and correlate the Liver fibrosis scores with the biochemical analysis using liver biopsy as the reference standard.

### **SOURCE OF DATA:**

Data for the study will be collected from the patients attending/referred to our hospital; who fulfil the inclusion criteria between NOVEMBER 2016 to JULY 2018.

### **METHOD OF COLLECTION OF DATA:**

The patients visiting our hospital who fulfil the inclusion criteria are subjected to the complete blood count and serological tests and then further a 2D ultrasonographic assessment of abdomen was done along with ARFI elastography to assess the liver parenchyma for fibrosis. The ultrasound technique used will be

performed with “Siemens Acuson S3000 HELX evolution” Ultrasound system. The patients also underwent liver biopsy on the same day.

## **RESULTS:**

We evaluated a total of 50 patients with a high risk consumption of alcohol, 40% of these patients had Severe fibrosis & cirrhosis of liver. ARFI elastography performed better than both APRI & FIB-4 indices for significant fibrosis  $\{F \geq 2$  (AUROC-0.98)}, severe fibrosis  $\{F \geq 3$  (AUROC-0.96)} & Cirrhosis of liver  $\{F=4$  (AUROC-0.97)} when the existing cut-offs of 1.34 m/s, 1.54 m/s & 1.80 m/s for  $F \geq 2$ ,  $F \geq 3$  &  $F=4$  stages respectively. However, with our observed Median shear wave velocities and the histopathological outcomes ARFI elastography had better diagnostic ability than the biochemical only in distinguishing Cirrhosis of liver ( $F=4$ ) from the severe fibrosis stage ( $F \geq 3$ ) with AUROC of 0.97, Whereas for  $F \geq 2$  &  $F \geq 3$  stages it was comparable to the biochemical indices with AUROC of 0.65 & 0.70.

## **CONCLUSION:**

ARFI elastography is a reliable screening tool for the liver fibrosis grading. It performs better than the biochemical indices in distinguishing significant fibrosis, severe fibrosis & cirrhosis of liver while the biochemical indices merely distinguish between severe fibrosis and no fibrosis. The distinction of these pathological stages affects the treatment plan and also monitoring of response to treatment. ARFI also has advantages of being a non-invasive, reliable & highly repeatable diagnostic test in contrast to the liver biopsy. When used as a screening tool it can eliminate the need for liver biopsy, which can be reserved in cases of dilemma.

## **INTRODUCTION**

Palpation, among the oldest of clinical skills, was used in ancient Egypt and is described in the Ebers Papyrus of 1552 BC. Elastography is merely a quantifiable ‘virtual palpation’ technique, where a region of tissue is compressed and the degree to which it distorts (known as strain) is assessed.<sup>(1)</sup>

Chronic liver disease is a substantial worldwide problem and major contributing factor for disease burden in India. For instance the prevalence of alcohol abuse is 5.1% of the total population and Liver cirrhosis mortality rate is high as 62.9% according to recent data published by the WHO in 2014.<sup>(2)</sup> The ultimate fate of all chronic liver diseases irrespective of etiology is progressive hepatic fibrosis, resulting in architectural distortion and cirrhosis.<sup>(3)</sup> Liver fibrosis is a dynamic process, and studies have shown that a regression is possible with treatment of the underlying condition.<sup>(4)</sup> Thus, non-invasive early diagnosis of liver fibrosis is the need of the hour.

Liver biopsy is currently the gold standard for assessing hepatic fibrosis. However, it is an invasive, painful procedure, with sampling error, interobserver variability and error rate of 33% limit its use.<sup>(5,6)</sup> Currently, transient elastography, shear-wave (SW) elastography, and acoustic radiation force impulse imaging are the three main ultrasound based elastographic techniques that allow direct and indirect quantification of liver stiffness.<sup>(7)</sup>

Acoustic radiation force impulse (ARFI) is a relatively newer elastography technique used for assessment of liver fibrosis. Virtual Touch Tissue Quantification method (employed in the Siemens machines) quantifies the amount of liver fibrosis

using the ARFI principle and can be used as a promising tool in non-invasive diagnosis of liver cirrhosis.<sup>(8)</sup>

In a recent study published in June 2016 Xu, Shi-Hao et al observed that Liver fibrosis index using Liver stiffness, platelet count and prothrombin time, is an independent predictor of liver fibrosis and also developed a novel LSPS (LFI+SPI) and LSPGS(LFI+SPI+GGT) indices for staging fibrosis which led to a reduction in the number of liver biopsies to 60.5% for significant fibrosis & 98% for cirrhosis respectively.<sup>(9)</sup>

Hence Acoustic radiation force impulse elastography can be used in conjunction with other biochemical tests and indices as an effective tool for acceptable non-invasive assessment of liver fibrosis.

## **AIMS & OBJECTIVE OF STUDY:**

The aim of this study is to evaluate the usefulness of ARFI (acoustic radiation force impulse) for assessing liver fibrosis and correlate the Liver fibrosis scores with the biochemical analysis considering liver biopsy as reference.

## **MATERIALS AND METHODS**

Ultrasound device which is used in the study is Siemens ACUSON S3000 model with Elastography software & curvilinear transducer (4C1). The spatial and temporal resolution for these machines is good. Quantitative shear wave tissue measurements across multiple transducers and study types can be done. The system also has a Color Doppler, Pulsed Doppler, and Continuous wave Doppler, M-mode & B-mode imaging capabilities.

### **SOURCE OF DATA:**

Data for the study will be collected from the patients attending/referred to our hospital; who fulfil the inclusion criteria between NOVEMBER 2016 to JULY 2018.

### **SAMPLE SIZE:**

Considering the sensitivity of ARFI elastography<sup>(8)</sup> of 93% and the sensitivity of clinical signs as 69%<sup>(10)</sup> at 95% confidence level & 80 % power sample size is 34.

$$n = \frac{z\alpha^2 p(100-p)}{D^2}$$

*Where  $z\alpha$  – z value at  $\alpha$  level*

*p- sensitivity for breast lesions*

*d- margin of error*

Hence 50 cases were included in the study.

### **STATISTICAL ANALYSIS:**

Data was presented diagrammatically, mean  $\pm$ SD and sensitivity and specificity by Fischer's, Chi square tests. Association with p values and AUROC was calculated.

1. Mean  $\pm$ SD
2. Kruskal-Wallis' Test for ANOVA
3. Sensitivity, specificity, negative predictive value (NPV) and positive predictive value (PPV)

4. Pearson's analysis
5. AUROC curve analysis
6. Box plots for the Mean values.

## **METHOD OF COLLECTION OF DATA**

### **STUDY DESIGN**

A prospective cross sectional study design was used.

### **METHOD OF COLLECTION OF DATA**

The patients visiting our hospital who fulfil the inclusion criteria are subjected to the complete blood count and serological tests and then further a 2D ultrasonographic assessment of abdomen is done along with ARFI elastography to assess the liver parenchyma for fibrosis. The ultrasound technique used will be performed with “Siemens Acuson S3000 HELX evolution” Ultrasound system. The patients will also undergo Liver Biopsy on the same day.

**APRI index is calculated using the formula:**

$$\text{APRI} = \frac{\frac{\text{AST level}}{\text{Upper limit for AST level}}}{\text{Platelet count (10}^9\text{/L)}} \times 100$$

**FIB-4 index is calculated using the formula:**

$$\text{FIB-4} = \frac{\text{Age (in years)} \times \text{AST level (IU/L)}}{\text{Platelet count (10}^9\text{/L)} \times \sqrt{\text{ALT (IU/L)}}}$$

**ARFI elastography will be performed using the WFUMB & Manufacturer guidelines as follows<sup>(11,12)</sup>:**

### **Pre-requisites:**

- The patient was asked to come with Fasting state;
- Dorsal decubitus position, with the right arm elevated above the head for optimal intercostal access;
- The patient was asked to hold the breath while performing each measurement. The patient was trained not to take a deep breath. Resting respiratory position (breath-hold without deep inspiration);

### **ROI placement**

- ROI placement was done 1.5-2.0 cm beneath the Glisson's capsule to avoid reverberation artifacts and increased sub capsular stiffness.
- ROI was placed perpendicular to the center of the transducer.
- ROI was placed to avoid large liver vessels.'

### **Unreliable Measurements**

- When the Interquartile range (IQR) of the measurements was  $> 0.3 \times$  Median shear wave speed the measurements were considered unreliable.

### **INCLUSION CRITERIA:**

All patients who visit Radiology department of our hospital who fulfil the following criteria:

- More than 18 years old.
- High risk alcohol consumption ( $>40\text{g}$  per day for men and  $>20\text{g}$  per day for women for a cumulative period of more than 5 years).<sup>(13)</sup>
- Alcoholics in whom liver disease is not explained by any other cause.



**EXCLUSION CRITERIA:**

The following patients will be excluded from the study:

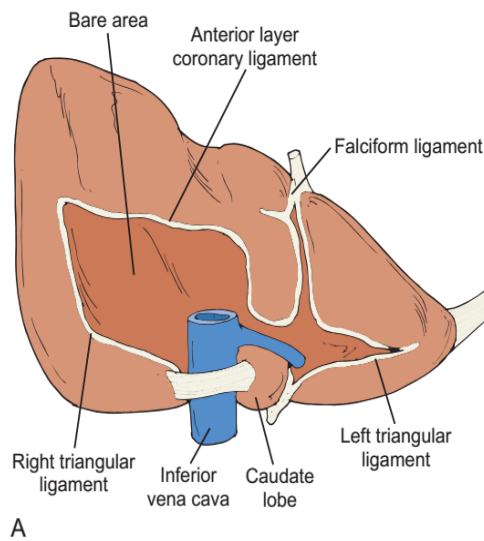
1. Liver trauma patients.
2. Established cases of cirrhosis.
3. Diagnosed cases of other liver diseases (viral hepatitis, autoimmune hepatitis, extrahepatic cholestasis and other liver diseases).
4. Patients in whom liver biopsy was not possible because of medical conditions.

## REVIEW OF LITERATURE

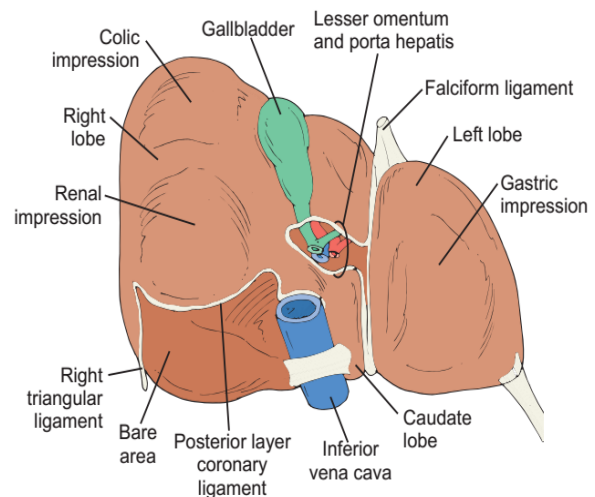
### ANATOMY

The liver is the largest solid organ in the abdomen, occupying major part of the right upper quadrant & a part of epigastrium; approximately weighing about 1.5kg in a normal adult. The liver has a convex *diaphragmatic surface* and a concave *visceral surface*. (Fig.1 A&B) Superiorly, laterally, and anteriorly it is bound by the diaphragm. The stomach, duodenum, and transverse colon are situated medial to the liver; the hepatic flexure lies inferiorly; and posteriorly it is bordered by the right kidney and adrenal gland. It is encapsulated by a dense layer of connective tissue, called *the Glisson's capsule*. Liver is covered by the peritoneum all over its surface except in the regions of the gallbladder fossa, the fossa for the inferior vena cava (IVC), and the bare area.

The bare area is in direct contact with the diaphragmatic surface posteriorly and is limited by the coronary ligament. The coronary ligament which is formed by folds of parietal and visceral peritoneum has two layers viz. anterior and posterior coronary ligaments. These layers fuse on the lateral surface forming the right triangular ligament and medially they form the left triangular ligament. The falciform ligament formed by the ventral fusion of the coronary ligament contains the round ligament of liver or the ligamentum teres. Falciform ligament divides the liver into the right & the left lobes and runs from the anterior abdominal wall and umbilicus to the anterior surface of the liver.<sup>(14,15)</sup>



A



B

**FIG 1 A. Diaphragmatic surface of liver**

**FIG 1 B. Visceral Surface of liver.**

The site where the hepatic artery and portal vein enter the liver, and the common hepatic duct exits the liver, is referred to as the hepatic hilum. These structures then run in the hepatoduodenal ligament.<sup>(16)</sup> *The hepatoduodenal ligament and the hepatogastric ligament* are formed by the right and left portions of the lesser omentum which spans from the lesser curvature of the stomach & first part of duodenum to the visceral peritoneum of the liver.<sup>(17)</sup>

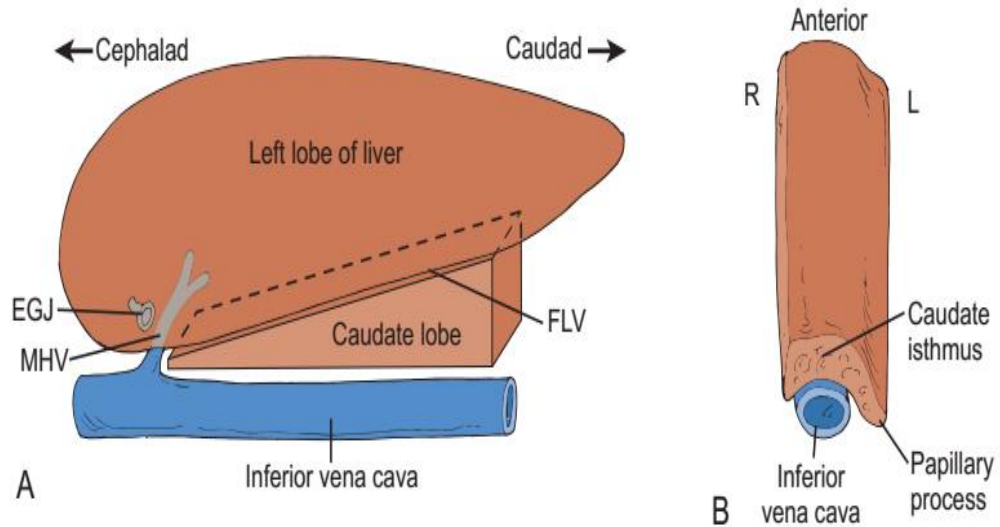
The Liver receives dual blood supply viz. from the *hepatic artery* (30%) a branch of the celiac axis and the *portal vein* (70%) which drains the blood from the gastrointestinal tract and spleen via splenic vein, left gastric vein and the superior and inferior mesenteric vein. The portal vein divides the liver into superior and inferior levels. The level of the portal vein is called the *principal plane*.<sup>(18)</sup> The hepatic venous system is formed by the three main tributaries the right, middle and the left hepatic veins joining to form the common hepatic vein which directly drains into the inferior vena cava. The hepatic veins receive blood from the hepatic sinusoids via the central veins of each functional hepatic lobule.

The Bismuth and Couinaud classification of liver anatomy divides the liver into four sectors and eight functionally independent segments based on the hepatic veins and branches of the portal vein.<sup>(15)</sup> The functional segmentation of the liver is based on surgical definition of feasible intrahepatic boundaries for resection. The segmental anatomy of the liver is primarily based on vascular anatomy. Each segment has an independent vascular supply and biliary drainage.<sup>(19,20)</sup> The Couinaud classification is particularly widely accepted mostly by the radiologists in Asia and Europe whereas the Bismuth classification is argued to give detailed anatomy for modern hepatic surgery and radiology. A simple comparison has been described in the table below.<sup>(21)</sup>

C. Couinaud (1957)		H. Bismuth (1982)	
Sector	Segment	Sector	Segment
Caudate lobe	I	Caudate lobe	I
Lateral	II	Posterior	II
Paramedian	III	Anterior	III
	IV		IVa, IVb
Paramedian	V	Anteromedial	V
	VIII		VIII
Lateral	VI	Posterolateral	VI
	VII		VII

**Table 1 Couinaud & Bismuth Classification of segments of Liver**

Segment I is the caudate lobe that lies in the posterior aspect of the liver and is bordered by the inferior vena cava posteriorly, the fissure for ligamentum venosum anteriorly and the middle hepatic vein superiorly. It is in connection with the right lobe of the liver from the isthmus of caudate lobe (Fig. 2A ).<sup>(22)</sup> *The caudate lobe anatomy is particularly of clinical importance as its enlargement implies cirrhosis and venous occlusion. (Fig. 2B)*

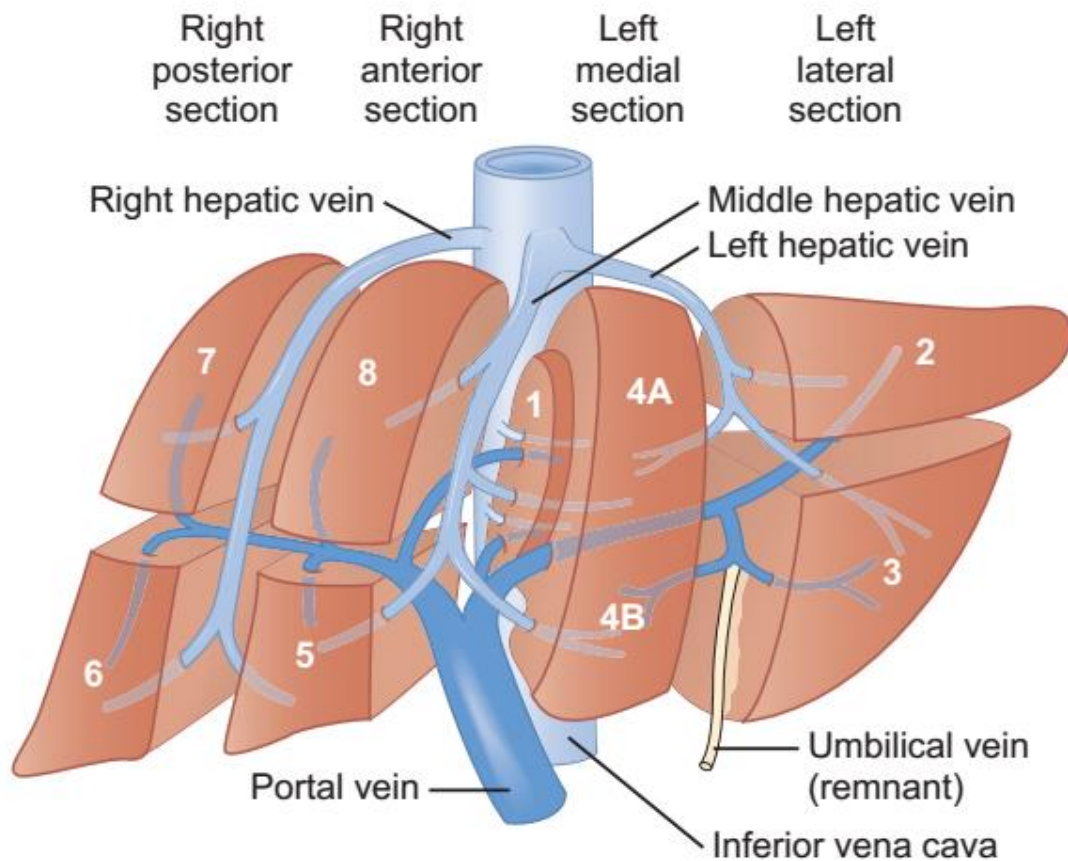


**Figure 2.A caudate lobe of liver above the inferior vena cava**

**Figure 2. B Cross sectional view showing caudate lobe of liver**

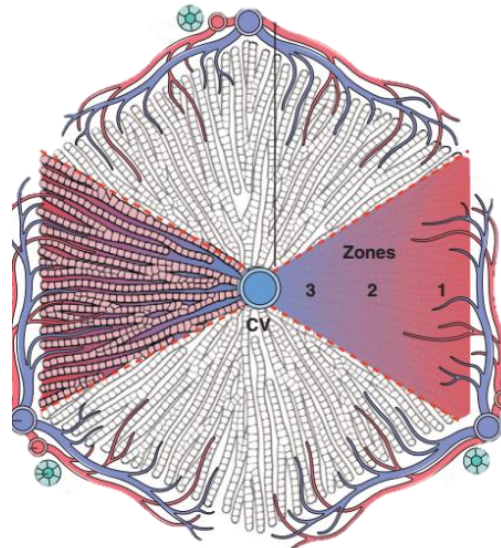
Middle hepatic vein divides the liver into the left and right lobes. The right lobe is further divided into the anterior (V & VIII) and posterior (VI & VII) sections by right hepatic vein. Similarly the left lobe is divided into the medial (IV) and lateral (II & III) sections by left hepatic vein. The segments drain into the respective hepatic veins in addition to it the central veins from segments IV (a&b), V & VIII drain into the middle hepatic vein. An exception to it is that segment VIII doesn't drain into the right hepatic vein.

The portal vein however divides the liver in the inferior aspect into the left and right lobe. Further, the right and left portal vein branches divide the lobes into superior (II, IVa, VII & VIII) and inferior segments (III, IVb, V & VI) respectively.

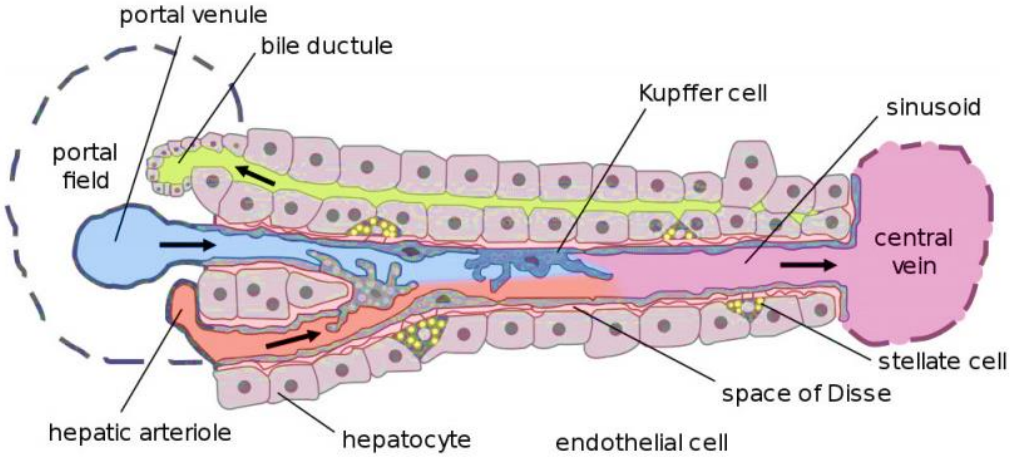


**Figure 3 Portal vein and hepatic veins dividing segments of liver**

The functional unit of the liver is a *hepatic lobule*. An idealized representation of the "classical" liver lobule is a six-sided prism about 2 mm long and 1 mm in diameter.<sup>(23)</sup> The sheets of hepatocytes are arranged along the sinusoids in a sheets and cords pattern which connect the portal venules (blue) and hepatic arterioles (red) to the central veins. Within the sheets of hepatocytes lie the biliary sinuses that drain into the bile ductules (green). (Fig 3) Each lobule is further classified into acini that are triangular units with base at the portal vein side converging towards the central veins. A single *acinus* can be further divided into Zones 1, 2 & 3 with respect to their distance from the portal venous side (Fig 4A).



**Figure 4 A Hexagonal Functional Unit of the liver showing zones of vascularisation**



**Figure 4 B Functionally Important cells of liver**

Other functionally important cells in the hepatic lobule are the kupffer cells that lie in the endothelial lining of the sinusoids and also the stellate cells that lie in the space of disse.(Fig 4B) Stellate cells normally function as storage cells for vitamin A, but during the development of fibrosis they activate and transform into myofibroblasts that account for the fibrosis (fibrous tissue deposition in the space of disse) in chronic liver diseases. The kupffer cells are specialized macrophages that break down the RBCs and form bilirubin which is further conjugated by the

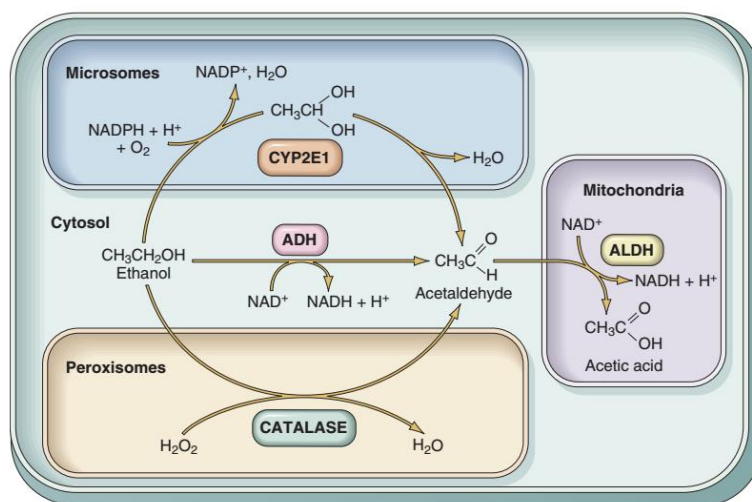
hepatocytes. Activation of kupffer cells is an intermediate step in the liver injury caused in alcoholic liver disease.

### Effects of Chronic Alcoholism and Pathogenesis of Alcoholic Liver Disease

Alcohol intake in moderate amounts is not harmful, but excessive alcohol intake results in serious physical and psychological effects. Alcohol is absorbed directly in the stomach and small intestine. It is then distributed to all the tissues and fluids of the body. Less than 10% is excreted unchanged in the urine, sweat, and breath. The exhaled amount of alcohol is proportional to the blood level. The various states of alcoholism range from drunk, drowsy, stupor and coma that occurs at concentrations as high as 300 mg/dL. The effects of alcohol vary by age, sex, body fat and chronicity.<sup>(24)</sup>

### Metabolism of alcohol

Most of the alcohol in the blood is oxidized to *acetaldehyde* in the liver by three enzyme systems viz. alcohol dehydrogenase, the microsomal ethanol-oxidizing system (CYP2E1), and catalase. *Acetaldehyde* is converted to *acetate* by acetaldehyde dehydrogenase, which is then utilized in the mitochondrial respiratory chain.<sup>(24)</sup>



**Figure 5 Metabolism of alcohol in the liver.**

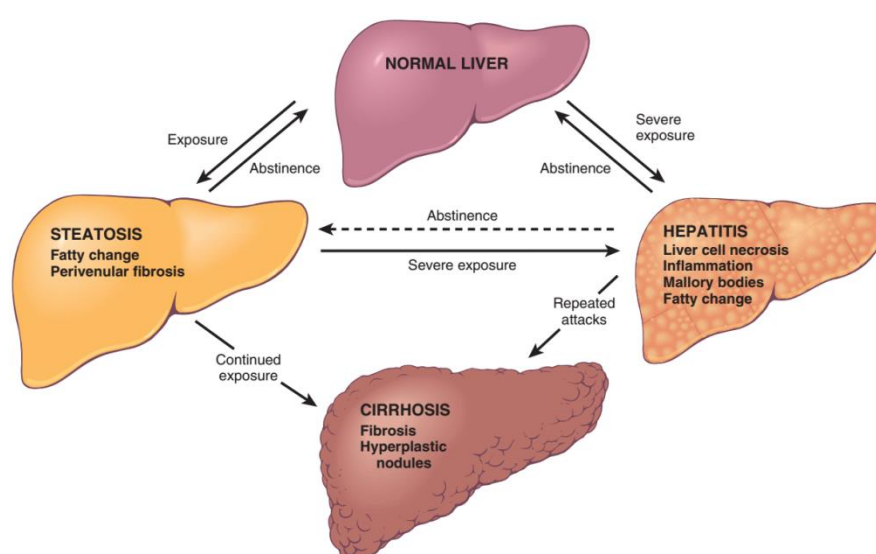


The most important toxic metabolites and certain metabolic pathways disrupted by oxidation of ethanol are:

- *Acetaldehyde*- which is toxic to the hepatocytes and also is the major contributing factor in the mechanism of liver injury due to alcohol.<sup>(25)</sup>
- Increased *NADH/NAD ratio*- As nicotinamide adenine dinucleotide (NAD) is required for the fatty acid oxidation; the reduction in its concentration is the cause for accumulation of fat in the hepatocytes.<sup>(26)</sup>
- *Reactive oxygen species* are the result of its oxidation by CYP2E1 and they are responsible for the lipid peroxidation of hepatocyte cell membranes.<sup>(27)</sup>
- *Lipopolysaccharide (an endotoxin)* is released from the wall of the gram negative intestinal flora and activates the kupffer cells and macrophages leading to the release of TNF and other cytokines that mediate liver injury.<sup>(28)</sup>

## EFFECTS OF CHRONIC ALCOHOLISM

The main effects of chronic alcoholism are fatty liver, alcoholic hepatitis, and cirrhosis (Fig 6) which leads to portal hypertension and increases the risk for development of hepatocellular carcinoma. The amount of alcohol intake and the duration are important regulators for the hepatic damage caused. Ingestion of as much as 80 gm of alcohol over one to several days generally produces mild, reversible *hepatic steatosis*.<sup>(24)</sup>



**Figure 6 Effects of alcoholism on Liver.**

Major risk factors for Alcoholic liver disease include: <sup>(13)</sup>

- Quantity and duration- Daily intake of 40-80 gm or more of ethanol generates significant risk for *severe hepatic injury*, and daily ingestion of 160 gm or more for 10 to 20 years is associated more consistently with severe injury. *Only 10% to 15% of alcoholics, however, develop cirrhosis.*<sup>(29)</sup>
- Gender-Women exhibit to have increased susceptibility to alcoholic liver disease at amounts >20 g/day.<sup>(30)</sup>

- Hepatitis C-HCV infection along with alcoholic liver disease is worsens the liver damage and is a poor prognostic factor.<sup>(31)</sup>
- Genetics- Patatin-like phospholipase domain-containing protein 3 (PNPLA3) alters the hepatic fatty acid & triglyceride metabolism which is a risk factor for alcoholic cirrhosis.<sup>(32)</sup>
- Fatty liver- Alcohol injury does not require malnutrition, but obesity and nonalcoholic fatty liver are risk factors.<sup>(33)</sup>

### **PATHOGENESIS OF ALCOHOLIC LIVER DISEASE**

Though the complete mechanism of liver injury in alcoholic liver disease is not understood clearly, the three main forms of alcohol liver disease can be classified as <sup>(24)</sup> :

1. Hepatic steatosis
2. Alcoholic steatohepatitis
3. Steatofibrosis finally causing Cirrhosis (Micronodular cirrhosis is characteristic)

#### **Hepatic steatosis**

Hepatic steatosis is mainly caused by the following changes that occur in response to the alcohol metabolism:

- Displacement of normal substrates away from catabolism and towards lipidsynthesis, as a result of increased generation of reduced nicotinamide adenine dinucleotide (NADH) by the two major enzymes of alcohol metabolism, the alcohol dehydrogenase and acetaldehyde dehydrogenase.<sup>(26)</sup>

- Impaired assembly and secretion of lipoproteins<sup>(26,34)</sup> and
- Increased peripheral catabolism of fat, which releases free fatty acids into the circulation.

Clinically the patients are asymptomatic and are usually incidentally diagnosed on a routine ultrasound examination to have hepatomegaly with changes of fatty infiltration. Mild elevation of serum bilirubin and alkaline phosphate levels is also seen.<sup>(35)</sup> With constant motivation and abstinence from alcohol the fatty changes can be reverted back to normal.

Histologic features are accumulation of lipids that begins as small droplets that coalesce into large droplets which distend the hepatocyte and push the nucleus away from the centre.<sup>(36)</sup> Macroscopically, the fatty liver in individuals with chronic alcoholism is a large, soft organ that is yellow and greasy.<sup>(24)</sup>

### **Alcoholic steatohepatitis**

With persistent consumption of alcohol the next form of liver injury that occurs is the alcoholic steatohepatitis. The causes for steatohepatitis include:

- Acetaldehyde- Causing lipid peroxidation and acetaldehyde-protein adduct formation, that disrupts cytoskeletal and membrane function.<sup>(25,26)</sup>
- Reactive oxygen species- Which react with cellular proteins, cause damage to membranes, and alter hepatocellular function. <sup>(26,27)</sup>
- Alcohol impairs hepatic metabolism of methionine, which *decreases glutathione levels*; sensitizing the liver to oxidative injury.<sup>(37,38)</sup>
- Release of bacterial endotoxin- which induces inflammatory responses in the liver, due to the activation of NF- $\kappa$ B, and release of TNF, IL-6, & TGF- $\alpha$ <sup>(39-41)</sup>

- Alcohol stimulates the release of endothelins from sinusoidal endothelial cells, causing vasoconstriction and *contraction of activated myofibroblastic stellate cells*, leading to a decrease in hepatic sinusoidal perfusion<sup>(42)</sup>

Clinically the patients usually experience malaise, anorexia, weight loss, and upper abdominal discomfort. Usually after a bout of heavy drinking, these symptoms may range from minimal to acute presentation of liver failure. Tender hepatomegaly and lab findings of elevated serum bilirubin, AST, ALT, ALP are also features of alcoholic hepatitis.<sup>(35)</sup> Classically, AST:ALT ratio >1 is a feature of the alcoholic liver cirrhosis that distinguishes it from other chronic liver diseases.

Histologically the following changes occur<sup>(36)</sup>

- 1. Hepatocyte swelling and necrosis:** Single or scattered foci of cells undergo swelling (ballooning) and necrosis. It is due to the accumulation of fat and water, as well as proteins that are normally exported.
- 2. Mallory-Denk bodies:** These are usually present as clumped, amorphous, eosinophilic material in ballooned hepatocytes. These inclusions are a characteristic but not specific feature of alcoholic liver disease.
- 3. Neutrophilic reaction:** Neutrophils infiltrate the hepatic lobule and accumulate around degenerating hepatocytes, particularly those having Mallory-Denk bodies.

### **Steatofibrosis**

Subendothelial matrix of liver contains a well-defined lattice-like meshwork of extracellular matrix (ECM) molecules that provide cellular support while allowing unimpeded transport of solutes and growth factors. During hepatic injury the ECM

composition becomes scar-like, and hepatocellular function deteriorates. Stellate cells (Hepatic stellate cells/HSCs) are the key fibrogenic cells.<sup>(43)</sup> HSCs are activated to undergo a phenotypic switch from a quiescent, vitamin A storing cell into proliferative, myofibroblast-like cells, exhibiting upregulated collagen synthesis.<sup>(44)</sup>

**‘Activation’** of hepatic stellate cells is the key event in fibrogenesis. Transforming growth factor (TGF)- $\beta$ , has been identified as the most profibrotic cytokine. It promotes HSC expression of collagen I, transition to a myofibroblast-like phenotype and inhibition of ECM degradation through the expression of tissue inhibiting metalloproteinases (TIMPs).<sup>(45)</sup> Initiation & perpetuation are the main components of the activation of HSCs.

**Initiation** or preinflammatory stage shows rapid changes in gene expression and phenotype that make the cells responsive to cytokines and other local stimuli. **Perpetuation** is composed of the cellular events that amplify the activated phenotype through enhanced growth factor expression and responsiveness. It is result of autocrine and paracrine stimulation, as well as from accelerated ECM remodeling and is a continuously dynamic process.<sup>(43,45,46)</sup>

Endothelial cells also take part in activation, both by production of cellular *fibronectin* and via conversion of TGF $\beta$  from the latent to active, pro-fibrogenic form.<sup>(39-41)</sup> Kupffer cells can stimulate matrix synthesis, cell proliferation and release of retinoids by stellate cells through the actions of cytokines and reactive oxygen intermediates/lipid peroxides. MMP-9 also released by the kupffer cells can activate latent TGF $\beta$ , which in turn stimulates stellate cell collagen synthesis.<sup>(47)</sup> ROS (reactive oxygen species) are capable of enhancing stellate cell activation and collagen synthesis. Nitric oxide (NO) can counterbalance the stimulatory effects of

ROS by reducing stellate cell proliferation and contractility; also produced by kupffer cells.<sup>(26–28)</sup>

Neutrophils are also an important source of ROS, which may have a direct stimulatory effect on stellate cell collagen synthesis via superoxide, they also produce NO. Transcriptional induction of matrix metalloproteinase-2, including endothelin-1 (ET-1), thrombin, FGF, VEGF, PDGF and insulin-like growth factor is essential for proliferation of the activated stellate cells.<sup>(47)</sup>

**Fibrogenesis** is mediated by the stellate cells which are the most important source of TGF $\beta$ 1 in liver fibrosis, but Kupffer cells and platelets also secrete this cytokine. Activation of HSCs is associated with increased responsiveness to TGF $\beta$  and in turn enhanced ECM synthesis. Connective tissue growth factor (CTGF) is a cytokine that promotes fibrogenesis in skin, lung and kidney & is strongly expressed by stellate cells during hepatic fibrosis.<sup>(48)</sup>

**Contractility:** There is a marked increase in the contractility of stellate cells during activation leading to increased portal resistance.<sup>(49)</sup> Endothelin-1 (ET-1) is the key contractile stimulus towards stellate cells in addition to increased endothelin-1, there is decreased nitric oxide that also contributes to the increased contractility of the stellate cells.

### **Contribution of steatosis to hepatic fibrosis**

- (1) Cyp2E1/Cyp 4A-mediated oxidant stress is mainly due to direct fibrogenic stimulus. Saturation of alcohol dehydrogenase pathways leads to induction of cytochrome 450 s. Oxidation of alcohol by Cyp2E1 or Cyp4A generates reactive oxygen species (ROS).

- (2) Inflammation with release of fibrogenic cytokines and mediators- leukocyte infiltration is a key feature of fibrosing steatotic liver diseases in alcoholic liver disease.
- (3) PPAR signaling and activity-Cyp4A is induced by PPARa, providing a source of oxidant stress. Second, loss of PPARa leads to abnormal fatty acid oxidation and steatohepatitis
- (4) Dysregulation of leptin expression and signaling. -A direct fibrogenic effect of leptin on wound healing has been documented.

### **Matrix degradation<sup>(50)</sup>**

There are broadly two kinds of matrix degradation in liver, pathologic matrix degradation and may therefore worsen liver disease, and restorative matrix degradation that helps in reversion of fibrosis. Matrix-metalloproteinases are calcium-dependent enzymes that specifically degrade collagens and non-collagenous substrates.

As noted, in liver 'pathologic' matrix degradation refers to the early disruption of the normal subendothelial matrix which occurs through the actions of at least four enzymes:

- Matrix metalloproteinase 2 (MMP2) and MMP-9 ('gelatinase A' & 'gelatinase B'), that degrade type IV collagen,
- Membrane-type metalloproteinase-1 or -2, which activates latent MMP2, and
- Stromelysin-1, which degrades proteoglycans and glycoproteins, and also activates latent collagenases.<sup>(43)</sup>

Failure to degrade the accumulated scar matrix is a major reason why fibrosis will progress to cirrhosis. Matrix metalloproteinase- 1 (MMP-1) is presumed to be the



main protease which can degrade type I collagen, the principal collagen in fibrotic liver progressive fibrosis is associated with marked increases in TIMP-1 and TIMP-2. Stellate cells are the major source of these inhibitors.

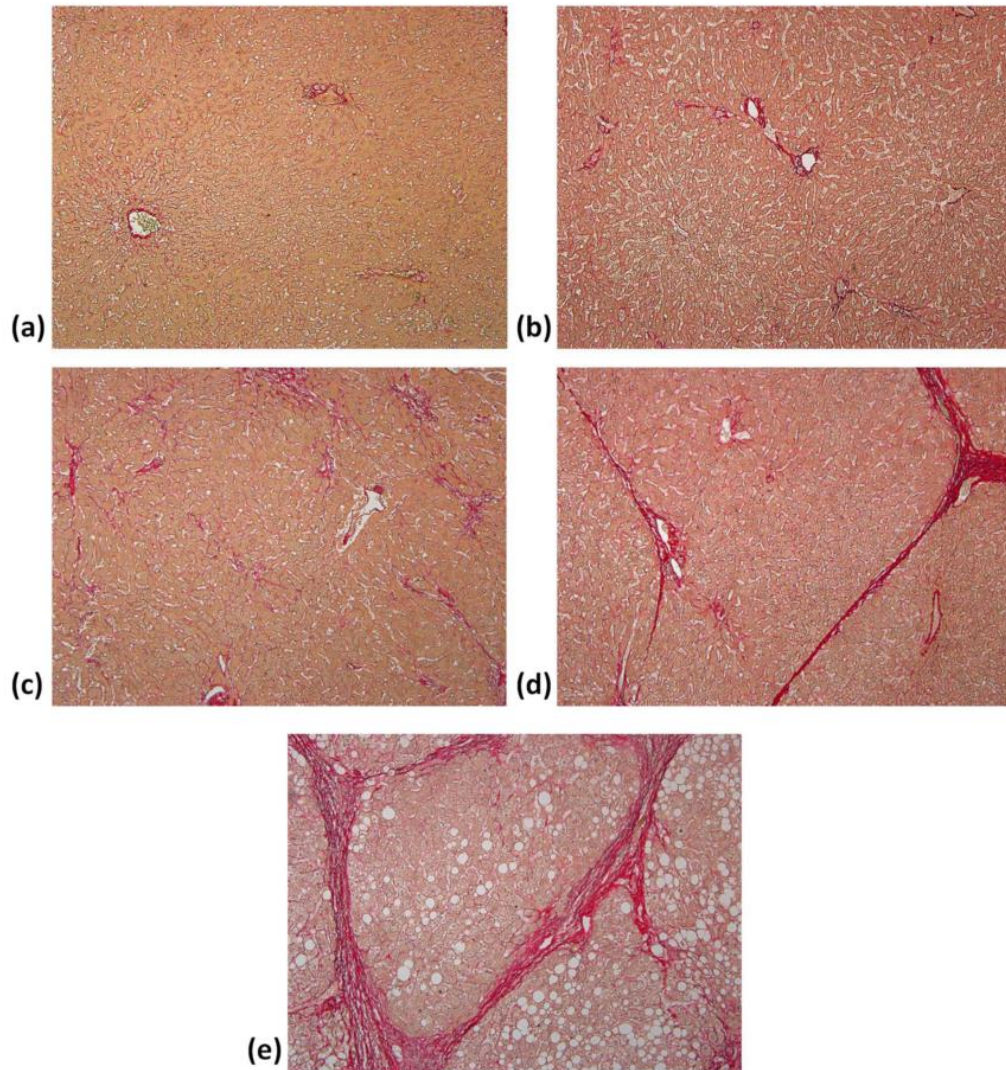
The above molecular changes in liver are manifested as mainly the following histological grades of fibrosis and necro-inflammatory activity according to the French METAVIR scoring system:

Score	Description
F0	No fibrosis
F1	Stellate enlargement of portal tract(portal fibrosis) but without septa formation
F2	Enlargement of portal tract with rare septa formation
F3	Numerous septa without cirrhosis
F4	Cirrhosis

**Table 2 Histological grades of fibrosis according to METAVIR staging.**

Grade	Activity
A0	No inflammation
A1	Mild inflammation
A2	Moderate inflammation
A3	Severe inflammation

**Table 3 Histological grades of activity according to METAVIR staging.**



**FIGURE 7 PR-stained sections (100 magnification) obtained from patients' livers with different degrees of fibrosis from F0 to F4.<sup>(51)</sup>**

**(a) F0: no fibrosis;**

**(b) F1: fibrous expansion of portal areas without septa (i.e., portal fibrosis);**

**(c) F2: portal fibrosis with few septa was observed;**

**(d) F3: fibrous expansion of portal areas with marked bridging or septa (i.e., septal fibrosis);**

**(e) F4: the tissue is composed of nodules surrounded completely by fibrosis (i.e., cirrhosis).**

## **Resolution of liver fibrosis and the fate of activated Stellate cells**

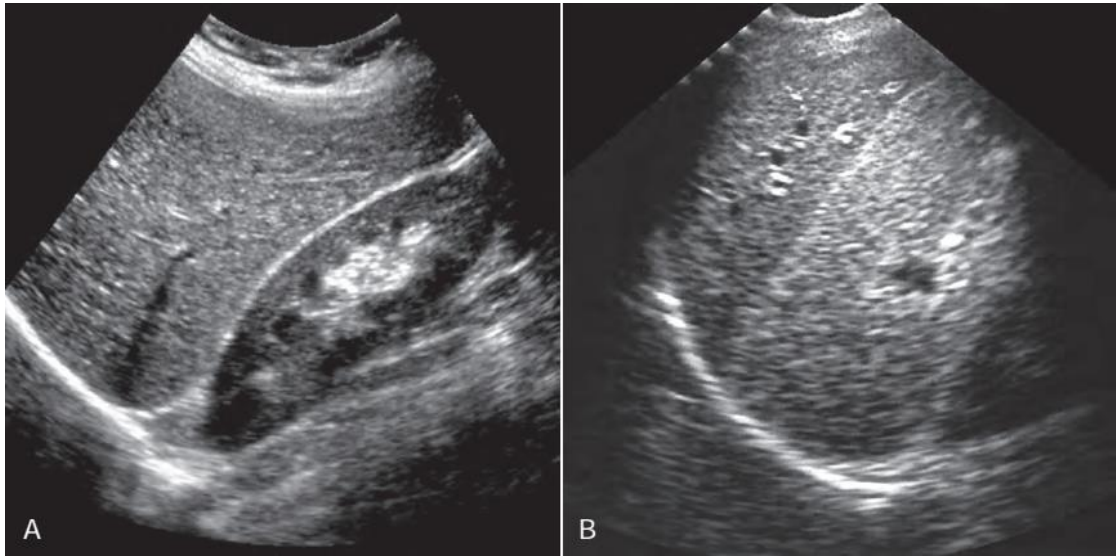
*Reversion* of fibrosis has not been demonstrated in vivo but has been well demonstrated in vitro. *Apoptosis* of HSCs accounts for the decrease of activated stellate cells during resolution of hepatic fibrosis. Recent literature suggests that active MMP2 correlates closely with apoptosis, and in fact may be stimulated by apoptosis.<sup>(47)</sup> Moreover, the fibrotic matrix may provide important survival signals to activated stellate cells. There is importance of apoptosis during reversal of fibrosis by using gliotoxin, a fungal toxin that induces apoptosis in HSCs, possibly by inhibition of NF-κB. In the CC4 model of hepatic fibrosis in rats, gliotoxin decreased the number of HSCs by inducing apoptosis. These data point to acceleration of stellate cell apoptosis as a potential target of antifibrotic therapy.<sup>(52)</sup>

## **Sonographic anatomy of the liver**

Liver is normally visualised sonographically with a curvilinear array 2-6Mhz transducer, if surface nodularity has to be visualised then a linear array transducer with 7-12Mhz can be used. Since it has a broad area of contact with the abdominal wall it is an ideal organ to be sonographically assessed in the abdomen.<sup>(14)</sup> Ideally the liver ultrasound is performed after 6 hours of fasting so that the gall bladder is not contracted. Liver can be approached either subcostally or intercostally, and has to be examined both in supine and right anterior oblique positions. Subcostal oblique view is taken by placing the probe in the epigastric region and then facing it to the tip of the right shoulder. Sagittal, transverse and coronal views are the basic part of the liver sonography.<sup>(53)</sup>

The normal liver parenchyma has a homogenous echotexture with mid-level echoes. It is hyperechoic/isoechoic to the adjacent right renal cortex but hypoechoic to the spleen and the pancreas. The size of the liver is variable and is most commonly

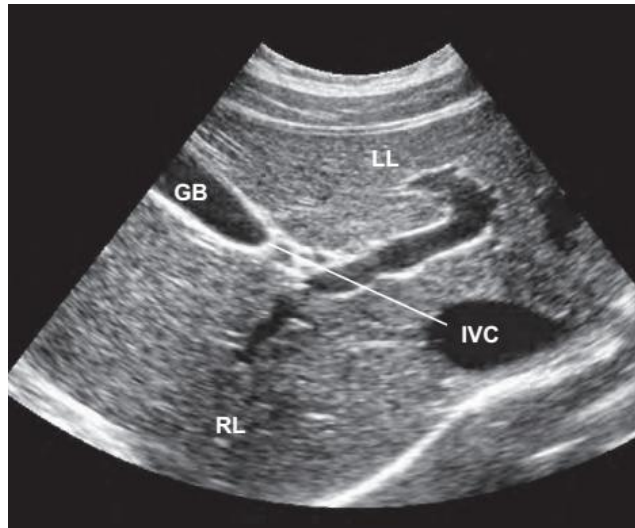
measured in the midhepatic line with 15.5 cm being a criteria for hepatomegaly in 75% of the patients and 13 cm being normal size in 93 % of cases.<sup>(54)</sup> However if the right lobe of liver extends beyond the lower pole of the right kidney or the inferior border is rounded then it can be regarded as hepatomegaly.<sup>(55)</sup>



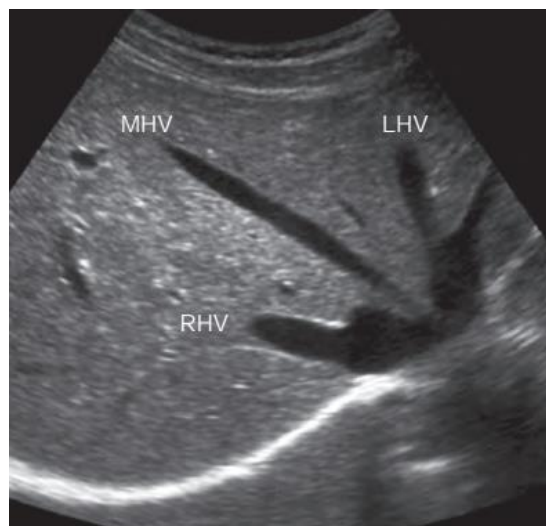
**Figure 8 A. Normal liver hypoechoic to the right renal cortex**

**Figure 8 B. Normal liver hypoechoic to the spleen**

The main lobar fissure divides the liver into two lobes namely the right and the left lobes. It is represented by a line joining the gall bladder and inferior vena cava. The segmental anatomy of the liver can be assessed on ultrasonography by placing the transducer in the relevant positions and appropriately sweeping it in anteroposterior and craniocaudal directions. To localise the lesions in the liver a detailed understanding of the segmental anatomy is of utmost importance and it is based on the hepatic vasculature.



**Figure 9 The main lobar fissure (White line) dividing the right and left lobe of the liver LEFT LOBE(LL), Right Lobe (RL), Gall bladder(GB) and Inferior Vena Cava (IVC)**



**Figure 10 Sub-costal view showing the hepatic veins**

## HISTORY AND EVOLUTION OF ELASTOGRAPHY

Palpation of the abdomen is a basic clinical examination method without which the abdomen examination is incomplete and has been in use since 3000-2500 BC by Imhotep an ancient Egyptian physician.<sup>(56)</sup> What if the palpation could be quantified? Elastography answers this basic thought. In Siemens ultrasound machines the ARFI technology is called the “Virtual Touch Tissue Quantification”.

There are various imaging modalities ranging from the conventional radiography to multislice computed tomography and Magnetic resonance imaging which can be used to assess the cross sectional anatomy of human body which give us a detailed understanding of the anatomical structures. Of these ultrasonography is an imaging modality that can be used to study the cross sectional anatomy in real time and can be repeated as many times as required. Even with its inherent limitations it has been widely used in almost every clinical setting.

*Compression sonography* came up based on compressibility of tissues for e.g. In diagnosis of deep vein thrombosis a patent vein is easily compressible whereas the one with a thrombus within is either partially or completely compressible. *Echopalpation* which is also a sonographic manipulation technique is performed by compressing the lesion with a finger and observing it on a grayscale ultrasonography for local compressibility of the tissue or a lesion. *Fremitus* is another such manoeuvre where the patient is asked to make a humming sound and then the vibrations transmitted to the lesion are visualised as a difference in colour uptake on colour Doppler where a stiff lesion appears black compared to the softer tissues taking up the colour. All these methods are one of the primitive ultrasonographic techniques of elastography.

With advancements in technology Tristram M et al<sup>(57)</sup> in 1986 were the first to quantify the tissue movement in vivo using the A-scan images which were obtained in succession and the displacements in liver and abdominal tumours caused by primary cardiac movement were measured. Soon *sonoelastography* was developed by Lerner RM et al<sup>(58)</sup> for detecting tissue elasticity; with the use of low frequency vibrations(10-10,000 Hz) applied externally they were able to map the tissue elasticity using Doppler colour flow mapping.

In 1991 Ophir J et al<sup>(59)</sup> were the first to quantify the strain and elastic modulus distribution in soft tissues using tissue phantoms and animal tissues and further emphasized on its potential clinical applicability. The technique was named the *strain elastography*; Which was later used for the prostate cancer specimens in 1995 by Rubens DJ et al<sup>(60)</sup> and for in vivo breast lesions in 1997 by Garra BS et al<sup>(61)</sup>. *Strain elastography* is a static elastographic method and it was soon superseded by the newer dynamic elastographic methods such as the transient elastography and shear wave elastography. Transient elastography was first introduced by Catheline and Fink in 1999 for A-mode and then it was extended to 2-D transient elastography by Sandrin et al in the same year. Further in 2002 Kathryn Nightingale et al<sup>(62)</sup> developed the acoustic radiation force impulse imaging which is now being utilised under the proprietary brand name VTTQ (virtual touch tissue quantification) implemented in the SIEMENS ultrasound machines.

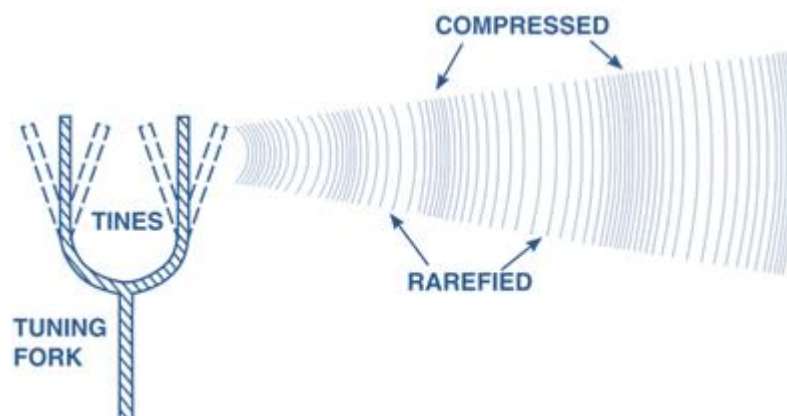
## Technique of Acoustic Radiation Force Impulse Elastography

Acoustic Radiation Force Impulse elastography is a technique that is used to determine the stiffness of a tissue in question. Tissues that were studied in developing the technique included kidney, spleen, uterus, ovary, breast lumpectomy specimens, thyroid and prostate.<sup>(62)</sup> It is a real-time 2D elastography technique and is advantageous over the Fibroscan (transient elastography technique).

### Physics

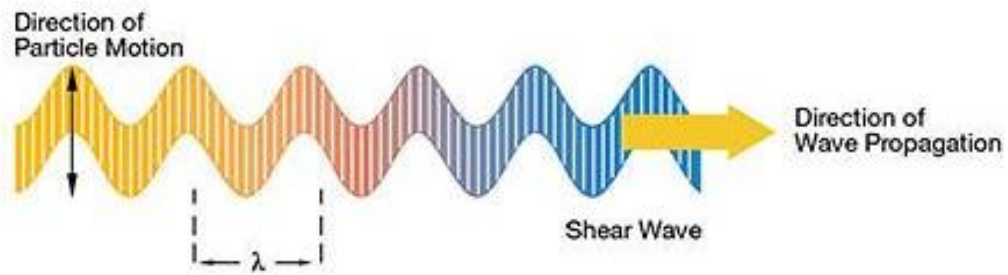
The technique is mainly based on the generation of the shear waves by sending acoustic push pulses to a selected region of interest and then measuring these shear wave velocities to determine the stiffness of the tissue. Unlike the transient elastography it does not require a dedicated ultrasonic probe that induces mechanical compression. It can be performed using the standard curvilinear probe itself.

The acoustic waves are longitudinal waves consisting of a compression and rarefaction components which are due to the adiabatic compression and decompression of the medium in which they propagate.



**Figure 11. Acoustic waves: Longitudinal waveform**





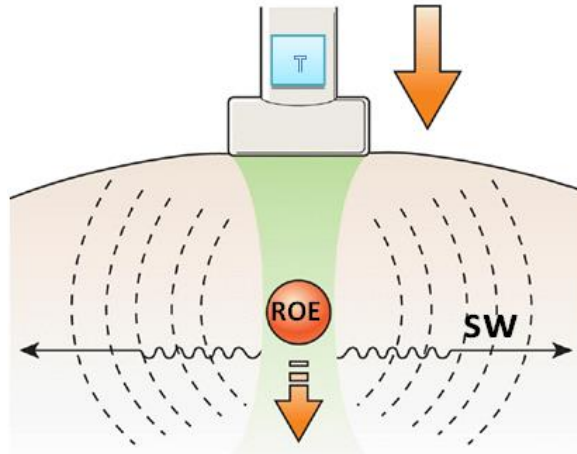
**Figure 12. A shear wave model <sup>(63)</sup>**

The ability of these acoustic waves to distort a medium such as soft tissue is manipulated to produce local distortion and the same is measured in terms of shear wave speeds which are indicative of a tissues' elasticity. Practically the Young's modulus is the quantitative measure of elasticity and the range of values can be used to attribute to a tissue as soft and hard respectively alongside a colour map similar to the one used in color Doppler.

The unique principle used in the ARFI elastography involves focussing acoustic radiation force to a focal spot called as the region of excitation (ROE). The acoustic waves are generated by the commonly used ultrasound transducers for instance 4C1 transducer used in the SIEMENS ACUSON S3000. Using complex mathematical calculations and a fluid model for the soft tissues the magnitude of the acoustic radiation force that is focussed in a soft tissue is calculated as follows, considering most of the attenuation from a soft tissue is mainly because of the absorption and the scattering effects are negligible.<sup>(64,65)</sup>

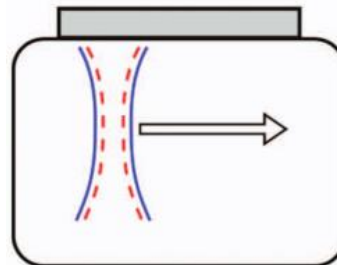
$$F = 2 \frac{\alpha I}{c_L}$$

Where **F** is magnitude of the radiation force, **α** is the absorption coefficient of the tissue, **c<sub>L</sub>** is the speed of sound in the tissue and **I** is the average local temporal intensity of the acoustic beam.



**Figure 13. Exciting a region with acoustic radiation force. Transducer (T) Region of excitation(ROE) Shear wave (SW)** <sup>(66)</sup>

The ARFI pulse sequence is composed of a tracking pulse and a push pulse. Push pulses are single pulses that are short duration pulses typically of 3-5 ms; sent at a frequency between 5-10kHz. The tracking pulses are the conventional ultrasound pulses. Both these pulses are aligned in the same axis.<sup>(66)</sup>



**Figure 14. Tracking Pulse (Blue line) and Push Pulse (Red dotted line) aligned in same axis** <sup>(65)</sup>

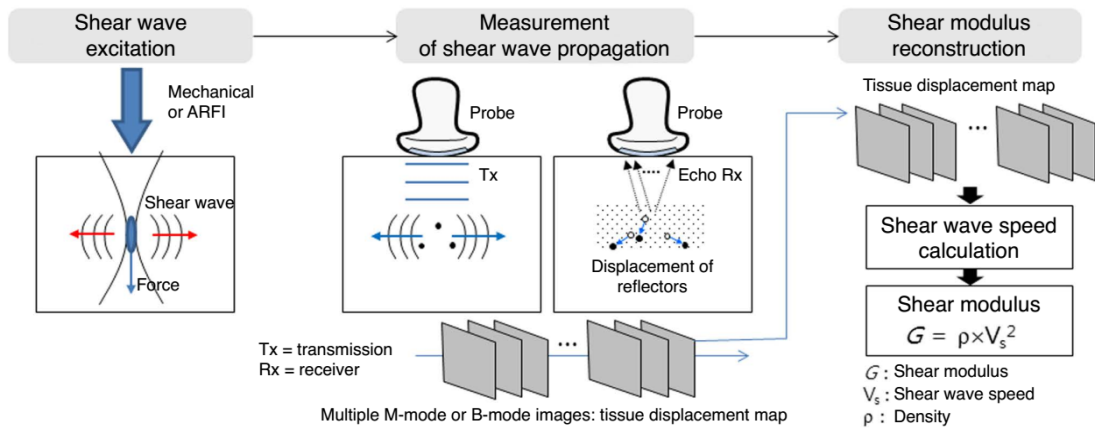
Once the shear waves are generated by excitation of a region, a box of predetermined size (0.5 x 1.0 cm) is selected where the propagating shear wave velocity is measured by comparison of the different data sets of the ultrasound signals used in the 2D ultrasound image formation to create a shear modulus reconstruction of the image and then a shear wave speed is calculated. For a given excitation the wavelength of the shear wave generated is constant. Thus shear wave speed is denoted as

$$V_s = \sqrt{\frac{G}{\rho}}$$

$V_s$ - Shear wave velocity

$G$ -Shear modulus

$\rho$ - Tissue density.



**Figure 15 Overview of Shear wave based elastography.** <sup>(66)</sup>

Frequency	2–7 MHz
F-number	F-2
Intensity( $I_{sppa.5}$ ) <sup>*</sup>	1400 W/cm <sup>2</sup>
Intensity( $I_{spta.3}$ )	0.7 W/cm <sup>2</sup>
Mechanical Index	1.5–3.0
Pulse Duration	0.1–0.5 ms
Temperature Rise	0.02–0.2°C
Displacement (peak)	10–20 μm

**Table 4 Typical parameters used for ARFI imaging** <sup>(64)</sup>

However, the practical applicability of these physical principles is different and is based on some basic assumptions about the tissues in vivo. The assumptions made are that the tissues are<sup>(67)</sup>:

**Linear-** When a tissue is compressed, the stress induced is directly proportional to the strain that is generated in the tissues. Which is partly true in vivo,

and simplifies computations. However, Linearity assumption fails as the force-deformation relationship varies as a function of stress. The tissue stiffness increases with compression,

**Elastic-** tissue deformation is independent of the differential stress applied and returns to its equilibrium state.

**Isotropic-**

The tissue is homogenous or symmetrical and response to stress is equal in all the directions.

But the assumption that tissue is isotropic (homogeneous) is does not hold true at tissue interfaces, and hence reflection of shear waves at tissue interfaces leads to inconsistent measurements.

**Incompressible-**

When certain amount of stress is applied to the tissues there is no alteration in the net volume of the tissue.

## **Elastography in Liver**

In 2007 Jayant Talwalkar et al<sup>(68)</sup> conducted a systematic review and meta-analysis of the ultrasound based transient elastography for detection of hepatic fibrosis and then came up with nine studies which were published in full. Further, they concluded transient elastography as a useful clinical test for detection of liver cirrhosis and that the role of transient elastography has already been well established in diagnosis and staging of liver fibrosis. However, they observed a diagnostic threshold (or cut-off value) bias which was responsible for heterogeneity of pooled results in patient groups.

### Normal Shear Wave Velocities of the Liver

Gerald Kircheis et al<sup>(69)</sup> in 2012 observed in 606 patients with various aetiologies of liver disease, that “an ARFI-SWV cut-off value of 1.29 m/s was normal {Sensitivity(Se) 91.4% and Specificity (Sp) 92.6%} for patients with no significant liver fibrosis and 1.60 m/s for patients with liver cirrhosis (Se-92.3% and Sp-96.5%) using transient elastography as reference. In 68 patients the liver biopsy was used as a reference and the optimal cut offs suggested for predicting liver fibrosis ( $F \geq 2$ ) was 1.32 m/s (Se-87.0% and Sp- 80.0%) and for liver cirrhosis (F4) 1.62 m/s (Se- 100% and Specificity Sp-85.7%). They also observed an excellent correlation for inter-and intraobserver reproducibility for ARFI-SWV measurements.

Rajneesh Madhok et al<sup>(70)</sup> in 2013 measured normal mean values of shear wave velocities in healthy liver and the mean liver stiffness value which was obtained by ARFI in the 137 healthy subjects was 1.197 m/s, and They found no significant difference between the mean ARFI values in men vs. women ( $1.195 \pm .25$  vs.  $1.199 \pm 0.26$  m/s,  $p = 0.939$ ) and among the different age groups.

AGE GROUP	FREQUENCY	MEAN VALUE
20-30	45	1.192±0.24
30-40	42	1.184±0.26
40-50	15	1.260±0.23
50-60	3	1.20±0.24
60-70	3	1.106±0.24

**Table 5 Shear Wave Velocities in different age groups**

In a study conducted in the year 2013 by Babita Raghuwanshi, Niti Jain & Manish Jain<sup>(71)</sup> the normal range of liver stiffness in 52 healthy volunteers (8 women,

44 men; mean age, 37.52 years; range, 14–61 years) of Indian population was in the range of **1.0-1.29 m/s**. They found a statistically significant difference ( $p < 0.05$ ) between the mean shear wave velocity values in deep right lobe of the liver and the values obtained on the surface of the right lobe (1.2 vs 1.05 m/s) and between the mean values obtained deep in the right lobe and those obtained deep in the left lobe (1.2 vs 1.0 m/s).

In 2016 Kim JE et al.<sup>(72)</sup> in their study of 521 subjects to assess the diagnostic performance of ARFI elastography in liver suggested mean shear wave velocities of the normal liver group as 1.08 m/s  $\pm$  0.15 (n=133); the fatty liver group, 1.02 m/s  $\pm$  0.16 (n=95); and of the chronic liver disease group, 1.66 m/s  $\pm$  0.60 (n=293) ( $p < 0.001$ ). They reported a significantly higher sensitivity of the mean SWV than the US-based scores ( $p < 0.001$ ), although the specificity was not ( $p > 0.05$ ). The mean SWV was better correlated with Child-Pugh scores and all liver function tests (except total protein) than the US-based scores from two radiologists.

## **ROLE OF ARFI ELASTOGRAPHY IN CHRONIC LIVER DISEASE OF VARIOUS ETIOLOGIES**

Fierbinteanu-Braticevici C. et al.<sup>(73)</sup> in 2009 studied the usefulness of ARFI as a non-invasive tool for assessment of liver fibrosis in 74 chronic hepatitis C patients. They observed a good correlation with the liver biopsy results. They concluded that ARFI elastography has very good accuracy for the assessment of liver fibrosis as area under receiver operating characteristic curve (AUROC) had a validity of 90.2% (95% CI AUROC = 0.831-0.972,  $P < 0.001$ ) for the diagnosis of significant fibrosis ( $F \geq 2$ ). ARFI sonoelastography predicted even better F3 or F4 fibrosis (AUROC = 0.993, 95% CI = 0.979-1) and was superior to other non-invasive methods (APRI Index, FibroMax) for staging liver fibrosis.

Sporea I. et al<sup>(74)</sup> in 2011 studied 274 subjects of chronic hepatitis C patients and found that a direct, strong, correlation (Spearman coefficient= 0.707) between ARFI measurements and fibrosis ( $P < 0.0001$ ) exists. For predicting the presence of fibrosis ( $F \geq 1$  METAVIR), significant fibrosis ( $F \geq 2$ ), severe fibrosis ( $F \geq 3$ ) and cirrhosis ( $F = 4$ ), the cut-off values of 1.19, 1.21, 1.58 and 1.82 m/s were determined, respectively, liver stiffness measurements had 73%, 84%, 84% and 91% Sensitivity respectively; 93%, 91%, 94%, 90% Specificity respectively; with AUROCs of 0.880, 0.893, 0.908 and 0.937, respectively. They concluded that ARFI measurement is a reliable method for predicting the severity of fibrosis in HCV patients.

Mark L. Palmeri et al<sup>(75)</sup> in 2011 noted that in 174 patients of NAFLD the shear stiffness distinguished low (fibrosis stage 0–2) from high (fibrosis stage 3–4) fibrosis stages with a sensitivity of 90% and a specificity of 90% (AUROC of 0.90). Shear stiffness also had a mild correlation with APRI (Coefficient of determination  $R^2=0.05$ ) and no correlation was noted between BMI and shear stiffness ( $R^2=0.22$ ).

Xiao-Ping Ye et al<sup>(76)</sup> in 2012 studied 138 chronic hepatitis B patients and their measured liver stiffness cut-off values were 1.69 m/s for predicting liver fibrosis of stage 3 or greater (AUROC = 0.99) and 1.88 m/s for stage 4 (AUROC = 0.97). However for the stage 2 and below the cut off values overlapped between the stages.

X.Sun et al<sup>(77)</sup> in 2015 undertook a study to assess the reserve function of liver using ARFI elastography in 76 patients with liver tumors and observed that the higher the *Liver Stiffness* (LS) value, the worse the liver reserve function and prognosis after surgery. They also observed a positive correlation of LD with *Indocyanin green retention after 15 min* (ICG-R15) ( $r = 0.617$ ,  $P < 0.01$ ) and *Child-Pugh* score ( $r = 0.772$ ,  $P < 0.01$ ). Meanwhile, LS negatively correlated with *Indocyanin green*

*clearance rate* (ICG-K) ( $r = -0.673$ ,  $P < 0.01$ ). AST, ALT and total bilirubin positively correlated with LS, while albumin was negatively correlated with LS ( $P < 0.05$ ). And, a LS value greater than 2.34 m/s suggested poor liver reserve function where non-surgical treatment is recommended (Se= 69.2% and Sp = 92.1%).

## **COMPARISON OF ARFI ELASTOGRAPHY AGAINST OTHER METHODS**

In another study by Sporea I. et al<sup>(78)</sup> in 2011, which compared the efficacy of ARFI against the use of TE in 223 subjects and concluded that the best test for predicting significant fibrosis ( $F \geq 2$ ) was TE with a cut-off value of 7.1 kPa (AUROC 0.953) . A strong linear correlation (Spearman rho = 0.870) was found between TE and fibrosis ( $P < 0.0001$ ); However, there was a weaker correlation between ARFI and fibrosis (Spearman rho = 0.646;  $P < 0.0001$ ). For ARFI, the cut-off value for predicting significant fibrosis was 1.27 m/s { AUROC- 0.890, Se: 88.7%, Sp: 67.5%, PPV: 64.5%, and NPV: 90% ( $P = 0.0044$ )}. For predicting cirrhosis ( $F = 4$ ), the optimum cut-off values were 14.4 kPa for TE (AUROC: 0.985, Se: 95.6%, Sp: 94.7%, PPV: 89.2%, NPV: 98%) and 1.7 m/s for ARFI (AUROC: 0.931, Se: 93%, Sp: 86.7%, PPV: 73.6%, NPV: 96.9%) ( $P = 0.0102$ ).

S. Bota et al<sup>(79)</sup> in 2011 conducted a study to assess the feasibility of performing ARFI elastography in 153 patients with ascites and found that for a cut-off value of 1.8 m/s for predicting cirrhosis, ARFI method had 98.1% sensitivity, 86.2% specificity, 96.4% positive predictive value, 92.5% negative predictive value and 95.6% accuracy for predicting cirrhotic ascites. For a cut-off value of 1.9 m/s the accuracy was 94.9% and for a 2 m/s cut-off value it was 92.8%. Thus they concluded it was feasible to utilise ARFI elastography in patients with ascites.



In 2013 J.Doherty et al<sup>(65)</sup> the biomedical engineers from Duke university in their review on soft tissue mechanics relevant to elasticity imaging, emphasized that the acoustic radiation force impulse elastography had an added advantage of being able to image the liver in patients with ascites which is not possible with cutaneous mechanical methods used such as the transient elastography.

In 2012 a study was conducted by O S Jaffer et al<sup>(80)</sup> to assess the repeatability of ARFI in 10 healthy volunteers (Mean age 31 years, 5-males & 5- females) found that with trained operators, ARFI is a reliable (Cronbach statistic value  $\geq 0.7$ ) and reproducible method of liver stiffness quantification in segments 5/6 and 7/8 but acquisition of measurements from segment 3 is unreliable (Cronbach statistic value  $< 0.7$ ). Values obtained deeper to the liver capsule are more reliable for liver stiffness quantification; since there was a negative correlation between the liver capsule to box distance (segment 5/6,  $r = -0.08$ ; segment 7/8,  $r = -0.06$ ;  $p < 0.001$ ).

F.Rust et al<sup>(81)</sup> in 2012 observed the diagnostic accuracy for TE measurements in with the M- and XL-probe and for ARFI of the right and left liver lobes of 57 patients of NAFLD as 0.73, 0.84, 0.71 and 0.60 for the diagnosis of severe fibrosis, and 0.93, 0.93, 0.74 and 0.90 for the diagnosis of cirrhosis, respectively. They also found *no significant difference of results between TE and ARFI in the subgroup of patients where TE measurement was possible*. However, a significant correlation was found for TE with histological liver fibrosis, and the correlation of ARFI with liver fibrosis was not statistically significant. They also described a novel Controlled Attenuation Parameter (CAP) to assess steatosis grading. The optimal cut-off was 245 dB/m for the diagnosis of steatosis grade  $\geq S2$  with a sensitivity of 97% and a specificity of 67% & 301 dB/m, for the diagnosis of steatosis grade S3 with a sensitivity of 76% and a specificity of 68%, and 303 dB/m for the diagnosis of

NAFLD activity score > 4 with a sensitivity of 74% and a specificity of 67%, respectively.

Fontanilla et al<sup>(82)</sup> in 2014 conducted a prospective study that included 60 healthy patients. They measured the shear wave speeds using both 4C1 & 9L4 transducers and observed no significant difference (For 4C1:  $t=0.917$ ,  $P=0.363$  For 9L4  $t=1.471$ ,  $P=0.147$ ) between the use of either probes. Age had a small effect on shear wave measurements (For 4C1:  $F=2.81$ ,  $p=0.048$  for 9L4:  $F=8.54$ ,  $p<0.001$ ). Body mass index and sex had no significant effects on ARFI values (For 4C1:  $p=0.953$  & for 9L4:  $p=0.100$ ). They also suggested reference values of Mean shear wave velocity in the right lobe as  $1.19 \pm 0.04$  m/s (SD 5 0.13) with the 4 C1 transducer and  $1.15 \pm 0.04$  m/s (SD 5 0.15) with the 9 L4 transducer.

Simona Bota et al<sup>(83)</sup> in 2013 did a meta-analysis comparing the ARFI elastography against transient elastography with the data available in the PubMed, Medline, Lilacs, Scopus, Ovid, EMBASE, Cochrane and Medscape databases. They included a total of 13 studies that together consisted of 1163 patients with chronic liver diseases. The diagnostic odds ratio of ARFI and TE did not differ significantly in the detection of significant fibrosis [mean difference in rDOR = 0.27 (95% CI: 0.69–0.14)] and cirrhosis [mean difference in rDOR = 0.12 (95% CI: 0.29–0.52)]. They also observed that the inability to obtain reliable measurements was more than thrice as high for TE as that of ARFI (Odds ratio-6.6% vs. 2.1%,  $P < 0.001$ ). *Upon this they concluded "Acoustic radiation force impulse elastography to be a good method with higher rate of reliable measurements and similar predictive value to TE for significant fibrosis and cirrhosis".*

	<b>Transient Elastography</b>		<b>Acoustic radiation force impulse elastography</b>	
<b>Inability to measure the liver stiffness values (P &lt; 0.001)</b>	6.6%		2.1%	
	<i>Sensitivity (%)</i>	<i>Specificity (%)</i>	<i>Sensitivity (%)</i>	<i>Specificity (%)</i>
<b>Detection of significant fibrosis, (F ≥ 2)</b>	0.78	0.84	0.74	0.83
<b>For the diagnosis of cirrhosis</b>	0.89	0.87	0.87	0.87
<b>The Mean difference in diagnostic odds ratio for Detection of significant fibrosis, (F ≥ 2)</b>	0.27			
<b>The Mean difference in diagnostic odds ratio For the diagnosis of cirrhosis</b>	0.12			

**Table 6 Comparison of Diagnostic performance of Transient Elastography & Acoustic radiation force impulse elastography.**

A pooled meta-analysis of studies done on ARFI elastography was conducted by Friedrich-Rust M et al<sup>(84)</sup> in the year 2012 where they obtained data for 518 patients from eight studies and suggested the optimal cut-off for the diagnosis of significant fibrosis as 1.34 m/s, 1.55 m/s for severe fibrosis and 1.80 m/s for the diagnosis of liver cirrhosis. The sensitivity specificity, PPV and NPV for these cut off values is presented in the table below.

<b>ARFI</b>	<b>AUROC</b>	<b>Cut-off (m/s)</b>	<b>Sensitivity (%)</b>	<b>Specificity (%)</b>	<b>PPV (%)</b>	<b>NPV (%)</b>	<b>+LR</b>
<b>F ≥ 2</b>	0.87	1.34	79	85	91	66	5.07
<b>F ≥ 3</b>	0.91	1.55	86	86	82	89	5.94
<b>F = 4</b>	0.93	1.80	92	86	71	97	6.72

**Table 7** *Cut off values for shear wave velocity to quantify liver fibrosis.*

In 2013 D'Onofrio M et al<sup>(8)</sup> reviewed several studies (26 studies on normal subjects & 22 studies on patients with liver fibrosis) and concluded that ARFI is a very reliable and successful imaging modality even in obese patients whereas the same is not the case with the transient elastography technique.

L.Rizzo et al<sup>(85)</sup> et al in 2011 compared the TE versus ARFI methods to measure liver stiffness in a cohort of 139 chronic hepatitis C patients and observed that the ARFI technique was better in diagnosing both the significant and severe fibrosis by partial AUROC analysis (Concordance rate for TE-45.4% and for ARFI-54.7%). In 6.5% of their study population TE was unreliable in contrast to ARFI being reliable (P=0.029) in all the study subjects. The best cut-off values for TE and ARFI for significant fibrosis (≥F2) were ≥6.5 kPa (AUROC: 0.78) and ≥1.3 m/s (AUROC: 0.86), respectively. For severe fibrosis (F3-F4), these cut-off values were 8.8 kPa (AUROC: 0.83) for TE and 1.7 m/s (AUROC: 0.94) for ARFI. For cirrhosis, TE had its best cut-off at ≥11 kPa (AUROC: 0.80) and ARFI at ≥2.0 m/s (AUROC: 0.89).

V.Leung et al<sup>(86)</sup> in 2013 compared the shear wave elastography with the Transient Elastography and concluded that "real-time shear wave elastography provides more accurate correlation of liver elasticity with liver fibrosis stage compared with transient elastography (P = 0.01–0.04), especially in identification of stage F2 or greater". Since SW elastography of liver had higher successful rate than

transient elastography of liver (98.9% vs. 89.6%). They also used a Combination SW elastography of liver and SW elastography of spleen to predict fibrosis staging which showed that diagnostic accuracy did not further improve when compared with SW elastography of liver alone (similar AUC;  $\geq$ F1, P = 0.87;  $\geq$ F2, P = 0.81;  $\geq$ F3, P = 0.84;  $\geq$ F4, P = 0.88)

Bota S et al<sup>(87)</sup> in 2014 showed in their meta-analysis which included 1031 patients with or without CLD that Reliable LS measurements by means of ARFI elastography were obtained in 93.3% of cases. The risk factors were associated with failed and unreliable measurements were age over 58 years (OR = 0.49; 95% CI 0.30–0.80, p = 0.005), male gender (OR = 0.58; 95% CI 0.34–0.94, p = 0.04), BMI > 27.7 kg/m<sup>2</sup> (OR = 0.23, 95% CI 0.13–0.41, p < 0.0001). In multivariate analysis all the factors mentioned above were independently associated with the risk of failed and unreliable measurements but their influence is limited in comparison to Transient Elastography.

In 2015 Gerber L et al<sup>(88)</sup> in their study which included 132 patients with chronic hepatopathies, showed that there was no significant difference in AUROCs for 2D-SWE, pSWE, and 1D-TE in the diagnosis of significant fibrosis (F $\geq$ 2: 0.87, 0.92, 0.91), advanced fibrosis (F $\geq$ 3: 0.91, 0.93, 0.94) and liver cirrhosis (F=4: 0.88, 0.90, 0.89), respectively between the three methods. Therefore, 2-D SWE, ARFI imaging and transient elastography seem to be comparably good methods for non-invasive assessment of liver fibrosis.

### **ARFI ELASTOGRAPHY IN ALCHOLIC LIVER DISEASE**

In 2014 D.Zhang et al<sup>(89)</sup> first studied the liver stiffness measurements using ARFI in alcoholic liver disease. The diagnostic accuracies expressed as AUROC

curves for ARFI elastography and APRI were 0.846 and 0.763 for the diagnosis of significant fibrosis ( $F \geq 2$ ), 0.875 and 0.688 for the diagnosis of severe fibrosis ( $F \geq 3$ ), and 0.893 and 0.648 for the diagnosis of liver cirrhosis, respectively. The AUROC values of ARFI elastography were significantly better than those of APRI for predicting severe fibrosis ( $P = 0.02$ ) and cirrhosis ( $P = 0.04$ ). They concluded that "ARFI elastography is an acceptable method for predicting the severity of fibrosis in patients with ALD. ARFI elastography is influenced by elevated aminotransferase levels in ALD".

<i>Stage of Liver Fibrosis</i>	<i>Shear wave velocity in Patients with normal ALT levels</i>	<i>Shear wave velocity in Patients with elevated ALT levels</i>
<b>F&gt;2</b>	1.24 m/s	1.33 m/s
<b>F&gt;3</b>	1.27 m/s	1.40 m/s
<b>F=4</b>	1.41 m/s	1.65 m/s

**Table 8** *Shear wave velocities in patients with and without elevated ALT levels.*

Anita Kiani et al<sup>(90)</sup> in 2016 conducted a study in France among the individuals who had a history high risk alcohol consumption & were undergoing detoxification and determined various cut off values and concluded that it can be used as a useful and easy non-invasive tool to assess liver fibrosis in patients undergoing detoxification.

<i>Stage of Liver Fibrosis</i>	<b>F<math>\geq</math>2</b>	<b>F<math>\geq</math>3</b>	<b>F=4</b>
<b>ARFI cut-off (m/s)</b>	1.63	1.84	1.94
<b>Sensitivity(%)</b>	82.4 (0.70-0.95)	82.4 (0.64-1.00)	92.3 (0.78-1.00)
<b>Specificity (%)</b>	83.3 (0.73-0.94)	78.5 (0.69-0.89)	81.6 (0.72-0.90)
<b>AUROC</b>	0.87	0.86	0.89
<b>PPV (%)</b>	77.8 (0.64-0.91)	50.0 (0.31-0.69)	48.0 (0.28-0.68)
<b>NPV (%)</b>	87.0 (0.77-0.97)	94.4 (0.88-1.00)	98.2 (0.95-1.00)

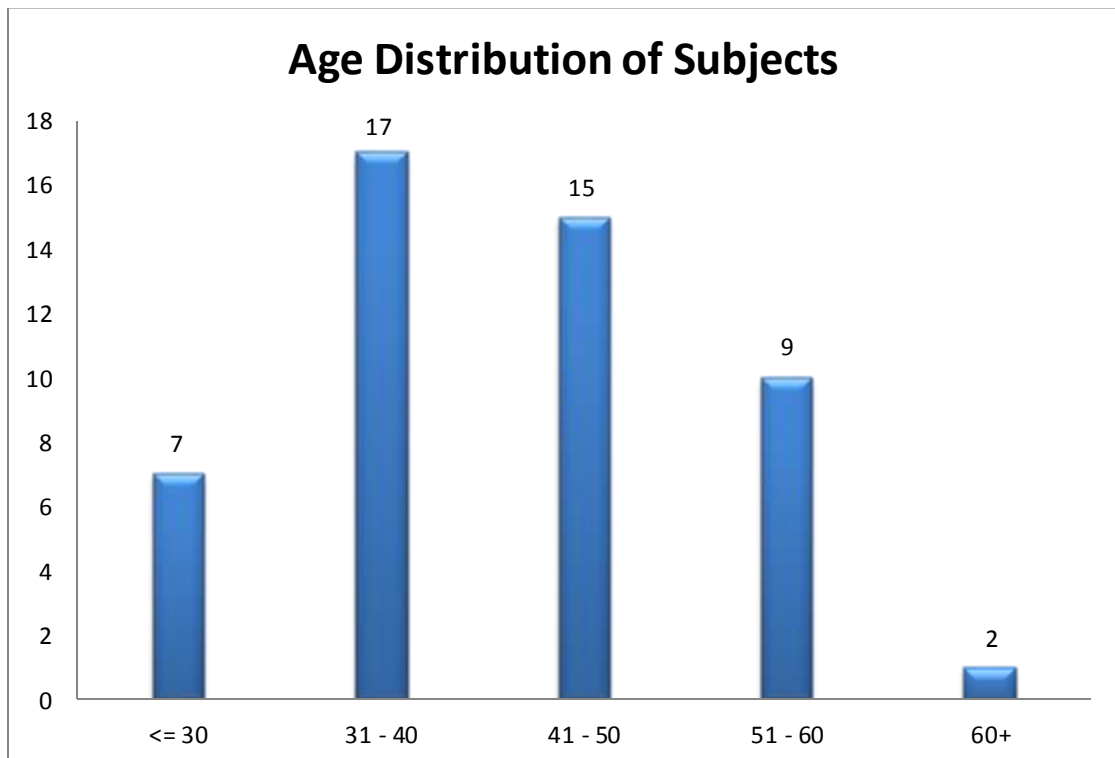
**Table 9** *Diagnostic performance of acoustic radiation force impulse for the different liver fibrosis stages*

## **RESULTS**

A total of 50 cases matched the inclusion criteria in a time period of approximately Two years. Various statistical analyses that help in diagnosis of liver fibrosis are described below:

### **Age distribution:**

The age distribution of the patients in our study ranged from 24 to 62 years with the mean age being  $41.86 \pm 9.81$  years. Maximum subjects (n=17) were in the age group of 31-40 years with only TWO of the subjects in the 7th decade of their life.



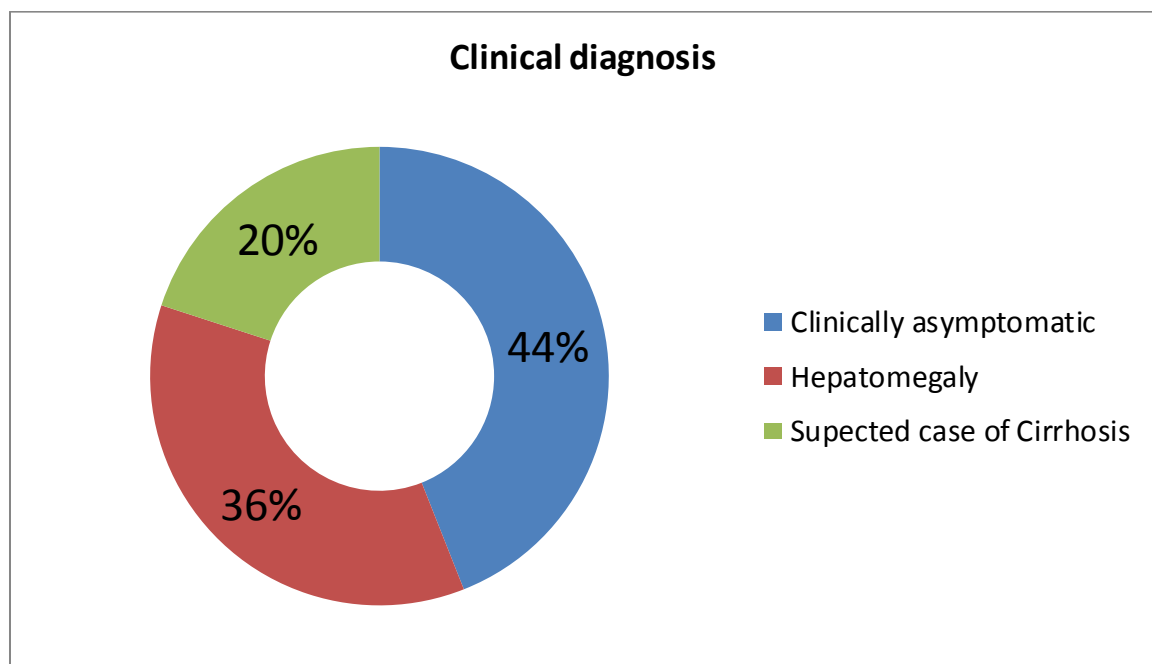
**Figure 16 depicting Bar diagram of age distribution of patients in our study**

**Gender distribution:**

All of the 50 cases studied were males, since we did not encounter any female subjects with high risk consumption of alcohol.

**Distribution of cases according to Clinical Presentation:**

Major group (44%, n=22) of the study subjects were clinically asymptomatic with only history of high risk consumption of the alcohol. 20% of the cases (n=10) did not have an established diagnosis of cirrhosis and had been sent with a suspicion of cirrhosis based on clinical signs viz. Hepatosplenomegaly with clinical signs of ascites, and were referred for evaluation of radiological evidence of cirrhosis. 36% of the cases (n=18) were found to have hepatomegaly with high risk alcoholism.



**Figure 17 Distribution of cases according to clinical diagnosis**



**Distribution of cases according stratified on the basis of APRI Criteria available :**

(91,92)

<b>Stage of fibrosis (Based on APRI)</b>	<b>No. of Patients</b>	<b>Percentage</b>
No Significant fibrosis	35	70.00
Inconclusive for fibrosis	4	8.00
Significant fibrosis	5	10.00
Probable cirrhosis	6	12.00
Total	50	100

**Table 10 APRI grades of fibrosis**

**Distribution of cases according stratified on the basis of FIB-4 Index:** <sup>(92,93)</sup>

<b>Stage of fibrosis (Based on Fib-4)</b>	<b>No. of Patients</b>	<b>Percentage</b>
No Severe fibrosis	31	62.00
Inconclusive for Severe Fibrosis	9	18.00
Severe Fibrosis	10	20.00
Total	50	100

**Table 11 FIB-4 grades of fibrosis**

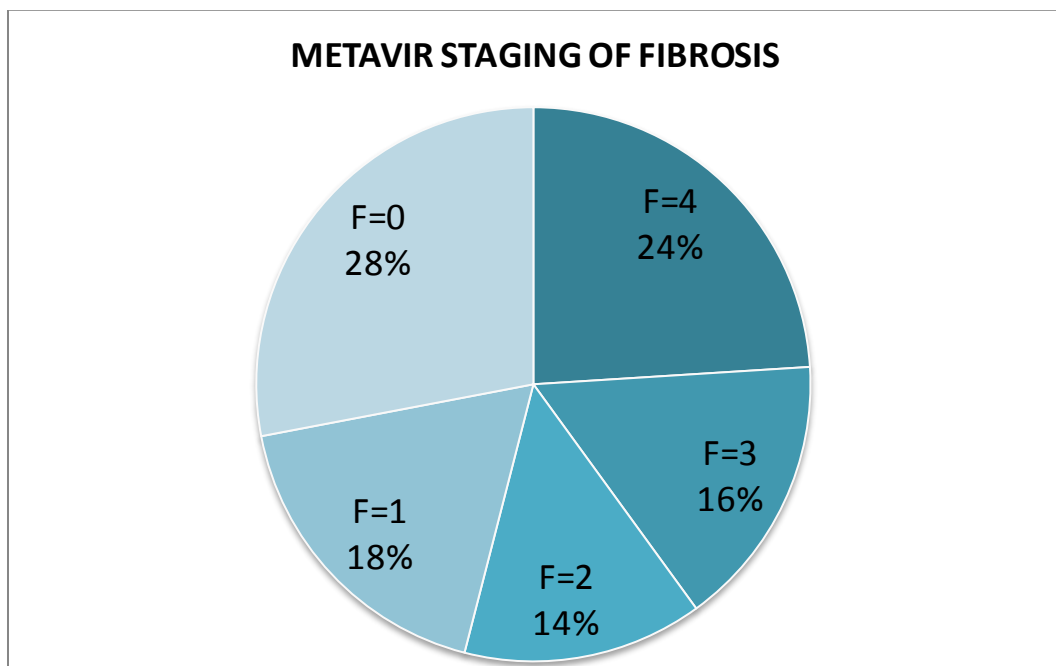
**Distribution of cases according to their pathological stages of Fibrosis:**

Among the 50 subjects with high risk alcohol consumption that we studied, Maximum no of subject (n=14) were histopathologically reported as having no fibrosis corresponding to the stage F=0 of the METAVIR scoring of fibrosis. 24% of

the cases (n=12) were finally diagnosed with cirrhotic (METAVIR F=4) liver biopsy specimen.

<b>Pathological diagnosis</b>	<b>METAVIR staging of fibrosis</b>	<b>Percentage</b>
F=4	12	28
F=3	8	18
F=2	7	14
F=1	9	16
F=0	14	24

**Table 12 Pathological grades of fibrosis**

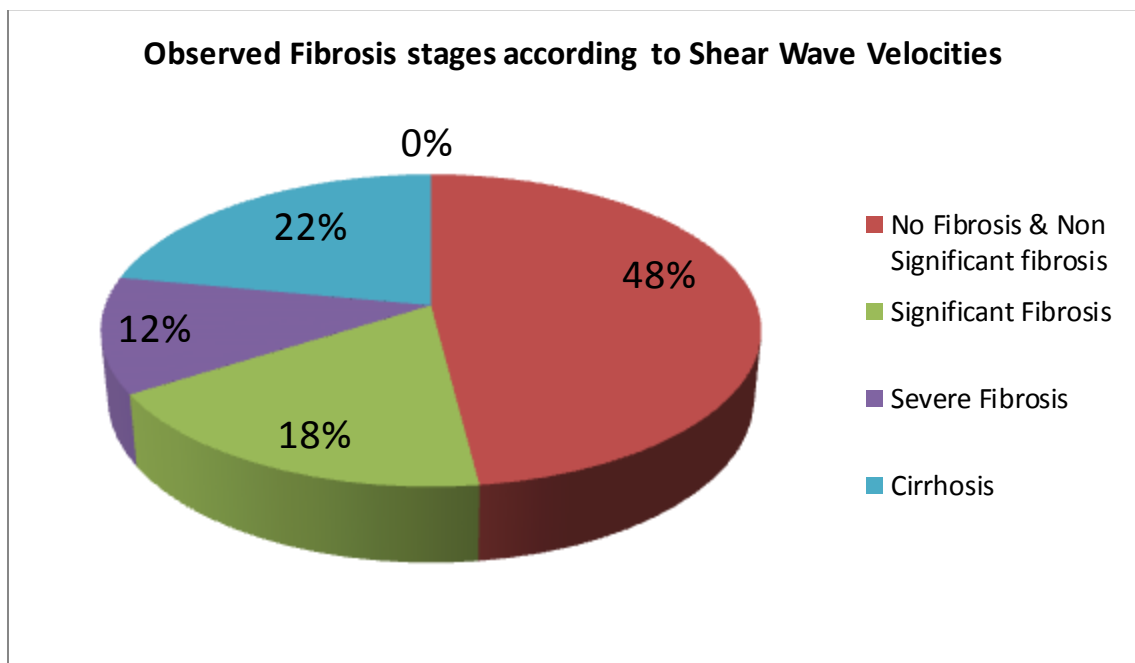


**Figure 18 Distribution of cases based on pathological stages of fibrosis**

**Distribution of cases according to their stages of Fibrosis based on suggested cut-offs by M. Friedrich-Rust et al for Liver Fibrosis:** <sup>(84)</sup>

<b>Stage of fibrosis (Based on shear wave velocities)</b>	<b>No. of Patients</b>
No Fibrosis & Non Significant fibrosis	24
Significant Fibrosis	9
Severe Fibrosis	6
Cirrhosis	11
<b>Total</b>	<b>50</b>

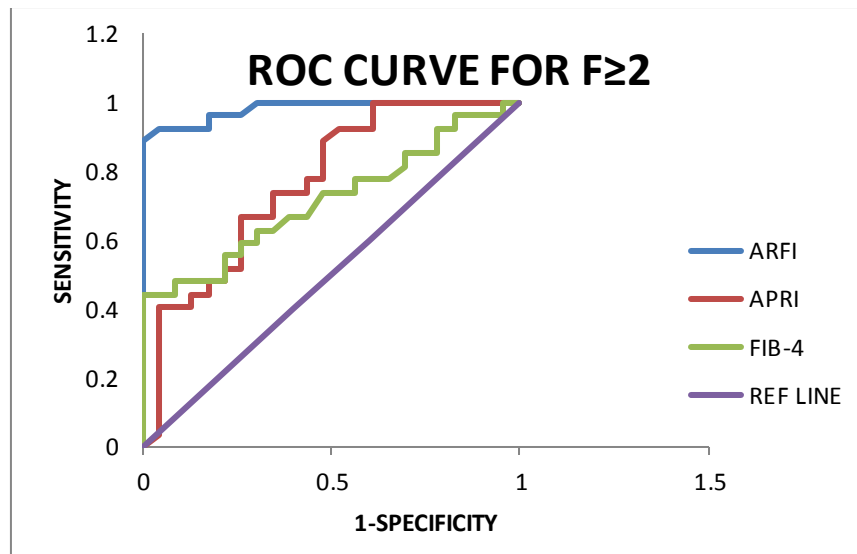
**Table 13 Shear wave elastography grades of fibrosis**



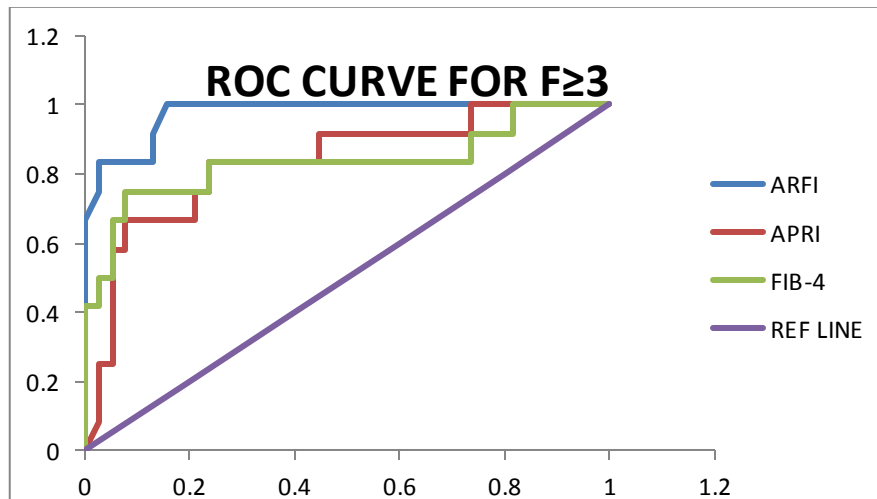
**Figure 19 Distribution of cases based on pathological stages of fibrosis**

**Diagnostic Performance of ARFI elastography based on existing criteria for**

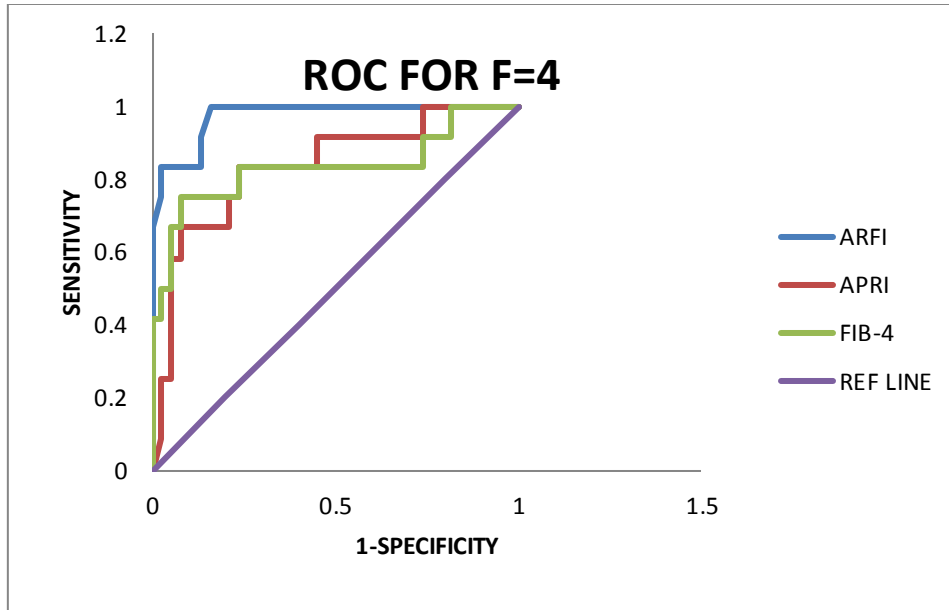
**Liver Fibrosis:**



**Figure 20 Showing AUROC curves using APRI Index (Red Line), ARFI elastography (Blue Line) & FIB-4 index (Green Line) as test curves in diagnosis of Significant Fibrosis & No/Non significant fibrosis considering histopathological outcomes (Liver Biopsy) the standard value curve represented in Purple.**



**Figure 21 Showing AUROC curve using APRI Index (Red Line), ARFI elastography (Blue Line) & FIB-4 index (Green Line) as test curves in diagnosis of Severe Fibrosis & Significant Fibrosis Considering Histopathological outcomes (Liver Biopsy) as the standard value curve represented in Purple.**



**Figure 22 Showing AUROC curve using APRI Index (Red Line), ARFI elastography (Blue Line) & FIB-4 index (Green Line) as test curves in diagnosis of Severe Fibrosis & Cirrhosis Considering Histopathological outcomes (Liver Biopsy) the standard value curve represented in Purple.**

For the sake of comparisons of the different diagnostic tests, the patients have been divided as follows:

<b>Pathological diagnosis (METAVIR Stages)</b>	<b>Number of patients (n)</b>
<b>GROUP A (F=0+ F=1)</b>	23 (14+9)
<b>GROUP B (F=2)</b>	7
<b>GROUP C (F=3)</b>	8
<b>GROUP D (F=4)</b>	12

**Table 14 Grouping of the Cases for comparison**

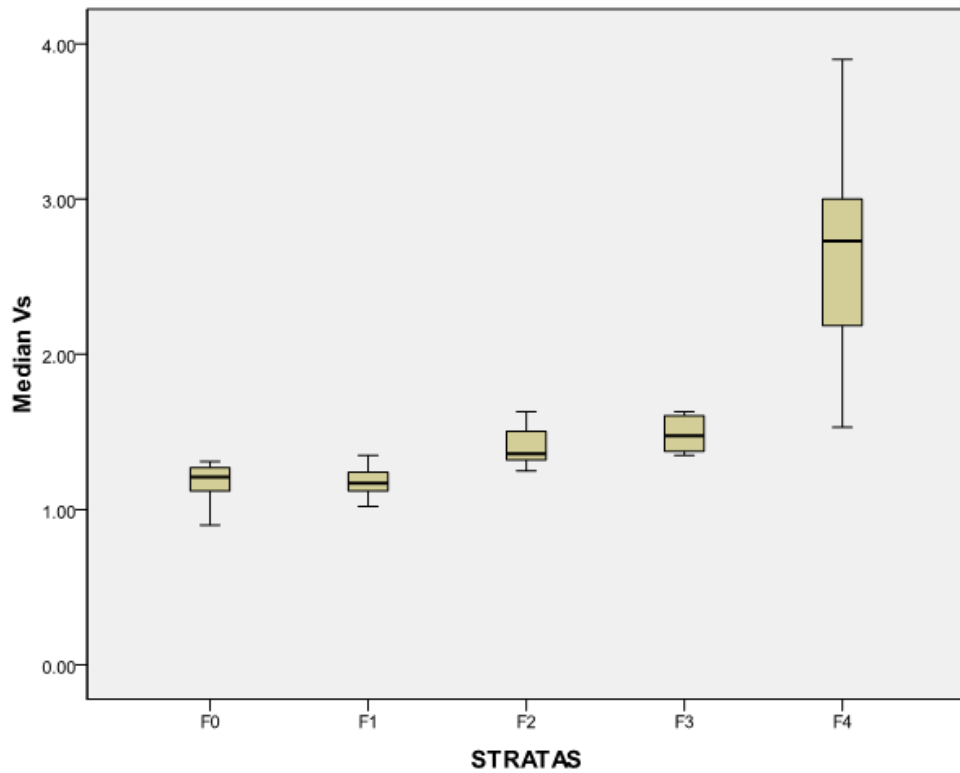
	GROUP A (F=0+ F=1) vs. GROUP B (F=2)			GROUP C (F=3) vs. GROUP D (F=4)			GROUP B (F=2) vs. GROUP C (F=3)		
Patients (n=50)	APRI	Median Vs	FIB-4	APRI	Median Vs	FIB-4	APRI	Media n Vs	FIB-4
Sensitivity	0.52	<b>0.93</b>	0.55	0.83	<b>1.00</b>	0.83	0.65	<b>1.00</b>	0.70
Specificity	0.78	<b>0.96</b>	0.78	0.76	<b>0.63</b>	0.74	0.80	<b>0.80</b>	0.80
PPV	0.74	<b>0.78</b>	0.75	0.53	<b>0.92</b>	0.50	0.68	<b>0.75</b>	0.70
NPV	0.58	<b>0.95</b>	0.60	0.94	<b>0.97</b>	0.93	0.77	<b>0.95</b>	0.80
AUROC	0.77	<b>0.98</b>	0.72	0.83	<b>0.97</b>	0.83	0.82	<b>0.96</b>	0.83
95% CI	0.49- 0.80	0.00- 1.00	0.518- 0.821	0.651- 0.945	0.702- 0.930	0.636- 0.934	0.575- 0.875	0.810- 0.990	0.605- 0.895
P value	0.069	0.001	0.041	0.002	0.001	0.002	0.0008	0.046	0.003

**Table 15 Diagnostic performance of APRI Index vs ARFI Elastography (Median Vs) vs FIB-4 Index using the cut-offs suggested by M. Friedrich-Rust et al for Liver Fibrosis<sup>(84)</sup>**

### **Observations Particular to our study**

Comparison between Fibrosis stage and Median Vs	N	Minimum	Maximum	Mean	Std. Deviation	Kruskal Walli's test
F0	14	0.90	1.31	1.1786	0.12799	P=0.001*
F1	9	1.02	1.35	1.1811	0.09880	
F2	7	1.25	1.63	1.4129	0.15052	
F3	8	1.35	2.32	1.5725	0.31963	
F4	12	1.53	3.90	2.6192	0.68931	
Total	50	.90	3.90	1.6206	0.68704	

**TABLE 16 Comparison of Median Shear Wave (Vs) speed measurements for different pathological stages of fibrosis.**



**Figure 23 Box Plots of the observed median shear wave velocities.**

<i>Stage of Liver Fibrosis</i>	<b>F<math>\geq</math>2</b>	<b>F<math>\geq</math>3</b>	<b>F=4</b>
<b>ARFI cut-off (m/s)</b>	1.37	1.51	1.87
<b>Sensitivity(%)</b>	56	60	83
<b>Specificity (%)</b>	89	80	97
<b>AUROC</b>	0.65	0.70	0.97

**Table 17 Cut-off values obtained from the AUROC analysis by maximising the Youden's Index**

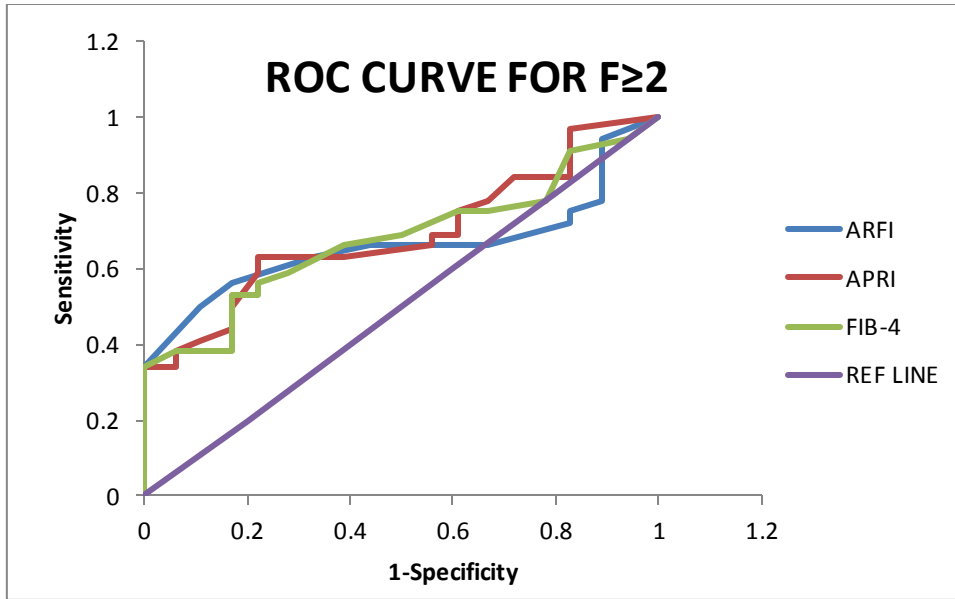


Figure 24 Showing AUROC curves using APRI Index (Red Line), ARFI elastography (Blue Line) & FIB-4 index (Green Line) as test curves in diagnosis of Significant Fibrosis & No/Non significant fibrosis considering histopathological outcomes (Liver Biopsy) the standard value curve represented in Purple.

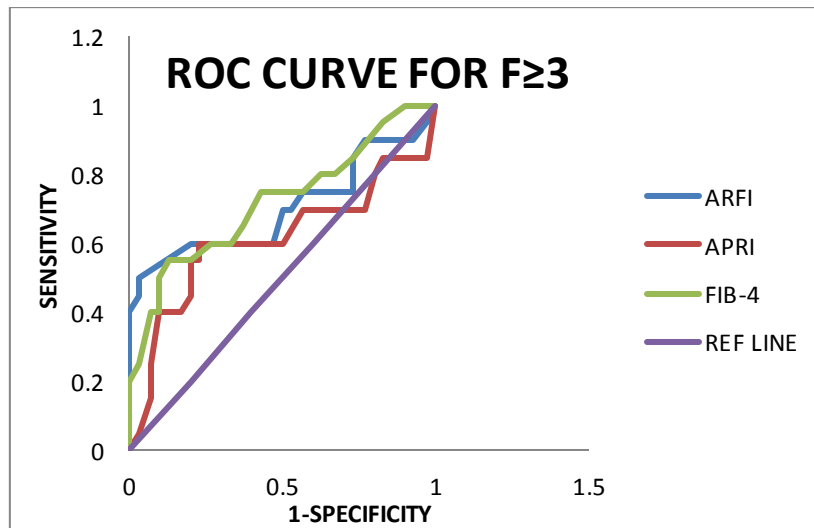
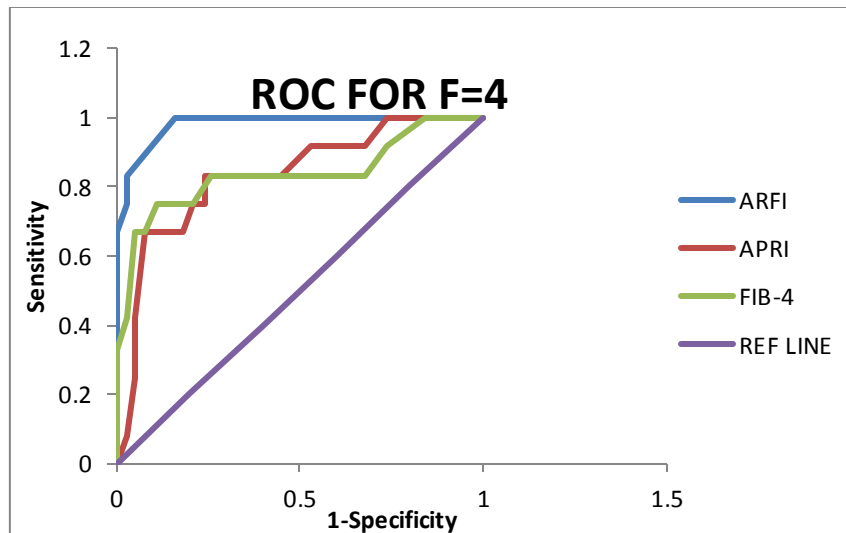


Figure 25 Showing AUROC curve using APRI Index (Red Line), ARFI elastography (Blue Line) & FIB-4 index (Green Line) as test curves in diagnosis of Severe Fibrosis & Significant Fibrosis Considering Histopathological outcomes (Liver Biopsy) as the standard value curve represented in Purple.





**Figure 26 Showing AUROC curve using APRI Index (Red Line), ARFI elastography (Blue Line) & FIB-4 index (Green Line) as test curves in diagnosis of Severe Fibrosis & Cirrhosis Considering Histopathological outcomes (Liver Biopsy) the standard value curve**

	<b>GROUP A (F=0+ F=1) vs. GROUP B (F=2)</b>	<b>GROUP C (F=3) vs. GROUP D (F=4)</b>	<b>GROUP B (F=2) vs. GROUP C (F=3)</b>
<b>Patients (n=50)</b>	<i>Median Vs</i>	<i>Median Vs</i>	<i>Median Vs</i>
<b>Sensitivity</b>	<b>0.56</b>	<b>0.83</b>	<b>0.60</b>
<b>Specificity</b>	<b>0.89</b>	<b>0.97</b>	<b>0.80</b>
<b>PPV</b>	<b>0.78</b>	<b>0.92</b>	<b>0.90</b>
<b>NPV</b>	<b>0.70</b>	<b>0.97</b>	<b>0.93</b>
<b>AUROC</b>	<b>0.65</b>	<b>0.97</b>	<b>0.70</b>
<b>95% CI</b>	0.00-1.00	0.810-0.990	0.702-0.930
<b>P value</b>	0.001	0.046	0.001

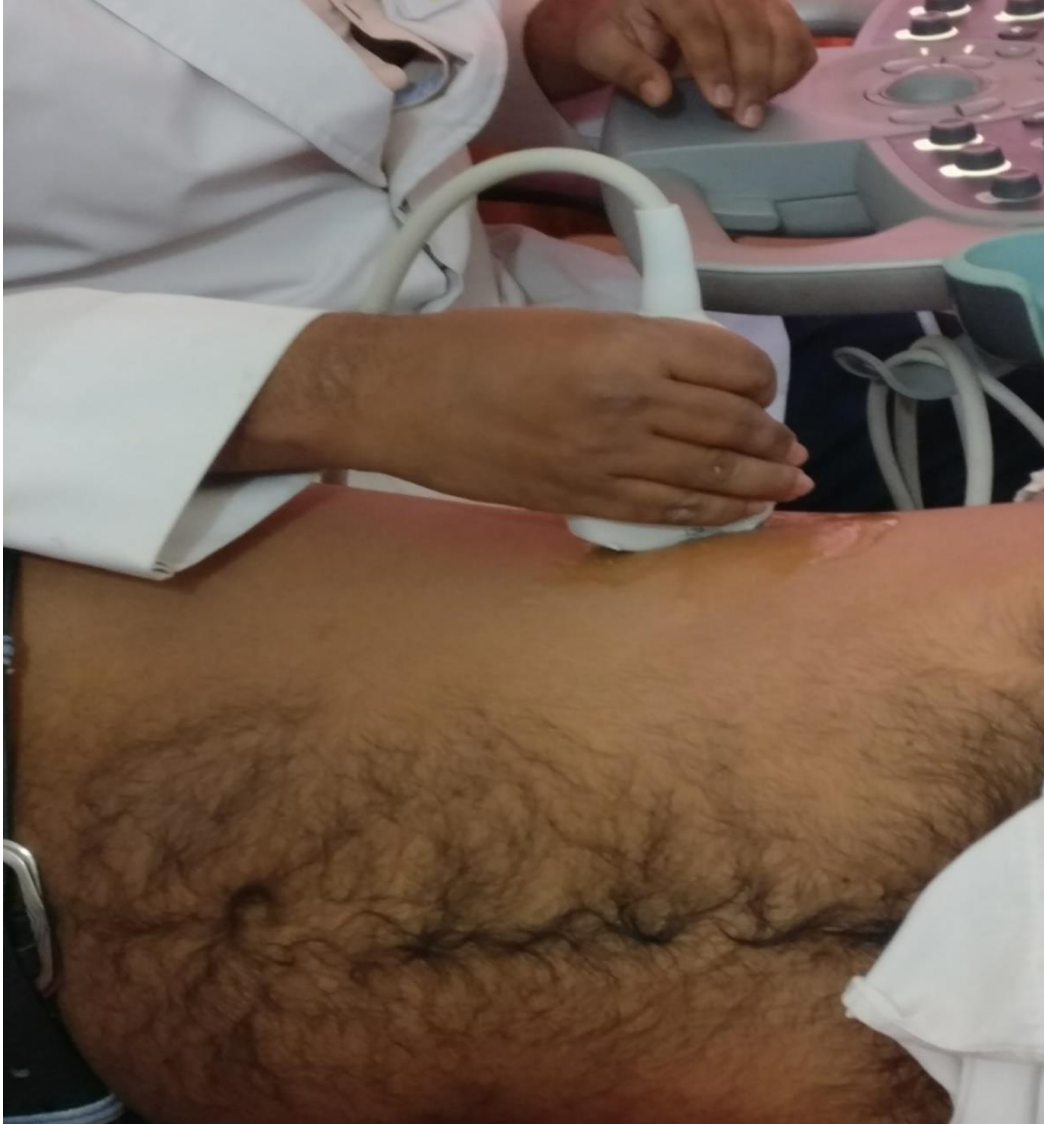**Table 18 Diagnostic performance of ARFI Elastography (Median Vs) using the cut-offs obtained based on our observations**

Based on the AUROC analysis there is a significant difference for all the three diagnostic tests in question except for APRI in distinguishing between the Non-

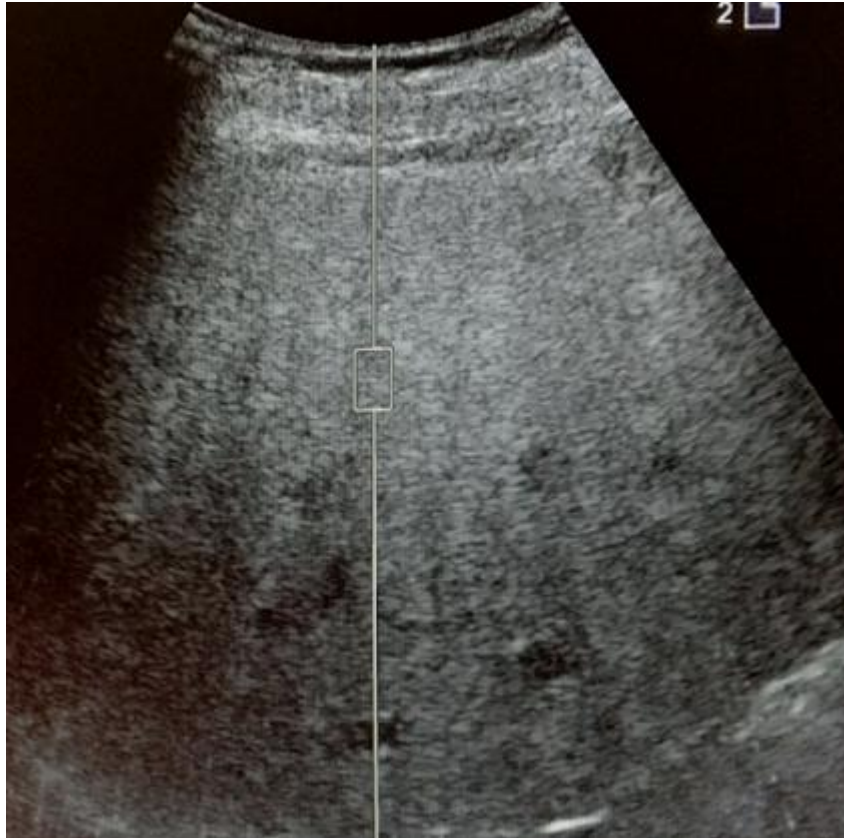
significant fibrosis and Significant fibrosis. Highest AUROC was derived for ARFI elastography followed by FIB-4 index and the APRI index in all the three subgroups to grade fibrosis. Within the fibrosis subgroups the AUROC was highest for the Non-significant vs the Significant fibrosis group followed by the, Implying the ability of ARFI elastography to better distinguish between the Non-significant & Significant Fibrosis.

In a nutshell the ARFI elastography outperforms both APRI and FIB-4 indices, as a diagnostic test. It also helps in distinguishing various stages of fibrosis better than APRI & FIB-4 indices. It also positively correlates {Pearson correlation (r): +0.76} with liver biopsy, the gold standard for Liver fibrosis.

## IMAGE GALLERY



**Figure 27 CORRECT PLACEMENT OF THE ULTRASOUND TRANSDUCER PERPENDICULAR TO THE SURFACE OF THE BODY WITH THE PATIENT IN THE LEFT LATERAL DECUBITUS POSITION**



**Figure 28 SELECTING THE CORRECT PLACEMENT OF ROI (REGION OF INTEREST) IN A HOMOGENOUS LIVER PARENCHYMA DEVOID OF ANY VESSELS AND THE ROI LINE IS PLACED PERPENDICULAR TO THE SURFACE.**

Abdomen Shear Velocity Measurements				
Site 1		Site 2		
Vs (m/s)	Depth (cm)	Vs (m/s)	Depth (cm)	
2.09	3.6	3.61	5.7	
2.11	3.6	3.25	5.6	
1.84	3.2	2.44	5.8	
1.95	3.2	3.11	5.8	
2.25	3.6	3.15	4.1	
2.25	3.6	3.50	4.6	
1.92	3.6	3.45	4.6	
2.20	3.1	3.21	4.6	
2.22	3.1	3.18	4.6	
2.58	3.1	3.30	4.6	
2.19	3.1			
Median	2.19		3.23	
Mean	2.15		3.22	
Std Dev	0.20		0.32	
IQR	0.30		0.30	
Overall Statistics				
	Median	2.44	Std Dev	0.61
	Mean	2.66	IQR	1.08

NOTE: Shear Wave Speed (Vs) values may vary among manufacturers!

**Figure 29 DISPLAY OF THE OBSERVED SHEAR WAVE VELOCITIES AND THE DEPTH FROM SURFACE AT WHICH THEY ARE MEASURED. THE MEDIAN SHEAR WAVE VELOCITY (Vs) IS ALSO DISPLAYED ALONG WITH THE MEAN, STANDARD DEVIATION AND INTERQUARTILE RANGE (IQR)**

## **DISCUSSION**

### **Age distribution:**

The age distribution of the patients in our study ranged from 24 to 62 years with the mean age being  $41.86 \pm 9.81$  years. In only the two other studies to our knowledge the mean age was  $40.73 \pm 9.49$  years<sup>(89)</sup> &  $43.8 \pm 10$  years.<sup>(90)</sup> Maximum subjects (n=17) were in the age group of 31-40 years which is the age group where maximum number of patients seek clinical attention due to diffuse alcoholic liver disease. Only TWO of the subjects were in the 7th decade of their life, since alcoholic cirrhosis as a high mortality elderly patients seeking clinical attention for liver disease that is clinically occult is not common. Seven patients were in the age group below 30 years, where there is increasing incidence of alcoholism in younger age group in this era. 15 subjects were in their fifties where sedentary lifestyle and other co-morbid conditions also play a role in the pathogenesis of liver disease.

### **Gender Distribution:**

All the subjects that were included in our study were males. The reason being the cultural practices of the Indian population wherein females are forbidden from drinking. However, in a study conducted on French population they included 69 males & 13 females.<sup>(90)</sup> While the study on Chinese population included 93 males and 6 females.<sup>(89)</sup>

### **Clinical Presentation:**

44% of the cases (n=22) were clinically asymptomatic even with chronic high risk drinking pattern, reflecting the indolent course of the evolution of liver fibrosis. 36% of the subjects had hepatomegaly on clinical examination and were sent to

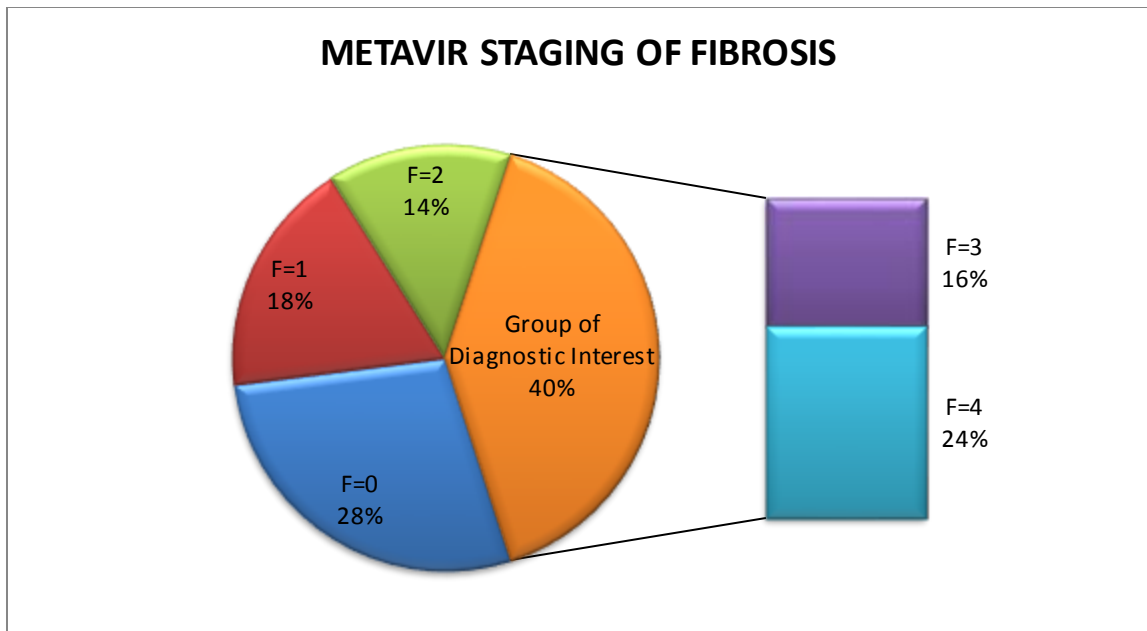
evaluate for the etiology. Causes of hepatomegaly are many and hence the physicians lean on biochemical tests and radiological evidence to determine the aetiology; which is why the supporting diagnostic tests need to be of high accuracy. 2D-Ultrasonography alone can detect various stages of the liver steatosis, as well as cirrhosis and signs of cirrhosis with portal hypertension, but by the time a diagnosis is made it's already too late to intervene. 20% of the study population included had been sent with some signs of cirrhosis of liver but the clinical signs alone were not helpful in labelling these patients as cirrhotic. An experienced clinician can make out an enlarged liver, can say if the surface is smooth or irregular and can even say where it is hard or soft. But it is beyond human capabilities to quantify the amount the hardness or softness when the difference is subtle. Elastography imaging techniques come to the rescue in such cases. When a patient visits a tertiary hospital and research centre, advanced techniques like elastography are available in such institutes and must be used to provide a better quality of care to the patients.

**Distribution of cases based on Pathological stages of Fibrosis: (what are the disadvantages of liver biopsy)**

Liver biopsy has been the gold standard for diffuse liver diseases for a long period now, yet an invasive procedure that many patients dislike or even are non-compliant to a doctor's advice. Nobody wants to stick a needle into their liver for petty reasons, for instance 44% of the study subjects were clinically asymptomatic and the first thing they asked us was if the biopsy was necessary in the first place. They were informed of the literature and the existing evidence based practices in medicine which helped them in making a better decision on what kind of care they would want to receive and they consented to undergo liver biopsy. However, of these 22 subjects 14 were diagnosed as having no fibrosis on METAVIR staging, while rest

of them had mild/non-significant fibrosis. The fact that even with high risk alcoholism, there wasn't any fibrosis in the liver so far was motivating enough for them to limit their alcohol intake. Now the question is what if the same decision could be made without the use of liver biopsy? Yes it is possible, and there are already several biochemical indices which have been clinically validated with certain amount of accuracy and have already been commercialised which will be discussed in detail further. But as radiologists we considered using elastography as one such easy diagnostic tool and evaluate how it would perform against the clinically available biochemical assays. However, the group of interest for clinicians is the severe fibrosis & cirrhosis which together constituted the 40% of included subjects. APRI & FIB-4 have been the indices that have been used by clinicians as an adjunct to determining the liver fibrosis. FIB-4 index can predict advanced fibrosis but it cannot distinguish between cirrhosis and severe fibrosis, which is of paramount importance since even advanced fibrosis is reversible contrary to cirrhosis which is irreversible. Even though APRI could do so, it performed inferior to the ARFI elastography technique that we used. Our study group also involved 9 patients with mild fibrosis & 7 patients with significant fibrosis. The METAVIR staging system also includes the Activity scoring, which is beyond the scope of this study.





**Figure 30 Case Distribution according to METAVIR staging of fibrosis showing group of interest.**

<b>Pathological Distribution</b>	<b>D. Zhang et al<sup>(89)</sup> {n(%)}</b>	<b>Anita Kiani et al<sup>(90)</sup> {n(%)}</b>	<b>Meta-Analysis by M. Friedrich-Rust et al<sup>(84)</sup> {n(%)}</b>	<b>Present Study {n(%)}</b>
<b>F=0</b>	2(2.02)	13(15.8)	39 (12.5)	14(28)
<b>F=1</b>	37(37.4)	35(42.7)	74(23.7)	9(18)
<b>F=2</b>	35(35.4)	17(20.7)	72(23.1)	7(14)
<b>F=3</b>	16(16.2)	4(4.9)	42(13.5)	8(16)
<b>F=4</b>	9(9.1)	13(15.8)	85(27.2)	12(24)
<b>Total</b>	<b>99</b>	<b>82</b>	<b>312</b>	<b>50</b>

**Table 19 Comparison of Pathological groups of Studies available in Literature.**

In comparison to the studies which we have compared the patients in our study had maximum percentage of cases in the No fibrosis (28%) & Cirrhosis (24%)

groups; However the percentage of cases in Non-Significant fibrosis (18%) & Significant Fibrosis were less than the other studies. Severe Fibrosis (16%) group was similar in size to that of the Chinese population study and more than the French population & Meta-analysis studies.

### **Role of APRI & FIB-4 index in liver fibrosis**

Of the 50 cases we studied only 6 cases could be classified to be probable of cirrhosis using the existing guidelines for application of APRI into clinical practice;<sup>(91,92)</sup> which is only half of the pathologically proven cirrhosis. 5 cases were deemed to be in the significant fibrosis group, 35 cases belonged to the no significant fibrosis group. However, 4 cases could not be definitely classified into either the significant fibrosis or the no fibrosis groups; a diagnostic dilemma that could only be solved by pathological staging. ARFI Elastography helps to solve this problem. The APRI also could not be utilised in distinguishing between significant and severe fibrosis, the diagnostic value of this differentiation may not have any implications as of now but with evolving concepts in management of the liver fibrosis it would be of paramount importance in the future. ARFI elastography attempts to resolve the dilemma and can be used in monitoring of response to therapy.

Similarly FIB-4 index was developed with incorporation of the age factor into the formula. It could make out 10 cases as having severe/advanced fibrosis, but there is no way it could determine if any of these cases had cirrhosis. This is one of the major drawbacks if intervention is planned to reverse the fibrosis from advanced fibrosis which can reverse in contrast to cirrhosis where there can only be regression rather than reversal. Upon that, FIB-4 index also failed to make out if there was advanced fibrosis or not in 9 of the cases we studied. However, it could rule out 31

cases to have no significant fibrosis, of which 30 were further pathologically proven not to have severe fibrosis.

### **Role of Elastography in Liver Fibrosis**

As discussed earlier there has been enough evidence with pooled meta-analysis studies to establish a clear advantage of different elastographic methods in diagnosis of liver fibrosis and cirrhosis. We chose to find out how well the ARFI elastographic method which is a shear wave based technique performs against the clinically used biochemical indices. We first used the standard WFUSMB guidelines on liver elastography to stratify the patients into four groups based on the observed median shear wave velocities.

<b>Stage of fibrosis (Based on shear wave velocities)</b>	<b>No. of Patients</b>
<b>No Fibrosis (F0) &amp; Non Significant fibrosis (F1)</b>	24
<b>Significant Fibrosis (<math>\geq</math>F2)</b>	9
<b>Severe Fibrosis (<math>\geq</math>F3)</b>	6
<b>Cirrhosis (F=4)</b>	11

**Table 20 Distribution of cases based on ARFI elastography using suggested cut-offs <sup>(84)</sup>**

Upon this we could accurately classify 11 out of the 12 cases to be cirrhotic, 6 of the 8 cases to be having severe fibrosis, 9 cases were staged to have significant fibrosis and 24 cases could be determined to have either no fibrosis / non-significant fibrosis. ROC curve analysis was done to determine the diagnostic accuracy for each of these stratified classes.

**The observed means of Vs for different stages of Fibrosis were as follows:**

In the 50 subjects we studied the observed shear wave velocities are shown in Table below.

<b>Comparison between Fibrosis stage and Median Vs</b>	<b>Number of subjects (n)</b>	<b>Minimum Vs(m/s)</b>	<b>Maximum Vs(m/s)</b>	<b>Mean Vs(m/s)</b>	<b>Standard Deviation</b>	<b>Kruskal Walli's test</b>
<b>F0</b>	14	0.90	1.31	<b>1.18</b>	<b>0.13</b>	P=0.001*
<b>F1</b>	9	1.02	1.35	<b>1.18</b>	<b>0.10</b>	
<b>F2</b>	7	1.25	1.63	<b>1.41</b>	<b>0.15</b>	
<b>F3</b>	8	1.35	2.32	<b>1.57</b>	<b>0.32</b>	
<b>F4</b>	12	1.53	3.90	<b>2.62</b>	<b>0.69</b>	
<b>Total</b>	50	0.90	3.90	1.62	0.69	

**Table 21 Mean of the Median Shear Wave Speed values with pathological diagnosis as the reference**

14 patients were detected to have no liver fibrosis (F=0) despite their high risk alcoholism status. The observed mean of Vs in these patients was  $1.18 \pm 0.13$  m/s which is comparable to the results of normal liver stiffness in *Indian men* i.e.  $1.195 \pm 0.25$  m/s by R. Madhok et al<sup>(70)</sup> and 1.0-1.29 m/s B. Raghuvanshi et al.<sup>(71)</sup> However, these studied did not have any liver biopsy validation. 9 subjects had non-significant fibrosis (F=1) with mean Vs of  $1.18 \pm 0.1$  m/s. There were no studies available to compare these values as the significance of these strata of the patients is of very limited value many authors did not report the results.

Seven subjects had Significant fibrosis (F=2) of liver with mean shear wave velocity of  $1.41 \pm 0.15$  m/s. These values observed in our study for significant fibrosis group were higher than the cut-off value of 1.34 m/s as suggested by Friedrich-Rust M et al<sup>(84)</sup> in their meta-analysis. D. Zhang et al reported Vs of  $1.42 \pm 0.36$  m/s in 35 patients that belonged to the significant fibrosis (F=2) group which are comparable to our observed results. However, Anita Kiani et al<sup>(90)</sup> in their study reported much higher values of  $1.86 \pm 0.42$  m/s for 17 patients in this group.

Eight subjects in our study belonged to the severe fibrosis group (F=3) with a mean Vs of  $1.57 \pm 0.32$  which is close to the cut off of 1.55 m/s suggested by Friedrich-Rust M et al.<sup>(84)</sup> Zhang et al in their study had 16 patients in this group with a mean Vs of  $1.89 \pm 0.67$  m/s which is much higher than both our observation as well as the cut off suggested by Friedrich-Rust M et al. Similar results were observed by Anita Kiani et al in their study which included only 4 patients in this group and showed a mean Vs of  $1.83 \pm 0.47$ . These values are higher than our observations and even similar to the F=2 group as observed in their study, which could confound distinction between the F=2 & F=3 group of patients.

Twelve (24%) of the cases we studied had cirrhosis (F=4) of liver and demonstrated a mean Vs of  $2.62 \pm 0.69$ . These values are much higher than the suggested 1.80 m/s cut-off,  $2.25 \pm 0.36$  m/s as seen in the study by Anita Kiani et al with 13 subjects in this group and  $2.11 \pm 0.54$  m/s as documented by Zhang et al with 9 patients in this subgroup.

	<b>Present Study</b>					
	<b>ARFI cut-off (m/s)</b>	<b>Sensitivity (%)</b>	<b>Specificity (%)</b>	<b>AUROC</b>	<b>PPV</b>	<b>NPV</b>
<b>F<math>\geq</math>2</b>	1.37	56	89	0.65	0.78	0.70
<b>F<math>\geq</math>3</b>	1.51	60	80	0.7	0.90	0.93
<b>F=4</b>	1.87	83	97	0.97	0.92	0.97
<b>Meta-Analysis by M. Friedrich-Rust et al<sup>(84)</sup></b>						
<b>F<math>\geq</math>2</b>	1.34	79	85	0.87	0.91	0.66
<b>F<math>\geq</math>3</b>	1.55	86	86	0.91	0.82	0.89
<b>F=4</b>	1.8	92	86	0.93	0.71	0.97
<b>D. Zhang et al<sup>(89)</sup></b>						
<b>F<math>\geq</math>2</b>	1.27	77	85	0.85	0.89	0.70
<b>F<math>\geq</math>3</b>	1.40	84	82	0.88	0.62	0.93
<b>F=4</b>	1.65	89	84	0.89	0.36	0.99
<b>Anita Kiani et al<sup>(90)</sup></b>						
<b>F<math>\geq</math>2</b>	1.63	82	83	0.87	0.78	0.87
<b>F<math>\geq</math>3</b>	1.84	82	78	0.86	0.50	0.94
<b>F=4</b>	1.94	92	82	0.89	0.48	0.98

**TABLE 22 Comparison of Cut-offs and Diagnostic performance of Present Study with Available meta-analysis.**

With results obtained in our study, it was possible to utilise the existing cut-offs for liver fibrosis of various aetiologies with a high AUROC for significant (AUROC -0.98), severe (AUROC -0.97) & (AUROC -0.96) cirrhosis stages of the alcoholic liver disease. However, when this model was not applied, only the cirrhosis group a clear advantage over the biochemical tests (AUROC -0.97). Severe (F=3) & Significant fibrosis groups showed diagnostic accuracy comparable to the biochemical tests (AUROC for F3-0.70 & AUROC for F2-0.65). Hence, we propose the existing cut-offs as suggested by Friedrich-Rust M et al can be utilised even in studies with smaller size and alcoholic liver disease such as the current study.

We also found a positive correlation between ARFI elastography & Liver Biopsy. In our study group there were 24 patients who did not have any significant liver fibrosis based on both ARFI elastography as well as the liver biopsy outcome. These strata of the patients constituted to be of 48% of the study population where a liver biopsy could have been avoided. And of the 30 cases (60%) who had advanced fibrosis based on liver biopsy, ARFI elastography was able to identify 11 of the 12 cirrhosis cases and even down staged one case to be of severe fibrosis with AUROC as high as 0.98 where in the liver biopsy could have been avoided. Similarly it could identify 6 of the 8 cases of severe fibrosis and down-staged two cases to be consisting of significant fibrosis. *ARFI elastography with the existing cut-offs is a reliable and accurate diagnostic test with potential to avoid liver biopsies in at least 72% of the cases if used as a screening tool.*

**Factors affecting the shear wave measurements.**<sup>(94,95)</sup>

- Significant increase in the shear wave speeds were noted after food intake.
- Shear wave velocities measured in standing position are higher than those measured in supine position when taken in a fasting state.
- In right heart failure, the ARFI values were elevated.
- Raised ALT levels significantly increased the shear wave velocities measured.

### **Advantages of ARFI elastography**

1. It doesn't require any additional hardware apart from the standard ultrasound scanner unlike the 1-D elastographic techniques.
2. The B-mode image can be used to select a proper homogenous region of interest and also avoid large vessels, dilated biliary radical etc.
3. In comparison to 1D-TE, where an external compression has to be applied the shear wave elastography produces shear waves which are induced locally inside the liver. Thus in a setting of ascites and obesity the shear wave elastography is more reliable.<sup>(4,96,97)</sup>
4. Similarly, the reproducibility is much better in the ARFI technique in comparison to the external excitation techniques such as the Fibroscan.
5. Since the ARFI method uses internal excitation of the tissue, physiologic motion such as the cardiac motion degrades the quality of the shear waves generated and hence it is unreliable to use the method on the left lobe of liver.<sup>(98,99)</sup>

### **Disadvantages of ARFI elastography**

1. General sonographic limitations viz. acoustic shadowing, reverberation, and clutter artefacts.
2. It is an operator dependent technique and hence a better learning curve is required.
3. The shear wave speeds measured are manufacturer specific, hence standard reference values cannot be compared across different ultrasound systems.



4. The depth upto which the elastographic measurements can be reliable is limited and is set to 8 cm for the ultrasound device we used.

### **Limitations of the present study**

- The sample size was relatively small.
- The study included only one observer in 60% of cases.
- The effect of right heart failure on liver stiffness measurements which is known to elevate the liver stiffness was not included in our study.
- Our study did not take into consideration the BMI, Age and ALT levels which are also factors that affect Liver Stiffness measurements.
- There was no comparison with Transient Elastography in our study.
- Shear wave elastography has been known to show considerable variations with different manufacturers, which was not included in our study.
- All the measurements were made in the right lobe of the liver only and comparison to left lobe was not done.
- The duration of alcohol consumption and its association with the liver stiffness was not considered in our study.

### **Future Directions**

- A larger cohort of the patients need be studied for future studies.
- Inter- & Intra-observer variability can be studied with observers having variable experience in the technique.

- With already promising evidence for ARFI elastography, a diagnostic algorithm that can include shear wave velocity needs to be obtained so that the need to order liver biopsy can be reduced to minimal number of cases with high diagnostic dilemma.
- With recent advancements MR Elastography has been shown to have promising results, so ARFI elastography needs to be compared to it and diagnostic accuracy and feasibility need to be studied.

## **SUMMARY**

- A total of 50 cases were studied, 12 of these were cirrhotic, 8 had severe fibrosis, 7 had significant fibrosis, 9 were having non-significant fibrosis and the rest of 14 cases had no fibrosis.
- Suggested cut off values as validated by M. Friedrich-Rust et al<sup>(84)</sup> had excellent diagnostic performance with AUROC of 0.98,0.97 & 0.96 for F=4, F $\geq$ 3 & F $\geq$ 2 stages respectively.
- The diagnostic value with our observed values had AUROC of 0.97,0.70 & 0.65 for F=4, F $\geq$ 3 & F $\geq$ 2 stages respectively.
- The cut-offs obtained with the observed values were 1.87,1.51 & 1.37 m/s for F=4, F $\geq$ 3 & F $\geq$ 2 stages respectively.

## **CONCLUSION**

- Liver fibrosis is a dynamic process and its progression is dependent on the chronic exposure of the liver to the alcohol. Reversal of liver fibrosis has been possible in severe fibrosis patients too, which is not the same with cirrhosis of Liver.
- Non-invasive assessment of the liver fibrosis has been gaining a lot of importance with respect to the treatment options available. If only alcohol is determined as the causal agent, then the treatment will include nonspecific nutritional support and cessation of alcohol consumption. It can be achieved with constant support from the treating physician and the psychiatrists who are actively involved.
- Staging of liver fibrosis helps the patients in a reward system behaviour where a patient is committed to detoxification and a regression or reversal of liver fibrosis encourages the patients to further comply with treatment.
- ARFI elastography is one such non-invasive diagnostic test which can be performed with the 2D- ultrasonographic study; it has an independent diagnostic ability to perform with AUROC of 0.98 for Cirrhosis.
- The available cut-off values of shear wave velocities have been well validated in this study with high diagnostic performance for significant ( $F \geq 2$ ) & severe ( $F \geq 3$ ) fibrosis and Cirrhosis as well.
- ARFI elastography does not add significant time to the 2-D Ultrasonography study. Hence can be performed along with the grayscale sonography. It also does not require separate mechanical push device as in transient elastography and hence is available incorporated into the standard probes that are used for routine sonographic examinations.

- Unlike the liver biopsy, ARFI elastography uses a region of interest that can be assessed for as many sample areas as possible and for as many repetitions as required. It can be performed even in patients with altered coagulation factors.
- ARFI elastography can be used as a screening tool in asymptomatic patients with suspected liver cirrhosis when biochemical tests reveal an abnormality or altered biochemical indices (for eg. APRI & FIB-4).
- Thus, ARFI elastography of the liver can reduce the need for liver biopsy if used in conjunction with the biochemical tests, a positive history of high risk chronic alcoholism and even 2D-Ultrasonography.

## **BIBLIOGRAPHY**

1. Cosgrove D. An overview of sonoelastography. *Hire*. 2009;4(2):47–8.
2. World Health Organization. WHO country profile -India. 2010.
3. Friedman SL. Hepatic fibrosis - overview. *Toxicology*. 2008 Dec;254(3):120–9.
4. Barr RG, Ferraioli G, Palmeri ML, Goodman ZD, Garcia-Tsao G, Rubin J, et al. Elastography Assessment of Liver Fibrosis: Society of Radiologists in Ultrasound Consensus Conference Statement. *Radiology*. 2015;000(0):150619.
5. Cadranet JF, Rufat P, Degos F. Practices of liver biopsy in France: results of a prospective nationwide survey. For the Group of Epidemiology of the French Association for the Study of the Liver (AFEFL). *Hepatology*. 2000 Sep;32(3):477–81.
6. Afdhal NH, Nunes D. Evaluation of Liver Fibrosis: A Concise Review. *Am J Gastroenterol*. 2004 Jun;99(6):1160–74.
7. Faria SC, Ganesan K, Mwangi I, Shieh-morteza M, Viamonte B, Mazhar S, et al. MR imaging of liver fibrosis: current state of the art. *Radiographics*. 2009;29(6):1615–35.
8. D’Onofrio M, Crosara S, de Robertis R, Canestrini S, Demozzi E, Gallotti A, et al. Acoustic radiation force impulse of the liver. *World J Gastroenterol*. 2013;19(30):4841–9.
9. Shi-Hao X, Qiao L, Yuan-Ping H, Ying L. Development of a model based on biochemical, real-time tissue elastography and ultrasound data for the staging

- of liver fibrosis and cirrhosis in patients with chronic hepatitis B. *Mol Med Rep.* 2016;
10. Malik R, Lai M, Sadiq A, Farnan R, Mehta S, Nasser I, et al. Comparison of transient elastography, serum markers and clinical signs for the diagnosis of compensated cirrhosis. *J Gastroenterol Hepatol.* 2010;25(9):1562–8.
  11. Royal T, Hospital M, Paper W. Best Practices for Detecting Liver Fibrosis with ARFI. 2015.
  12. Ferraioli G, Filice C, Castera L, Choi BI, Sporea I, Wilson SR, et al. WFUMB Guidelines and Recommendations for Clinical Use of Ultrasound Elastography: Part 3: Liver. *Ultrasound Med Biol.* 2015;41(5):1161–79.
  13. Kasper D, Fauci A, Hauser S, Longo D, Jameson J, Loscalzo J. *Harrison's Principles of Internal Medicine.* McGraw Hill Professional; 2015. 2052 p.
  14. Gore RM, Levine MS. *Textbook of Gastrointestinal Radiology.* 4Th Editio. Philadelphia, PA: Saunders; 2015. 1471-6 p.
  15. Gupta AK, Chowdhury V, Khandelwal N, editors. *Diagnostic Radiology: Gastrointestinal and Hepatobiliary Imaging.* Third edit. New Delhi: Jaypee Brothers Medical Publishers; 2009. 205-6 p.
  16. Butler P, Mitchell AWM, Ellis H, editors. *Applied Radiological Anatomy for Medical Students.* Cambridge: Cambridge University Press; 2007. 42-3 p.
  17. Applegate EJ. *The Sectional Anatomy Learning System: Concepts.* Third edit. Missouri: Saunders; 2010. 66-7 p.
  18. McWilliams S. *Practical Radiological Anatomy.* Boca Raton, FL: CRC Press;

2011. 155-6 p.

19. Mukai JK, Stack CM, Turner DA, Matalon TA, Gould RJ, Petasnick JP, et al. Imaging of surgically relevant hepatic vascular and segmental anatomy. Part 2. Extent and resectability of hepatic neoplasms. *Am J Roentgenol.* 1987;149(2):293–7.
20. Mukai JK, Stack CM, Turner DA, Matalon TA, Gould RJ, Petasnick JP, et al. Imaging of surgically relevant hepatic vascular and segmental anatomy. Part 1. Normal Anatomy. *Am J Roentgenol.* 1987;149(2):293–7.
21. Rutkauskas S, Gedrimas V, Pundzius J, Barauskas G, Basevicius A. Clinical and anatomical basis for the classification of the structural parts of liver. *Medicina (Kaunas).* 2006;42(2):98–106.
22. Dodds J, Erickson J, Stewart T, Taylor J. Caudate lobe of the liver: anatomy, embryology, and pathology. *Am J Roentgenol.* 1990;154(1):87–93.
23. Hill MA. The Liver Lobule [Internet]. UNSW Embryology. 2016 [cited 2016 Oct 6]. Available from: [https://embryology.med.unsw.edu.au/embryology/index.php/File:Liver\\_animated\\_cartoon.gif](https://embryology.med.unsw.edu.au/embryology/index.php/File:Liver_animated_cartoon.gif)
24. Kumar V, Abbas AK, Aster JC. Robbins and Cotran Pathologic Basis of Disease Professional Edition. 9th editio. Philadelphia, PA: Saunders; 2015. 425-7 p.
25. Seitz HK, Stickel F. Molecular mechanisms of alcohol-mediated carcinogenesis. *Nat Rev Cancer.* 2007 Aug;7(8):599–612.



26. Cederbaum AI. ALCOHOL METABOLISM. *Clin Liver Dis.* 2012 Nov;16(4):667–85.
27. Albano E. Alcohol, oxidative stress and free radical damage. *Proc Nutr Soc.* 2006 Aug;65(3):278–90.
28. Tsutsui H, Nishiguchi S. Importance of Kupffer Cells in the Development of Acute Liver Injuries in Mice. *Int J Mol Sci.* 2014 May 5;15(5):7711–30.
29. Anand BS. Cirrhosis of liver. *West J Med.* 1999 Aug;171(2):110–5.
30. Thun MJ, Peto R, Lopez AD, Monaco JH, Henley SJ, Heath CWJ, et al. Alcohol consumption and mortality among middle-aged and elderly U.S. adults. *N Engl J Med.* 1997 Dec;337(24):1705–14.
31. Peters MG, Terrault NA. Alcohol Use and Hepatitis C. *Hepatology* [Internet]. 2002 Nov;36(5 0 1):S220–5. Available from: <http://www.ncbi.nlm.nih.gov/pmc/articles/PMC4123319/>
32. Ochi T, Munekage K, Ono M, Higuchi T, Tsuda M, Hayashi Y, et al. Patatin-like phospholipase domain-containing protein 3 is involved in hepatic fatty acid and triglyceride metabolism through X-box binding protein 1 and modulation of endoplasmic reticulum stress in mice. *Hepatology Res.* 2016 May;46(6):584–92.
33. Diehl AM. Obesity and alcoholic liver disease. *Alcohol.* 2004 Aug;34(1):81–7.
34. Sabesin SM. Lipid and lipoprotein abnormalities in alcoholic liver disease. *Circulation.* 1981 Sep;64(3 Pt 2):III 72-84.
35. Marsano LS, Mendez C, Hill D, Barve S, McClain CJ. Diagnosis and treatment of alcoholic liver disease and its complications. *Alcohol Res Health.*

- 2003;27(3):247–56.
36. Crawford JM. Histologic Findings in Alcoholic Liver Disease. *Clin Liver Dis.* 2012;16(4):699–716.
  37. Halsted CH, Medici V. Vitamin-Dependent Methionine Metabolism and Alcoholic Liver Disease. *Adv Nutr.* 2011 Sep 6;2(5):421–7.
  38. Powell CL, Bradford BU, Craig CP, Tsuchiya M, Uehara T, O’Connell TM, et al. Mechanism for Prevention of Alcohol-Induced Liver Injury by Dietary Methyl Donors. *Toxicol Sci.* 2010 May 29;115(1):131–9.
  39. Luedde T, Schwabe RF. NF- $\kappa$ B in the liver—linking injury, fibrosis and hepatocellular carcinoma. *Nat Rev Gastroenterol Hepatol.* 2011 Feb;8(2):108–18.
  40. Ramadori G, Armbrust T. Cytokines in the liver. *Eur J Gastroenterol Hepatol.* 2001;13(7):777–84.
  41. Seki E, Brenner DA. Toll- like receptors and adaptor molecules in liver disease: update. *Hepatology.* 2008;48(1):322–35.
  42. Leite LN, Lacchini R, Carnio EC, Queiroz RH, Tanus-Santos JE, de Oliveira AM, et al. Ethanol consumption increases endothelin-1 expression and reactivity in the rat cavernosal smooth muscle. *Alcohol Alcohol.* 2013;48(6):657–66.
  43. Friedman SL. Liver fibrosis – from bench to bedside. *J Hepatol.* 2003;38:38–53.
  44. Alison MR, Vig P, Russo F, Bigger BW, Amofah E, Themis M, et al. Hepatic

- stem cells: from inside and outside the liver? *Cell Prolif.* 2004 Feb;37(1):1–21.
45. Cassiman D, Libbrecht L, Desmet V, Deneef C, Roskams T. Hepatic stellate cell/myofibroblast subpopulations in fibrotic human and rat livers. *J Hepatol.* 2002 Feb;36(2):200–9.
  46. Dooley S, Delvoux B, Lahme B, Mangasser-Stephan K, Gressner AM. Modulation of transforming growth factor beta response and signaling during transdifferentiation of rat hepatic stellate cells to myofibroblasts. *Hepatology.* 2000 May;31(5):1094–106.
  47. Preaux AM, Mallat A, Nhieu JT, D'Ortho MP, Hembry RM, Mavrier P. Matrix metalloproteinase-2 activation in human hepatic fibrosis regulation by cell-matrix interactions. *Hepatology.* 1999 Oct;30(4):944–50.
  48. Igarashi A, Nashiro K, Kikuchi K, Sato S, Ihn H, Fujimoto M, et al. Connective tissue growth factor gene expression in tissue sections from localized scleroderma, keloid, and other fibrotic skin disorders. *J Invest Dermatol.* 1996 Apr;106(4):729–33.
  49. Rockey DC. Hepatic blood flow regulation by stellate cells in normal and injured liver. *Semin Liver Dis.* 2001 Aug;21(3):337–49.
  50. Benyon RC, Arthur MJ. Extracellular matrix degradation and the role of hepatic stellate cells. *Semin Liver Dis.* 2001 Aug;21(3):373–84.
  51. Tsui P-H, Ho M-C, Tai D-I, Lin Y-H, Wang C-Y, Ma H-Y. Acoustic structure quantification by using ultrasound Nakagami imaging for assessing liver fibrosis. *Sci Rep.* 2016;6(April):33075.

52. Wright MC, Issa R, Smart DE, Trim N, Murray GI, Primrose JN, et al. Gliotoxin stimulates the apoptosis of human and rat hepatic stellate cells and enhances the resolution of liver fibrosis in rats. *Gastroenterology*. 2001 Sep;121(3):685–98.
53. Rumack CM. *Diagnostic Ultrasound*. Fourth edi. Philadelphia, PA: Mosby, Inc., an affiliate of Elsevier Inc.; 2011. 78-146 p.
54. Gosink BB, Leymaster CE. Ultrasonic determination of hepatomegaly. *J Clin Ultrasound*. 1981 Jan 1;9(1):37–41.
55. Brant WE, Helms C. *Fundamentals of Diagnostic Radiology*. Third Edi. Lippincott Williams & Wilkins; 2007.
56. Garra BS. Elastography: history, principles, and technique comparison. *Abdom Imaging*. 2015;40(4):680–97.
57. Tristram M, Barbosa DC, Cosgrove DO, Nassiri DK, Bamber JC, Hill CR. Ultrasonic study of in vivo kinetic characteristics of human tissues. *Ultrasound Med Biol*. 1986 Dec;12(12):927–37.
58. Lerner RM, Huang SR, Parker KJ. “Sonoelasticity” images derived from ultrasound signals in mechanically vibrated tissues. *Ultrasound Med Biol*. 1990;16(3):231–9.
59. Ophir J, Cespedes I, Ponnekanti H, Yazdi Y, Li X. Elastography: a quantitative method for imaging the elasticity of biological tissues. *Ultrason Imaging*. 1991 Apr;13(2):111–34.
60. Rubens J, Mayer D, Hadley A. Sonoelasticity Imaging of Prostate Cancer: In

- Vitro Results. *Radiology*. 1995;195:379–83.
61. Garra BS, Cespedes EI, Ophir J, Spratt SR, Zurbier RA, Magnant CM, et al. Elastography of breast lesions: initial clinical results. *Radiology*. 1997;202(1):79–86.
  62. Nightingale K, Bentley R, Trahey GE, Imaging U, Radiation A, Impulse F. Observations of tissue response to acoustic radiation force: opportunities for imaging. *Ultrason Imaging*. 2002;24(3):129–38.
  63. Ultrasonic Flaw Detection Tutorial [Internet]. Available from: <http://www.olympus-ims.com/en/ndt-tutorials/flaw-detection/wave-propagation/>
  64. Nightingale K. Acoustic Radiation Force Impulse (ARFI) Imaging: a Review. *Curr Med Imaging Rev*. 2012;7(4):328–39.
  65. Doherty J, Trahey G, Nightingale K, Palmeri M. Acoustic radiation force elasticity imaging in diagnostic ultrasound. *IEEE Trans Ultrason Ferroelectr Freq Control*. 2013;60(4):685–701.
  66. Jeong WK, Lim HK, Lee H-K, Jo JM, Kim Y. Principles and clinical application of ultrasound elastography for diffuse liver disease. *Ultrason (Seoul, Korea)*. 2014;33(3):149–60.
  67. Sigrist RMS, Liao J, Kaffas A El, Chammas MC, Willmann JK. Ultrasound elastography: Review of techniques and clinical applications. *Theranostics*. 2017;7(5):1303–29.
  68. Talwalkar JA, Kurtz DM, Schoenleber SJ, West CP, Montori VM. Ultrasound-

- based transient elastography for the detection of hepatic fibrosis: Systematic review and meta-analysis. *Clin Gastroenterol Hepatol.* 2007;5(10):1214–20.
69. Kircheis G, Sagir A, Vogt C, Dahl S Vom, Kubitz R, Häussinger D. Evaluation of acoustic radiation force impulse imaging for determination of liver stiffness using transient elastography as a reference. *World J Gastroenterol.* 2012;18(10):1077–84.
70. Madhok R, Tapasvi C, Prasad U, Gupta AK, Aggarwal A. Acoustic Radiation Force Impulse Imaging of the Liver: Measurement of the Normal Mean Values of the Shearing Wave Velocity in a Healthy Liver. *J Clin Diagn Res.* 2013 Jan;7(1):39–42.
71. Raghuwanshi B, Jain N, Jain M. Normal values in healthy liver in central India by acoustic radiation force impulse imaging. *J Clin Diagnostic Res.* 2013;7(11):2498–501.
72. Kim JE, Lee JY, Kim YJ, Yoon JH, Kim SH, Lee JM, et al. Acoustic Radiation Force Impulse Elastography for Chronic Liver Disease: Comparison with Ultrasound-Based Scores of Experienced Radiologists, Child-Pugh Scores and Liver Function Tests. *Ultrasound Med Biol.* 2010;36(10):1637–43.
73. Fierbinteanu-Braticevici C, Andronescu D, Usvat R, Cretoiu D, Baicus C, Marinoschi G. Acoustic radiation force imaging sonoelastography for noninvasive staging of liver fibrosis. *World J Gastroenterol.* 2009;15(44):5525–32.
74. Sporea I, Sirli R, Bota S, Fierbințeanu-Braticevici C, Petrișor A, Badea R, et al. Is ARFI elastography reliable for predicting fibrosis severity in chronic HCV

- hepatitis? *World J Radiol.* 2011;3(7):188–93.
75. Palmeri ML, Wang MH, Rouze NC, Abdelmalek MF, D. C, Guy, et al. Noninvasive evaluation of hepatic fibrosis using acoustic radiation force-based shear stiffness in patients with nonalcoholic fatty liver disease. *J Hepatol.* 2011;55(3):666–72.
76. Ye XP, Ran HT, Cheng J, Zhu YF, Zhang DZ, Zhang P, et al. Liver and spleen stiffness measured by acoustic radiation force impulse elastography for noninvasive assessment of liver fibrosis and esophageal varices in patients with chronic hepatitis B. *J Ultrasound Med.* 2012;31(8):1245–53.
77. Sun X, Liang L, Cao H, Men Q, Hou K, Chen Z, et al. Liver reserve function assessment by acoustic radiation force impulse imaging. 2015;21(32):9648–55.
78. Sporea I, Badea R, Sirli R, Lupsor M, Popescu A, Danila M, et al. How efficient is acoustic radiation force impulse elastography for the evaluation of liver stiffness? *Hepat Mon.* 2011;11(7):532–8.
79. Bota S, Sporea I, Sirli R, Popescu A, Dănilă M, Sendroiu M. Value of acoustic radiation force impulse elastography for the assessment of ascites syndrome. *World J Radiol.* 2011;3(8):205–9.
80. Jaffer OS, Lung PFC, Bosanac D, Patel VM, Ryan SM, Heneghan MA, et al. Acoustic radiation force impulse quantification: Repeatability of measurements in selected liver segments and influence of age, body mass index and liver capsule-to-box distance. *Br J Radiol.* 2012;85(1018):858–63.
81. Friedrich-Rust M, Romen D, Vermehren J, Kriener S, Sadet D, Herrmann E, et al. Acoustic radiation force impulse-imaging and transient elastography for

- non-invasive assessment of liver fibrosis and steatosis in NAFLD. *Eur J Radiol.* 2012 Mar;81(3):e325-331.
82. Fontanilla T, Canas T, Macia A, Alfageme M, Gutierrez Junquera C, Malalana A, et al. Normal values of liver shear wave velocity in healthy children assessed by acoustic radiation force impulse imaging using a convex probe and a linear probe. *Ultrasound Med Biol.* 2014 Mar;40(3):470–7.
83. Bota S, Herkner H, Sporea I, Salzl P, Sirli R, Neghina AM, et al. Meta-analysis: ARFI elastography versus transient elastography for the evaluation of liver fibrosis. *Liver Int.* 2013;33(8):1138–47.
84. Friedrich-Rust M, Nierhoff J, Lupsor M, Sporea I, Fierbinteanu-Braticevici C, Strobel D, et al. Performance of Acoustic Radiation Force Impulse imaging for the staging of liver fibrosis: A pooled meta-analysis. *J Viral Hepat.* 2012;19(2):212–9.
85. Rizzo L, Calvaruso V, Cacopardo B, Alessi N, Attanasio M, Petta S, et al. Comparison of Transient Elastography and Acoustic Radiation Force Impulse for Non-Invasive Staging of Liver Fibrosis in Patients With Chronic Hepatitis C. *Am J Gastroenterol.* 2011 Dec;106(12):2112–20.
86. Leung VY, Shen J, Wong VW, Abrigo J, Wong GL, Chim AM, et al. Quantitative elastography of liver fibrosis and spleen stiffness in chronic hepatitis B carriers: comparison of shear-wave elastography and transient elastography with liver biopsy correlation. *Radiology.* 2013;269(3):910–8.
87. Bota S, Sporea I, Sirli R, Popescu A, Danila M, Jurchis A, et al. Factors associated with the impossibility to obtain reliable liver stiffness measurements



- by means of Acoustic Radiation Force Impulse (ARFI) elastography--analysis of a cohort of 1,031 subjects. *Eur J Radiol.* 2014 Feb;83(2):268–72.
88. Gerber L, Kasper D, Fitting D, Knop V, Vermehren A, Sprinzl K, et al. Assessment of liver fibrosis with 2-D shear wave elastography in comparison to transient elastography and acoustic radiation force impulse imaging in patients with chronic liver disease. *Ultrasound Med Biol.* 2015 Sep;41(9):2350–9.
  89. Zhang D, Li P, Chen M, Liu L, Liu Y, Zhao Y, et al. Non-invasive assessment of liver fibrosis in patients with alcoholic liver disease using acoustic radiation force impulse elastography. *Abdom Imaging.* 2014;40(4):723–9.
  90. Kiani A, Brun V, Lainé F, Turlin B, Morcet J, Michalak S, et al. Acoustic radiation force impulse imaging for assessing liver fibrosis in alcoholic liver disease. *World J Gastroenterol.* 2016;22(20):4926.
  91. Lin Z-H, Xin Y-N, Dong Q-J, Wang Q, Jiang X-J, Zhan S-H, et al. Performance of the aspartate aminotransferase-to-platelet ratio index for the staging of hepatitis C-related fibrosis: an updated meta-analysis. *Hepatology.* 2011 Mar;53(3):726–36.
  92. Chou R, Wasson N. Blood tests to diagnose fibrosis or cirrhosis in patients with chronic hepatitis C virus infection: a systematic review. *Ann Intern Med.* 2013 Jun;158(11):807–20.
  93. Sterling RK, Lissen E, Clumeck N, Sola R, Correa MC, Montaner J, et al. Development of a simple noninvasive index to predict significant fibrosis in patients with HIV/HCV coinfection. *Hepatology.* 2006 Jun;43(6):1317–25.

94. Goertz RS, Egger C, Neurath MF, Strobel D. Impact of food intake, ultrasound transducer, breathing maneuvers and body position on acoustic radiation force impulse (ARFI) elastometry of the liver. *Ultraschall Med.* 2012 Aug;33(4):380–5.
95. Popescu A, Bota S, Sporea I, Sirli R, Danila M, Racean S, et al. The Influence of Food Intake on Liver Stiffness Values Assessed by Acoustic Radiation Force Impulse Elastography ;Preliminary Results. *Ultrasound Med Biol.* 2016 Dec 12;39(4):579–84.
96. Tang A, Cloutier G, Szeverenyi NM, Sirlin CB. Ultrasound elastography and MR elastography for assessing liver fibrosis: Part 1, principles and techniques. *Am J Roentgenol.* 2015;205(1):22–32.
97. Shiina T, Nightingale KR, Palmeri ML, Hall TJ, Bamber JC, Barr RG, et al. Wfumb Guidelines and Recommendations for Clinical Use of Ultrasound Elastography: Part 1: Basic Principles and Terminology. *Ultrasound Med Biol.* 2015;41(5):1126–47.
98. Samir AE, Dhyani M, Vij A, Bhan AK, Halpern EF, Méndez-Navarro J, et al. Shear-wave elastography for the estimation of liver fibrosis in chronic liver disease: determining accuracy and ideal site for measurement. *Radiology.* 2015;274(3):888–96.
99. Toshima T, Shirabe K, Takeishi K, Motomura T, Mano Y, Uchiyama H, et al. New method for assessing liver fibrosis based on acoustic radiation force impulse: a special reference to the difference between right and left liver. *J Gastroenterol.* 2011 May;46(5):705–11.

## ANNEXURE-I

### ETHICAL COMMITTEE CLEARANCE CERTIFICATE



B.L.D.E. UNIVERSITY'S  
SHRI.B.M.PATIL MEDICAL COLLEGE, BIJAPUR-586 103  
INSTITUTIONAL ETHICAL COMMITTEE



#### **INSTITUTIONAL ETHICAL CLEARANCE CERTIFICATE**

The Ethical Committee of this college met on 04/10/2016 at 3-00pm to scrutinize the Synopsis of Postgraduate Students of this college from Ethical Clearance point of view. After scrutiny the following original/corrected & revised version synopsis of the Thesis has been accorded Ethical Clearance.

Title Acoustic radiation force impulse imaging for assessing liver fibrosis in alcoholic liver disease

Name of P.G. student Iranna Maliappa Hittalamani  
Dept of Radiodiagnosis

Name of Guide/Co-investigator Dr Remesh C Pattansetti  
Professor of Radiodiagnosis

DR. TEJASWINI VALLABHA  
CHAIRMAN  
INSTITUTIONAL ETHICAL COMMITTEE  
BLDEU'S, SHRI.B.M.PATIL  
MEDICAL COLLEGE, BIJAPUR.

Following documents were placed before E.C. for Scrutinization

- 1) Copy of Synopsis/Research project.
- 2) Copy of informed consent form
- 3) Any other relevant documents.

## **ANNEXURE-II**

### **PROFORMA**

**B. L. D. E. (DEEMED TO BE UNIVERSITY)**

**SHRI B. M. PATIL MEDICAL COLLEGE, HOSPITAL & RESEARCH  
CENTRE, VIJAYAPURA**

**“ACOUSTIC RADIATION FORCE IMPULSE IMAGING FOR ASSESSING  
LIVER FIBROSIS IN ALCOHOLIC LIVER DISEASE”**

#### **CASE SHEET PROFORMA**

**NAME:**

**AGE:**

**SEX:**

**IP/OP NO:**

**CHIEF COMPLAINTS:**

**DETAILED HISTORY: Chronic alcoholism**

**RELEVANT CLINICAL EXAMINATION FINDINGS:**

**Jaundice**

**Fetor hepaticus—a sweet, pungent breath odor**

**Scleral icterus**

**Ascites**

**Asterixis**

**Hepatomegaly**

**Splenomegaly**

**Clubbing and hypertrophic osteoarthropathy.**

**Gynecomastia**

**PROVISIONAL CLINICAL DIAGNOSIS:**

**RADIOLOGICAL FINDINGS:**

<b>2D USG findings</b>	<b>Shear wave velocity (MEDIAN)</b>	<b>Fibrosis Grading</b>

**BIOCHEMICAL PROFILE**

<b>TESTS</b>	<b>VALUES</b>
<b>AST</b>	
<b>ALT</b>	
<b>SERUM BILIRUBIN TOTAL</b>	
<b>SERUM BILIRUBIN DIRECT</b>	
<b>SERUM BILIRUBIN INDIRECT</b>	
<b>PLATELET COUNT</b>	
<b>PROTHROMBIN TIME</b>	
<b>APRI</b>	
<b>FIB-4</b>	

## **ANNEXURE-III**

### **CONSENT FORM**

**TITLE OF RESEARCH: ACOUSTIC RADIATION FORCE IMPULSE  
IMAGING FOR ASSESSING LIVER FIBROSIS IN ALCOHOLIC LIVER  
DISEASE**

**GUIDE: DR. RAMESH C PATTANSHETTI**

**P.G. STUDENT: DR. IRANNA MALLAPPA HITTALAMANI**

#### **PURPOSE OF RESEARCH:**

I have been informed that the purpose of this study is to assess the role of Elastography in differentiating benign and malignant breast lesions.

#### **PROCEDURE:**

I understand that I will undergo history, clinical examination, ultrasonographic/elastographic examination and FNAC/Histopathological follow up.

#### **RISKS AND DISCOMFORTS:**

I understand that there is no risk involved and I may experience mild pain during the above mentioned procedures.

#### **BENEFITS:**

I understand that my participation in this study will help to assess the role of Elastography in evaluating breast lesions.

#### **CONFIDENTIALITY:**

I understand that the medical information produced by the study will become a part of hospital record and will be subjected to confidentiality and privacy regulations of hospital. If the data is used for publications the identity of the patient will not be revealed.

**REQUEST FOR MORE INFORMATION:**

I understand that I may ask for more information about the study at any time.

**REFUSAL OR WITHDRAWAL OF PARTICIPATION:**

I understand that my participation is voluntary and I may refuse to participate or withdraw from study at any time

**INJURY STATEMENT:**

I understand in the unlikely event of injury to me during the study I will get medical treatment but no further compensations. I will not hold the hospital and its staff responsible for any untoward incidence during the course of study.

**I have read the foregoing information, or it has been explained to me in my own language. I have had the opportunity to ask questions about it and any questions that I have asked have been answered to my satisfaction. I consent voluntarily to participate as a participant in this research.**

Name of Participant

Signature of Participant/Thumb  
print of participant

Name of Witness

Signature of Witness/Thumb print  
of Witness

## **KEY TO MASTER CHART**

**Median Vs-** Median Shear Wave velocity

**FIB4-** Fibrosis-4 Index

**APRI-** AST to Platelet Ratio Index

**F0-**No fibrosis

**F1-**Stellate enlargement of portal tract(portal fibrosis) but without septa formation

**F2-**Enlargement of portal tract with rare septa formation

**F3-**Numerous septa without cirrhosis

**F4-**Cirrhosis

**A0-**No inflammation

**A1-**Mild inflammation

**A2-**Moderate inflammation

**A3-**Severe inflammation



**MASTER CHART**

Sl no	NAME	AGE (in years)	Median Vs (in m/s)	APRI	FIB-4	Clinical diagnosis	Pathological diagnosis	GRADES OF LIVER FIBROSIS		
								Using Vs	Using APRI	Using FIB-4
1	AHMAD HUSEN	46	1.61	1.233	1.97	Hepatomegaly	F=2, A=1	≥F3	F=0/1	F=0/1
2	B S NEGINAL	45	1.1	0.126	0.47	Hepatomegaly	F=1, A=0	F=0/1	F=0/1	F=0/1
3	BASAVARAJ	35	2.45	2.373	5.97	Suspected case of Cirrhosis	F=4, A=2	F4	F4	≥F3
4	BASAVARAJ	24	1.4	0.2	0.38	Clinically asymptomatic	F=2, A=1	≥F2	F=0/1	F=0/1
5	BHIMANAGOUDA	40	1.53	0.26	0.56	Hepatomegaly	F=3, A=1	≥F2	F=0/1	F=0/1
6	BHIMARAY	29	1.05	0.16	0.36	Clinically asymptomatic	F=0, A=0	F=0/1	F=0/1	F=0/1
7	C R SAGAR	51	1.27	0.173	0.94	Hepatomegaly	F=0, A=0	F=0/1	F=0/1	F=0/1
8	DR BASAVARAJ RODAGI	59	2.89	2.256	3.52	Suspected case of Cirrhosis	F=4, A=3	F4	F4	≥F3
9	Dr PRAKASH M	52	2.32	1.795	4.6	Suspected case of Cirrhosis	F=4, A=2	F4	≥F2	≥F3
10	GANESH	29	2.94	0.505	0.55	Hepatomegaly	F=4, A=2	F4	F=0/1	F=0/1
11	H M JALAGAR	44	1.39	0.262	1.06	Hepatomegaly	F=3, A=0	≥F2	F=0/1	F=0/1
12	ISHWAR	50	2.57	1.607	3.99	Suspected case of Cirrhosis	F=4, A=1	F4	≥F2	≥F3
13	M A HADIMANI	50	0.96	0.113	0.48	Clinically asymptomatic	F=0, A=0	F=0/1	F=0/1	F=0/1
14	MANJUNATH	31	1.31	0.243	0.43	Clinically asymptomatic	F=0, A=0	F=0/1	F=0/1	F=0/1
15	PRAKASH P	50	1.35	0.42	1.22	Clinically asymptomatic	F=3, A=2	≥F2	F=0/1	F=0/1
16	R R LODI	32	1.17	0.601	2.13	Clinically asymptomatic	F=1, A=0	F=0/1	F=0/1	≥F2
17	RAJENDRA S PRASAD	51	1.12	0.188	0.86	Hepatomegaly	F=1, A=0	F=0/1	F=0/1	F=0/1
18	S H BARAGANI	41	1.21	0.162	0.58	Clinically asymptomatic	F=0, A=0	F=0/1	F=0/1	F=0/1
19	S M KALAGI	46	1.21	0.255	0.8	Hepatomegaly	F=0, A=0	F=0/1	F=0/1	F=0/1
20	S S KAGWAD	32	1.63	0.305	0.5	Hepatomegaly	F=2, A=1	≥F3	F=0/1	F=0/1
21	S Y KURI	58	1.02	0.135	0.78	Clinically asymptomatic	F=1,A=0	F=0/1	F=0/1	F=0/1
22	SANJAY	29	1.36	0.369	0.79	Clinically asymptomatic	F=2,A=1	≥F2	F=0/1	F=0/1
23	SHANKARGOUDA	29	1.19	1.134	1.84	Hepatomegaly	F=0, A=0	F=0/1	F=0/1	≥F2
24	SHARANAPPA	35	1.15	0.37	0.84	Fatty liver	F=1,A=0	F=0/1	F=0/1	F=0/1
25	SHIVAKUMAR HITTALAMANI	54	1.21	0.239	1.07	Clinically asymptomatic	F=1,A=0	F=0/1	F=0/1	F=0/1
26	SHIVANNA	45	1.31	0.145	0.82	Clinically asymptomatic	F=0, A=0	F=0/1	F=0/1	F=0/1
27	SIDDAPPA	40	1.36	0.255	0.73	Hepatomegaly	F=2,A=0	≥F2	F=0/1	F=0/1
28	SIDDU	38	1.25	0.356	0.81	Hepatomegaly	F=0, A=0	F=0/1	F=0/1	F=0/1
29	SURENDRA	45	1.35	0.891	2.22	Hepatomegaly	F=1, A=0	≥F2	F=0/1	≥F2
30	SY SHAHAPUR	52	1.24	0.142	0.6	Clinically asymptomatic	F=1, A=0	F=0/1	F=0/1	F=0/1

31	U R BENKI	28	1.3	0.518	0.53	Hepatomegaly	F=0, A=0	F=0/1	F=0/1	F=0/1
32	VEERENDRA YARANAL	46	1.63	2.32	4.55	Clinically asymptomatic	F=3, A=2	≥F3	F4	≥F3
33	BHIMASHANKAR BANSODE	42	0.9	0.46	1.64	Clinically asymptomatic	F=0, A=0	F=0/1	F=0/1	≥F2
34	GANESH PATIL	38	1.12	0.386	1.31	Clinically asymptomatic	F=0, A=0	F=0/1	F=0/1	F=0/1
35	HUSENBASHA	55	1.57	0.378	1.55	Hepatomegaly	F=4, A=1	≥F3	F=0/1	≥F2
36	KASHAYYA	35	3.06	5.95	9.14	Suspected case of Cirrhosis	F=4, A=2	F4	F4	≥F3
37	MANJUNATH BIRADAR	25	1.23	0.374	0.73	Clinically asymptomatic	F=0, A=0	F=0/1	F=0/1	F=0/1
38	PUNDALIK	60	1.36	0.455	1.54	Clinically asymptomatic	F=3, A=1	≥F2	F=0/1	≥F2
39	SANGANABASU	62	1.53	0.573	2.25	Hepatomegaly	F=4, A=1	≥F3	F=0/1	≥F2
40	SHARANAPPA GOUDAR	45	1.27	5.95	1.68	Hepatomegaly	F=1, A=1	F=0/1	F4	≥F2
41	VENKATESH	44	2.05	0.224	0.72	Suspected case of Cirrhosis	F=4, A=1	F4	F=0/1	F=0/1
42	SIDDAPPA	52	1.58	0.89	2.9	Clinically asymptomatic	F=3, A=1	≥F3	F=0/1	≥F2
43	RAVUTAPPA	49	3.9	2.6	9.2	Suspected case of Cirrhosis	F=4, A=2	F4	F4	≥F3
44	MALLANNA	39	1.28	0.45	0.82	Clinically asymptomatic	F=2, A=1	F=0/1	F=0/1	F=0/1
45	IMAMBU	32	3.26	1.89	5.94	Suspected case of Cirrhosis	F=4, A=1	F4	≥F2	≥F3
46	SHIVAKUMAR WARAD	38	1.19	0.4	0.75	Clinically asymptomatic	F=0, A=0	F=0/1	F=0/1	F=0/1
47	GOUDAPPAGOUDA KOTI	40	1.42	0.45	0.86	Clinically asymptomatic	F=3, A,1	≥F2	F=0/1	F=0/1
48	SHIVAPPA INDI	35	2.89	1.8	3.6	Suspected case of Cirrhosis	F=4, A=2	F4	≥F2	≥F3
49	SALIM SHAIKH	34	2.32	1.722	3.95	Suspected case of Cirrhosis	F=3, A=1	F4	≥F2	≥F3
50	PARASHURAM	32	1.25	0.385	0.82	Clinically asymptomatic	F=2, A=0	F=0/1	F=0/1	F=0/1